



Bleeding control of an injury to the infrarenal inferior vena cava and right external iliac vein by ipsilateral internal iliac artery and superficial femoral vein ligation after blunt abdominal trauma in Korea: a case report

Hoonsung Park, MD , Maru Kim, MD , Dae-Sang Lee, MD , Tae Hwa Hong, MD , Doo-Hun Kim, MD , Hangjoo Cho, MD

Department of Trauma Surgery, Uijeongbu St. Mary's Hospital, College of Medicine, The Catholic University of Korea, Uijeongbu, Korea

Inferior vena cava (IVC) injuries, while accounting for fewer than 0.5% of blunt abdominal trauma cases, are among the most difficult to manage. Despite advancements in prehospital care, transportation, operative techniques, and perioperative management, the mortality rate for IVC injuries has remained at 20% to 66% for several decades. Furthermore, 30% to 50% of patients with IVC injuries succumb during the prehospital phase. A 65-year-old male patient, who had been struck in the back by a 500-kg excavator shovel at a construction site, was transported to a regional trauma center. Injuries to the right side of the infrarenal IVC and the right external iliac vein (EIV) were suspected, along with fractures to the right iliac bone and sacrum. The injury to the right side of the infrarenal IVC wall was repaired, and the right internal iliac artery was ligated. However, persistent bleeding around the right EIV was observed, and we were unable to achieve proximal and distal control of the right EIV. Attempts at prolonged manual compression were unsuccessful. To decrease venous return, we ligated the right superficial femoral vein. This reduced the amount of bleeding, enabling us to secure the surgical field. We ultimately controlled the bleeding, and approximately 5 L of blood products were infused intraoperatively. A second-look operation was performed 2 days later, by which time most of the bleeding sites had ceased. Orthopedic surgeons then took over the operation, performing closed reduction and external fixation. Five days later, the patient underwent definitive fixation and was transferred for rehabilitation on postoperative day 22.

Keywords: Inferior vena cava injury; External iliac vein injury; Blunt abdominal trauma; Superficial femoral vein ligation; Case reports

Received: April 5, 2023
Revised: August 15, 2023
Accepted: August 21, 2023

Correspondence to
Hangjoo Cho, MD
Department of Trauma Surgery,
Uijeongbu St. Mary's Hospital, College
of Medicine, The Catholic University of
Korea, 271 Cheonbo-ro, Uijeongbu
11765, Korea
Tel: +82-31-820-5066
Email: surgeryman@catholic.ac.kr

INTRODUCTION

Inferior vena cava (IVC) injuries, which account for less than 0.5% of blunt abdominal trauma, are among the most challeng-

ing to manage [1]. Despite advancements in prehospital care, transportation, operative techniques, and perioperative management, the mortality rate has remained unchanged for decades [2]. The mortality rate associated with IVC injuries is notably

high, ranging from 20% to 66%. Furthermore, 30% to 50% of patients with an IVC injury succumb during the prehospital phase [3].

The incidence rates for iliac vascular injuries and isolated iliac vein injuries resulting from abdominal blunt trauma stand at 2.3% and 0.1%, respectively. Literature indicates that the mortality rate for patients suffering from iliac vascular injury can range anywhere from 25% to 80% [4].

The traditional approach to treating traumatic injuries of the IVC involves surgical repair. Depending on the location of the injury and whether there is active bleeding or a hematoma, a variety of surgical repair techniques may be employed [5].

There are no clear society-based guidelines available that define the role of endovascular therapy in patients with IVC injuries [6]. There are, however, a handful of case reports demonstrating successful endovascular management of such injuries, contingent upon the patient's condition [5].

We present a case in which successful surgical repair was achieved for an infrarenal IVC and right external iliac vein (EIV) injury. This was accomplished through the ligation of the ipsilateral internal iliac artery (IIA) and superficial femoral vein (SFV) following blunt abdominal trauma.

CASE REPORT

A 65-year-old male patient, who sustained a back injury from a 500-kg excavator shovel at a construction site, was transported to Uijeongbu St. Mary's Hospital (Uijeongbu, Korea), a regional trauma center. His Glasgow Coma Score was 15, and he reported experiencing abdominal and pelvic pain.

The patient's initial blood pressure was recorded at 65/40 mmHg, with a heart rate of 116 beats/min. His respiratory rate was measured at 20 breaths/min, and his body temperature was 36 °C. The initial hemoglobin level was 9.6 g/dL. A pelvic binder was applied during the prehospital stage.

The Focused Assessment with Sonography for Trauma yielded negative results. The chest x-ray was clear, while the pelvic x-ray revealed diastasis of the right sacroiliac (SI) joint, along with fractures of the right superior and inferior ramus. A computed tomography (CT) scan was taken as the operating room was being prepared. The scan suggested injuries to the right side of the infrarenal IVC and the right EIV. Additionally, they showed a fracture of the right iliac bone, the right sacrum ala, and the fourth sacrum. A substantial retroperitoneal hematoma and extravasation along the right EIV were also detected in the CT scan (Fig. 1). During the initial resuscitation, 1 L of crystalloid and 1 unit of

packed red blood cells (pRBCs) were administered. Despite this, the patient's blood pressure remained at 65/56 mmHg.

The patient was moved to the operating room, where we performed a crash laparotomy. We discovered a transected small bowel and promptly ligated the lumen to prevent further contamination. Although there was no evidence of intraperitoneal hemorrhage, we did find a retroperitoneal hematoma situated around the aortic bifurcation. The infrarenal IVC was exposed using the Cattell-Braasch maneuver. We repaired a 5-mm longitudinal injury on the right side of the infrarenal IVC wall using prolene. We then proceeded with further dissection of the iliac artery and vein. The right IIA was ligated. We observed multiple and diffuse bleeding around the right EIV. Despite suturing the suspected right EIV bleeding site with prolene, the bleeding persisted. Even after allowing ample time for manual compression, we were unable to achieve hemorrhagic control.

We opted to ligate the right SFV to diminish venous return. The right superficial femoral artery and vein were isolated, after which the SFV was ligated using silk. This procedure led to a decrease in bleeding, enabling us to secure the surgical field. We then managed to control the bleeding by packing gauze in the right lower quadrant, covering the right SI joint diastasis. A side-to-side anastomosis of the transected small bowel was performed using a linear stapler. Upon completion of the gauze packing, the patient's blood pressure was recorded at 94/66 mmHg, body temperature at 35.5 °C, and lactate levels at 83 mg/dL. We proceeded with a temporary abdominal closure and closed the incision in the right inguinal area. The findings and procedures from the initial operation are summarized in Fig. 2, while the patient's timeline is detailed in Fig. 3.

During the operation, approximately 5 L of blood products were infused using a rapid infusion system. These products included 9 units of pRBCs, 8 units of platelets, and 8 units of fresh frozen plasma (FFP). Prior to a second-look operation, an additional 3 units of pRBCs, 6 units of FFP, and 6 units of cryoprecipitate were infused.

On the morning of the second-look operation, the patient's blood pressure registered at 109/67 mmHg, his body temperature was 36.8 °C, and his lactate level was 16 mg/dL. The second-look operation took place 2 days later. The majority of the bleeding sites had ceased. The injured right EIV was discovered to be ruptured, but the bleeding was successfully managed. Some of the bleeding sites were ligated with prolene (Fig. 4). The serosal injury to the ascending colon was repaired. The abdominal layers were closed in sequence. Following this, orthopedic surgeons assumed control of the operation and performed a closed reduc-

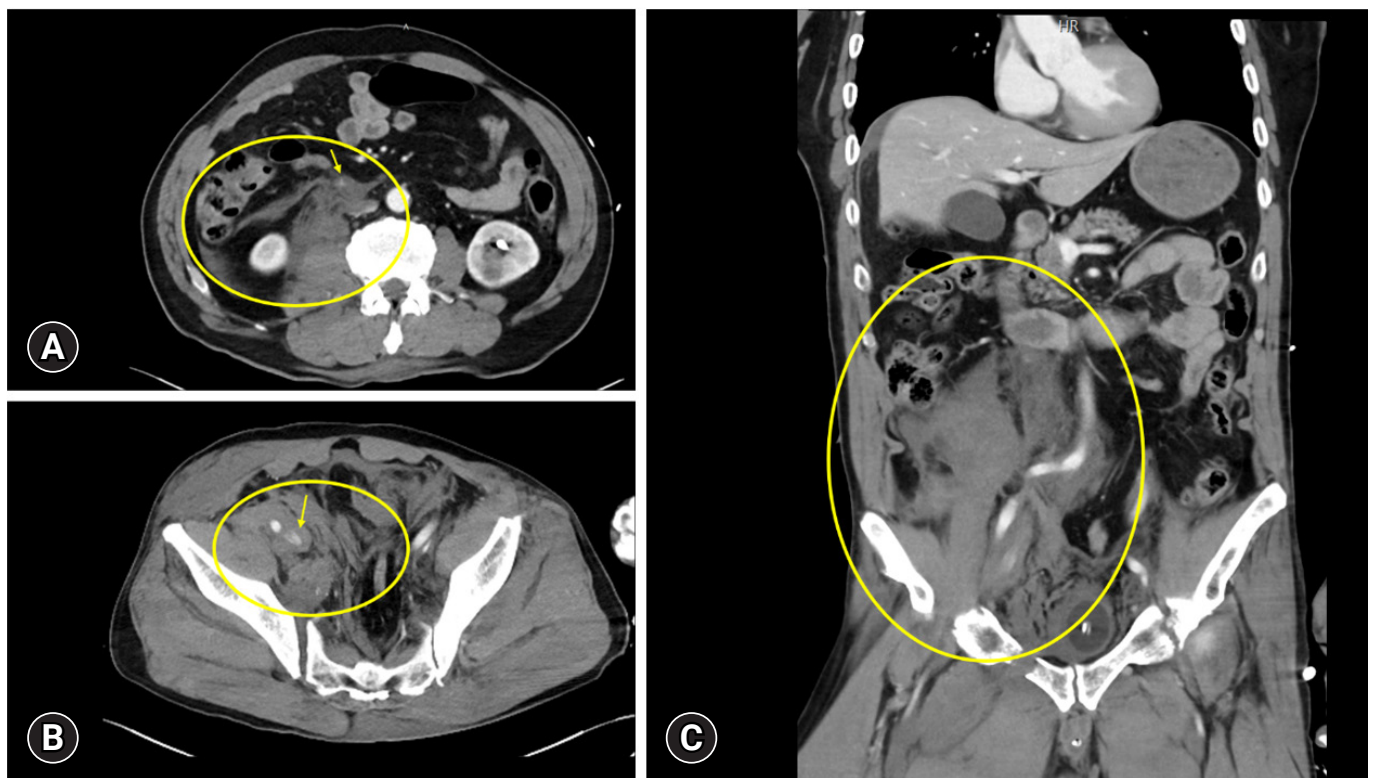


Fig. 1. Initial abdominopelvic computed tomography findings. Retroperitoneal hematoma (circles) and extravasations (arrows) with a suspected inferior vena cava (IVC) and right external iliac vein (EIV) injury are shown. (A) Retroperitoneal hematoma and extravasations around infrarenal IVC. (B) Retroperitoneal hematoma and extravasations around right EIV. (C) Retroperitoneal hematoma and extravasations around infrarenal IVC and right EIV, a coronal view.

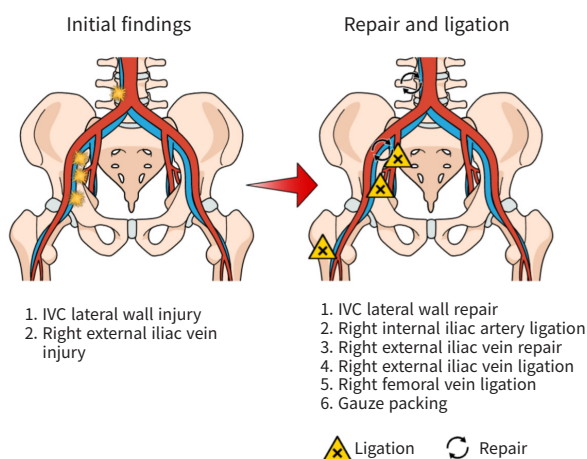


Fig. 2. Summary of the first operation. The operation was implemented in numerical order. IVC, inferior vena cava.

tion and external fixation.

Five days later, the patient exhibited definite fixation and was subsequently transferred for rehabilitation on postoperative day 22. On postoperative day 14, the patient underwent a lower ex-

tremity CT angiogram, which revealed deep vein thrombosis (DVT) extending from the ruptured right EIV to the popliteal vein (Fig. 5). Despite this, the patient did not experience severe swelling, pain, pulmonary embolism, or compartment syndrome. Three months later, he was able to begin walking with the aid of a walker.

Ethics statement

Informed consent for publication of the research details and clinical images was obtained from the patient.

DISCUSSION

IVC is divided into subsegments, which are commonly referred to as infrarenal, suprarenal, retrohepatic, and suprahepatic [7]. Most IVC injuries necessitate surgical exploration to control bleeding and perform a definitive repair. A free rupture into the peritoneal cavity can be identified by any alteration in hemodynamics or by an inadequate hemodynamic response to rapid volume resuscitation [8–10]. If feasible, a running suture using 4-0 or 5-0 prolene can be employed to complete the primary repair. If

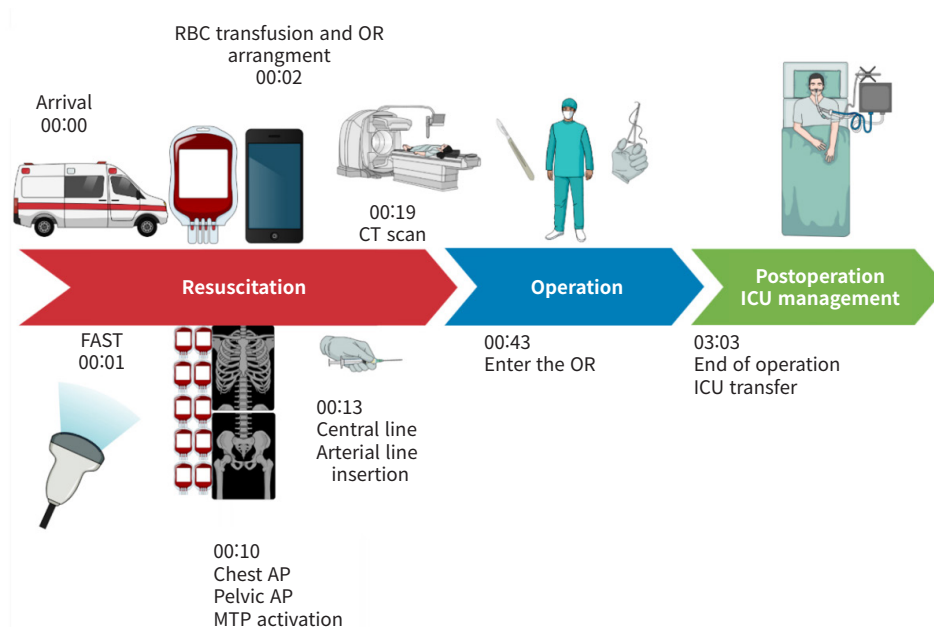


Fig. 3. Timeline of the patient's injury and management. FAST, Focused Assessment with Sonography for Trauma; RBC, red blood cell; OR, operating room; AP, anteroposterior; MTP, massive transfusion protocol; CT, computed tomography; ICU, intensive care unit.

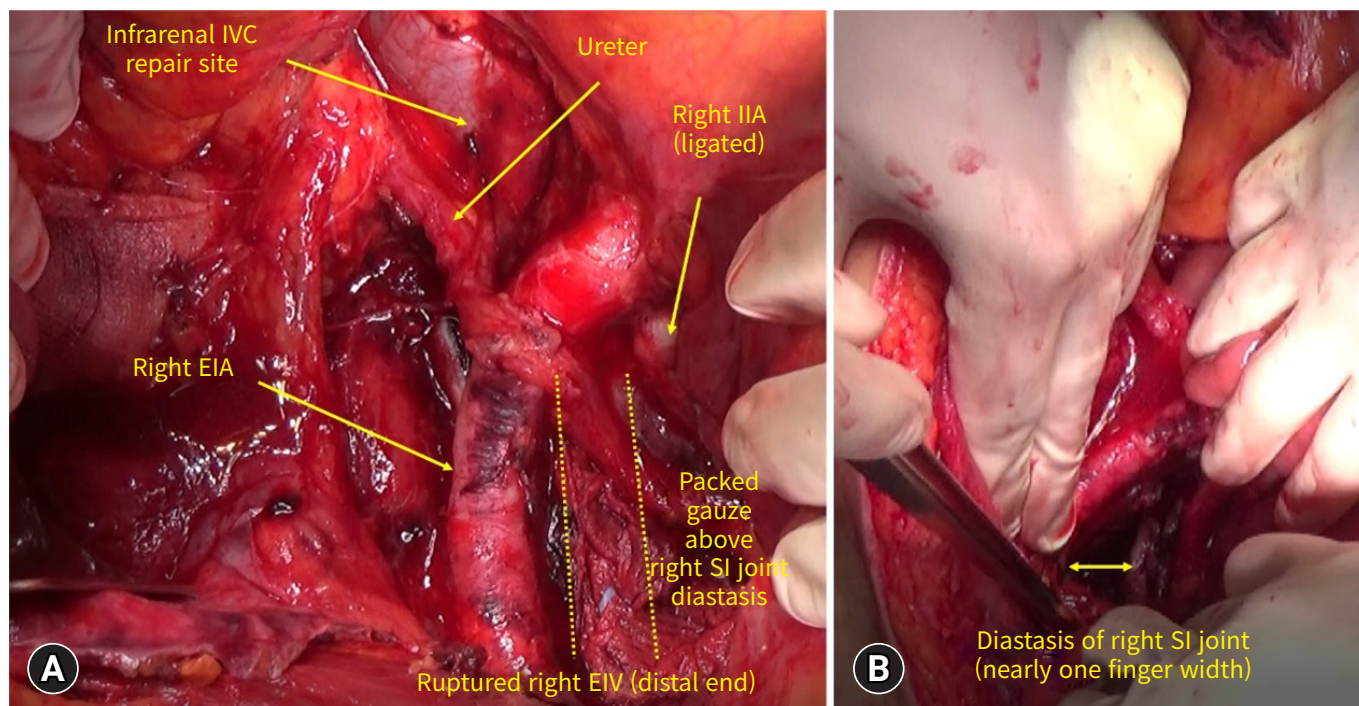


Fig. 4. Operative findings of the second-look operation. (A) Anatomy of the bleeding site. (B) Right sacroiliac (SI) joint diastasis. IVC, inferior vena cava; IIA, internal iliac artery; EIA, external iliac artery; EIV, external iliac vein.

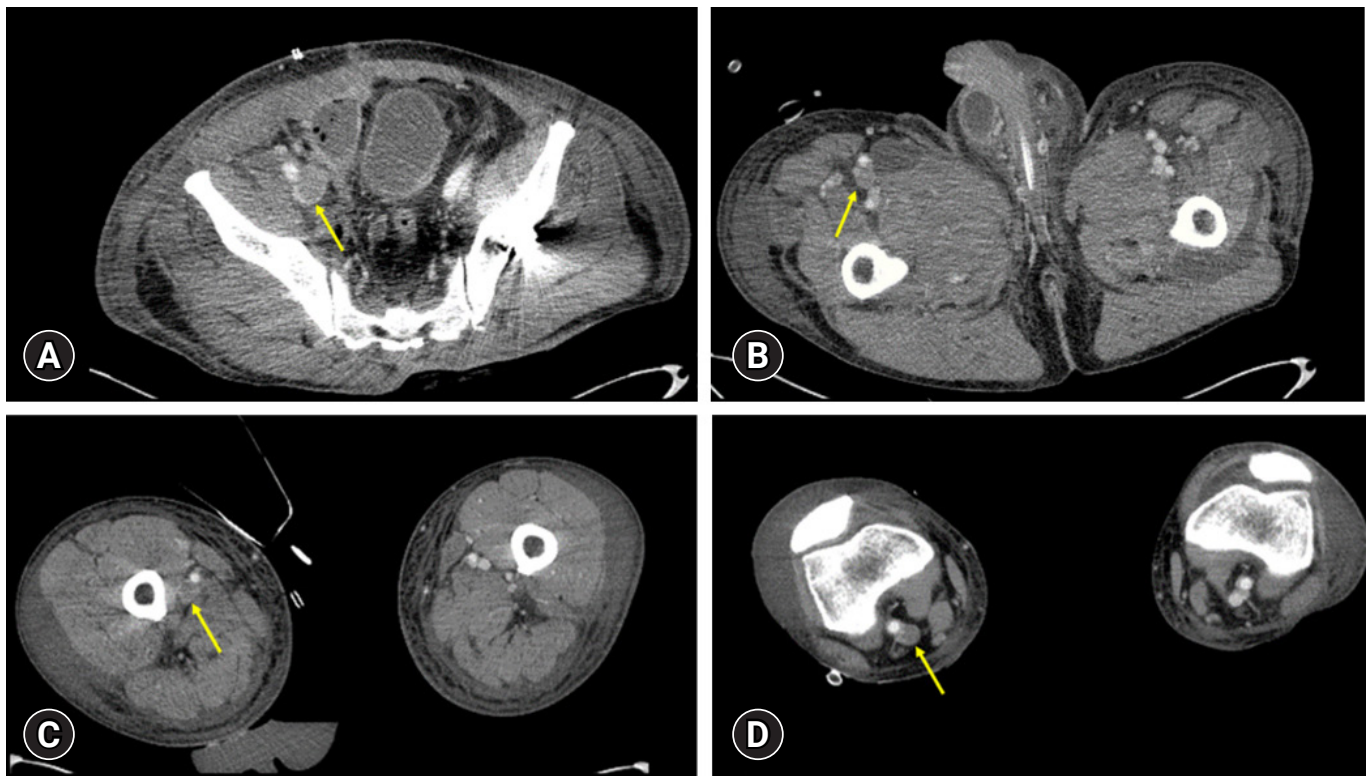


Fig. 5. Computed tomography angiogram on postoperative day 14. Deep vein thrombosis (arrows) from the ruptured right external iliac vein to popliteal vein. (A) The remnant right external iliac vein. (B, C) Femoral vein. (D) Popliteal vein.

the repair proves challenging, a side-biting Satinsky clamp may be beneficial for venorrhaphy [7]. In cases where multiple techniques fail to control the hemorrhage, surgeons might contemplate ligating the IVC.

In the event of a vein injury, the surgical treatment options typically include either repair or ligation. There has been ongoing debate regarding the choice between repair and ligation in the case of an IVC injury. A meta-analysis published in 2021 [11] examined this issue, incorporating data from 14 studies and a total of 885 patients. The findings indicated that ligation was associated with a higher mortality rate compared to IVC repair. However, when it came to mortality rates, there was no statistically significant difference between infrarenal IVC ligation and repair.

Magee et al. [4] studied 6,262 patients with iliac vascular injuries, using data from the National Trauma Data Bank (2007–2012). The study focused on the outcomes of repair versus ligation of isolated iliac vein injuries. Their findings indicated that compared to iliac vein repair, ligation was associated with a higher mortality rate. However, there were no statistically significant differences between the two methods in terms of DVT, pulmonary embolism, fasciotomy, or amputation.

Bilateral IIA ligation is a surgical treatment option for managing massive retroperitoneal hemorrhage in unstable patients with pelvic fractures [12]. The patient in question was unstable, presenting with a massive retroperitoneal hemorrhage due to an infrarenal IVC and right EIV injury. It was determined that the sacrum fracture was on the right side, with the majority of his injuries being right-sided. Consequently, we surmised that ipsilateral IIA ligation would be sufficient to control the hemorrhage.

In this case, we tried to repair the infrarenal IVC injury rather than ligate it. Despite repair of the right EIV bleeding site and subsequent manual compression, distal bleeding continued. Therefore, we ligated the ipsilateral SFV to reduce inflow, which successfully controlled the hemorrhage. A CT angiogram on postoperative day 14 revealed a DVT below the ruptured right EIV. However, a CT angiogram 7 months postoperatively showed collateral venous flow around the ruptured right EIV. Despite the presence of a DVT distal to the ruptured right EIV, the patient's condition and symptoms showed improvement.

In summary, we report a case of successful bleeding control of an infrarenal IVC and right EIV injury by ipsilateral IIA and SFV ligation after blunt abdominal trauma.

ARTICLE INFORMATION

Author contributions

Conceptualization: HC; Formal analysis: all authors; Methodology: HC; Project administration: HC; Visualization: HP, MK, DSL, THH, DHK; Writing—original draft: HP; Writing—review & editing: all authors. All authors read and approved the final manuscript.

Conflicts of interest

Hangjoo Cho is an Editorial Board member of the *Journal of Trauma and Injury*, but was not involved in the peer reviewer selection, evaluation, or decision process of this article. The authors have no other conflicts of interest to declare.

Funding

The authors received no financial support for this study.

Data availability

Data sharing is not applicable as no new data were created or analyzed in this study.

REFERENCES

1. Zia Ur Rehman. Inferior vena cava injuries: a clinical review. *J Pak Med Assoc* 2020;70:1069–71.
2. Eachempati SR, Robb T, Ivatury RR, Hydo LJ, Barie PS. Factors associated with mortality in patients with penetrating abdominal vascular trauma. *J Surg Res* 2002;108:222–6.
3. Matsumoto S, Jung K, Smith A, Coimbra R. Management of IVC injury: repair or ligation? A propensity score matching analysis using the national trauma data bank. *J Am Coll Surg* 2018;226:752–9.
4. Magee GA, Cho J, Matsushima K, et al. Isolated iliac vascular injuries and outcome of repair versus ligation of isolated iliac vein injury. *J Vasc Surg* 2018;67:254–61.
5. Kobayashi LM, Costantini TW, Hamel MG, Dierksheide JE, Coimbra R. Abdominal vascular trauma. *Trauma Surg Acute Care Open* 2016;1:e000015.
6. Santini A, Dargy N, Umstot R, Adkins N, Nanjundappa A. Endovascular repair of a traumatic inferior vena cava injury after exploratory laparotomy. *J Vasc Surg Cases Innov Tech* 2022;8:694–7.
7. Castater CA, Carlin M, Parker VD, et al. Intra-abdominal inferior vena cava injuries: operative strategies and outcomes. *Am Surg* 2021;87:1316–26.
8. Giannakopoulos TG, Avgerinos ED. Management of peripheral and truncal venous injuries. *Front Surg* 2017;4:46.
9. van Rooyen PL, Karusseit VO, Mokoena T. Inferior vena cava injuries: a case series and review of the South African experience. *Injury* 2015;46:71–5.
10. Khan IR, Hamidian Jahromi A, Khan FM, Youssef AM. Non-operative management of contained retrohepatic caval injury. *Ann Vasc Surg* 2012;26:420.
11. Byerly S, Tamariz L, Lee EE, et al. A systematic review and meta-analysis of ligation versus repair of inferior vena cava injuries. *Ann Vasc Surg* 2021;75:489–96.
12. DuBose J, Inaba K, Barmparas G, et al. Bilateral internal iliac artery ligation as a damage control approach in massive retroperitoneal bleeding after pelvic fracture. *J Trauma* 2010;69:1507–14.