

## Pediatrics

## 2 year outcome for 8 year old female managed with partial cystectomy for primary bladder clear cell carcinoma

Edward C. Diaz<sup>a,\*</sup>, Monica G. Velasquez<sup>a</sup>, Chia-Sui Kao<sup>b</sup>, Hsi-Yang Wu<sup>a</sup><sup>a</sup> Department of Urology, Stanford University Medical Center, 300 Pasteur Drive, RM-S-287, Grant Building, 2nd Floor, Stanford, CA, 94305, USA<sup>b</sup> Department of Pathology, Stanford University Medical Center, 300 Pasteur Drive, RMH1402, MC 5626, Stanford, CA, 94305, USA

## ARTICLE INFO

## Keywords:

Bladder cancer  
 Partial cystectomy  
 Clear cell carcinoma  
 Pediatric

## ABSTRACT

Bladder cancer is rare in the pediatric population, and clear cell carcinoma is extremely rare with one other pediatric case reported. Here we report the clinical outcome for a medically complicated pediatric patient with muscle invasive clear cell carcinoma treated with partial cystectomy without neoadjuvant or adjuvant therapy. Final pathology was stage T2bN0M0 with negative margins. At 2 years, there is no disease recurrence by cystoscopy, chest and abdominal imaging. Postoperative issues have been related to reduced bladder capacity and compliance and the patient is currently managed with continuous urinary diversion and will require future definitive lower tract reconstruction.

## Introduction

Clear cell carcinoma of the bladder is rare. There is a higher incidence in women with a mean reported age of 57 years.<sup>1</sup> Histologic review of bladder clear cell carcinoma demonstrates characteristics similar to mullerian derived malignancies. Its etiology remains unknown, but is suspected to arise from mullerian remnants in the bladder or originate or differentiate from urothelial cells.<sup>2</sup> Herein is a case of clear cell carcinoma of the bladder in a pediatric patient with multiple comorbidities treated with partial cystectomy.

## Presentation

The patient is an eight-year-old female that underwent stem cell transplant at four years of age for Crohn's disease. Post-transplant course was complicated by BK viremia, graft versus host disease, failure to thrive, and recurrent Crohn's disease. During evaluation for failure to thrive, MRI enterography revealed a 2.4 × 4.2 × 2.7 cm mass at the bladder dome. See Fig. 1. There were no complaints of hematuria, pneumaturia, fecaluria, dysuria, voiding dysfunction, or incontinence.

## Preoperative evaluation

Cystoscopy revealed a mass at the dome and posterior wall of the bladder. There was no trigone involvement. Colonoscopy was negative

for bowel pathology. Pathology from TURBT showed muscle invasive gland-forming epithelial malignancy consistent with adenocarcinoma. Nonspecific serum tumor markers were elevated: AFP 150 (normal < 10), CA125 75 (normal < 35), CA19-9 322 (normal < 35), HE4 169 (normal < 70); CEA, beta-HCG, and CA15-3 were normal. PET scan showed uptake in the primary bladder tumor without evidence of metastatic disease. CT chest was negative.

## Intraoperative course

The patient underwent partial cystectomy with en bloc resection of urachus and umbilicus and bilateral pelvic lymph node dissection. Nearly 75% of the bladder was resected. Ureteral reimplantation was not necessary. Frozen sections taken at the margins of resection returned negative.

## Postoperative course

Postoperative gravity cystogram at two weeks showed bilateral vesicoureteral reflux without leak. The urethral catheter was removed and she was initiated on timed voiding, anticholinergics, and antibiotic prophylaxis. Final pathology returned T2bN0 high-grade clear cell carcinoma with negative margin. There was no evidence of typical urothelial carcinoma and no evidence of urachal or gastrointestinal origin. See Fig. 2. Postoperative renal bladder ultrasound at 4 weeks

\* Corresponding author.

E-mail address: [ecdiaz@stanford.edu](mailto:ecdiaz@stanford.edu) (E.C. Diaz).<sup>1</sup> Present Address: Division of Pediatric Urology, Advocate Children's Hospital, 8901 West Golf Road, Suite 301, Des Plaines IL 60016.

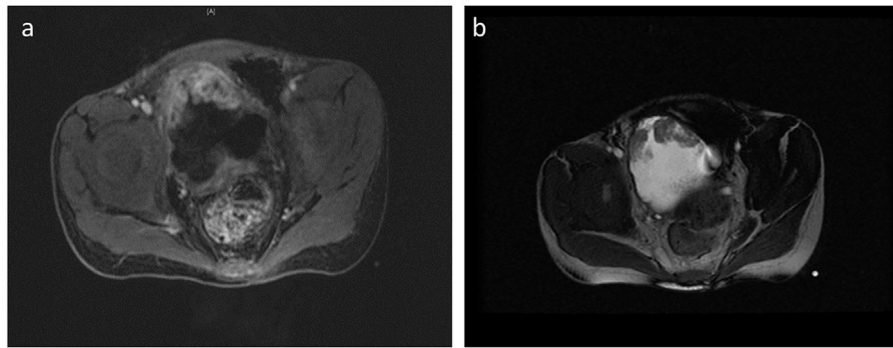


Fig. 1. MRI images of bladder mass: a) T1 weighted b) T2 weighted.

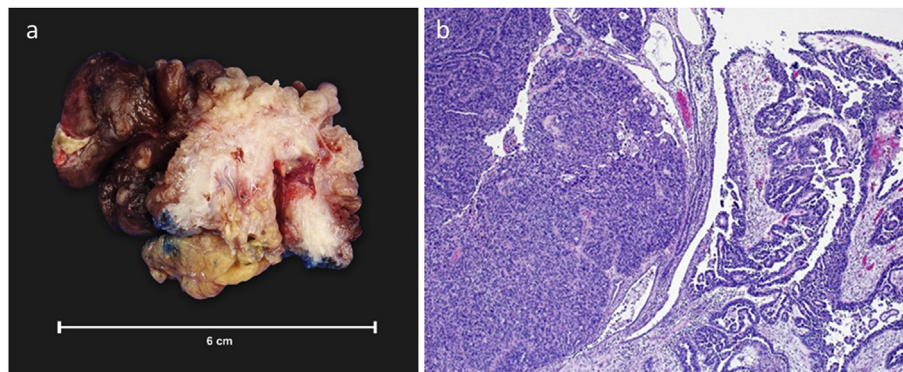


Fig. 2. a) Gross image of tumor with papillary surface proliferations (top) and underlying muscularis propria with perivesical fat. b) Histologic image of tumor with solid (left) and papillary (right) growth patterns.

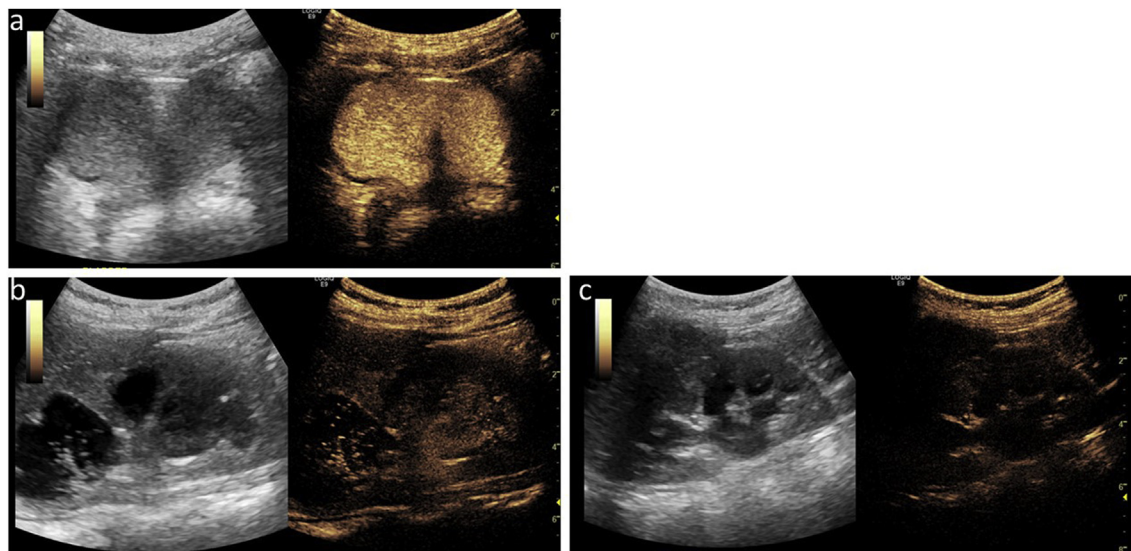


Fig. 3. Postoperative Contrast Enhanced US VCUG: a) Bladder with smooth contour b) Right kidney demonstrating passive reflux with Society for Pediatric Urology (SFU) Grade 3 hydronephrosis c) left kidney with reflux during voiding and SFU Grade 2 hydronephrosis.

demonstrated new bilateral grade 2 hydronephrosis. Cystoscopy performed every three months has not revealed recurrence. Surveillance scans with chest CT and abdominal MRI have also been negative for recurrence. Video urodynamics 6 months after resection demonstrated a small capacity, poorly compliant bladder. Urgency and desire to void occurred at low volumes at safe detrusor pressures ( $< 30$  cm of water). There was bilateral passive grade 3 vesicoureteral reflux (VUR). See Fig. 3. Tumor markers decreased since partial cystectomy with AFP and CA125 normalizing. HE4 and CA19-9 have decreased after surgery but

remain slightly elevated without a concerning trend. Testing of the tumor tissue revealed the presence of polyoma virus and an APC mutation. Patient genetic testing has not revealed any identifiable genetic predisposition. At 15 months postop, due to persistent bilateral hydronephrosis and episodes of flank pain, she underwent testing with a Mag3 renal scan that demonstrated no obstruction. She was converted to continuous urinary drainage with a suprapubic catheter at 15 months postop due to multiple admissions for acute kidney injury.

## Comment

One other case report of pediatric bladder clear cell carcinoma has been reported in the literature.<sup>3</sup> Similar to our patient, there was no gross hematuria, gender was female, and tumor stage was T2bN0M0. Unlike our patient, the other patient had urinary symptoms (incontinence) and their tumor involved the trigone and urethra. Our patient's clinical outcome appears more favorable as the other patient went on to develop metastatic disease. Direct histopathologic comparison of the cases has not been performed, but may reveal molecular differences that could contribute to differences in tumor biology. Earlier diagnosis in our patient may also be the reason for the difference in clinical course, as our patient had no urinary symptoms prior to diagnosis.

Clear cell carcinoma is a high grade lesion and is treated with radical cystectomy with lymph node dissection. A recent analysis of the National Cancer Database reveals the importance of surgical extirpation in invasive non-urachal carcinomas.<sup>4</sup> Surgical planning for this case was unique and a challenge given the patient's comorbidities impacting the use of intestine: Crohn's disease, history of graft versus host disease of bowel, and colonic stricture. Given the endoscopic findings and TURBT pathology, expert multidisciplinary consensus was that partial cystectomy with en bloc resection of the urachus was the best surgical option. Neoadjuvant therapy was not viewed as conferring significant advantage to early surgical resection and there was insufficient data to strongly recommend adjuvant therapy in the setting of negative margins.

Partial cystectomy has been used in the treatment of rhabdomyosarcoma of the bladder, and this cohort of patients provides insight into the functional consequences of this operation and the increased complications seen with adjuvant radiation therapy. These studies convey the importance of monitoring upper and lower tract changes in pediatric patients undergoing partial cystectomy.<sup>5</sup> Our patient developed reduced capacity and compliance, urinary tract infection, and high grade bilateral vesicoureteral reflux. She is currently being managed with continuous urinary diversion via cystostomy. Future plans for bladder reconstruction are being balanced with the patient's oncologic prognosis. Given the existing case reports for clear cell carcinoma and discussion with our oncology colleagues we believe it is an appropriate time to pursue lower tract reconstruction to improve capacity and

compliance. Discussion of future surgical reconstruction is beyond the scope of this report. However, it will once again be a challenge and will take into consideration her comorbidities, her oncologic status, and her ability to perform catheterization.

## Conclusion

This is only the second case of clear cell carcinoma of the bladder reported in a pediatric patient. Definitive conclusions cannot be drawn, but our patient obtained good oncologic results with partial cystectomy alone which contrasts to the aggressive tumor biology seen in the prior pediatric case report. Further reporting and characterization of these rare pediatric tumors is necessary to better identify prognostic variables that can guide treatment and predict outcome.

## Conflicts of interest

The authors declare that there are no conflicts of interest regarding the publication of this article.

## Appendix A. Supplementary data

Supplementary data to this article can be found online at <https://doi.org/10.1016/j.eucr.2019.100948>.

## References

1. Adeniran AJ, Tamboli P. Clear cell adenocarcinoma of the urinary bladder: a short review. *Arch Pathol Lab Med.* 2009;133(6):987–991.
2. Oliva E, Amin MB, Jimenez R, et al. Clear cell carcinoma of the urinary bladder: a report and comparison of four tumors of mullerian origin and nine of probable urothelial origin with discussion of histogenesis and diagnostic problems. *Am J Surg Pathol.* 2002;26:190–197.
3. Minkowitz SY, Wade R, Adam A. The first report of urothelial (clear cell variant) bladder cancer in a child. *Urology.* 2016;97:204–207.
4. Davaro F, Schaefer J, May A, Raza J, Siddiqui S, Hamilton Z. Invasive non-urachal adenocarcinoma of the bladder: analysis of the National Cancer Database. *World J Urol.* 2019;37(3):497–505.
5. Yeung CK, Ward HC, Ransley PG, et al. Bladder and Kidney Function after cure of pelvic rhabdomyosarcoma in childhood. *Br J Canc.* 1994;70:1000–1003.