

Marking nut anaphylaxis

Jie Shen Fok^{1,*}, Anita Christine Kral², John Hayball², and William B Smith^{1,3}

¹Department of Clinical Immunology and Allergy, Royal Adelaide Hospital, Adelaide, South Australia 5000, Australia

²Experimental Therapeutics Laboratory, School of Pharmacy and Medical Sciences, University of South Australia, Adelaide, South Australia 5001, Australia

³Allergy SA, Adelaide, South Australia 5067, Australia

Marking nut *Semecarpus anacardium*, so-called because it contains a pigment that has been used in the past to mark fabrics, is a known cause of contact hypersensitivity. It may be ingested as an ingredient of some traditional Hindi foods. We describe the first reported case of anaphylaxis to marking nut.

Key words: Marking nut; Anaphylaxis; Hypersensitivity

INTRODUCTION

Marking nut (*Semecarpus anacardium*), so-called because it contains a pigment that has been used in the past to mark fabrics, is a known cause of contact hypersensitivity. It may be ingested as an ingredient of some traditional Hindi foods, and is related to cashew. We describe the first reported case of anaphylaxis to marking nut.

CASE REPORT

A 59-year-old Indian Hindu priest at a local temple in South

Australia was offered a homemade sweet by a devotee after a religious ceremony. Within thirty minutes he developed periorbital swelling, lip swelling, a sensation of throat swelling and wheezing. The ambulance officers found him to be haemodynamically stable without desaturation. Facial swelling was evident. He received adrenaline and was observed overnight at the Emergency Department of a local hospital, with resolution of all symptoms by discharge the following day.

We determined the ingredients of the sweet and carried out skin prick testing. The initial round of testing with commercial extracts (Hollister-Stier/Stallergenes) was negative to cow's milk, wheat, wheat flour, cashew, and coconut. Further food extracts were prepared as slurries using a mortar and pestle by

Correspondence: Jie Shen Fok
Department of Clinical Immunology and Allergy, Royal Adelaide Hospital, Level 9 Main Block, Royal Adelaide Hospital, North Terrace, Adelaide, South Australia 5000, Australia
Tel: +61-8-8222-2953
Fax: +61-8-8222-0020
E-mail: JieShen.Fok@sa.gov.au

This is an Open Access article distributed under the terms of the Creative Commons Attribution. Non-Commercial License (<http://creativecommons.org/licenses/by-nc/4.0/>) which permits unrestricted non-commercial use, distribution, and reproduction in any medium, provided the original work is properly cited.

Received: March 25, 2016

Accepted: June 21, 2016

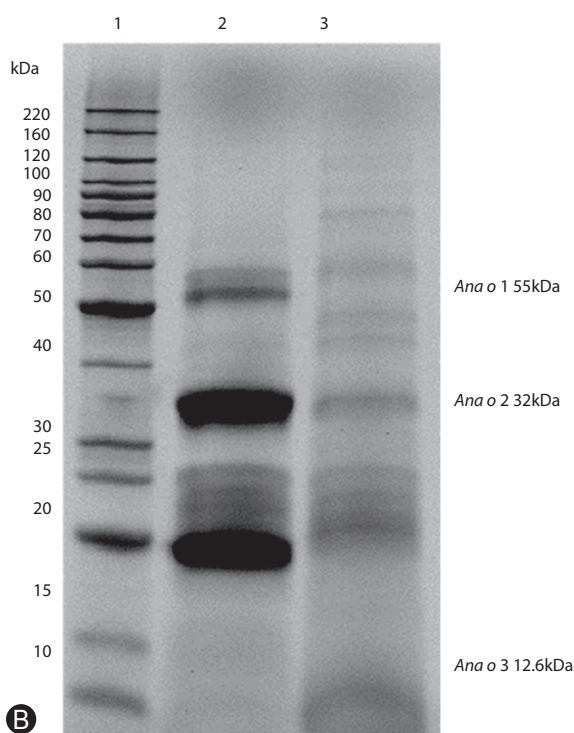


Fig. 1. (A) Marking nut. (B) Protein electrophoresis comparing marking nut extract and cashew nut extract. Lane 1, BenchMark unstained protein ladder (Life Technologies, a subsidiary of Thermo Fisher Scientific, Waltham, MA, USA); lane 2, cashew nut extract; lane 3, marking nut extract.

grinding food with saline solution. Poppy seeds and guar gum were negative. The patient supplied a small sample of a mixture containing *aliv* seeds (watercress seeds) and marking nut, which produced a positive wheal and flare reaction. Subsequently we obtained pure samples of *aliv* seeds (result negative) and marking nut (clear positive response, with a wheal size of 10 mm and flare size of 20 mm) (Fig. 1A)

We prepared protein extracts from marking nut and cashew by grinding nuts as above, defatting with acetone and reconstituting with sterile phosphate-buffered saline. Sodium dodecyl sulfate-

polyacrylamide gel electrophoresis (Fig. 1B) showed prominent protein bands at around 20–25 kDa and 32 kDa, as well as others at higher molecular weight. One of these bands was in a similar position to the known cashew allergenic protein *Ana o 2*. Despite extensive attempts we were unable to obtain a positive signal on IgE, IgG, or IgG4 immunoblot using the patient’s serum.

DISCUSSION

The marking nut, also known as the oriental cashew nut, belongs to the family Anacardiaceae, which contains the genera *Anacardium* (cashew), *Mangifera* (mango), *Pistacia* (pistachio), *Semecarpus* (marking nut), and *Toxicodendron* (poison ivy, poison oak). The latter is a common cause of contact dermatitis in the United States, with urushiol being the primary irritant and allergen. Locally known as *bhilawa* or *ballataka*, the marking nut is a product of deciduous tree found in the outer Himalayas and hotter parts of India up to 1,067 m height. The bark exudes an irritant secretion on incising. Traditionally it is believed to contain therapeutic properties and has been used extensively in Ayurvedic medicine since ancient times.

This blackish nut leaves an indelible ink and is recognized to have caused washerman’s dermatitis among British soldiers in the 1940s [1]. Several case reports of contact dermatitis (type 4 hypersensitivity reaction) caused by the marking nut have been described from subcontinental India, related to its use as hair dye, voodoo treatment, remedy for eczema or tattoo removal [2-6]. The contact allergen is thought to be urushiol [7].

We believe this is the first case report describing anaphylaxis (type 1 hypersensitivity reaction) to the marking nut in relation to oral ingestion. Presumably this is mediated by specific IgE to one or more allergenic protein(s) although we were unable to identify them. Cross reactivity between related species of nuts is well described, in particular cashew and pistachio [8-10]. Our protein electrophoresis demonstrated that marking nut contains proteins of similar molecular weight to known cashew nut allergens. Notably however, our patient’s skin prick test was negative to cashew nut and he consumed cashew without adverse reaction.

REFERENCES

1. Livinghood CS, Rogers AM, Fitz-Hugh T. Dhobi mark dermatitis. *J Am*

- Med Assoc 1943;123:23-6.
2. Ghorpade A. Targetoid skin lesions with marking nut hair dye. *Int J Dermatol* 2015;54:1414-5.
 3. Ghorpade A. Contact dermatitis caused by Indian marking nut juice used to relieve ankle pain. *Int J Dermatol* 2014;53:e117-9.
 4. Ghorpade A. Nutty dermatitis-marking-nut dermatitis after use as a home remedy. *Clin Exp Dermatol* 2009;34:e997-8.
 5. Ghorpade A. Voodoo dermatitis after an attempted voodoo cure for marking nut dermatitis. *Int J Dermatol* 2009;48:663-5.
 6. Verma P, Chhabra N, Sharma R. Severe marking-nut dermatitis. *Dermatitis* 2012;23:293-4.
 7. Bhatia K, Kataria R, Singh A, Safderi ZH, Kumar R. Allergic contact dermatitis by *Semecarpus anacardium* for evil eye: a prospective study from central India. *Indian J Basic Appl Med Res* 2014;3:122-7.
 8. Fernández C, Fiandor A, Martínez-Garate A, Martínez Quesada J. Allergy to pistachio: crossreactivity between pistachio nut and other Anacardiaceae. *Clin Exp Allergy* 1995;25:1254-9.
 9. Noorbakhsh R, Mortazavi SA, Sankian M, Shahidi F, Tehrani M, Azad FJ, Behmanesh F, Varasteh A. Pistachio allergy-prevalence and in vitro cross-reactivity with other nuts. *Allergol Int* 2011;60:425-32.
 10. Hasegawa M, Inomata N, Yamazaki H, Morita A, Kirino M, Ikezawa Z. Clinical features of four cases with cashew nut allergy and cross-reactivity between cashew nut and pistachio. *Allergol Int* 2009;58:209-15.