

CD4+ cells as a potential biomarker for cytomegalovirus retinitis in children with acute lymphocytic leukemia

Jian-Cang Wang¹, Fei-Fan Du¹, Ming Su¹, Xiao-Ge Yang¹, Mei-Jie Quan², Xiao-Ying Zhai²

¹Department of Ophthalmology, Hebei Children's Hospital, Hebei Medical University, Shijiazhuang, Hebei 050031, China;

²Department of Hematology, Hebei Children's Hospital, Hebei Medical University, Shijiazhuang, Hebei 050031, China.

To the Editor: Infection is one of the causes of death after chemotherapy in children with leukemia. About 20% to 30% acute lymphocytic leukemia (ALL) patients die from infection after chemotherapy.^[1] Patients with immune deficiency, under chemotherapy, or treated with immunosuppressor are more inclined to be infected with human cytomegalovirus (HCMV) which leads to severe systematic disorders.^[2] Cytomegalovirus retinitis (CMVR) is a major sight threatening disease which mainly occurs in patients with immune deficiency and results in blindness if treatment is delayed. The decrease of CD4+ T cells has been related to CMVR in immune deficiency syndrome like AIDS.^[3] However, little is known about the relation between the level of T cells with different markers and the onset of CMVR in ALL patients under chemotherapy. Therefore, this study was designed to investigate the diagnostic value of T cells with different markers for cytomegalovirus retinitis after chemotherapy in patients with ALL.

One hundred twenty-eight children with ALL who were under chemotherapy in the department of hematology from our hospital from January 2015 to September 2017 were included in this study. Inclusion criteria: (1) ALL was diagnosed by bone marrow examination; (2) ALL patients were under moderate risk and under uniform chemotherapy regimens; (3) Medical record was complete; (4) No HCMV infection before chemotherapy; (5) Patients were under ocular examination at regular intervals. All participants were divided into three groups based on whether they were infected with HCMV and whether they were present with CMVR. Group A included 99 patients who were HCMV negative. Group B included 18 patients who were HCMV positive but absent of CMVR. Group C included 11 patients who were HCMV positive and meanwhile present with CMVR.

Polymerase chain reaction (PCR) for CMV was used to determine blood CMV-DNA and urine CMV-DNA. When

CMV-DNA < 500U/mL, it was considered as CMV negative. When CMV-DNA > 500U/mL, it was considered as CMV positive. After chemotherapy, blood sample was obtained from all patients and flow cytometry was used to determine the number of T cells with different markers, including CD3, CD4, CD8.

In 128 ALL patients, 11 patients showed CMVR after chemotherapy. Among them, three patients underwent vision loss (3/11), eight patients did not undergo eye discomfort and were diagnosed as CMVR when ophthalmologic examination was performed (8/11), seven patients underwent eye lesion in binoculus (7/11), and the other four patients underwent single eye lesion (4/11). Lesion in three eyes in two patients occurred in the center (3/18), seven eyes in five patients in the rim (7/18), and eight eyes in four patients both in the center and in the rim (8/18).

Lesion in seven eyes in four patients involved in yellow spot (7/18). Four eyes in two patients were involved in retinopathy and optic neuritis (4/18). In these two patients, hyperaemia and diffused hemorrhage could be seen in optic disk with obscure boundary, as shown in Figure 1A. Nine eyes in five patients showed extensive retinal vasculitis (9/18) and the vagina vasorum in retina was obvious [Figure 1B and 1C]. Two eyes in one patient showed preretinal hemorrhage (2/18) [Figure 1D].

Table 1 showed the counting results of T cells with different markers after chemotherapy in three groups. Except CD4+ T cells/CD8+ T cells ratio, the number of CD3+ T cells, CD4+ T cells, and CD8+ T cells were significantly different among three groups. Notably, the number of CD4+ T cells in group A was remarkably higher than that in group B, and remarkably higher in group B than in group C (A > B > C).

For all sample, when the number of CD4+ T cells was higher than 200/μL, 100–200/μL, and lower than 100/μL, the CMVR positive rate was 6/7, 26.31% (5/19), and 0 (0/102).

Access this article online

Quick Response Code:



Website:
www.cmj.org

DOI:
10.1097/CM9.000000000000065

Correspondence to: Dr. Jian-Cang Wang, Department of Ophthalmology, Hebei Children's Hospital, Hebei Medical University, Shijiazhuang, Hebei 050031, China
E-Mail: wangjiancang@sina.com

Copyright © 2019 The Chinese Medical Association, produced by Wolters Kluwer, Inc. under the CC-BY-NC-ND license. This is an open access article distributed under the terms of the Creative Commons Attribution-Non Commercial-No Derivatives License 4.0 (CCBY-NC-ND), where it is permissible to download and share the work provided it is properly cited. The work cannot be changed in any way or used commercially without permission from the journal.

Chinese Medical Journal 2019;132(3)

Received: 26-11-2018 Edited by: Ning-Ning Wang

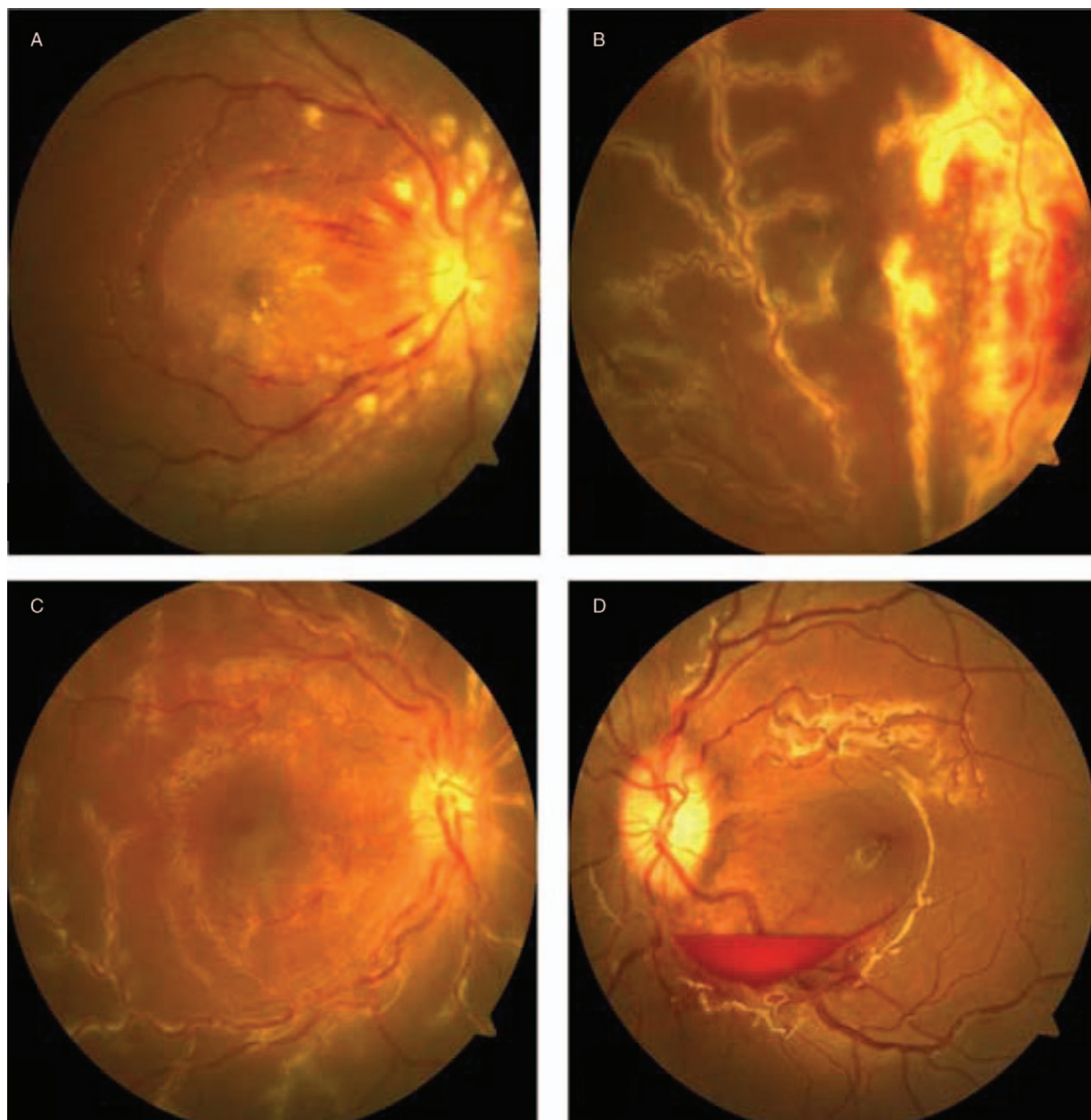


Figure 1: Photos of fundus disease in CMVR patients. (A) hyperaemia and diffused hemorrhage could be seen in optic disk with obscure boundary; (B and C) extensive retinal vasculitis and the vagina vasorum in retina; (D) preretinal hemorrhage. CMVR: Cytomegalovirus retinitis.

Table 1: T cells counts with different markers after chemotherapy in three groups of ALL

Items	Group A (n=99)	Group B (n=18)	Group C (n=11)	F	P
CD3 ⁺	817.10±299.26	622.17±271.89	519.82±119.24	7.96	<0.01
CD4 ⁺	395.75±86.27	259.56±70.62	110.36±50.00	73.40	<0.01
CD8 ⁺	293.18±104.33	197.89±26.30	171.55±61.37	14.19	<0.01
CD4 ⁺ /CD8 ⁺	1.12±0.25	1.09±0.24	1.18±0.19	0.51	>0.05

Group A: patients who were HCMV negative. Group B: patients who were HCMV positive but absent of CMVR; Group C: patients who were HCMV positive and meanwhile present with CMVR. ALL: Acute lymphocytic leukemia; CMVR: Cytomegalovirus retinitis; HCMV: Human cytomegalovirus.

In the 29 patients with HCMV infection, when the number of CD4⁺ T cells was higher than 200/μL, 100–200/μL, and lower than 100/μL, the HCMV infection rate was 0 (0/11), 45.45% (5/11), and 54.55% (6/11). The number of CD4+

T cells was negatively related to CMVR positive rate, and it showed a significant difference when χ^2 was performed ($\chi^2=70.187$, $P<0.01$). That is to say, as the number of CD4⁺ T cells decreased, the positive rate of CMVR increased.

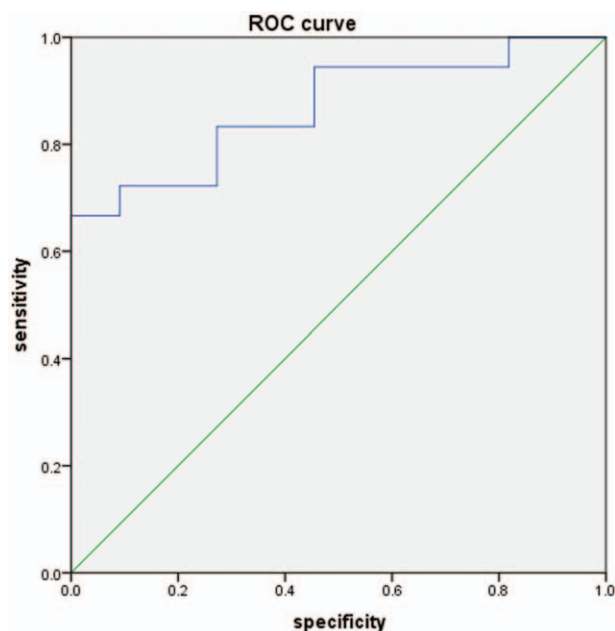


Figure 2: ROC curve of the number of CD4+ T cells for CMVR after chemotherapy in 128 ALL patients. The number of CD4+ T cells possessed a high diagnostic value for CMVR after chemotherapy in ALL patients, the area values under the curve of the number of CD4+ T cells was 0.920 ± 0.029 , $P < 0.001$. ALL: Acute lymphocytic leukemia; CMVR: Cytomegalovirus retinitis; ROC: Receiver operating characteristic curve.

After chemotherapy, 11 out of 128 ALL patients showed CMVR positive, which count for 8.59% in all sample. The range of CD4+ T cells in CMVR positive patients was 32–192/ μL , and the average was $113.72 \pm 59.36/\mu\text{L}$. Among these 11 patients, the number of CD4+ T cells in six patients was lower than 100/ μL , and 100–200/ μL in five patients. When the number of CD4+ T cells was higher than 200/ μL , no patients were CMVR positive.

Based on the relationship between the number of CD4+ T cells and CMVR positive rate, we would like to further determine the diagnostic value of CD4+ T cells for CMVR after chemotherapy in ALL patients, ROC curve analysis was performed. As shown in Figure 2, the area values under the curve of the number of CD4+ T cells was 0.920 ± 0.029 , which indicated that the number of CD4+ T cells possessed a high diagnostic value for CMVR after chemotherapy in ALL patients.

Cell-mediated immunity is the main force for anticancer, and T type lymphocytes play an important role in cell-mediated immunity. In our study, we measured the number of T cell subpopulation with different markers, including CD3, CD4, CD8, and investigated the relationship between CMVR positive rate and T cell-mediated immunity. We found that compared to the HCMV negative patients, HCMV positive patients showed a significantly lower level of CD3+, CD4, CD8+ T cells. And in patients with CMVR, those indexes were lower than patients without CMVR. Among that index, the level of CD4+ T cells was significantly lower in patients with CMVR than HCMV positive patients without CMVR, and the former was significantly lower than HCMV negative patients. It is well known that CD4+ T cell and CD8+ T cell are two important subpopulations of

T type lymphocytes.^[4] CD4+ T cells can activate phagocytes and CD8+ T cells and thus enhance the ability to combat cancer.^[5]

In this study, comparing to the HCMV negative patients, the HCMV positive patients showed a lower level of CD3+ T cells, CD4+ T cells and CD8+ T cells and a lower ratio of CD4+ T cells to CD8+ T cells. This indicated that the decreased cell-mediated immunity might cause HCMV infection or HCMV from the status of inertia to activation. What is more, comparing to the HCMV negative patients and HCMV positive patients without CMVR, the patients with CMVR showed a significantly lower level of index discussed above. This indicated that the occurrence of CMVR might be caused by the further decreased immunity after HCMV infection.

The diagnosis of CMVR is mainly based on ophthalmologic examination and medical history. When clinical feature shows no significant evidence of CMVR, laboratory examination is needed.^[6] On the one hand, CMV-IgM from the blood is the diagnostic index normally used for HCMV infection at present.^[7] However, for ALL patients who receive chemotherapy, their immunity has been impaired. When CMV-IgM can be detected in the blood, it is always found that CMVR is under a very severe condition. Therefore, its diagnostic value is evaluated. On the other hand, although sample from vitreous body and aqueous humor is much more accurate than that from blood, it becomes very unrealistic to obtain them because anesthesia or surgery is needed and the risk is comparatively high.

CMVR is an opportunistic infectious disease which can be normally found in ALL patients after chemotherapy.^[8] Lack of cytotoxic T lymphocytes and a low CD4+ lymphocyte count as considered to be risk factors for CMV disease.^[9] In this study, we found that the number of CD4+ T cells in CMVR was extremely low comparing to the other 2 groups. When the number of CD4+ T cells was lower than 200/ μL , the occurrence of CMVR tended to be significantly higher. What is more, we have another strong evidence that the area values under the curve of the number of CD4+ T cells was 0.920 ± 0.029 , and it indicated that the level of CD4+ T cells might be a potential biomarker for CMVR in ALL patients after chemotherapy.

The evidence discussed above suggest that when an ALL patient who is under chemotherapy appears eye discomfort and low level of CD4+ T cells, it is highly recommended that CMV-DNA from the blood and urine should be determined as the preliminary diagnosis for HCMV infection. And if the HCMV is positive, the ophthalmologic examination should be performed carefully to determine if CMVR is present and early treatment should be given in order to prevent vision loss.

Declaration of patient consent

The authors certify that they have obtained all appropriate patient consent forms. In the form, the patients have given their consent for their images and other clinical information to be reported in the journal. The patients understand that their names and initials will not be published and due efforts

will be made to conceal their identity, but anonymity cannot be guaranteed.

Conflicts of interest

None.

References

1. Liu AP, Lee V, Li CK, Ha SY, Chiang AK. Refractory acute lymphoblastic leukemia in Chinese children: bridging to stem cell transplantation with clofarabine, cyclophosphamide and etoposide. *Ann Hematol* 2016;95:501–507. doi: 10.1007/s00277-015-2577-7.
2. Buxmann H, Hamprecht K, Meyer-Wittkopf M, Friese K. Primary human cytomegalovirus (HCMV) infection in pregnancy. *Dtsch Arztebl Int* 2017;114:45–52. doi: 10.3238/arztebl.2017.0045.
3. Ozcan PY, Celik HT, Sonmez K, Celik M. Necrotizing retinitis secondary to congenital cytomegalovirus infection associated with severe combined immunodeficiency. *Case Rep Ophthalmol Med* 2016;2016:1495639. doi:10.1155/2016/1495639.
4. Pedrotti LP, Barrios BE, Maccio-Maretto L, Bento AF, Sena AA, Rodriguez-Galan MC, *et al*. Systemic IL-12 burst expands intestinal T-lymphocyte subsets bearing the alpha(4) beta(7) integrin in mice. *Eur J Immunol* 2016;46:70–80. doi:10.1002/eji.201545585.
5. Salimian J, Arefpour MA, Riazipour M, Poursasan N. Immunomodulatory effects of selenium and vitamin E on alterations in T lymphocyte subsets induced by T-2 toxin. *Immunopharmacol Immunotoxicol* 2014;36:275–281. doi:10.3109/08923973.2014.931420.
6. Zhao N, Liu L, Xu J. Cytomegalovirus retinitis in a patient with secondary acute lymphosarcoma leukemia undergoing allogeneic hematopoietic stem-cell transplantation: a rare case report: a care-compliant article. *Medicine (Baltimore)* 2017;96:e6878. doi: 10.1097/MD.0000000000006878.
7. Pirani V, Cavallero E, Mariotti C, Neri P, Nicolai M, Cesari C, *et al*. Acute macular neuroretinopathy associated with subclinical cytomegalovirus infection. *Int Ophthalmol* 2017;37:727–731. doi: 10.1007/s10792-016-0299-z.
8. Kobayashi R, Takanashi K, Suzuki D, Nasu T, Uetake K, Matsumoto Y. Retinitis from cytomegalovirus during maintenance treatment for acute lymphoblastic leukemia. *Pediatr Int* 2012;54:288–290. doi: 10.1111/j.1442-200X.2011.03429.x.
9. Jain R, Trehan A, Mishra B, Singh R, Saud B, Bansal D. Cytomegalovirus disease in children with acute lymphoblastic leukemia. *Pediatr Hematol Oncol* 2016;33:239–247. doi: 10.3109/08880018.2016.1173147.

How to cite this article: Wang JC, Du FF, Su M, Yang XG, Quan MJ, Zhai XY. CD4+ cells as a potential biomarker for cytomegalovirus retinitis in children with acute lymphocytic leukemia. *Chin Med J* 2019;132:356–359. doi: 10.1097/CM9.000000000000065