



Assessing Bone Marrow Activity with [^{18}F]FLT PET in Patients with Essential Thrombocythemia and Prefibrotic Myelofibrosis: A Proof of Concept

Technology in Cancer Research & Treatment
Volume 21: 1-8
© The Author(s) 2022
Article reuse guidelines:
sagepub.com/journals-permissions
DOI: 10.1177/15330338221086396
journals.sagepub.com/home/tct


Mohamed A. Yassin, MBBS, CABM, MSC, FACP, MSC¹,
Sadek A. Nehmeh, PhD², Abdulqadir J. Nashwan, MSc³ ,
Samah A. Kohla, PhD⁴, Shehab F. Mohamed, MD¹,
Omar M. Ismail, MD¹, Ahmad Al Sabbagh, PhD⁴,
Dina S. Soliman, PhD⁴, Lajos Szabados, MD⁵, and Hadi Fayad, PhD⁶

Abstract

Objectives: This study aims to assess the value of FLT-PET as a non-invasive tool to differentiate between patients with ET and Pre-PMF. This study is a pilot study to have a proof of concept only. **Methods:** This is a prospective, interventional study where a total of 12 patients were included. Each patient underwent FLT PET imaging as well as bone marrow examination (gold standard). In addition, semi-quantitative (SUVmax and SUVmean) measurements of FLT uptake in the liver, spleen, and Lspine, SUVmean, as well as the Total Lesion Glycolysis (TLG) of the Lspine were performed. Results from the two patient cohorts were compared using = Kruskal-Wallis statistical test. A *P*-value of <.05 is considered to be statistically significant. **Results:** The differences in FLT SUVmax and SUVmean measurements in the three organs (liver, spleen, and LSpine) between the ET and Pre-PMF patients were not statistically significant (*P* > .05). In contrast, TLG measurements in the LSpine were statistically different (*P* = .013), and therefore, compared to gold standard bone marrow results, TLG can separate ET and Pre-PMF patients. **Conclusion:** This study is a proof of concept about the potential to discriminate between ET and pre-PMF patients in a non-invasive way. TLG of the LSpine in FLT PET images is a potential quantitative parameter to distinguish between ET and pre-PMF patients.

Keywords

essential thrombocythemia, prefibrotic myelofibrosis, fluorothymidine F-18, positron emission tomography

Received: November 10, 2021; Revised: February 20, 2022; Accepted: February 22, 2022.

¹ Department of Medical Oncology/Hematology, National Centre for Cancer Care and Research, Hamad Medical Corporation, Doha, Qatar

² Department of Radiology, Weill Cornell Medicine, New York, USA

³ Department of Education & Practice Development, Hazm Mebaireek General Hospital, Doha, Qatar

⁴ Department of Laboratory Medicine and Pathology, Hematopathology Section, Hamad Medical Corporation, Doha, Qatar

⁵ Clinical Imaging Department, Hamad Medical Corporation, Doha, Qatar

⁶ Occupational Health and Safety Department, Hamad Medical Corporation, Doha, Qatar

Corresponding Authors:

Mohamed A. Yassin, Department of Medical Oncology/Hematology, National Center for Cancer Care and Research, Hamad Medical Corporation, Doha, Qatar
PO BOX 3050, Doha, Qatar.
Email: yassinmoha@gmail.com

Abdulqadir J. Nashwan, Department of Education & Practice Development, Hazm Mebaireek General Hospital (HMGH), Hamad Medical Corporation, PO Box 3050, Doha, Qatar.
Email: anashwan@hamad.qa



Introduction

³-¹⁸Fluoro-³'-deoxy-L-thymidine (18F-FLT) with PET is a non-invasive technique to image tumor cell proliferation in various cancers.^{1,2}

Myeloproliferative Neoplasms (MPNs) are clonal hematopoietic stem cell disorders characterized by the high rate of effective proliferation of one or more cell lineage. MPNs are overlapping syndromes that can progress to the fibrotic stage or evolve into acute leukemia.² Preliminary results of a pilot study¹ suggested that this technique could be useful to assess bone marrow (BM) activity and extramedullary hematopoiesis in patients with Myelofibrosis (MF).

The current standard for follow-up of these patients is based on pathological markers (peripheral blood counts and/ bone marrow histomorphology) and molecular markers. Bone marrow examination is the gold standard method to assess the disease's extent; it offers detailed information about cellularity, the morphology of each lineage, the degree of fibrosis, and the transformation and dysplastic features. However, many patients are reluctant to go for this invasive technique which precludes precise disease activity assessment at the desirable frequencies. A non-invasive technique that can offer reliable prognostic and predictive information about the disease is lacking.

The objective of this study is to explore the diagnostic value of FLT-PET in malignant hematopoiesis of Pre-PMF and ET. The potential to use FLT-PET metrics to differentiate between Pre-PMF and ET is assessed³ since this differentiation will optimize the therapeutic interventions (eg, anti-platelets and anti-coagulants) as thrombosis is related to ET while hemorrhage is more associated with pre-PMF.

Materials and Methods

Patients

This is a prospective, interventional study where a total of 13 patients (mean age of 43.23 ± 14.42 years, 7 males and 6

females) with Essential Thrombocythemia (ET) and/or Prefibrotic myelofibrosis were included in this study. One male subject was excluded due to an inconclusive diagnosis. The PET scan was done within three months from diagnoses and none of the patients treated with cytoreductive therapy at the time of performing the PET. The study was approved by the institutional review board. Written informed consents were obtained from all subjects. [clinicaltrials.gov identifier: NCT03116542]. Table 1 shows the patient demographics, including age, gender, diagnosis, and blood tests upon diagnosis.

Bone Marrow Histopathology

Bone marrow aspirate and biopsy were performed from the posterior iliac crest and examined by an experienced hematopathologist. The morphologic study was made by examination of Wright-Giemsa stained bone marrow aspirate as well as of hematoxylin and eosin-stained bone marrow core biopsy sections.

In the case of Pre-PMF, bone marrow biopsy shows megakaryocytic and granulocytic proliferation. Megakaryocytic abnormalities (including extensive clustering, megakaryocytic atypia, and abnormal chromatin clumping with hyperchromatic nuclei) are the key findings in diagnosing PMF and its distinctive form from other MPN, including ET.⁴

ET bone marrow biopsy shows proliferation mainly of the megakaryocytic lineage with increased numbers of enlarged mature megakaryocytes with hyperlobulated nuclei with no significant increase or left shift in neutrophil granulopoiesis or erythropoiesis and no increase in reticulin fibers.⁵

Bone marrow fibrosis (MF) grading was determined in silver-stained bone marrow biopsy sections using semiquantitative bone marrow fibrosis (MF) grading system previously proposed by Thiele et al.⁶ (European Consensus on the grading of bone marrow fibrosis [MF 0-3] with minor modifications concerning collagen and osteosclerosis and defined as follows: MF-0, with no increase in reticulin, MF-1 with a very loose network of reticulin fibers, MF-2 with more diffuse and more dense increase in

Table 1. Patient characteristics.

Patient no.	Age (y)	Gender	Upon Dx			Upon ¹⁸ F-FLT imaging			Dx
			Hemoglobin (g/dL)	Leukocytes (10 ⁹ /L)	Thrombocytes (10 ⁹ /L)	Hemoglobin (g/dL)	Leukocytes (10 ⁹ /L)	Thrombocytes (10 ⁹ /L)	
1	37	M	13.8	7.6	680	14	8	581	ET
2	24	F	12.5	8.4	1197	12.2	11.3	1217	ET
3	30	M	14.6	7.2	1880	14.2	4.9	399	ET
4	51	F	14.1	18	788	14.8	7.8	517	pre-PMF, (MF 1-2)
5	42	F	13.4	6.6	570	13.3	4.4	591	ET
6	31	F	11.2	17.2	940	10.1	5.4	561	pre-PMF, (MF 1-2)
7	56	M	13.6	9.6	726	14.3	8.8	679	ET
8	34	F	11.3	5.7	651	8.5	5.6	353	ET
9	35	M	15.7	16.5	804	14.8	8.7	656	pre-PMF
10	65	M	13.1	8.1	1121	11.5	3	264	ET
11	32	F	12.7	8.3	700	11.2	6.1	399	ET
12	58	M	16.3	9.9	968	13.1	5.3	374	ET
13	67	M	13.1	7.3	566	14.4	7.2	72	ET/ pre-PMF

Abbreviations: M, Male; F, Female; ET, Essential Thrombocythemia; pre-PMF, Prefibrotic myelofibrosis; Dx, Diagnosis.

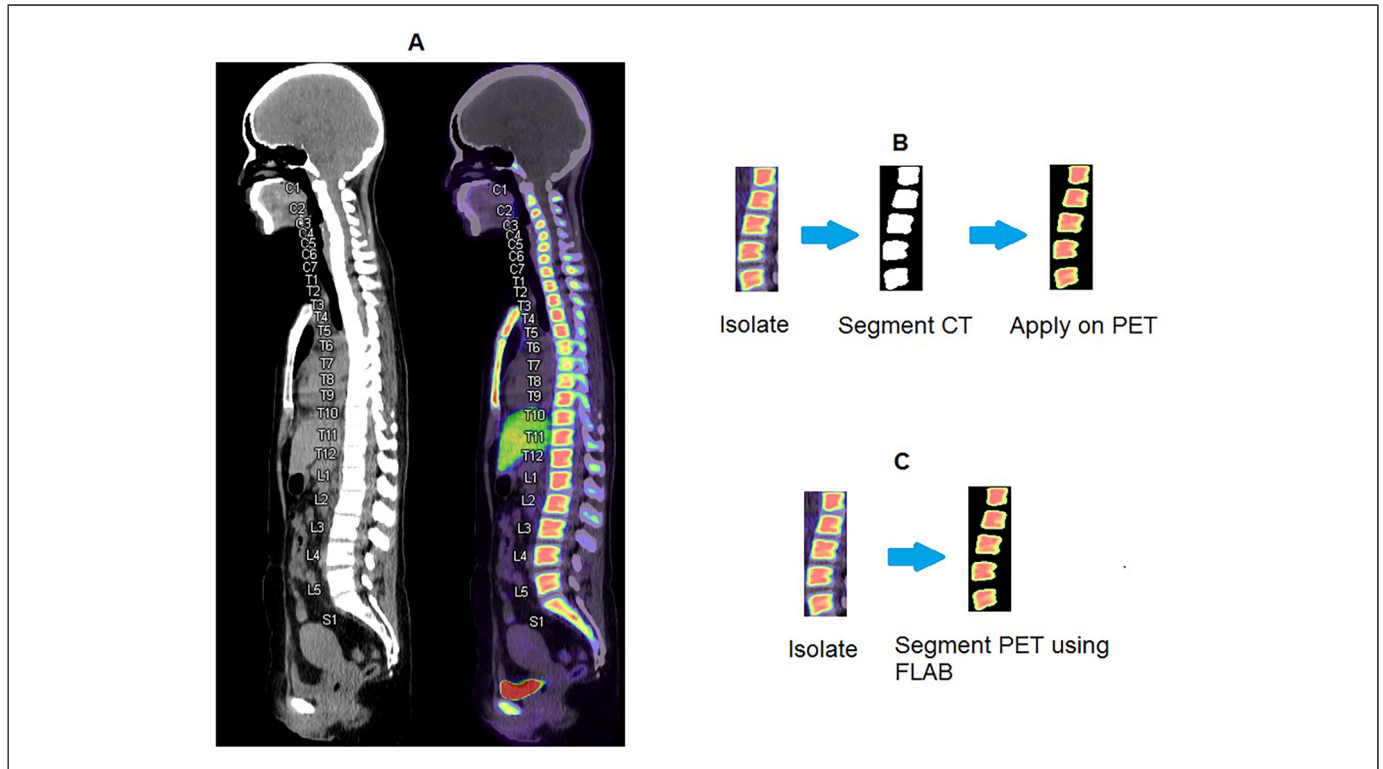


Figure 1. Labelling of L1 to L5 on CT and PET/CT images (B) Steps for the CT segmentation method (C) Steps for the PET segmentation method.

reticulin fibers and some course collagen fibers. MF-3, with course bundles of collagen fibers intermingled with dense reticulin accompanied by initial osteonecrosis.

[18F] FLT PET Acquisition

[18F] FLT PET was performed within three months post-inclusion. PET/CT images of the Total-body were acquired on a Siemens mCT scanner in 3D static mode for 3 min per bed position and at 60 min \pm 10 min post-injection of 280 MBq \pm 1% of [18F] FLT. CT images were acquired using the Care Dose and Care VK modules from Siemens. 18F-FLT PET Images were reconstructed using the Ultra HD PET algorithm provided by the manufacturer.

PET/CT Image Segmentation

The Lumbar spine (Lspine),⁷ was segmented on the CT images, as well as on the PET images, and then the corresponding PET SUVmean's were measured and compared. For both methods, the section encompassing L1 to L5 of the Lspine was labeled as shown in Figure 1A.

Figure 1B shows the steps for the first method. In the CT-based segmentation method, bones were segmented using a threshold >150 HU (Hounsfield Unit). The corresponding volume of interest was then overlaid on the FLT PET for quantitation purposes.

Figure 1C shows the steps for the second method. For the PET-based segmentation method, the bony anatomy within

the L1 to L5 segment was segmented using the fuzzy locally adaptive Bayesian (FLAB) segmentation method, an automatic delineation algorithm used to delineate an area to be identified from the background.⁸ The PET metrics deduced from the two methods were compared.

Image Analysis

An experienced nuclear physician unaware of the patients' medical histories conducted the visual and quantitative analysis of all PET FLT images for all the 12 patients.

A 5-point scale (value from 0 to 4) was used to assess the extension of the bone marrow humerus/femur. A score of 0 for humerus indicates that the humerus cannot be seen, and a score of 4 indicates that the whole humerus could be identified. A similar analysis was performed to the femur. SUVmax in the liver, spleen, and L-spine were reported.

After L-spine segmentation as described in the previous section, other measurements were done, including L-spine SUVmean and volume. Moreover, the total lesion glycolysis (TLG) of the L-spine, defined as

$$\text{TLG} = \text{SUVmean} \times \text{Volume} \quad (1)$$

Where SUVmean is the average SUV within the L-spine volume defined using the CT segmentation approach described earlier.

Statistical Analyses

The primary aim of this project was to study the ability of FLT-PET in differentiating between Pre-PMF and ET. The focus of the data analysis was to determine the predictive value and accuracy of FLT-PET uptake in predicting diagnosis. For this purpose, we used receiver-operating-characteristic (ROC) curves and computed areas under curves (AUCs) for each parameter for its robustness in predicting the diagnosis. Kruskal-Wallis test was used to assess whether if the PET metrics can discriminate between ET and Pre PMF patients. A P -value of $<.05$ was considered to be statistically

significant. All statistical tests were done using the MedCalc software (MedCalc, Ostend, Belgium).

Results

CT-based segmentation method (Figure 1B) was compared to the FLAB PET-based segmentation method. Obtained PET metrics (Voluma, SUVmean, and TLG) deduced from the two methods were compared. Differences between the two segmentations were not significant, with a P -value of .39, so the first method was used.

Figure 2 shows an example of 3 PET FLT patients with different bone marrow humerus/femur extension levels. The

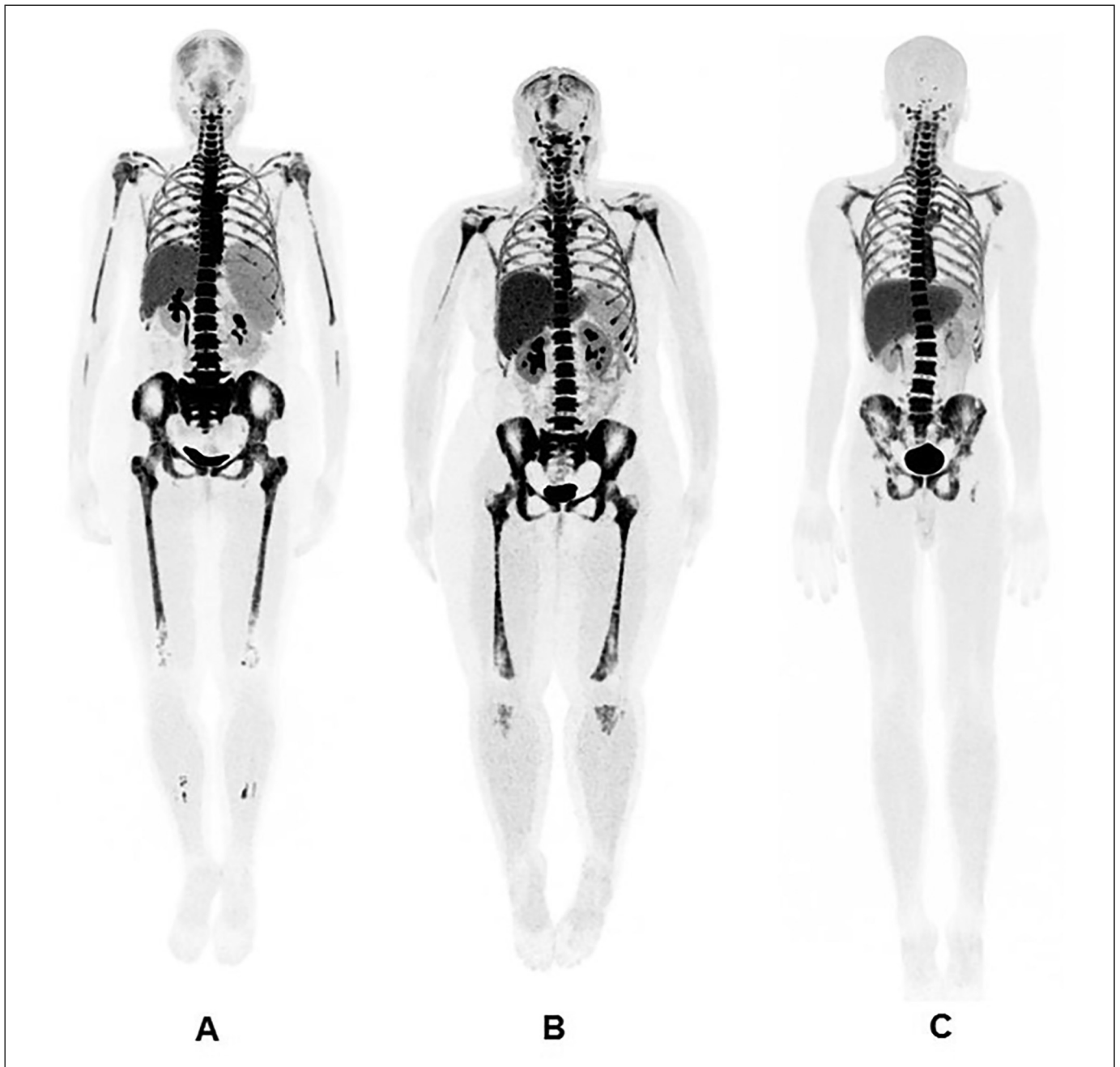


Figure 2. Example of 3 PET FLT patients with different bone marrow humerus / femur extension levels (A) 4/4 (B) 1/4 (C) 0/1

corresponding scores as indicated by the nuclear physicians were 4/4 (humerus/Femur, Figure 2A), 1/4 (Figure 2B) and 0/4 (Figure 2C). A total of 2 patients had an extension level of 0, 6 patients with a 1 extension level, 2 patients with 2 extension level and one patient on each 3 and 4 extension levels. Applying the Kruskal-Wallis test on all 12 patients' data in order to separate ET and Pre PMF patients while using extension level criteria led to an insignificant separation with the corresponding P -value of .36 and .55 for the humerus and femur extension, respectively. Regarding SUVmean calculation, the mean \pm standard deviation for the liver, spleen, and L-spine were 7.17 ± 1.77 , 3.23 ± 0.79 and 21.56 ± 5.27 , respectively. Similarly, no separation was obtained for ET and PrePMF patients with corresponding P -values of .4, .52 and .52. An example of

patient separation when using the L-spine SUVmean is shown in Figure 3. As noticed ET patients had L-spine SUVmean values ranging from 14.79 to 30.96 while PrePMF patients had L-spine SUVmean values ranging from 20.33 to 24.87.

The L-spine SUVmean, volume and TLG were 16.66 ± 3.14 , 3705 ± 284 , and $61\,416 \pm 10\,997$, respectively. The difference in L-spine SUVmean between ET and PrePMF patients was statistically insignificant (P -value = .31) as shown in Figure 4A. ET patients had L-spine SUVmean values ranging from 11.92 to 20.49 while PrePMF patients had L-spine SUVmean values ranging from 17.54 to 19.93. When using the L-spine volume, although the P -value was $>.05$ (.079), the separation seems to be better but still non-significant (Figure 4B). Two ET outlier was noticed having L-spine volume of 3929 and 4129. Finally, Figure 5 shows the Kruskal-Wallis test plot for the L-spine TLG. As shown in Figure 5, a significant separation can be noticed with a P -value of .013 (P -value $<.05$). A TLG value of 70 000 seems to separate both groups. Finally, ROC curve analysis for the L-spine TLG is shown in Figure 6. ROC was 1 and no false positive or false negative was obtained.

Discussion

Pre-PMF and ET exhibited different features of bone marrow; however, this is not always easy to judge objectively, making pathologists' distinction often suboptimal. And in another scenario, bone marrow which is mandated for diagnosis, cannot be obtained due to technical issues or patient-related factors. In the 2016 revised classification,^{9,10} MN pre-PMF was recognized as a separate entity, distinct from ET. Thrombosis and hemorrhage represent two of the main causes of morbidity and mortality in patients with ET. Incidence of arterial and venous thrombosis prior to diagnosis revealed no significant

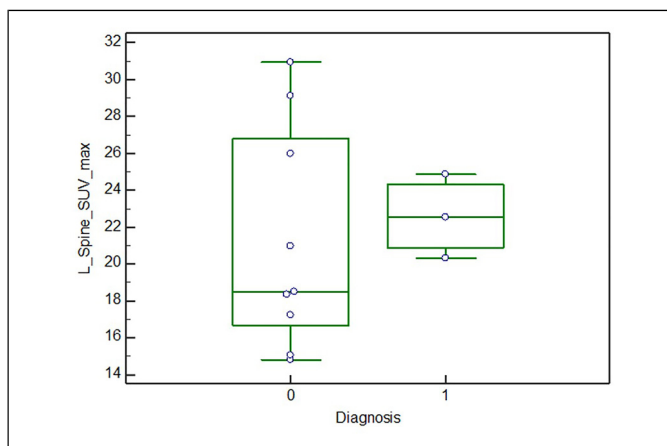


Figure 3. Kruskal Wallis test results when using the Lspine SUVmax to separate the ET and pre PMF groups. 0 value in the Diagnosis x-axis corresponds to ET and 1 value in the Diagnosis x-axis corresponds to PMF group. The Y axis corresponds to the SUVmax of the Lspine.

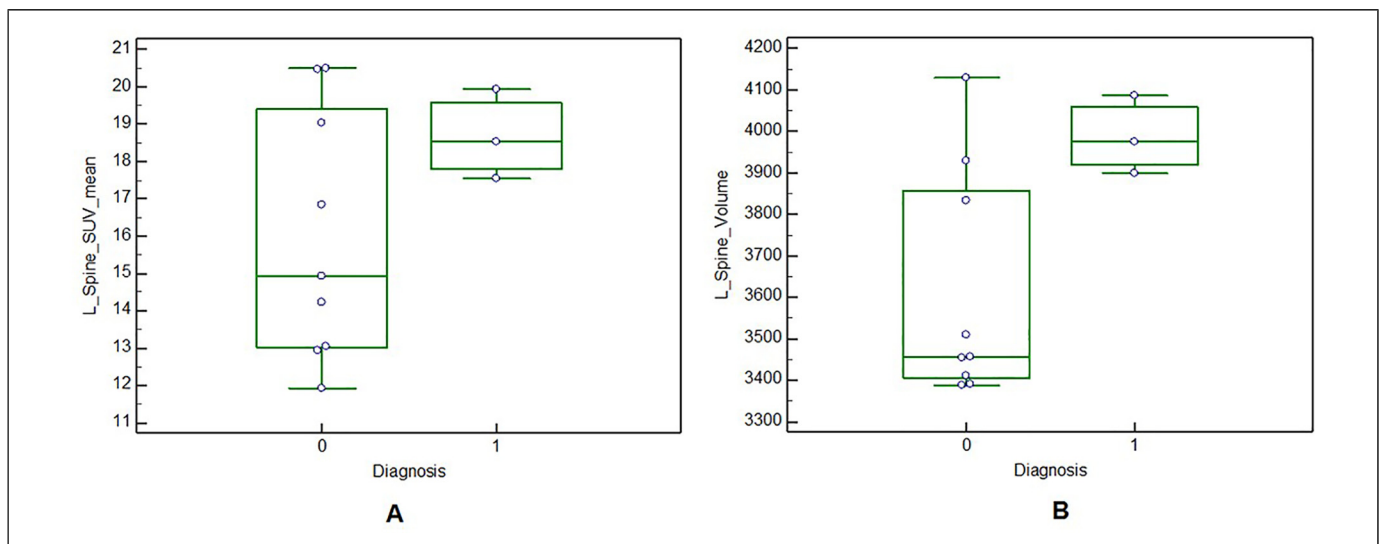


Figure 4. Kruskal Wallis test results when using the (A) Lspine SUVmean to separate the ET and pre PMF groups (B) Lspine volume to separate the ET and pre PMF groups. 0 value in the Diagnosis x-axis corresponds to ET and 1 value in the Diagnosis x-axis corresponds to PMF group. The Y axis corresponds to the SUVmean of the Lspine in A and to the Volume of the Lspine in B.

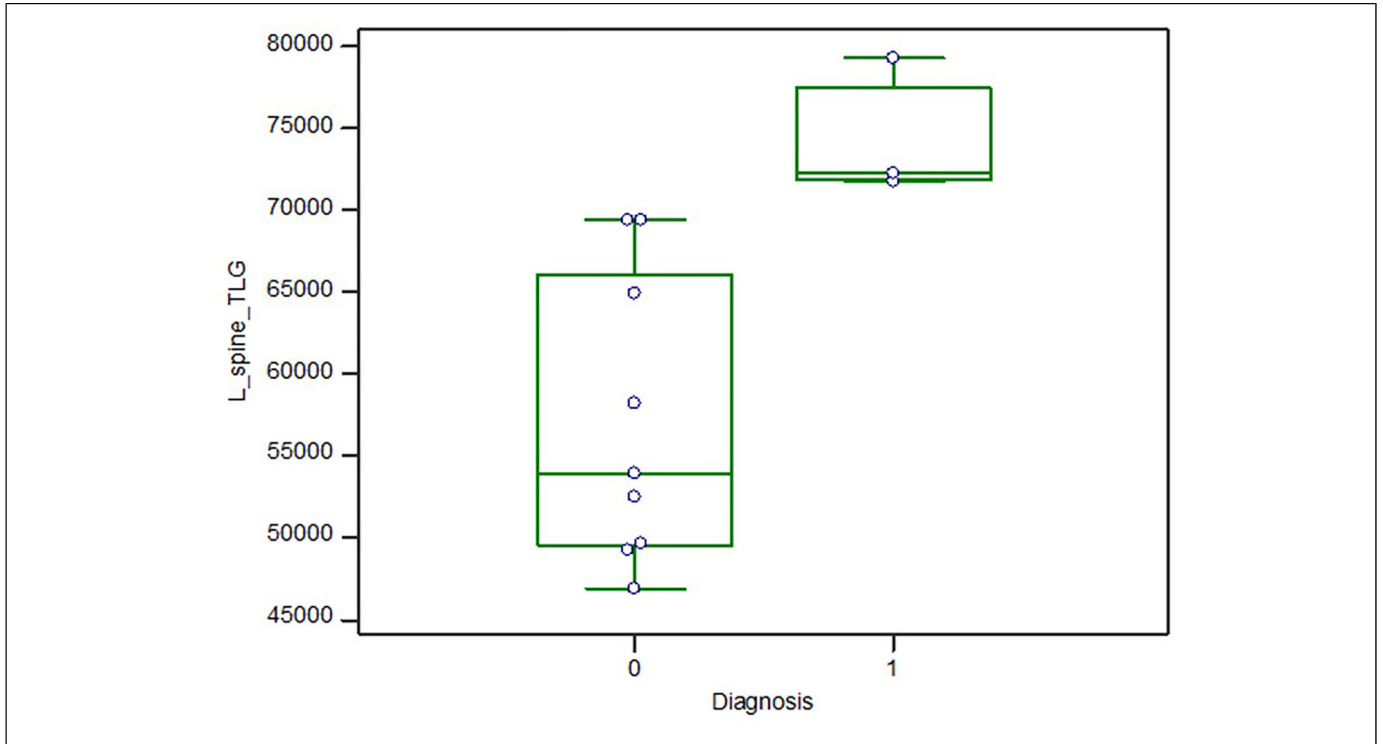


Figure 5. Kruskal Wallis test results when using the Lspine TLG to separate the ET and pre PMF groups. 0 value in the Diagnosis x-axis corresponds to ET and 1 value in the Diagnosis x-axis corresponds to PMF group. The Y axis corresponds to the TLG of the Lspine.

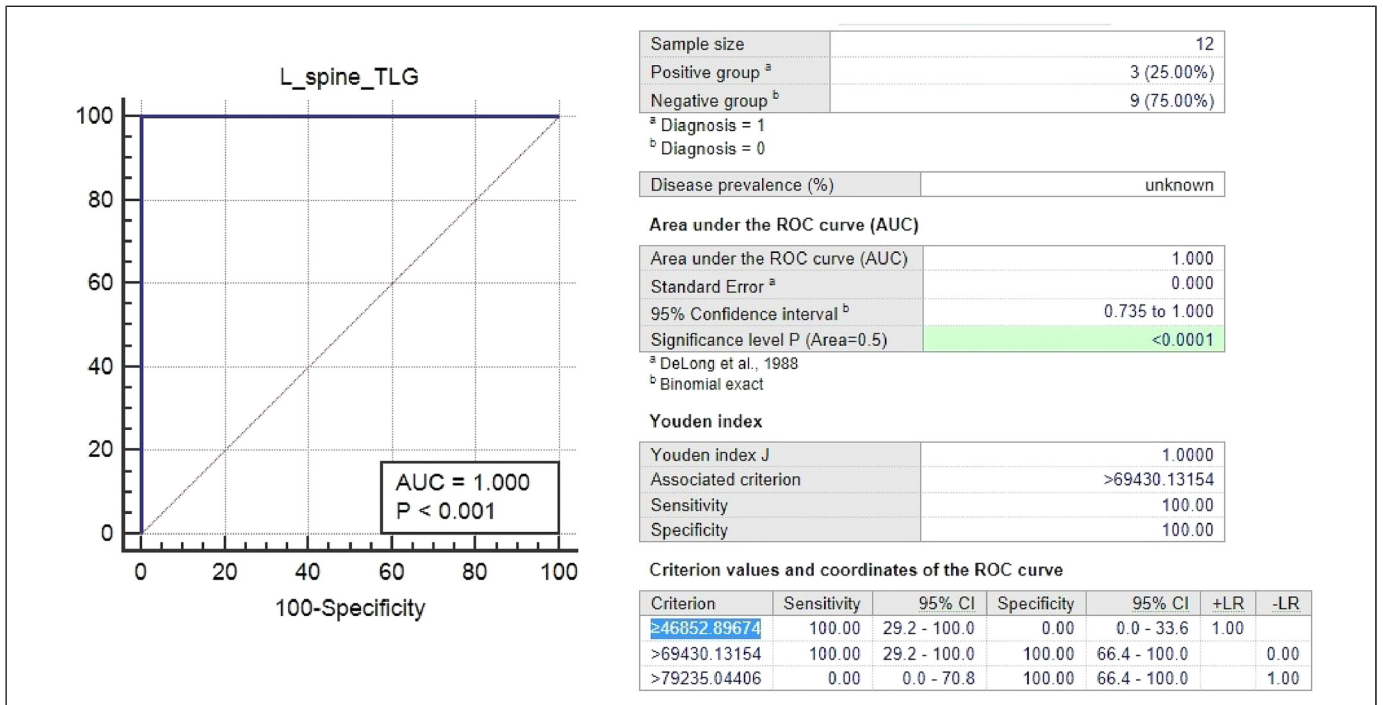


Figure 6. ROC curve analysis when using the Lspine TLG to separate the ET and pre-PMF groups.

differences (23% /20 and 9/8%) in WHO-defined ET compared with pre-PMF; thrombotic complications were also similar during the follow-up. Thrombosis is not significantly

different, whereas bleeding is more frequent in pre-PMF. Concerning the history of major bleeding (mostly gastrointestinal) at diagnosis according to the largest cohort of

WHO-diagnosed patients, until now reported (891 ET and 180 pre-PMF), frequencies were relatively rare (4% vs 7%) and not significantly different. Contrasting these incidences, major hemorrhage during follow-up occurred only in 6% of ET but in 12% of the pre-PMF patients ($P = .009$), consistent with a rate of 0.79 and 1.39% patient-years, respectively ($P = .039$). Median survival is significantly shorter in pre-PMF, and 10-year cumulative rates progression to overt myelofibrosis is 0–1% versus 10–12%, and leukemic transformation is 1–2% versus 2–6%, in ET and pre-fibrotic-PMF, and this reflects the importance of differentiating between the two conditions.¹¹

The initial measurement of different PET FLT images showed no correlation between basic measurements such as SUVmean and, ET/ Pre-PMF patients' separation. All P -values were insignificant as per the Kruskal-Wallis test. L-spine volume and TLG were then calculated. ET and Pre-PMF patients' separation was not possible while using volume and SUVmean (P -values of .079 and .31 respectively) but feasible when using TLG (P -value of .013). A TLG L-spine value of 70 000 seems to separate both groups in a significant way.

In France, a study was conducted to assess the diagnostic efficacy of FLT PET imaging in 15 patients with myelofibrosis, the results of were compared to the bone marrow. The study revealed that FLT/PET appears to be a reliable and practical tool for assessing hematopoietic activity in bone marrow, measuring the severity of myelofibrosis, and monitoring noninvasively the patients' outcomes.¹²

One of the most important aspects of this study is to avoid invasive techniques such as biopsy especially since many patients are reluctant to go to a biopsy which precludes precise assessment of disease activity at the desirable frequencies. FLT/PET will offer a good alternative as a non-invasive technique that can offer reliable prognostic and predictive information.

The major limitation of our study is the number of patients, which is limited to 12 patients. However, our main goal is to have a pilot study and, therefore, a proof of concept. Future work will concentrate on recruiting more patients and consolidating our results.

Conclusion

In conclusion, TLG of Lspine extracted from FLT/PET can be a potential factor that can separate ET and Pre PMF patients without the need for any invasive procedure such as biopsy.

Author Contributions

Conceptualization: MAY. Funding acquisition: MAY. Formal Analysis: HFD. Data curation, Methodology: MAY, SAN, AJN, SAK, SFM, OMI, AAS, DSS, LAS, HFD. Writing—original draft, Writing—review & editing: MAY, SAN, AJN, SAK, SFM, OMI, AAS, DSS, LAS, HFD. All authors read and approved the final manuscript.

Availability of Data and Material

All data generated or analyzed during this study are included in this published article.

Declaration of Conflicting Interests

The author(s) declared no potential conflicts of interest with respect to the research, authorship, and/or publication of this article.

Ethics Approval and Consent to Participate

The project has been approved by the Medical Research Center (MRC) IRB in Hamad Medical Corporation (16287/16). The study has been conducted in accordance with the ethical standards noted in the 1964 Declaration of Helsinki and its later amendments or comparable ethical standards. Informed consents were obtained from the participants.

Funding

The author(s) disclosed receipt of the following financial support for the research, authorship, and/or publication of this article: This work was supported by the Hamad Medical Corporation (grant number 16287/16).

ORCID iD

Abdulqadir J. Nashwan  <https://orcid.org/0000-0003-4845-4119>

References

1. Agool A, Schot BW, Jager PL, Vellenga E. 18F-FLT PET in hematologic disorders: a novel technique to analyze the bone marrow compartment. *J Nucl Med*. 2006 Oct 1;47(10):1592-1598.
2. Arber DA, Orazi A, Hasserjian R, et al. The 2016 revision to the World Health Organization classification of myeloid neoplasms and acute leukemia. *Blood*. 2016 May 19; 127(20):2391-2405.
3. Yassin MA, Nehmeh SA, Nashwan AJ, et al. A study of 18F-FLT positron emission tomography/computed tomography imaging in cases of prefibrotic/early primary myelofibrosis and essential thrombocythemia. *Medicine (Baltimore)*. 2020;99(45):1–5.
4. Yassin MA, Taher A, Mathews V, et al. MERGE: a multinational, multicenter observational registry for myeloproliferative neoplasms in Asia, including Middle East, Turkey, and Algeria. *Cancer Med*. 2020;9(13):4512–4526.
5. Thiele J, The KH. WHO Diagnostic criteria for polycythemia vera, essential thrombocythemia, and primary myelofibrosis. *Curr Hematol Malig Rep*. 2009(Jan 4(1):33-40.
6. Thiele J, Kvasnicka HM, Facchetti F, Franco V, van der Walt J, Orazi A. European consensus on grading bone marrow fibrosis and assessment of cellularity. *Haematologica*. 2005Jan 1;90(8):1128-1132.
7. Shen G, Liang M, Su M, Kuang A. Physiological uptake of 18F-FDG in the vertebral bone marrow in healthy adults on PET/CT imaging. *Acta Radiol*. 2018 Dec;59(12):1487-1493.
8. Hatt M, Le Rest CC, Turzo A, Roux C, Visvikis D. A fuzzy locally adaptive Bayesian segmentation approach for volume determination in PET. *IEEE Trans Med Imaging*. 2009 Jan 13;28(6):881-893.
9. Barbui T, Thiele J, Carobbio A, et al. Disease characteristics and clinical outcome in young adults with essential thrombocythemia versus early/prefibrotic primary myelofibrosis. *Blood*. 2012 July 19;120(3):569-571.

10. Barbui T, Thiele J, Gisslinger H, et al. The 2016 WHO classification and diagnostic criteria for myeloproliferative neoplasms: document summary and in-depth discussion. *Blood Cancer J.* 2018;8(2):1-11.
11. Finazzi G, Carobbio A, Thiele J, et al. Incidence and risk factors for bleeding in 1104 patients with essential thrombocythemia or prefibrotic myelofibrosis diagnosed according to the 2008 WHO criteria. *Leukemia.* 2012;26(4):716-719.
12. Vercellino L, Ouvrier MJ, Barré E, et al. Assessing bone marrow activity in patients with myelofibrosis: results of a pilot study of 18F-FLT PET. *J Nucl Med.* 2017;58(10):1603-1608.