



Review

Endoscopic Management of Pediatric Cholesteatoma

Peter J. Ryan^a, Nirmal P. Patel^{a, b, *}^a Department of Otolaryngology and Head and Neck Surgery, Royal North Shore Hospital, St Leonards, NSW, Australia^b Kolling Deafness Research Centre, Macquarie University and University of Sydney, NSW, Australia

ARTICLE INFO

Article history:

Received 22 July 2018

Received in revised form

19 November 2018

Accepted 20 November 2018

Keywords:

Cholesteatoma

Pediatric

Endoscopic

Minimally-invasive

Middle ear

Mastoid

ABSTRACT

Pediatric cholesteatoma occurs in one of two forms: congenital cholesteatoma, developing from embryonic epidermal cell rests or acquired cholesteatoma, associated with a focal defect in the tympanic membrane. This disease has been traditionally managed with the operating microscope, often requiring mastoidectomy for adequate visualization of and access to the middle ear and mastoid cavities. Recently, advances in endoscopic equipment have enabled otologists to manage most cases of pediatric cholesteatoma via a minimally-invasive, transcanal endoscopic approach. This review discusses the current literature relating to the etiopathogenesis, assessment and endoscopic management of pediatric cholesteatoma. Early outcomes of endoscopic treatment, emerging trends and technologies are also reviewed.

© 2018 PLA General Hospital Department of Otolaryngology Head and Neck Surgery. Production and hosting by Elsevier (Singapore) Pte Ltd. This is an open access article under the CC BY-NC-ND license (<http://creativecommons.org/licenses/by-nc-nd/4.0/>).

Contents

1. Introduction	18
2. Epidemiology	18
3. Classification	18
3.1. Congenital cholesteatoma	18
3.1.1. Classification	19
3.1.2. Etiology	19
3.1.3. Staging	20
3.2. Acquired cholesteatoma	20
3.2.1. Classification	20
3.2.2. Etiology	20
4. Preoperative assessment and operative planning	20
4.1. Clinical assessment for TEES	21
4.1.1. Lateral meatus	21
4.1.2. Bony canal	21
4.1.3. Meatus and canal relative to disease burden	21
4.2. Radiological assessment for TEES	22
4.2.1. Computed tomography	22
4.2.2. Diffusion-weighted magnetic resonance imaging	22
5. Intraoperative considerations	22
5.1. Anesthetic	22
5.2. Positioning and wound preparation	22
6. Removal of cholesteatoma in hidden areas and special considerations	23

* Corresponding author. Suite A12, 24 Lexington Drive, Bella Vista, NSW, 2153, Australia.

E-mail address: nirmal.p.patel@gmail.com (N.P. Patel).

Peer review under responsibility of PLA General Hospital Department of Otolaryngology Head and Neck Surgery.

<https://doi.org/10.1016/j.joto.2018.11.009>

1672-2930/© 2018 PLA General Hospital Department of Otolaryngology Head and Neck Surgery. Production and hosting by Elsevier (Singapore) Pte Ltd. This is an open access article under the CC BY-NC-ND license (<http://creativecommons.org/licenses/by-nc-nd/4.0/>).

6.1. Attic and antrum 23
 6.2. Retrotympanum 23
 6.3. Protympanum 23
 6.4. Limited canal wall up mastoidectomy (LCWU) with endoscope assistance 23
 6.5. Special considerations for acquired cholesteatoma 23
 6.6. Special considerations for congenital cholesteatoma 24
 6.7. Considerations in endoscopic pediatric ear reconstruction 24
 7. Outcomes with EES compared to CWU 24
 8. Future considerations 25
 9. Conclusion 25
 Funding 25
 References 25

1. Introduction

Congenital and acquired pediatric cholesteatoma has been successfully managed with the microscope for many decades. Minimally invasive approaches that seek to minimize trauma to normal tissue yet achieve similar surgical goals would be logical to apply to the pediatric population. In the last 5 years, with the introduction of high quality narrow diameter endoscopes, cold light sources, ultra-high definition cameras and screens, endoscopic ear surgery (EES) has evolved into a method to successfully treat pediatric cholesteatoma in a minimally invasive manner. This review seeks to outline the current methods and results of EES in the pediatric cholesteatoma population.

2. Epidemiology

The true incidence of pediatric cholesteatoma is not known, and epidemiological studies are sparse. A retrospective review of 122 children operated on for cholesteatoma in Denmark between 1965 and 1978 inferred an annual incidence of pediatric cholesteatoma of 2.9 per 100 000 children (Tos, 1983). This reported incidence remains a good estimate despite its limitation to a single centre in a well-developed country with excellent access to health care. In children, there appears to be a slight male predilection (relative risk 1.4) (Olszewska et al., 2004). The mean ±SD age of children at diagnosis is 5.6 ±2.8 years in congenital cholesteatoma and 9.7 ±3.3 years in acquired cholesteatoma (Nelson et al., 2002). A large historical cohort study (Djurhuus et al., 2015) demonstrated a 20-fold increase in the incidence of surgically-treated middle ear cholesteatoma in individuals with cleft palate and a 14-fold increase in the incidence among individuals with cleft lip and palate. However, no difference in incidence was observed in individuals with cleft lip alone. Girls with Turner syndrome are at a higher risk of developing middle ear disease, including cholesteatoma (Hall et al., 2009) with a reported lifetime incidence in this population of approximately 4% (Lim et al., 2014).

3. Classification

Broadly, pediatric cholesteatoma is classified as congenital or acquired. Congenital cholesteatoma occurs as a “closed type” congenital cholesteatoma (CTCC), the more common encapsulated cyst; or an “open type” congenital cholesteatoma (OTCC) where the stapes is replaced by a medial and lateral plaque-like keratinizing epithelium. Acquired pediatric cholesteatoma is further subdivided into more common middle ear/mastoid or rarer external ear canal.

3.1. Congenital cholesteatoma

Congenital cholesteatoma occurs behind an intact tympanic membrane in a patient with no history of perforation or otorrhea and no prior otologic surgery (Levenson et al., 1989). Congenital cholesteatoma accounts for 10–28% of pediatric cholesteatomas (Potsic et al., 2002a) although this may be underestimated as congenital cholesteatomas resulting in perforation of the tympanic membrane may be incorrectly classified as acquired disease (Darrouzet et al., 2002). Fig. 1 shows the atypical otoscopic findings of an OTCC that may be mistaken for acquired cholesteatoma.

Consistent with an increasing awareness of the disease and improved otoscopic equipment, the most common presentation of congenital cholesteatoma is an asymptomatic middle ear mass (82% of cases) (Potsic et al., 2002a) as seen in Figs. 2 and 3. In this retrospective cohort study, the authors found that 13% of congenital cholesteatomas were found at myringotomy for serous otitis media.

The anterosuperior quadrant is most commonly involved (82% of cases), followed by the posterosuperior quadrant (49% of cases). Ossicular chain involvement and mastoid extension is present in 42% and 23% of cases respectively. Single-quadrant disease is confined to the anterosuperior quadrant in 77% of cases and the posterosuperior quadrant in 22% of cases (Potsic et al., 2002a).

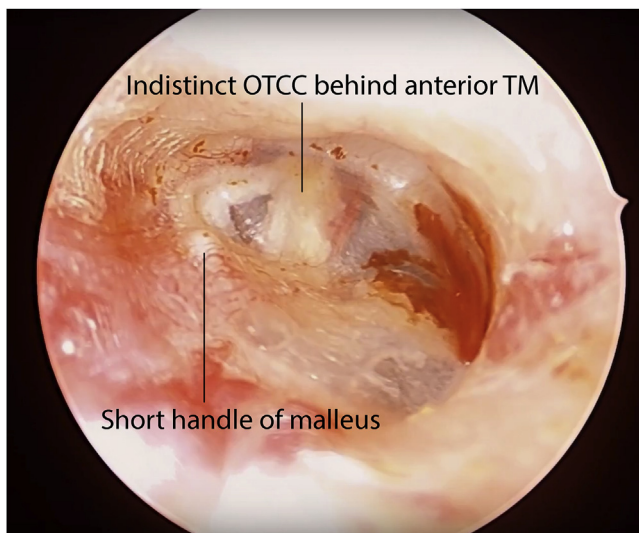


Fig. 1. Atypical otoscopic findings in open type congenital cholesteatoma may be mistaken for acquired cholesteatoma in a 10-year-old, right ear.

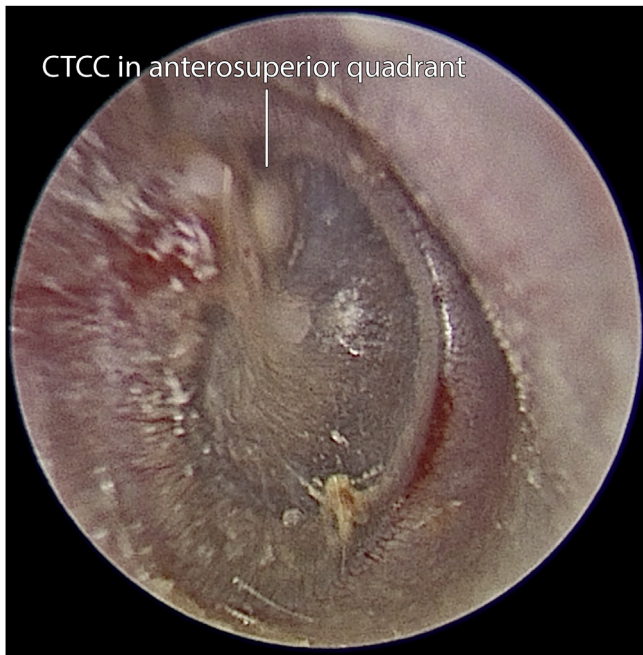


Fig. 2. Otoscopic view of a CTCC in a 2-year-old, right ear.

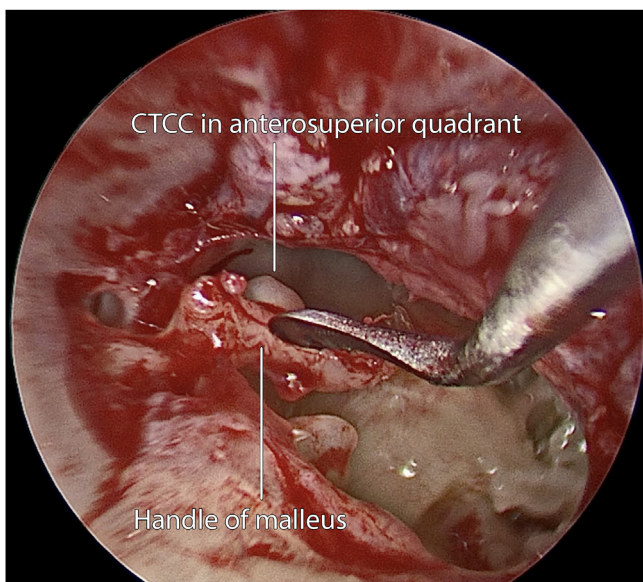


Fig. 3. Operative findings of the CTCC in the same 2-year-old shown in Fig. 2.

3.1.1. Classification

Histopathologically, congenital cholesteatoma takes one of two forms. CTCCs occur as an epithelial cyst without exposure of keratin (Figs. 2 and 3), whereas OTCCs occur as plaque-like lesions of keratinizing epithelium usually replacing a portion or all of the stapes (Figs. 4 and 5). CTCC has a higher prevalence than OTCC (approximately two-thirds of cases), confirmed in most published series (Bacciu et al., 2014). A 15-year retrospective review of 96 congenital cholesteatomas compared the clinical features of the two forms: CTCC was associated with a younger age at diagnosis (6.5 years compared to 11 years in OTCC). 100% of CTCC were diagnosed with otoscopy compared to 40% of OTCC. All cases of OTCC were of a more advanced stage at diagnosis (64% Stage III; 36% Stage IV). The

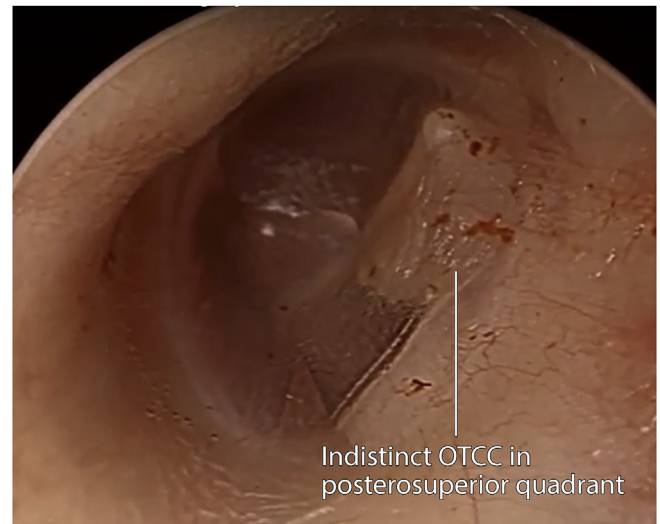


Fig. 4. Otoscopic view of an OTCC in a 12-year-old, left ear.

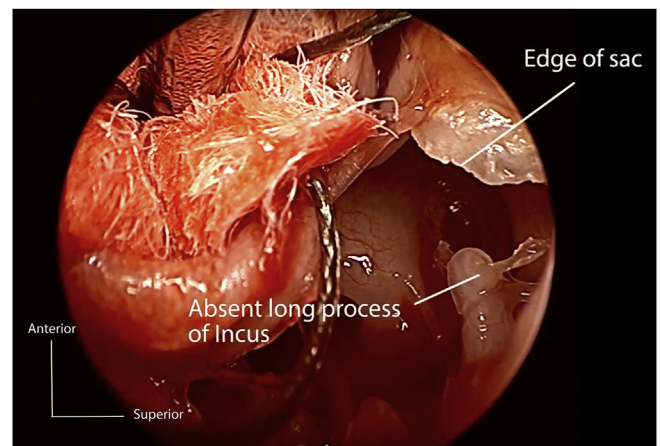


Fig. 5. Operative findings of the OTCC in the same 12-year-old shown in Fig. 4.

authors demonstrated a significantly increased rate of residual cholesteatoma (based on postoperative otoscopy) in OTCC (OR 7.39, 95% CI 1.1–49.8, $p = 0.03$) (Bacciu et al., 2014).

3.1.2. Etiology

The etiology of congenital cholesteatoma is not known with certainty. Multiple etiopathogenic theories have been proposed and discussed over more than a century, however many remain without convincing supportive evidence (Persaud et al., 2007). The most widely accepted etiopathogenic theory was proposed by Michaels (1986). He studied stained sections of 76 fetal temporal bones and demonstrated the presence of an epidermoid (distinct squamous cell nest with unknown function) in the anterosuperior mesotympanum (Persaud et al., 2007). In his series, this epidermoid formation was not found beyond a gestational age of 33 weeks and Michaels proposed that its persistence could lead to the development of congenital cholesteatoma. In a more recent study, Levine, et al. (1998) demonstrated persistence of epidermoid formations in fetal and postnatal temporal bones beyond 33 weeks gestation to an age of 2 years and 7 months. This work alone did not explain congenital cholesteatomas originating in other areas of the middle ear. More recently, however, epidermoid formations have been demonstrated in other regions of the middle ear, strongly

supporting epidermoid formation as the anlage for congenital cholesteatoma (Persaud et al., 2007).

3.1.3. Staging

Potsic et al. (2002b) proposed the widely used staging system for congenital cholesteatoma, shown in Table 1. The authors demonstrated that the incidence of residual disease increased with disease stage, from 13% in stage I disease to 67% in stage IV disease. A similar classification was employed by Nelson et al. (2002), that likewise demonstrated higher rates of residual cholesteatoma with more advanced disease.

3.2. Acquired cholesteatoma

The development of acquired cholesteatoma (Fig. 6) is associated with a defect in the tympanic membrane, most commonly a focal retraction pocket (Persaud et al., 2007).

3.2.1. Classification

Historically, acquired cholesteatoma has been classified “primary acquired” cholesteatoma where it originates in a limited retraction of the pars flaccida and “secondary acquired” cholesteatoma where it occurs as a result of a posterosuperior tympanic membrane perforation. Lau and Tos (1989) proposed an alternative classification that is more clinically useful and based on otoscopic findings: (1) attic cholesteatomas originate in a retraction or perforation of Shrapnell’s membrane; (2) sinus cholesteatomas originate in a retraction or perforation of the posterosuperior tympanic membrane, spreading to the stapedial niche and tympanic sinus; (3) tensa retraction cholesteatomas arise from a retraction or perforation of the whole pars tensa, including anterior and inferior segments.

Acquired cholesteatoma can occur outside of the middle ear cavity in other areas of the skull, intracranially and in the external auditory canal (EAC). Pediatric EAC cholesteatoma is a rare entity that may be confused with keratosis obturans (Olszewska et al., 2004) and has been associated with significant morbidity including formation of a labyrinthine fistula and invasion into the bony wall of the jugular bulb (Jang et al., 2016b). EAC cholesteatoma is, therefore, an important consideration in a child presenting with otalgia, otorrhea and no apparent middle ear disease.

3.2.2. Etiology

Like congenital cholesteatoma, the etiology of acquired cholesteatoma is not known with certainty. Local infection is commonly found in the setting of cholesteatoma, however its role in cholesteatoma etiology is not confirmed.

The most widely accepted etiopathogenic theory was proposed by Tos (1988), in which a cholesteatoma forms within a deep, advancing retraction pocket most commonly of the pars flaccida. The tympanic membrane is composed of three embryologic layers: an inner endodermal mucosal layer, a middle fibrous mesodermal lamina, and an outer ectodermal epithelial layer, the latter possessing a unique radial migratory capability (Louw, 2010) that confers to the tympanic membrane an ability to self-cleanse (Preciado, 2012). In the setting of chronic eustachian tube

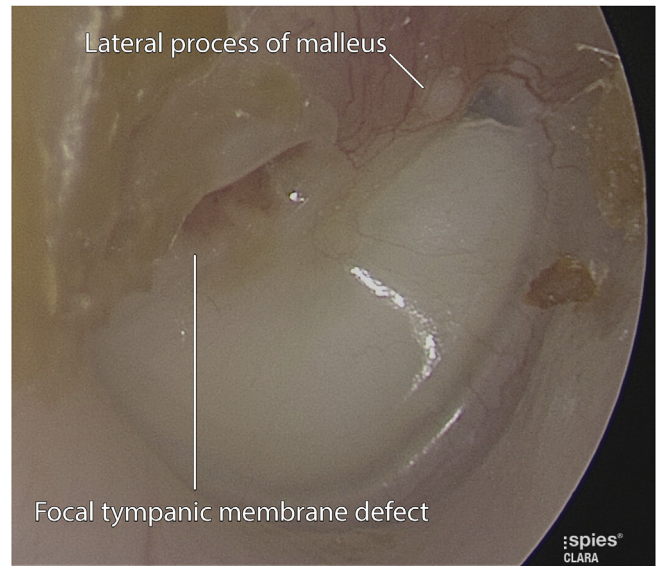


Fig. 6. Acquired pediatric cholesteatoma resulting from a focal defect in the tympanic membrane in a 5-year-old, right ear.

dysfunction, as a retraction pocket advances and its neck narrows, the ability of the retracted epithelium to self-cleanse becomes impaired, debris and actively proliferating epithelium becoming trapped to form a cholesteatoma sac.

Several other theories explain the origin of cholesteatoma in other areas of the middle ear cavity. Epithelial migration around the margin of a perforation can occur anywhere on the tympanic membrane. Intervening infection can arrest migration, invoke hyperplasia and induce cholesteatoma formation (Louw, 2010). Blast injuries, middle ear surgery and fractures of the petrous temporal bone can result in implantation of epithelium in the middle ear cavity, potentially resulting in cholesteatoma formation.

4. Preoperative assessment and operative planning

Complete transtympanic visualization of the middle ear cavity with the operating microscope is difficult in all but the largest canals, with the view limited by the narrowest segment of the ear canal (Tarabichi and Kapadia, 2017). For this reason, the preferred traditional approach to pediatric cholesteatoma has involved a postauricular canal wall up (CWU) mastoidectomy, canalplasty and a posterior tympanotomy to provide access to the tympanic cavity for visualization and instrumentation. Due to slightly lower rates of recidivism, CWD procedures may be appropriate in patients for whom follow-up presents difficulties or resources available for relook procedures are scarce (McGuire et al., 2016; Osborn et al., 2012). However, in the pediatric population, the requirement for long-term follow-up and mastoid cavity care, poorer hearing outcomes, water exposure restrictions and future considerations such as fitting of hearing aids mean that canal wall down (CWD) procedures are largely out of favor except for markedly aggressive

Table 1
Staging of congenital cholesteatoma (Potsic et al., 2002b).

Stage	Description
I	Single quadrant disease without ossicular involvement or mastoid extension
II	Disease involving multiple quadrants without ossicular involvement or mastoid extension
III	Ossicular involvement, defined as ossicular erosion or necessity of surgical removal for disease eradication
IV	Disease with any mastoid extension

recurrent disease (Shirazi et al., 2006).

The wide viewing angle of modern endoscopes (Fig. 7) overcomes many of the limitations of the operating microscope, making minimally-invasive, transcanal endoscopic ear surgery (TEES) feasible for the management of pediatric cholesteatoma of the tympanic cavity (Marchioni et al., 2015). When cholesteatoma extends through the aditus into the mastoid, microscopic removal remains the gold standard.

Careful preoperative assessment is essential to determine the extent of disease and therefore, parent/patient preoperative counseling. Clinical and radiological assessment proceeds from lateral to medial, determining whether resection will be totally endoscopic, require a canal widening procedure and/or mastoidectomy.

4.1. Clinical assessment for TEES

Three particular domains should be assessed preoperatively to identify limitations or obstacles to TEES. This assessment is possible in the otologist's rooms or clinic prior to surgery.

4.1.1. Lateral meatus

Rigid endoscopy performed preoperatively with a 3 mm scope is useful to identify the meatal diameter and determine its capacity to accommodate both scope and instruments during TEES. Pediatric cartilage as well as skin is thinner and relatively more elastic than the adult. Therefore, a “collapsing canal” is more likely with suction, which in turn may cause barotrauma of the ear canal skin and tympanic membrane, impairing the surgeon's view.

4.1.2. Bony canal

The pediatric canal doubles in length from 11 to 20 mm between the ages of 5 and 18 (Isaacson, 2014). During that time the external bony canal diameter increases from 4 to 6 mm. Concerns regarding the narrow pediatric ear canal limiting the utility of endoscopic approaches to the tympanic cavity are valid but appear not to be well-founded with several series reporting successful removal of pediatric cholesteatoma confined to the tympanic cavity in all included cases (Ito et al., 2015; Marchioni et al., 2015). A Japanese series demonstrated successful cholesteatoma removal by TEES using rigid endoscopes with a 2.7 mm outer diameter through canals as narrow as 3.2 mm anteroposteriorly and 3.4 mm superiorly (Ito et al., 2015). Nevertheless, a narrow canal can significantly limit the view and passage of instruments during EES as demonstrated in Figs. 8 and 9.

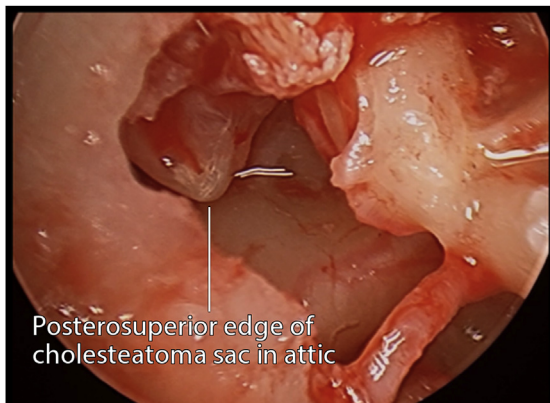


Fig. 7. Angled scope view of attic cholesteatoma sac in a right ear, exemplifying the wide viewing angle of modern endoscopes in a 12-year-old.

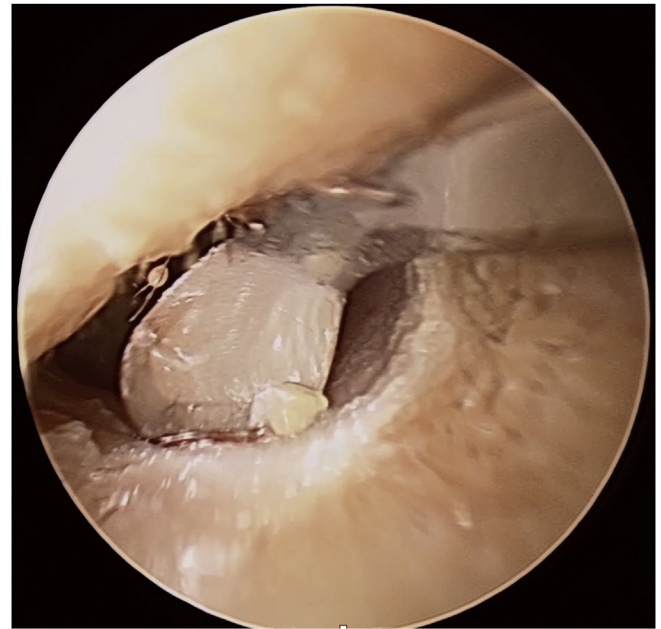


Fig. 8. Narrow left ear canal with angled beaver tympanoplasty blade demonstrating the limitation a narrow canal can place on the view and passage of instruments in a 3-year-old, left ear.

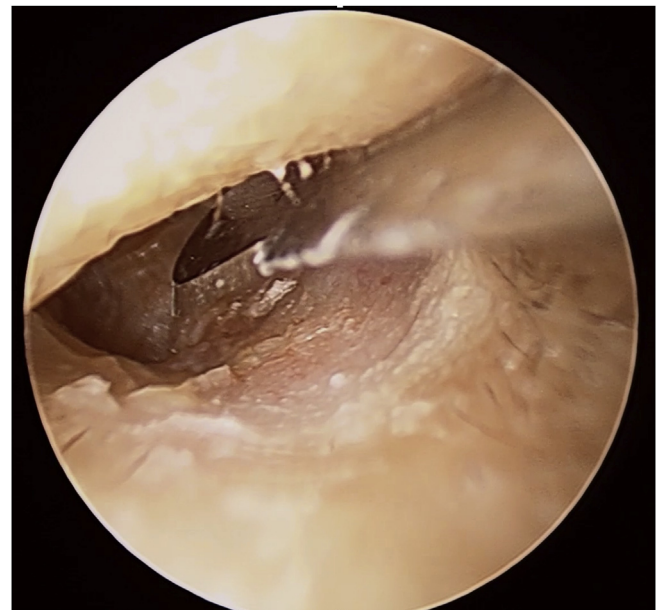


Fig. 9. Straight beaver tympanoplasty blade permitted more easily in the same narrow canal as Fig. 8.

4.1.3. Meatus and canal relative to disease burden

Once the meatus and bony canal have been assessed, the approach should be assessed relative to the disease burden. If the disease can be visualized with a 0-degree scope at the bony-cartilaginous junction then complete endoscopic removal is likely. If there is a narrow canal or large anterior overhang and the view of the disease is limited, then the parents/patient may need to be counseled regarding canal widening.

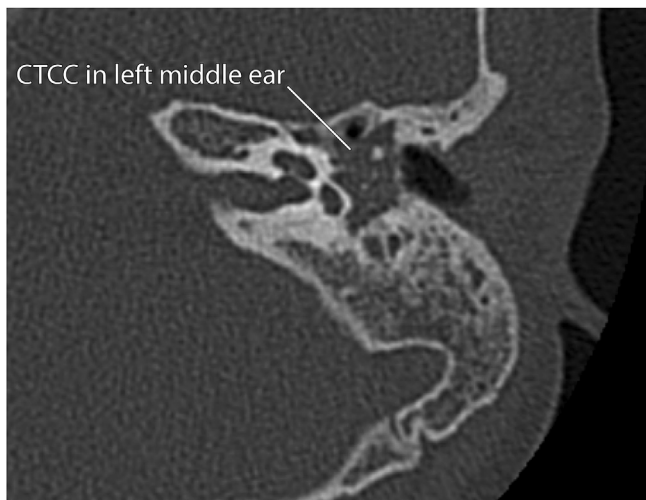

Fig. 10. Axial CT image of a left CTCC in a 5-year-old.

4.2. Radiological assessment for TEES

Radiological assessment is used to identify the presence and extent of cholesteatoma spread into the mastoid and temporal bone.

4.2.1. Computed tomography

CT (Fig. 10) is the ideal modality for assessment of disease and bony erosion however, certain considerations need to be made in the pediatric population. Firstly, children below 4 may find lying still difficult even for the short acquisition times of modern machines. Secondly, radiation concerns of the parents need to be balanced with the requirement for accurate preoperative planning. The effective radiation dose of computed tomography in children is relatively high compared with other imaging modalities and is increased due, in part, to their small body size (Kim et al., 2017). The effective radiation dose of a low-dose temporal bone CT protocol in a 5-year-old child is 0.25 mSv compared with up to 1.7 mSv in literature-derived protocols (Nauer et al., 2011). The annual background radiation in the United States is 2.28 mSv (United States Environmental Protection Agency, 2018). Low dose temporal bone CT appears sufficient to define the bony anatomy of the middle ear however the detail provided is insufficient for the identification of smaller structures such as the stapes (Nauer et al., 2011). Pediatric temporal bone CT potentially exposes radiosensitive organs such as

Box 1

Comparative radiation doses. Compiled from (NSW ACI, 2012) and (Nauer et al., 2011)

Exposure	Effective dose (mSv)
Chest X-Ray	~0.02
7-h flight	0.05
Mammogram	0.1 to 1
Low-dose CT petrous temporal bones	0.25
Return flight (Sydney to London)	~0.25
CT petrous temporal bones (literature-derived protocols)	0.9 to 2.6
Annual background radiation (USA)	2.28
CT pulmonary angiogram	>10

the eyes and thyroid. The effective radiation dose of a single, high-dose temporal bone CT scan in a child is not sufficient to confer carcinogenic or other health-related risks (Box 1) (Kim et al., 2017). However, subjecting patients to the lowest possible dose that achieves the image quality and detail required for preoperative planning is appropriate.

Disease that extends posterior to the lateral semicircular canal, into a deep type c sinus tympani or complications of cholesteatoma such as fistulae or tegmen erosions will generally require preoperative counseling for mastoidectomy.

4.2.2. Diffusion-weighted magnetic resonance imaging

Diffusion weighted MRI (Non-EPI DWI) is the imaging of choice for identifying cholesteatoma in the mastoid. Children have a lower sensitivity and specificity (65–70%) (Clarke et al., 2017) likely due to higher prevalence of inflammatory disease in the developing ear compared to the adult. MRI-identification of disease is also poor when its size is < 4 mm or in an OTCC where the keratin is flat.

5. Intraoperative considerations

5.1. Anesthetic

Endoscopic work is possible under assisted local anesthesia; however, the vast majority of pediatric cases require a general anesthetic with intubation using a standard endotracheal tube or laryngeal mask. South RAE tubes, commonly used in otolaryngological procedures, should be avoided as long procedure times may cause compressive injury to the lower lip.

Volatile anesthetics, propofol and older opioids such as morphine cause vasodilation (Saad and Aladawy, 2013), thereby increasing bleeding.

A total intravenous anesthetic (TIVA) using a remifentanyl and propofol infusion has been reliably demonstrated in endoscopic sinus and craniofacial surgery to reduce intraoperative bleeding, post-operative edema and ecchymoses (Eberhart et al., 2003; Wormald et al., 2005). Controlled hypotension is more easily achieved in TIVA; remifentanyl, a very short-acting μ -opioid agonist and propofol enable more precise control of intraoperative blood pressure compared with volatile inhalational anesthetics such as sevoflurane/isoflurane plus fentanyl/alfentanil (Eberhart et al., 2003; Wormald et al., 2005). The pulse and mean arterial blood pressure should be kept as low as possible, within the safety profile of the patient.

5.2. Positioning and wound preparation

The patient's head is placed on a small head ring and if the child is < 12 years of age then often a small gel bag is required under the shoulders to slightly extend the neck and offset the occipital protuberance. A facial nerve monitor is used in all cases and the surgeon should avoid over-rotating the neck which may lead to neurapraxia and jugular compression. Slight reverse Trendelenburg is preferred by some surgeons to theoretically reduce bleeding.

If the need for a postauricular incision is anticipated with preoperative planning, then hair is shaved and the skin marked up now.

Injection is performed, either preoperatively or after sterile preparation of the skin, with 0.75% Ropivacaine and 1:50000 adrenaline. Caution is required in children under 3 years as the mastoid tip is not formed yet. When injecting near the mastoid tip a finger is placed in the tympanomastoid groove to disperse local anesthesia away from the facial nerve.

A single canal injection (25G – 30G) very slowly in the vascular strip is often all that is required, as well as tragal and conchal

injections. Overinjection should be avoided as this may greatly reduce vision in the canal. Neuro Patties or an Otowick (Medtronic, 2018) with 1:1000 adrenaline is placed in the bony medial canal whilst hair is then cut from the lateral meatus.

Equipment that is required for most endoscopic pediatric cholesteatoma surgery include, the smaller diameter 3 mm endoscopes (11–14 cm, 0, 30 and 45°) as well as, a dedicated endoscopic ear surgery tray with angled instruments (Karl Storz GmbH, 2018; Spiggle & Theis Medizintechnik GmbH, 2018).

6. Removal of cholesteatoma in hidden areas and special considerations

6.1. Attic and antrum

Bone removal for access to the attic and antrum includes the standard variety of methods: curette, protected tip burr, piezo-electric devices and osteotome. Minimal bone removal is all that is usually required to see all aspects of the anterior and posterior attic with angled scopes. Care is required in this region with insertion and manipulation of angled scopes and instruments. Furthermore, excessive removal of the scutum may create a problem with reconstruction as pediatric tragal cartilage is smaller than the adult.

6.2. Retrotympanum

An area that is difficult to access with traditional canal wall up methods, the retrotympanum usually requires 30- or 45-degree scopes to visualize the lateral aspects of region (Fig. 11). Moving to the contralateral side of the patient's head may help the surgeon with visualization and more natural hand eye movements. An intimate knowledge of the anatomy including sub-classification of recesses allows the surgeon to be confident of removal, when for example bridge configurations need to be removed to fully access disease.

6.3. Protympanum

The protympanum is the region in front of the cochleocarotid groove, bound superiorly by the tensor canal and supratubal recess, inferiorly by the protiniculum and laterally by the lateral lamina which separates the region from the mandibular fossa. Pediatric

cholesteatoma often occurs in pneumatized bones so this region is well developed and subclassifications, which have been recently described (Jufas et al., 2016) should be understood by the surgeon.

The protympanum usually requires removal of the tympanic membrane off the handle of the malleus and angled scopes to be completely visualized (Figs. 12 and 13). Manipulation of angled instruments in the region should be undertaken with care to avoid injury to the stapes bone as well as the facial nerve. When beginning to dissect this region, the novice endoscopic surgeon should start with either division of the incudostapedial joint or removal of the ossicles to minimize the risk of sensorineural hearing loss.

6.4. Limited canal wall up mastoidectomy (LCWU) with endoscope assistance

With extensive mastoid disease a mastoidectomy is required. In combination with the endoscopic approach, no canalplasty or disturbance of the lateral vascular strip occurs, so a limited canal wall up mastoidectomy (LCWU) is preferred. The limited form still requires identification of the tegmen, posterior canal wall and sigmoid sinus, however, bony removal does not need to extend posteriorly to view the attic. Furthermore, angled endoscopes may be used to assist in the lateral attic and antral dissection. A wet sponge can be placed at the posterior margin of the mastoidectomy incision and the endoscope rested on the sponge to minimize slipping of the scope on a wet mastoidectomy site.

Since no external canal surgery occurs in the LCWU, the neotympanic membrane heals quicker and there is a reduced risk of blunting and external ear canal healing problems.

6.5. Special considerations for acquired cholesteatoma

The acquired form of pediatric cholesteatoma has two macroscopic forms, an encapsulated sac or infiltrative. Furthermore, in children the disease is often concurrent with acute or chronic inflammation making dissection particularly difficult. Using methods outlined previously to reduce bleeding including TIVA anesthetic, reverse Trendelenburg position, proper infiltration, frequent use of 1:1000 adrenaline-soaked Neuro patties, irrigation and patience will help.

Laser ablation of dissected regions using CO₂, Argon or KTP (Potassium titanyl phosphate) laser, has been shown to reduce recurrence rates in small series, particularly in the pediatric population (Hamilton, 2005; James, 2013; le Nobel and James, 2016).

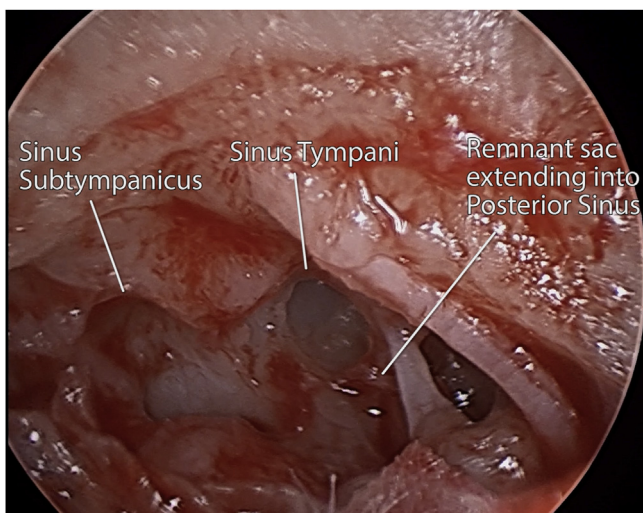


Fig. 11. Contralateral view of retrotympanum after resection in an 8-year-old, right ear.

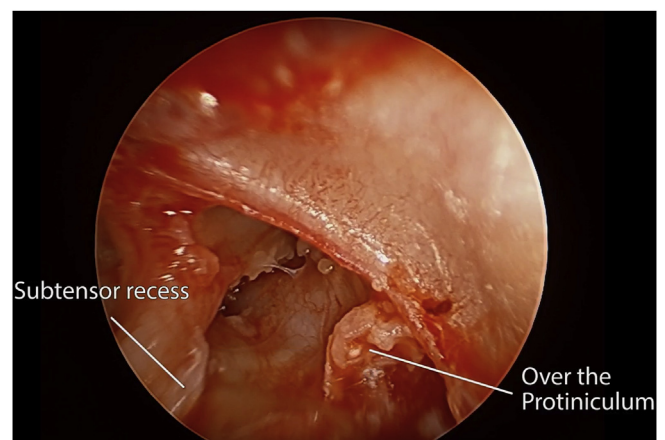


Fig. 12. Protympanum: cholesteatoma in subtensor space and over protiniculum in a 10-year-old, right ear.

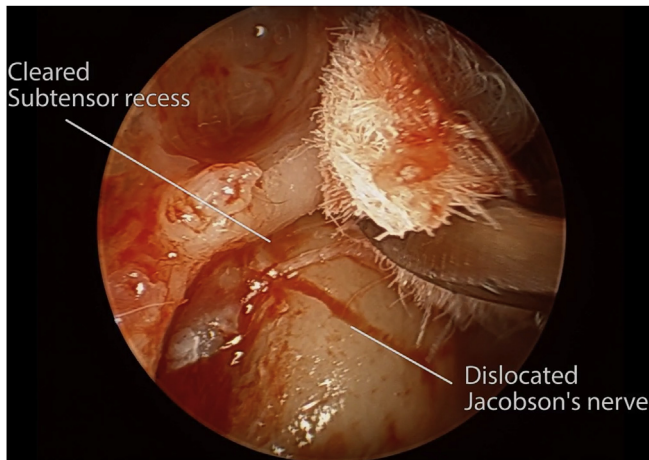


Fig. 13. Protympanum: clearing the subtensor recess in a 10-year-old, right ear.

Care of course should be taken in region of the facial nerve, oval and round windows.

6.6. Special considerations for congenital cholesteatoma

CTCC represents an ideal indication for EES. Angled scopes may provide a view of the anterior aspect of the handle of the malleus and tensor tympani to facilitate direct-view dissection of disease in this region (Fig. 14). A recent Korean publication highlights the possibility of successfully removing cysts applied to the tympanic membrane with a transtympanic incision and gelfoam patch (Jang et al., 2016a). Also, a larger series of congenital cholesteatoma demonstrated that lesions that are involving the tensor tympani tendon tend to have a higher recurrence rate (Lee et al., 2017).

The OTCC has a variable relationship to the oval window. Care may often be required here as the epithelial plaque may replace the footplate and dissection reveals membranous labyrinth which requires simultaneous perichondrial or fascial patching, to reduce the risk of sensorineural hearing loss.

6.7. Considerations in endoscopic pediatric ear reconstruction

Reconstruction of the attic and tympanic membrane following cholesteatoma resection in EES most commonly uses composite

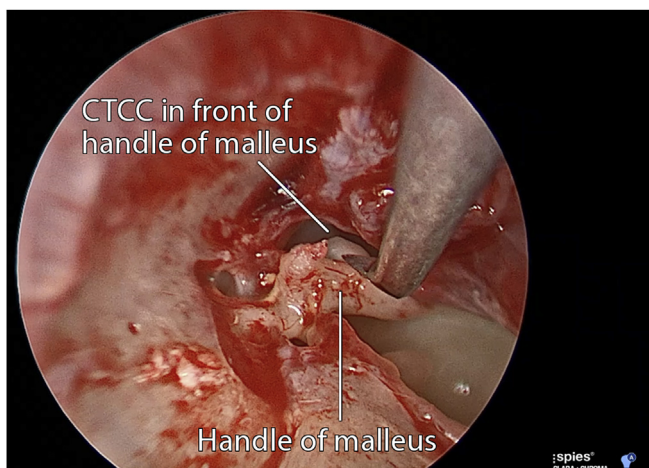


Fig. 14. Dissection of CTCC off the handle of malleus in a 2-year-old, right ear.

cartilage grafts (Figs. 15 and 16). Cartilage has been reliably demonstrated to retract less and provides similar hearing results (Dornhoffer, 1997). Two unique challenges are encountered compared to the adult reconstruction (see Fig. 17).

- Pediatric tragal cartilage is relatively smaller and thinner than the adult – care must be taken to minimize the defect size to only that which is required. Other possible sites of composite cartilage graft harvest include the conchal bowl and triangular fossa.
- Ongoing Eustachian tube dysfunction and exposure to environmental risks means that in the younger child, post reconstruction infections and chronic otitis media may occur. Some authors advocate the use of ventilation tubes in such recurrent cases in front or through the cartilage graft (Russell et al., 2015).

7. Outcomes with EES compared to CWU

Several recent studies have compared outcomes in TEES for removal of cholesteatoma with outcomes in exclusively microscopic and combined transcanal, transmastoid approaches. Currently reported series are limited by relatively small sample sizes inhibiting the authors' ability to achieve statistical significance in important outcomes and the bias introduced by early endoscopic approaches being reserved for limited, early stage disease.

Two studies (Hunter et al., 2016; Marchioni et al., 2015) demonstrated lower rates of residual disease in endoscopic approaches to cholesteatoma removal (20%) compared with 40% in exclusively microscopic cases and 34.4% with CWD approaches ($p > 0.05$). Hunter et al. (2016) compared pure tone average, (PTA), air-bone gap (ABG) and word recognition (WR) scores pre- and post-operatively in patients undergoing exclusively microscopic, combined transcanal, transmastoid and TEES approaches. PTA, ABG and WR scores were tested in accordance with the guidelines of the Hearing Committee of the American Academy of Otolaryngology – Head and Neck Surgery (Gurgel et al., 2012). The authors demonstrated that pure tone averages improved postoperatively from 33.2 to 26.6 dB HL in exclusively microscopic approaches ($p = 0.054$), from 33.9 to 24.3 dB HL in transcanal, transmastoid approaches ($p = 0.047$) but most significantly from 27.4 to 16.7 dB HL ($p = 0.011$) in TEES approaches. Only patients undergoing TEES

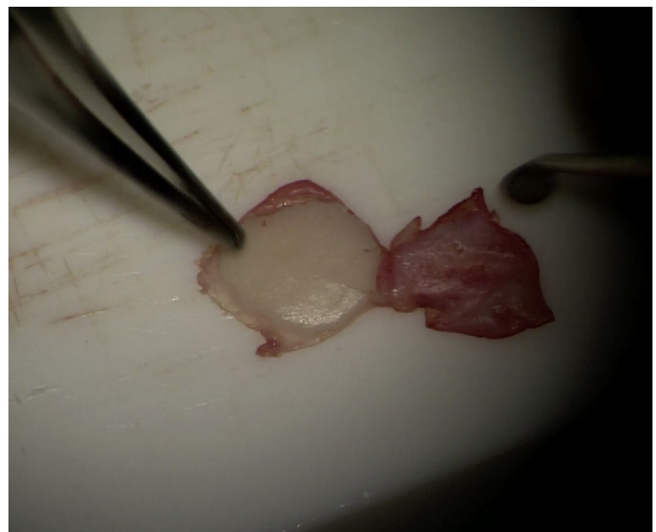


Fig. 15. Thin tragal cartilage graft used in reconstruction in a 3-year-old.

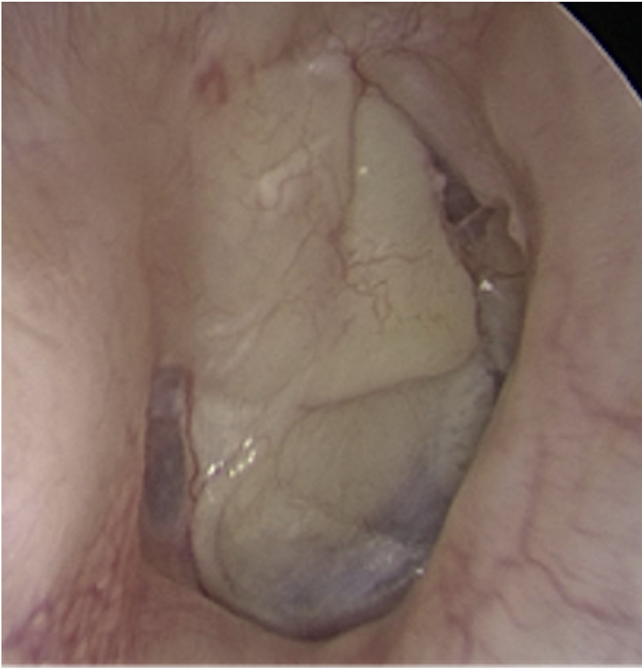

Fig. 16. Otoscopic view of a right post-operative attic and tympanum reconstruction (at 8 weeks), 12-year-old.

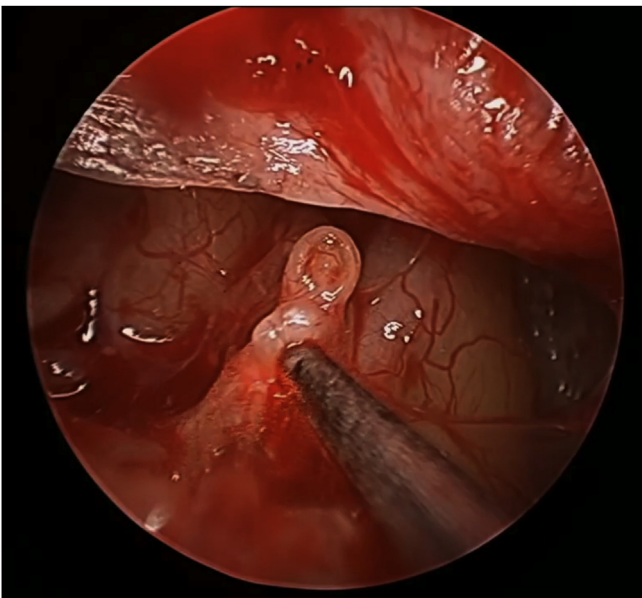


Fig. 17. KTP laser in use over the stapedius tendon during EES for pediatric cholesteatoma in a 6-year-old, left ear.

demonstrated a statistically significant improvement in the air-bone gap, although it is worth noting this group had the lowest preoperative PTA thresholds. At the time of reporting, mean length of follow-up for these two studies was 36 months (Marchioni et al., 2015) and 18.8 months (Hunter et al., 2016). There is evidence that TEES is associated with improved health-related quality of life (HRQoL) postoperatively (Lailach et al., 2015). Patients undergoing TEES demonstrated the lowest restriction in the hearing function, ear symptoms and mental health domains compared with transcanal, transmastoid and CWD approaches. The difference in ear

symptoms (otalgia, otorrhea, aural fullness, headache, hearing loss) was statistically significant (Lailach et al., 2015).

As the number of TEES cases continues to rise, newer equipment and techniques enable the treatment of more advanced disease via this approach. These early studies should be repeated to test the persistence and significance of promising but early outcomes.

8. Future considerations

Instrument and equipment improvements will likely expand the repertoire of EES.

Malleable and directable instruments such as the Malleable sinus suction catheters (MedTronic, 2018) available for endoscopic sinus surgery will likely soon be produced for the ear.

Scope technology continues to improve with chip on tip CMOS technology allowing autofocus and improved dynamic range of light. 3D endoscopes as small as 4 mm are now commercially available (Karl Storz GmbH, 2018) and some manufacturers have 3D bendable scopes to look around structures (Olympus Corp.). In time, with miniaturization, these technologies will translate into the ear.

In-camera live post processing with narrow band imaging (NBI) is available in several specialties to better identify tissue and blood vessels. Staining of keratin and identification with such technology is also a promising idea that may further reduce residual cholesteatoma rates.

Lastly, argon retinal lasers similar in outer diameter to current argon, CO₂ and KTP tips have been shown to be applicable to the ear in microscopic surgery (Yau et al., 2015). These lasers have an illuminated tip and are steerable. With miniaturization these may become a very useful tool in managing difficult to reach areas with TEES.

9. Conclusion

Most cases of pediatric cholesteatoma can now successfully be managed with a minimally invasive transcanal endoscopic approach. The otologist should consider this method, along with canal wall up and canal wall down techniques when managing cholesteatoma in the child.

Funding

This research did not receive any specific grant from funding agencies in the public, commercial, or not-for-profit sectors.

References

- Bacciu, A., Di Lella, F., Pasanisi, E., Gambardella, I., Saccardi, M.S., Bacciu, S., Vincenti, V., 2014. Open vs closed type congenital cholesteatoma of the middle ear: two distinct entities or two aspects of the same phenomenon? *Int. J. Pediatr. Otorhinolaryngol.* 78 (12), 2205–2209. <https://doi.org/10.1016/j.ijporl.2014.10.014>.
- Clarke, S.E., Mistry, D., Al Thubaiti, T., Khan, M.N., Morris, D., Bance, M., 2017. Diffusion-weighted magnetic resonance imaging of cholesteatoma using PROPELLER at 1.5T: a single-centre retrospective study. *Can. Assoc. Radiol. J.* 68 (2), 116. <https://doi.org/10.1016/j.carj.2016.05.002>.
- Darroutzet, V., Duclos, J.Y., Portmann, D., Bebear, J.P., 2002. Congenital middle ear cholesteatomas in children: our experience in 34 cases. *Otolaryngol. Head Neck Surg.* 126 (1), 34–40. <https://doi.org/10.1067/mhn.2002.121514>.
- Djurhuus, B.D., Skytthe, A., Faber, C.E., Christensen, K., 2015. Cholesteatoma risk in 8,593 orofacial cleft cases and 6,989 siblings: a nationwide study. *Laryngoscope* 125 (5), 1225–1229. <https://doi.org/10.1002/lary.25022>.
- Dornhoffer, J.L., 1997. Hearing results with cartilage tympanoplasty. *Laryngoscope* 107 (8), 1094–1099.
- Eberhart, L.H., Folz, B.J., Wulf, H., Geldner, G., 2003. Intravenous anesthesia provides optimal surgical conditions during microscopic and endoscopic sinus surgery. *Laryngoscope* 113 (8), 1369–1373. <https://doi.org/10.1097/00005537-200308000-00019>.
- Gurgel, R.K., Jackler, R.K., Dobie, R.A., Popelka, G.R., 2012. A new standardized

- format for reporting hearing outcome in clinical trials. *Otolaryngol. Head Neck Surg.* 147 (5) <https://doi.org/10.1177/0194599812458401>.
- Hall, J.E., Richter, G.T., Choo, D.L., 2009. Surgical management of otologic disease in pediatric patients with Turner syndrome. *Int. J. Pediatr. Otorhinolaryngol.* 73 (1), 57–65. <https://doi.org/10.1016/j.ijporl.2008.09.022>.
- Hamilton, J.W., 2005. Efficacy of the KTP laser in the treatment of middle ear cholesteatoma. *Otol. Neurotol.* 26 (2), 135–139.
- Hunter, J.B., Zuniga, M.G., Sweeney, A.D., Bertrand, N.M., Wanna, G.B., Haynes, D.S., Rivas, A., 2016. Pediatric endoscopic cholesteatoma surgery. *Otolaryngol. Head Neck Surg.* 154 (6), 1121–1127. <https://doi.org/10.1177/0194599816631941>.
- Isaacson, G., 2014. Endoscopic anatomy of the pediatric middle ear. *Otolaryngol. Head Neck Surg.* 150 (1), 6–15. <https://doi.org/10.1177/0194599813509589>.
- Ito, T., Kubota, T., Watanabe, T., Futai, K., Furukawa, T., Kakehata, S., 2015. Transcanal endoscopic ear surgery for pediatric population with a narrow external auditory canal. *Int. J. Pediatr. Otorhinolaryngol.* 79 (12), 2265–2269. <https://doi.org/10.1016/j.ijporl.2015.10.019>.
- James, A.L., 2013. Endoscopic middle ear surgery in children. *Otolaryngol. Clin North Am* 46 (2), 233–244. <https://doi.org/10.1016/j.otc.2012.10.007>.
- Jang, C.H., Jung, E.K., Sung, C.M., Kim, S.B., Kim, Y.Y., Seong, J.Y., Cho, Y.B., 2016a. Minimally invasive transcanal myringotomy for pediatric early stage congenital cholesteatoma. *Int. J. Pediatr. Otorhinolaryngol.* 90, 1–4. <https://doi.org/10.1016/j.ijporl.2016.08.013>.
- Jang, C.H., Kim, Y.Y., Seong, J.Y., Kang, S.H., Jung, E.K., Sung, C.M., Cho, Y.B., 2016b. Clinical characteristics of pediatric external auditory canal cholesteatoma. *Int. J. Pediatr. Otorhinolaryngol.* 87, 5–10. <https://doi.org/10.1016/j.ijporl.2016.05.029>.
- Jufas, N., Marchioni, D., Tarabichi, M., Patel, N., 2016. Endoscopic anatomy of the promyrtympanum. *Otolaryngol. Clin.* 49 (5), 1107–1119. <https://doi.org/10.1016/j.otc.2016.05.009>.
- Karl Storz GmbH, 2018. Human Medicine – Otorhinolaryngology. <https://www.karlstorz.com/de/en/ear-nose-throat.htm>. (Accessed 27 January 2018).
- Kim, S.Y., Kim, H.-S., Park, M.H., Lee, J.H., Oh, S.H., Chang, S.O., Kim, Y.H., 2017. Optimal use of CT imaging in pediatric congenital cholesteatoma. *Auris Nasus Larynx* 44 (3), 266–271. <https://doi.org/10.1016/j.anl.2016.07.009>.
- Lailach, S., Kemper, M., Lasurashvili, N., Beleites, T., Zahnert, T., Neudert, M., 2015. Health-related quality of life measurement after cholesteatoma surgery: comparison of three different surgical techniques. *Eur. Arch. Oto-Rhino-Laryngol.* 272 (11), 3177–3185. <https://doi.org/10.1007/s00405-014-3370-2>.
- Lau, T., Tos, M., 1989. Tensa retraction cholesteatoma: treatment and long-term results. *J. Laryngol. Otol.* 103 (2), 149–157.
- le Nobel, G.J., James, A.L., 2016. Recommendations for potassium-titanyl-phosphate laser in the treatment of cholesteatoma. *J. Int Adv Otol* 12 (3), 332–336. <https://doi.org/10.5152/iao.2016.2838>.
- Lee, C.H., Kim, S.Y., Kim, H.M., Kim, Y.J., Kim, J.Y., Kim, M.K., 2017. Cochleariform process abutment on TBCT in early congenital cholesteatoma. *Otol. Neurotol.* 38 (1), 79–85. <https://doi.org/10.1097/MAO.0000000000001240>.
- Levenson, M.J., Michaels, L., Parisier, S.C., 1989. Congenital cholesteatomas of the middle ear in children: origin and management. *Otolaryngol. Clin.* 22 (5), 941–954.
- Levine, J.L., Wright, C.G., Pawlowski, K.S., Meyerhoff, W.L., 1998. Postnatal persistence of epidermoid rests in the human middle ear. *Laryngoscope* 108 (1 Pt 1), 70–73.
- Lim, D.B., Gault, E.J., Kubba, H., Morrissey, M.S., Wynne, D.M., Donaldson, M.D., 2014. Cholesteatoma has a high prevalence in Turner syndrome, highlighting the need for earlier diagnosis and the potential benefits of otoscopy training for paediatricians. *Acta Paediatr.* 103 (7), e282–e287. <https://doi.org/10.1111/apa.12622>.
- Louw, L., 2010. Acquired cholesteatoma pathogenesis: stepwise explanations. *J. Laryngol. Otol.* 124 (6), 587–593. <https://doi.org/10.1017/S0022215109992763>.
- Marchioni, D., Soloperto, D., Rubini, A., Villari, D., Genovese, E., Artioli, F., Presutti, L., 2015. Endoscopic exclusive transcanal approach to the tympanic cavity cholesteatoma in pediatric patients: our experience. *Int. J. Pediatr. Otorhinolaryngol.* 79 (3), 316–322. <https://doi.org/10.1016/j.ijporl.2014.12.008>.
- McGuire, J.K., Wasl, H., Harris, T., Copley, G.J., Fagan, J.J., 2016. Management of pediatric cholesteatoma based on presentations, complications, and outcomes. *Int. J. Pediatr. Otorhinolaryngol.* 80, 69–73. <https://doi.org/10.1016/j.ijporl.2015.10.041>.
- Medtronic, 2018. Meroceel. <http://www.merocel.com/>. (Accessed 27 January 2018).
- MedTronic, 2018. Related Surgical Navigation Products. <http://www.medtronic.com/us-en/healthcare-professionals/products/ear-nose-throat/image-guided-surgery/fusion-ent-navigation-system/related-navigation-products.html>. (Accessed 27 January 2018).
- Michaels, L., 1986. An epidermoid formation in the developing middle ear: possible source of cholesteatoma. *J. Otolaryngol.* 15 (3), 169–174.
- Nauer, C.B., Rieke, A., Zubler, C., Candrea, C., Arnold, A., Senn, P., 2011. Low-dose temporal bone CT in infants and young children: effective dose and image quality. *AJNR Am J Neuroradiol* 32 (8), 1375–1380. <https://doi.org/10.3174/ajnr.A2524>.
- Nelson, M., Roger, G., Koltai, P.J., Garabedian, E.N., Triglia, J.M., Roman, S., Hammel, J.P., 2002. Congenital cholesteatoma: classification, management, and outcome. *Arch. Otolaryngol. Head Neck Surg.* 128 (7), 810–814.
- NSW ACI, 2012. Radiology Clinician Fact Sheet – Radiation Information. https://www.aci.health.nsw.gov.au/_data/assets/pdf_file/0006/174552/MI-Clinician-Factsheet.pdf. (Accessed 30 January 2018).
- Olzewska, E., Wagner, M., Bernal-Sprekelsen, M., Ebmeyer, J., Dazert, S., Hildmann, H., Sudhoff, H., 2004. Etiopathogenesis of cholesteatoma. *Eur. Arch. Oto-Rhino-Laryngol.* 261 (1), 6–24. <https://doi.org/10.1007/s00405-003-0623-x>.
- Osborn, A.J., Papsin, B.C., James, A.L., 2012. Clinical indications for canal wall-down mastoidectomy in a pediatric population. *Otolaryngol. Head Neck Surg.* 147 (2), 316–322. <https://doi.org/10.1177/0194599812445539>.
- Persaud, R., Hajioff, D., Trinidad, A., Khemani, S., Bhattacharyya, M.N., Papadimitriou, N., Bhattacharyya, A.K., 2007. Evidence-based review of aetiological theories of congenital and acquired cholesteatoma. *J. Laryngol. Otol.* 121 (11), 1013–1019. <https://doi.org/10.1017/S0022215107000503>.
- Potsic, W.P., Korman, S.B., Samadi, D.S., Wetmore, R.F., 2002a. Congenital cholesteatoma: 20 years' experience at the children's hospital of Philadelphia. *Otolaryngol. Head Neck Surg.* 126 (4), 409–414. <https://doi.org/10.1067/mhn.2002.123446>.
- Potsic, W.P., Samadi, D.S., Marsh, R.R., Wetmore, R.F., 2002b. A staging system for congenital cholesteatoma. *Arch. Otolaryngol. Head Neck Surg.* 128 (9), 1009–1012.
- Preciado, D.A., 2012. Biology of cholesteatoma: special considerations in pediatric patients. *Int. J. Pediatr. Otorhinolaryngol.* 76 (3), 319–321. <https://doi.org/10.1016/j.ijporl.2011.12.014>.
- Russell, J.S., Cox, M.D., Anderson, S.R., Dornhoffer, J.L., 2015. Pediatric cartilage tympanoplasty with primary intubation. *Otol. Neurotol.* 36 (3), 453–456. <https://doi.org/10.1097/MAO.0000000000000694>.
- Saad, H., Aladawy, M., 2013. Temperature management in cardiac surgery. *Glob Cardiol Sci Pract* 2013 (1), 44–62. <https://doi.org/10.5339/gcsp.2013.7>.
- Shirazi, M.A., Muzaffar, K., Leonetti, J.P., Marzo, S., 2006. Surgical treatment of pediatric cholesteatomas. *Laryngoscope* 116 (9), 1603–1607. <https://doi.org/10.1097/01.mlg.0000233248.03276.9b>.
- Spiggle and Theis Medizintechnik GmbH, 2018. Otolaryngology. <http://www.spiggle-theis.com/en/products/otology>. (Accessed 28 January 2018).
- Tarabichi, M., Kapadia, M., 2017. Transcanal Endoscopic Management of Acquired Cholesteatoma. Operative Techniques in Otolaryngology-head and Neck Surgery. <https://doi.org/10.1016/j.otot.2017.01.005>.
- Tos, M., 1983. Treatment of cholesteatoma in children. A long-term study of results. *Am. J. Otol.* 4 (3), 189–197.
- Tos, M., 1988. Incidence, etiology and pathogenesis of cholesteatoma in children. *Adv. Oto-Rhino-Laryngol.* 40, 110–117.
- United States Environmental Protection Agency, 2018. Radiation Sources and Doses. <https://www.epa.gov/radiation/radiation-sources-and-doses>. (Accessed 12 January 2018).
- Wormald, P.J., van Renen, G., Perks, J., Jones, J.A., Langton-Hewer, C.D., 2005. The effect of the total intravenous anesthesia compared with inhalational anesthesia on the surgical field during endoscopic sinus surgery. *Am. J. Rhinol.* 19 (5), 514–520.
- Yau, A.Y., Mahboubi, H., Madudoc, M., Ghavami, Y., Djalilian, H.R., 2015. Curved adjustable fiberoptic laser for endoscopic cholesteatoma surgery. *Otol. Neurotol.* 36 (1), 61–64. <https://doi.org/10.1097/MAO.0000000000000527>.