

Retrospective Study

Oncology and reproductive outcomes over 16 years of malignant ovarian germ cell tumors treated by fertility sparing surgery

Muangloei Rungoutok, Prapaporn Suprasert

Specialty type: Obstetrics and gynecology**Provenance and peer review:** Unsolicited article; Externally peer reviewed.**Peer-review model:** Single blind**Peer-review report's scientific quality classification**Grade A (Excellent): 0
Grade B (Very good): B
Grade C (Good): C
Grade D (Fair): 0
Grade E (Poor): 0**P-Reviewer:** Jian X, China; Yang YZ, China**Received:** July 7, 2022**Peer-review started:** July 7, 2022**First decision:** August 22, 2022**Revised:** August 26, 2022**Accepted:** September 9, 2022**Article in press:** September 9, 2022**Published online:** October 24, 2022**Muangloei Rungoutok, Prapaporn Suprasert**, Department of Obstetrics and Gynecology, Chiang Mai University, Muang 50200, Chiang Mai, Thailand**Corresponding author:** Prapaporn Suprasert, MD, Associate Professor, Department of Obstetrics and Gynecology, Chiang Mai University, 110 Inthawarorod Road, Muang 50200, Chiang Mai, Thailand. psuprase@gmail.com

Abstract

BACKGROUND

Malignant ovarian germ cell tumors (MOGCT) are rare and frequently occur in women of young and reproductive age and the oncologic and reproductive outcomes after fertility-sparing surgery (FSS) for this disease are still limited.

AIM

To evaluate the oncology and reproductive outcomes of MOGCT patients who underwent FSS.

METHODS

All MOGCT patients who underwent FSS defined as the operation with a preserved uterus and at least one side of the ovary at our institute between January 2005 and December 2020 were retrospectively reviewed.

RESULTS

Sixty-two patients were recruited for this study. The median age was 22 years old and over 77% were nulliparous. The three most common histology findings were immature teratoma (32.2%), dysgerminoma (24.2%), and yolk sac tumor (24.2%). The distribution of stage was as follows; Stage I, 74.8%; stage II, 9.7%; stage III, 11.3%; and stage IV, 4.8%. Forty-three (67.7%) patients received adjuvant chemotherapy. With a median follow-up time of 96.3 mo, the 10-year progression-free survival and overall survival were 82.4% and 91%, respectively. For reproductive outcomes, of 43 patients who received adjuvant chemotherapy, 18 (41.9%) had normal menstruation, and 17 (39.5%) resumed menstruation with a median time of 4 mo. Of about 14 patients who desired to conceive, four were pregnant and delivered good outcomes. Only one case was aborted. Therefore, the successful pregnancy rate was 28.6%

CONCLUSION

The oncology and reproductive outcomes of MOGCT treated by FSS are excellent.

Many patients show a long survival time with normal menstruation. However, the obstetric outcome is not quite satisfactory.

Key Words: Malignant ovarian germ cell tumor; Fertility-sparing surgery; Oncology outcome; Reproductive outcome; Pregnancy rate; Survival rate

©The Author(s) 2022. Published by Baishideng Publishing Group Inc. All rights reserved.

Core Tip: The oncology and reproductive outcomes of malignant ovarian germ cell tumors treated by fertility-sparing surgery were satisfying. Even though most patients developed normal menstruation, nearly 1/3 were successfully pregnant and delivered.

Citation: Rungoutok M, Suprasert P. Oncology and reproductive outcomes over 16 years of malignant ovarian germ cell tumors treated by fertility sparing surgery. *World J Clin Oncol* 2022; 13(10): 802-812

URL: <https://www.wjgnet.com/2218-4333/full/v13/i10/802.htm>

DOI: <https://dx.doi.org/10.5306/wjco.v13.i10.802>

INTRODUCTION

Malignant ovarian germ cell tumors (MOGCT) account for about 5% of all ovarian cancer cases and approximately 70% develop in young women[1]. With the introduction of chemotherapy consisting of bleomycin, etoposide, and cisplatin (BEP) for MOGCT treatment after surgery, the outcome of this malignancy is excellent even in the advanced stage[2]. The cure rate of MOGCT in the early stage and the advanced stage was 100% and 75%, respectively[3]. Therefore, in patients who were of young and reproductive age, the role of fertility-sparing surgery (FSS) defined as cytoreductive surgery with preservation of the contralateral adnexa and uterus is the standard treatment for these patients[4]. We previously reported a 10-year overall survival (OS) rate as high as 86.2% but did not focus on the patients who underwent FSS[5]. Therefore, with the limited data on oncology and reproductive outcomes of FSS especially in Southeast Asia, this study was conducted to identify these outcomes of MOGCT patients who were treated by FSS.

MATERIALS AND METHODS

Study population

After the protocol was approved by the local ethics committees, the medical records of the MOGCT patients who underwent FSS defined as surgical cytoreduction with preservation of the uterus and unilateral adnexa at Chiang Mai University Hospital from January 2005 through December 2020 were reviewed. The patients who developed other histologic types arising in germ cell tumors were excluded. The basic clinical data, histology, staging, type of surgery, chemotherapy regimen, and outcomes were identified. All pathology specimens were examined by gynecologic pathologists in our institute. The decision of treatment depended on the preference of the physicians.

Oncology outcome

After complete treatment, the surveillance schedule was set every 3 mo in the first year, every 4 mo in the second year, every 6 mo in the third to fifth year, and annually thereafter. At that time, all of the patients were examined for a blood test for MOGCT and were examined by gynecologic oncologists. Pelvic ultrasonography was done at each visit for unmarried patients. Other imaging modalities such as CT were utilized when clinically indicated or with a rising of tumor markers.

Progression-free survival (PFS) was defined as the time between the month of the primary surgery and the month of tumor progression or recurrence detection or last contact, whereas OS was defined as the similar starting time of PFS to the month of patient death or last contact. The death data was also sought from the Thai Civil registration system *via* the National identification card number. Both PFS and OS were estimated by the Kaplan-Meier method using the SPSS for Windows program (Version 22; IBM Corporation, Armonk, New York, United States). Descriptive data of all studied patients are presented as the mean with range and discrete data are reported as numbers and percentages.

Reproductive outcome

The reproductive outcome after FSS was identified by collecting the data on the menstrual status during and after treatment, the number of pregnancies and childbirth before and after treatment, the present marital status, the childbearing desire, the method of pregnancy, gestational age at delivery, birth weight of the baby, and obstetrical complications from the medical records and direct contact with the patients by phone for more information.

RESULTS

Among 98 MOGCT, 62 patients underwent FSS in the studied period. The clinical data are presented in [Table 1](#). The median age of these patients was 22 with a range of 4-34 years old. Over 77% of them were nulliparous and the three most common presentations were pelvic mass, abdominal pain, and abdominal distension. Approximately 54.8% of the tumors were located on the right side and 41.9% on the left side.

The details of FSS are as follows: Unilateral salpingo-oophorectomy (SO) in 49 cases, unilateral ovarian cystectomy in four, and unilateral SO with contralateral ovarian cystectomy in the rest. A frozen section was done in 26 cases. About staging procedures, peritoneal cytology was done in 39 cases with ten cases revealing positive malignancy cells, while omentectomy was done in 44 cases and lymphadenectomy was performed in 30, with four cases each having positive results. Half of the studied patients underwent an appendectomy. Regarding the surgical outcomes, 75.8% had complete resections.

The three leading histology types were immature teratoma (32.3%), dysgerminoma (24.2%), and yolk sac tumor (24.2%). The majority of the patients were in stage I (74.2%) and about 4.8% were in stage IV. Nearly 70% of the patients were given adjuvant chemotherapy. All except one was BEP regimen. Only one case was given etoposide + methotrexate + actinomycin D + cyclophosphamide + vincristine (EMACO). This case was diagnosed with stage IV choriocarcinoma. About one-third of the patients received four to six cycles of chemotherapy. Concerning the long-term side effects of chemotherapy, numbness occurred in three cases, lung fibrosis occurred in two, and hearing problems in two. Five patients died; two died from neutropenic sepsis and the rest from the progression of the disease.

Oncology outcome

With a median follow-up time of 96.3 mo, the 10-year PFS and OS were 82.4% and 91% as shown in [Figures 1 and 2](#), respectively. However, 62.9% did not continue regular follow-ups.

Four cases developed progression after primary FSS. The details of these patients are summarized in [Table 2](#). One of them lived while the others died from the disease progression during treatment. The surviving case was a 17-year-old with stage IC1 grade 2 immature teratoma. The primary surgery was right SO and appendectomy with pelvic recurrence developing 1 mo after the operation. She underwent tumor debulking and received six cycles of the BEP regimen. She is still alive without disease with an overall survival of 109 mo. The other three cases had stage IV disease. The histology was yolk sac tumor in two cases with choriocarcinoma in the remainder. All of them underwent FSS and received multiple chemotherapy regimens with unfavorable outcomes and died of disease after primary surgery at 16, 28, and 30 mo. One case developed lung fibrosis after being administered two cycles of the BEP regimen.

Regarding four patients who underwent only a cystectomy, the pathology was immature teratoma in two cases (stage IA grade 2 and stage IC grade 1), papillary thyroid cancer arising from mature teratoma (1), and carcinoid tumor (1). Only one case of stage IA grade 2 immature teratoma received four cycles of BEP regimen while the other received only an operation. All of them are still alive at present with an overall survival of 44-173 mo.

Reproductive outcome

Of 62 patients, 43 received adjuvant chemotherapy with BEP in 41 cases and EMACO in the rest. The menstrual history of these patients is summarized in [Table 3](#). Forty-two percent of the patients had menstruation while receiving chemotherapy, while 39.5% resumed menstruation after complete treatment with a median resumption time of 4 mo. One case was five years old at the treatment time with menarche at age 12 (seven years later).

Eight patients were without menstruation after chemotherapy. The one case without menarche at presentation was 12 years old. She was diagnosed with stage I mixed MOGCT and received six cycles of BEP regimen after undergoing right SO at 5 years of age. She was followed regularly with no evidence of recurrence. The remaining seven patients developed premature menopause. One case was diagnosed as having a stage IIA endodermal sinus tumor at 29 years old. She received six cycles of BEP regimen after undergoing right SO and omentectomy on January 1, 2017. One year after that, she developed a left ovarian tumor measuring 10 cm × 15 cm and received a hysterectomy with left SO. The final pathology revealed grade 1 endometrioid CA. The patient was given six cycles of carboplatin with a disease-free survival of 61 mo and received estradiol valerate 2 mg as hormonal therapy. The other two patients underwent FSS and received three and six cycles of BEP, respectively. Both cases did not resume menstruation after completing treatment. One case received hormonal therapy. However, both cases

Table 1 Clinical data (n = 62)

	n (%)
Median age (range; yr)	22.0 (4-34)
Parity before surgery	
0	48 (77.4)
1	8 (12.9)
2	6 (9.7)
Presentation	
Pelvic mass	24 (38.7)
Abdominal pain	18 (29.0)
Abdominal distension	15 (24.2)
Others ¹	5 (8.1)
Tumor side	
Right	34 (54.8)
Left	26 (41.9)
Bilateral	2 (3.2)
Detail of FSS	
Unilateral SO	49 (79.0)
Unilateral cystectomy	4 (6.5)
Unilateral SO & cystectomy	9 (14.5)
Frozen section	26 (41.9)
Cytology	
Not done	23 (37.1)
Negative	29 (46.8)
Positive	10 (16.1)
Omentectomy	
Not done	18 (29.0)
Negative	40 (64.5)
positive	4 (6.5)
Lymphadenectomy	
Not done	32 (51.6)
Negative	26 (41.9)
Positive	4 (6.5)
Appendectomy	32 (51.6)
Surgical outcome	
No residual	47 (75.8)
Optimal	5 (8.1)
Suboptimal (residual tumor > 1 cm)	10 (16.1)
Histology	
Dysgerminoma	17 (27.4)
Immature teratoma	20 (32.3)
Yolk sac tumor	15 (24.2)
Mixed type	5 (8.1)

Others ²	5 (8.1)
Stage	
I	46 (74.2)
II	6 (9.7)
III	7 (11.3)
IV	3 (4.8)
Adjuvant chemotherapy	
None	19 (30.6)
BEP	42 (67.7)
EMACO	1 (1.6)
Cycles of chemotherapy	
1-3	6
4-6	33
> 6	4
Long-term side effect	
None	46 (74.2)
Numbness	3 (4.8)
Lung fibrosis	2 (3.2)
High-frequency hearing loss	1 (1.6)
Tinnitus	1 (1.6)
Progression of disease	4 (9.5)
Death	5 (8.1)
Alive	55 (88.7)
Missing data	2 (3.2)

¹Others: Amenorrhea (2), anti-NMDAR (N-methyl D-aspartate receptors) encephalitis (1), incidental finding during cesarean section (1), and hyperthyroidism (1).

²Others: Struma ovarii (1), carcinoid (1), chorioCA (1), steroid cell tumor (1), and papillary thyroid CA arising in teratoma (1).

Death: SN 43, 52, 74, 108, and 110. SO: Salpingo-oophorectomy; BEP: Bleomycin etoposide cisplatin; EMACO: Etoposide methotrexate actinomycin D cyclophosphamide vincristine.

were followed for only 1 year after FSS. Four cases died, two from neutropenic sepsis, and two from disease progression after multiple chemotherapy regimens. The details of these patients are summarized in [Table 4](#).

Regarding 19 patients who underwent only FSS without adjuvant chemotherapy, one was lost to follow-up since surgery while the remaining 18 had no problem with menstruation. One case was diagnosed with stage I immature teratoma and received left SO with omentectomy and appendectomy at 4 years old. At 15 years old, her menarche occurred.

For pregnancy outcomes, the data was available in 30 patients and revealed that 14 cases attempted to become pregnant and four of them (28.6%) succeeded in delivering a term baby after 1 year for two cases and 6 years for one case. One patient was known to give one term birth due to unavailable contact details. Three cases underwent unilateral SO and the rest received a unilateral ovarian cystectomy. The histology of these four cases was grade 1 carcinoid tumor neuroendocrine tumor (1), dysgerminoma (2), and grade 1 immature teratoma (1). Moreover, one case developed a spontaneous abortion 2 years after treatment and was never pregnant again. She was diagnosed with a steroid cell tumor. None of the patients who attempted to conceive actively tried to become pregnant by going to an infertility clinic. The details of these patients are shown in [Table 5](#).

Table 2 Progression cases (*n* = 4)

SN	Year	Age	Stage	Histology	Chemotherapy	Cycle	Site	Primary surgery	Note
50	2013	17	IC1	Immature teratoma grade 2	None	-	Right	Right SO and appendectomy	PFS 3 mos → pelvic recurrence → debulking tumor and BEP × 6 cycles → alive without disease DFS 103 mos, overall survival 109 mo
52	2013	15	IV	Yolk sac tumor	BEP	8	Right	Right SO and left cystectomy and omentectomy	Progression after BEP × 8: Liver & lung metastasis → TIP × 2 → PT × 1 → ifosfamide × 1 → progression → death (overall survival 16 mo)
74	2010	18	IV	Choriocarcinoma	EMACO	6	Left	Left SO and omentectomy and appendectomy and PAN sampling	EMACO × 6 → progression (PFS 7 mos) → cisplatin and ifosfamide × 5 → paclitaxel × 1 → Act D and 5 FU × 1 → VAC × 1 → TAH and right SO (19/4/2011) → EMA/EP × 9 → TP/TE × 1 → BEP × 2 → palliative treatment → death 5/7/2012 overall survival 28 mo
110	2005	16	IV	Yolk sac tumor	BEP × 2 → EP × 11	12	Right	Right SO and appendectomy	Progression after EP × 11 → ifosfamide × 1 → EMA × 1 → single paclitaxel × 1 → palliative RT 25/1/2006 → VAC × 1 → Death 4/7/2007, OS 30 mo (lung fibrosis after BEP × 2)

PFS: Progression-free survival; DFS: Disease-free survival; SO: Salpingo-oophorectomy; PAN: Para-aortic lymph node; BEP: Bleomycin etoposide cisplatin; EMACO: Etoposide methotrexate actinomycin D cyclophosphamide vincristine; TIP: Paclitaxel ifosfamide cisplatin; PT: Paclitaxel carboplatin; Act D; actinomycin d; EMA/EP: Etoposide methotrexate actinomycin D etoposide cisplatin; 5FU: Fluorouracil; VAC: Vincristine dactinomycin and cyclophosphamide; TP/TE: Paclitaxel cisplatin/paclitaxel etoposide; TAH: Total abdominal hysterectomy; EP: Etoposide cisplatin, palliative; RT: Radiotherapy.

Table 3 Menstrual data of studied patients who received chemotherapy (*n* = 43)

	<i>n</i> (%)
No menstruation after treatment	8 (18.6)
No menarche ¹	1
Premature menopause	7
Resume menstruation ²	17 (39.5)
1 mo	2
2 mo	2
3 mo	2
4 mo	3
5 mo	1
6 mo	6
Median 4 mo (1-6)	
Menstruation during and post-treatment	18 (41.9)

¹SN 4, no menarche at age 12 years old.

²SN 64, menarche at age 12.

DISCUSSION

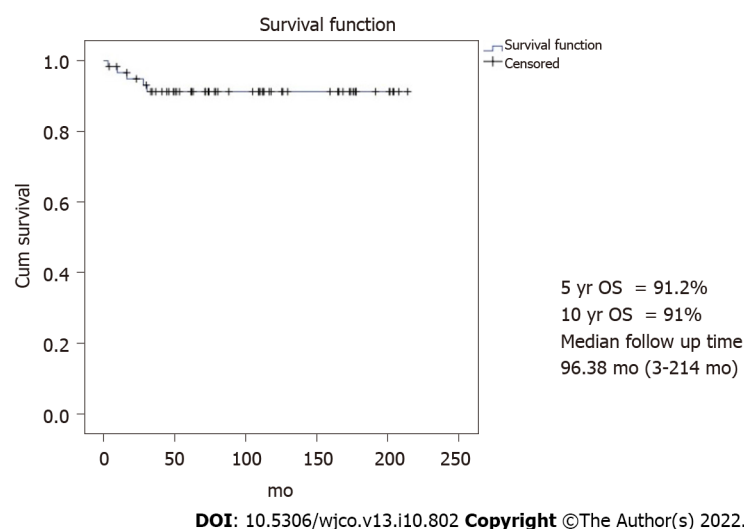
Oncology outcome

The outcome of 62 MOGOT patients who were treated by FSS in the present study was excellent with the 10-year PFS and OS being 82.4% and 91%, respectively. These results were close to the previous reports. Zamani *et al*[6] studied 79 MOGCT over 15 years and showed the 10-year OS as 94.4%. This study recruited only stages I-III while our study recruited all stages including three progressed cases of

Table 4 Details of premature menopausal patients (n = 7)

SN	Year	Age	Stage	Histology	Chemotherapy	Cycle	Site	Primary surgery	Note
25	2017	29	IIA	Yolk sac tumor	BEP	6	Right	Right SO and omentectomy January 6, 2017	16/1/18 abdominal pain and pelvic mass size 10 cm × 15 cm, solid and cystic, movable AFP 2.2 → TAH and left SO 19/1/18 → endometrioid CA IA → carboplatin × 6 → complete response → DFS 61 mo, HRT
43	2014	16	III	Dysgerminoma	BEP	4	Bilateral	Left SO and omentectomy	Partial response during BEP, overall survival of 3 mo, death from sepsis (neutropenia)
52	2013	15	IV	Yolk sac tumor	BEP	8	Right	Right salpingo-oophorectomy with left ovarian cystectomy	PFS 15 mo → TIP × 2 cycles → PT × 1 → ifosfamide × 1 cycle → death OS 16 mo
87	2008	28	I	Dysgerminoma	BEP	3	Left	Left SO	HRT icycloprogynova lost to follow up since 2009, unknown status
108	2005	15	III	Yolk sac tumor	BEP	6	Right	Right SO	Febrile neutropenia → sepsis → death 2005 OS 9 mo
110	2005	16	IV	Yolk sac tumor	BEP × 2 → EP × 11	12	Right		Progression after EP × 11 → ifosfamide × 1 → EMA × 1 → single paclitaxel × 1 → palliative RT January 25, 2006 → VAC × 1 → Death July 4, 2007, OS 30 mo (lung fibrosis after BEP × 2)
114	2005	23	II	Dysgerminoma	BEP	6	Right	Right SO	Alive, loss after 12 mo since start treatment, no HRT

BEP: Bleomycin etoposide cisplatin; SO: Salpingo-oophorectomy; TAH: Total abdominal hysterectomy; AFP: Alpha-fetoprotein; DFS: Disease free survival; HRT: Hormonal replacement therapy; PFS: Progression free survival; TIP: Paclitaxel ifosfamide cisplatin; PT: Paclitaxel carboplatin; OS: Overall survival; EP: Etoposide cisplatin; EMA: Etoposide methotrexate + actinomycin D; palliative RT: Radiotherapy.

**Figure 1 Overall Survival.** 5-year overall survival (OS) = 91.2%, 10-year OS = 91%, and median follow-up time = 96.38 mo (3-214 mo). OS: Overall survival.

stage IV. Another study from Korea[1] studied 171 MOGCT patients who underwent FSS for 23 years (1992-2015). They reported the 5-year PFS and OS as 86% and 97%, respectively. About 14.6% developed recurrent disease and the death rate of disease was 2.9%. This recurrence rate was higher than our study which showed the progression of the disease at only 1.6%. However, due to over 2/3 of our patients without regular follow-up, the actual number of recurrence patients might be missed. However, the death rate of this disease in our study was 4.8%, which is near the Korean report. In addition, Beiner *et al* [7] reviewed eight retrospective studies comparing FSS with the conventional operation for MOGCT patients and found that both types of surgery were not significant for recurrence.

Regarding ovarian cystectomy in MOGCT, although this operation was not the standard of FSS, Tamauchi *et al*[8] showed an excellent outcome in eight patients who were diagnosed with early-stage

Table 5 Pregnancy outcomes

SN	Year	Age Dx	Age Preg	Stage	Histology	Site	Chemotherapy	Cycle	Parity	Primary surgery	Pregnancy outcome
19	2018	30	31	IA	Carcinoid tumor neuroendocrine tumor grade 1 arising in mature cystic teratoma	Left	None	-	1001	Laparoscopic left ovarian cystectomy June 1, 2018	1 Term pregnancy, GA 39 wk, NL August 1, 2019, BW 3030 gm
53	2013	21	27	IC	Dysgerminoma	Right	BEP	4	-	Right SO and omentectomy and appendectomy June 15, 2013	1 Term pregnancy, C/S GA 38 wk April 23, 2019, BW 2780 gm, omphalocele 9 cm × 8 cm, and atrial septal defect → surgical correction
84	2008	19	21	IA	Steroid cell tumor	Right	None	-	-	Right SO and omentectomy and PNS and PAS December 18, 2008	1 spontaneous abortion 31/1/2010
92	2005	34	35	IA	Immature teratoma grade ¹	Left	None	-	1001	Left SO	1 Term pregnancy, GA 38 wk, NL 10/12/2006, BW 2700 gm
94	2007	24	26	IA	Dysgerminoma	Left	None	-	1001	Left SO and omentectomy October 9, 2007	1 Term pregnancy with no available data of birth date, GA, and BW

¹Parity before primary surgery.

NB: 14 of 30 patients who could be contacted for this information revealed an attempt to conceive. GA: Gestational age; BW: Birth weight; BEP: Bleomycin etoposide cisplatin; SO: Salpingo-oophorectomy; C/S: Cesarean section; PNS: Pelvic lymph node sampling; PAS: Para-aortic lymph node sampling.

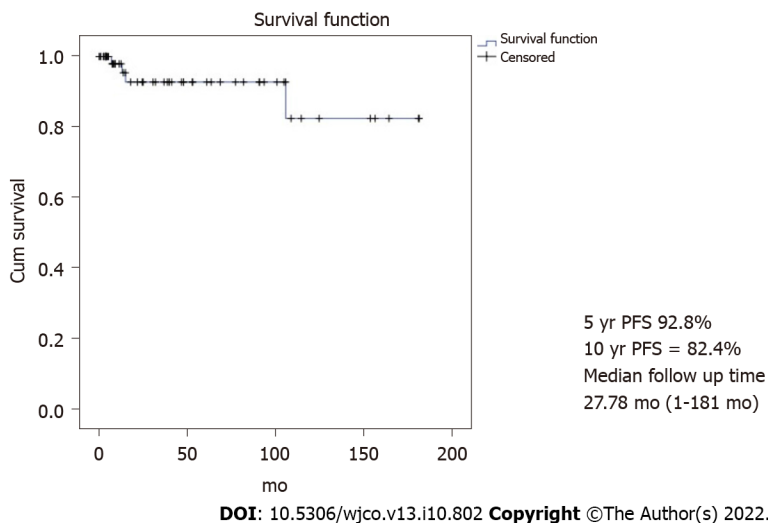


Figure 2 Progression free survival. 5-year progression free survival (PFS) = 92.8%, 10-year PFS = 82.4%, and median follow-up time = 27.78 mo (1-181 mo). PFS: Progression-free survival.

immature teratoma treated by ovarian cystectomy. Five patients received chemotherapy. With a median follow-up time of 4.7 years, all patients were still free of disease. The authors suggested that cystectomy followed by adjuvant chemotherapy showed impressive outcomes for early-stage MOGCT, especially in immature teratoma. For our study, four cases underwent ovarian cystectomy with one case of stage IA grade 2 immature teratoma and received adjuvant chemotherapy. All of them were still alive at a duration time of 44-173 mo after surgery.

Reproductive outcome

The 70.8% of patients who had no menstruation during treatment by FSS and chemotherapy in this study resumed menstruation with a median time of 4 mo. The true premature ovarian failure from chemotherapy occurred in only two (3.2%) cases. Both underwent unilateral SO with three and six cycles of the BEP regimen. Turkmen *et al*[9] used the Tokai Ovarian Tumor Study Group database on ovarian cancer patients and selected 110 MOGCT patients who received FSS with a median follow-up

period of 10.4 years for the study. In this Japanese report, 63.9% of the patients received the BEP regimen and about 30.6% received the cisplatin + vincristine + bleomycin regimen. They revealed premature menopause which was close to our study of 2.9%.

Regarding the obstetric outcome, our study reported that the rate of term pregnancy was 28.6%. This result was different from that of a Japanese study[9]. The authors revealed that 45 patients attempted to become pregnant with 40 patients succeeding in deliveries with total pregnancies as term deliveries in 54 (83.1%) cases, preterm delivery in two (3.2%), and abortion in 12 (18.5%). Seven cases received fertility treatment. A publication from Iran reported that 19 of 26 (73%) MOGCT patients who underwent FSS were successful in delivery without infertility treatment[6]. In addition, Mikuš *et al*[10] reported that the pregnancy rate in 20 German patients with MOGCT who desired to become pregnant of their series was 50%. The pregnancy rate from previous studies was higher than that of our study, which showed the successful pregnancy rate was only 28.6%. The difference might be from the current trend of Thai culture to have fewer children, the missing data from the patients unable to be contacted, and those non-actively who tried to conceive in our patients.

The strength of our study was the real-world series of patients with MOGCT treated by FSS in a single institute to show the oncology and reproductive outcomes. However, with the limitation of the retrospective study, about 2/3 of the patients were not followed for a long time. Therefore, some data were missed.

CONCLUSION

In conclusion, the oncology and reproductive outcomes of MOGCT treated by FSS were good. Many patients showed a long survival time with normal menstruation. However, the obstetric outcome in patients who attempted to conceive was not quite as high.

ARTICLE HIGHLIGHTS

Research background

Malignant ovarian germ cell tumors (MOGCT) are rare and frequently occur in women of young and reproductive age. Fertility-sparing surgery (FSS) is the main treatment for these patients. However, oncologic and reproductive outcomes after FSS for this disease are still limited.

Research motivation

Due to the limited data on oncology and reproductive outcomes of FSS especially in Southeast Asia, this study was conducted to identify these outcomes of MOGCT patients who were treated by FSS.

Research objectives

To evaluate the oncology and reproductive outcomes of MOGCT who underwent FSS.

Research methods

All MOGCT patients who underwent FSS defined as the operation with a preserved uterus and at least one side of the ovary at our institute between January 2005 and December 2020 were retrospectively reviewed.

Research results

Sixty-two patients were reviewed in this study. The median age was 22 years old and over 77% were nulliparous. The three most common histology findings were immature teratoma (32.2%), dysgerminoma (24.2%), and yolk sac tumor (24.2%). The distribution of stage was as follows: Stage I, 74.8%; stage II, 9.7%; stage III, 11.3%; stage IV, 4.8%. About 2/3 of the patients received adjuvant chemotherapy. With a median follow-up time of 96.3 mo, the 10-year progression-free survival and overall survival were 82.4% and 91%, respectively. For reproductive outcomes, of 43 patients who received adjuvant chemotherapy, 18 (41.9%) had normal menstruation and 17 (39.5%) resumed menstruation with a median time of 4 mo. Of about 14 patients who desired to conceive, four were pregnant and delivered good outcomes. Only one case was aborted. Therefore, the successful pregnancy rate was 28.6%.

Research conclusions

The oncology and reproductive outcomes of MOGCT treated by FSS were excellent. Many patients showed a long survival time with normal menstruation. However, the obstetric outcome was not quite high.

Research perspectives

The strength of our study was the real-world series of patients with MOGCT treated by FSS in a single institute to show the oncology and reproductive outcomes. However, with the limitation of the retrospective study, about 2/3 of the patients were not followed for a long time. Therefore, some data were missed. A good plan follow-up is needed in the future.

FOOTNOTES

Author contributions: Rungoutok M and Suprasert P contributed equally to this work; Suprasert P designed the research study; Rungoutok M and Suprasert P performed the research and contributed analytic tools; Suprasert P analyzed the data and wrote the manuscript; all authors have read and approved the final manuscript.

Institutional review board statement: The study was approved by Chiang Mai University Ethic Committees (Research ID: 7736; Study Code: OBG-2563-07736).

Informed consent statement: Patients were not required to give informed consent for the study because the analysis used anonymous clinical data that were obtained after each patient agreed to treatment by written consent.

Conflict-of-interest statement: All authors declare no potential conflict of interest for the article.

Data sharing statement: Technical appendix, statistical code, and dataset available from the corresponding author at psuprase@gmail.com. Participants consent was not obtained but the presented data are anonymized and risk of identification is low.

Open-Access: This article is an open-access article that was selected by an in-house editor and fully peer-reviewed by external reviewers. It is distributed in accordance with the Creative Commons Attribution NonCommercial (CC BY-NC 4.0) license, which permits others to distribute, remix, adapt, build upon this work non-commercially, and license their derivative works on different terms, provided the original work is properly cited and the use is non-commercial. See: <https://creativecommons.org/licenses/by-nc/4.0/>

Country/Territory of origin: Thailand

ORCID number: Muangloei Rungoutok 0000-0002-1124-0662; Prapaporn Suprasert 0000-0002-0205-2280.

S-Editor: Liu JH

L-Editor: Wang TQ

P-Editor: Liu JH

REFERENCES

- 1 **Park JY**, Kim DY, Suh DS, Kim JH, Kim YM, Kim YT, Nam JH. Analysis of outcomes and prognostic factors after fertility-sparing surgery in malignant ovarian germ cell tumors. *Gynecol Oncol* 2017; **145**: 513-518 [PMID: 28372870 DOI: 10.1016/j.ygyno.2017.03.023]
- 2 **Williams S**, Blessing JA, Liao SY, Ball H, Hanjani P. Adjuvant therapy of ovarian germ cell tumors with cisplatin, etoposide, and bleomycin: a trial of the Gynecologic Oncology Group. *J Clin Oncol* 1994; **12**: 701-706 [PMID: 7512129 DOI: 10.1200/JCO.1994.12.4.701]
- 3 **Di Tucci C**, Casorelli A, Morrocchi E, Palaia I, Muzii L, Panici PB. Fertility management for malignant ovarian germ cell tumors patients. *Crit Rev Oncol Hematol* 2017; **120**: 34-42 [PMID: 29198336 DOI: 10.1016/j.critrevonc.2017.10.005]
- 4 **Brown J**, Friedlander M, Backes FJ, Harter P, O'Connor DM, de la Motte Rouge T, Lorusso D, Maenpaa J, Kim JW, Tenney ME, Seckl MJ. Gynecologic Cancer Intergroup (GCIg) consensus review for ovarian germ cell tumors. *Int J Gynecol Cancer* 2014; **24**: S48-S54 [PMID: 25341580 DOI: 10.1097/IGC.0000000000000223]
- 5 **Neeyalavira V**, Suprasert P. Outcomes of malignant ovarian germ-cell tumors treated in Chiang Mai University Hospital over a nine year period. *Asian Pac J Cancer Prev* 2014; **15**: 4909-4913 [PMID: 24998562 DOI: 10.7314/apjcp.2014.15.12.4909]
- 6 **Zamani N**, Rezaei Poor M, Ghasemian Dizajmehr S, Alizadeh S, Modares Gilani M. Fertility sparing surgery in malignant ovarian Germ cell tumor (MOGCT): 15 years experiences. *BMC Womens Health* 2021; **21**: 282 [PMID: 34348686 DOI: 10.1186/s12905-021-01437-8]
- 7 **Beiner ME**, Gotlieb WH, Korach Y, Shrim A, Stockheim D, Segal Y, Fridman E, Ben-Baruch G. Cystectomy for immature teratoma of the ovary. *Gynecol Oncol* 2004; **93**: 381-384 [PMID: 15099949 DOI: 10.1016/j.jmig.2020.08.018]
- 8 **Tamauchi S**, Kajiyama H, Yoshihara M, Ikeda Y, Yoshikawa N, Nishino K, Utsumi F, Niimi K, Suzuki S, Kikkawa F. Reproductive outcomes of 105 malignant ovarian germ cell tumor survivors: a multicenter study. *Am J Obstet Gynecol* 2018; **219**: 385.e1-385.e7 [PMID: 30086295 DOI: 10.1016/j.ajog.2018.07.021]
- 9 **Turkmen O**, Karalok A, Basaran D, Kimyon GC, Tasci T, Ureyen I, Tulunay G, Turan T. Fertility-Sparing Surgery Should Be the Standard Treatment in Patients with Malignant Ovarian Germ Cell Tumors. *J Adolesc Young Adult Oncol* 2017; **6**:

270-276 [PMID: [28085535](#) DOI: [10.1089/jayao.2016.0086](#)]

- 10 **Mikuš M**, Benco N, Matak L, Planinić P, Ćorić M, Lovrić H, Radošević V, Puževski T, Bajt M, Vujić G. Fertility-sparing surgery for patients with malignant ovarian germ cell tumors: 10 years of clinical experience from a tertiary referral center. *Arch Gynecol Obstet* 2020; **301**: 1227-1233 [PMID: [32253553](#) DOI: [10.1007/s00404-020-05522-5](#)]



Published by **Baishideng Publishing Group Inc**
7041 Koll Center Parkway, Suite 160, Pleasanton, CA 94566, USA

Telephone: +1-925-3991568

E-mail: bpgoffice@wjgnet.com

Help Desk: <https://www.f6publishing.com/helpdesk>

<https://www.wjgnet.com>

