

Case Report / Olgu Sunumu

## Multiple thrombi in a child diagnosed with coronavirus disease 2019 treated with cardiac surgery

*Koronavirüs hastalığı 2019 tanılı çocukta kardiyak cerrahi ile tedavi edilen çoklu trombus*

Aybüke Akaslan Kara<sup>1</sup>, Elif Kıymet<sup>1</sup>, Cüneyt Zihni<sup>2</sup>, Yeşim Oymak<sup>3</sup>, Mustafa Karaçelik<sup>4</sup>

<sup>1</sup>Department of Pediatric Infectious Diseases, University of Health Sciences Dr. Behçet Uz Child Disease and Pediatric Surgery Training and Research Hospital, İzmir, Türkiye

<sup>2</sup>Department of Pediatric Cardiology, University of Health Sciences Dr. Behçet Uz Child Disease and Pediatric Surgery Training and Research Hospital, İzmir, Türkiye

<sup>3</sup>Department of Pediatric Hematology-Oncology, University of Health Sciences Dr. Behçet Uz Child Disease and Pediatric Surgery Training and Research Hospital, İzmir, Türkiye

<sup>4</sup>Department of Cardiovascular surgery, University of Health Sciences Dr. Behçet Uz Child Disease and Pediatric Surgery Training and Research Hospital, İzmir, Türkiye

### ABSTRACT

Coronavirus disease 2019 (COVID-19) is characterized predominantly by respiratory symptoms but may affect all systems, and it has been associated with thrombosis in adults. Case series investigating the COVID-19-associated multisystem inflammatory syndrome in children have reported high fibrinogen and D-dimer levels; however, it is not known whether this causes thrombophilia. Herein, we report a previously healthy 13-year-old male patient who had multiple thromboses associated with COVID-19, which occurred during long-term follow-up and was successfully treated with cardiac surgery. We want to emphasize that the long-term effects of COVID-19 are not yet known and that the follow-up of these cases should be continued.

**Keywords:** COVID-19, multisystem inflammatory syndrome, thrombus.

The severe acute respiratory syndrome coronavirus 2 (SARS-CoV-2) is predominantly characterized by respiratory symptoms, while extrapulmonary manifestations are increasingly reported during the COVID-19 pandemic. Hypercoagulability, including deep vein thrombosis, pulmonary embolism, and cardiac thrombus, is thought to play a leading role in the pathogenesis of death during the follow-up

### ÖZ

Koronavirüs hastalığı 2019 (COVID-19) ağırlıklı olarak solunum semptomları ile karakterizedir ancak tüm sistemleri etkileyebilir ve yetişkinlerde tromboz ile ilişkilendirilmiştir. Çocuklarda COVID 19 ile ilişkili multisistem enflamatuvar sendromu inceleyen olgu serilerinde yüksek fibrinojen ve D-dimer seviyeleri bildirmiştir ancak bunun trombofiliye neden olup olmadığı bilinmemektedir. Bu makalede, uzun süreli takip sırasında ortaya çıkan ve kalp cerrahisi ile başarılı bir şekilde tedavi edilen COVID-19 enfeksiyonu ile ilişkili birden fazla trombusu olan daha öncesinde sağlıklı 13 yaşında bir erkek hasta bildirildi. COVID-19'un uzun dönemli etkilerinin henüz bilinmediğini ve bu olguların takibine devam edilmesi gerektiğini vurgulamak istedik.

**Anahtar sözcükler:** COVID-19, multisistem enflamatuvar sendrom, trombus.

in adults.<sup>[1]</sup> However, there are few reports of thromboembolic complications in children with SARS-CoV-2. Multisystem inflammatory syndrome in children (MIS-C) has been reported in children following infection with SARS-CoV-2.<sup>[2]</sup> Although high fibrinogen and D-dimer levels have been described in the presence of MIS-C, reports of thrombophilia in children with MIS-C are rare.

Received: June 01, 2021 Accepted: September 01, 2021 Published online: April 27, 2022

**Correspondence:** Aybüke Akaslan Kara, MD. SBÜ Dr. Behçet Uz Çocuk Hastalıkları ve Çocuk Cerrahisi Eğitim ve Araştırma Hastanesi, Çocuk Enfeksiyon Hastalıkları Kliniği, 35240 Konak, İzmir, Türkiye.  
Tel: +90 507 - 291 97 37 e-mail: aybukeakaslan@hotmail.com

### Cite this article as:

Akaslan Kara A, Kıymet E, Zihni C, Oymak Y, Karaçelik M. Multiple thrombi in a child diagnosed with coronavirus disease 2019 treated with cardiac surgery. Turk Gogus Kalp Dama 2022;30(2):277-280

©2022 All right reserved by the Turkish Society of Cardiovascular Surgery.

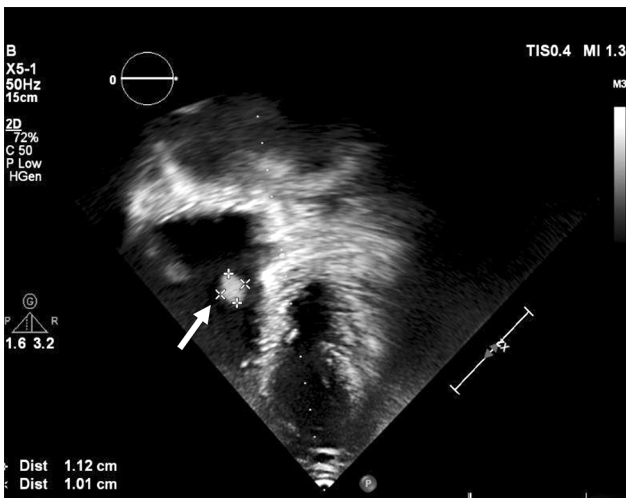
This is an open access article under the terms of the Creative Commons Attribution-NonCommercial License, which permits use, distribution and reproduction in any medium, provided the original work is properly cited and is not used for commercial purposes (<http://creativecommons.org/licenses/by-nc/4.0/>).

In this case report, a previously healthy male child with infarctions due to pulmonary embolism, a history of MIS-C, and thrombi in the tricuspid valve and the superior sagittal sinus is presented.

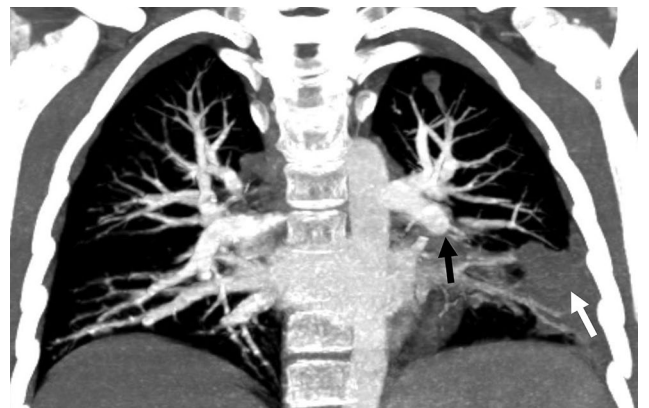
### CASE REPORT

A 13-year-old male child was admitted to our clinic due to a thrombus in the tricuspid valve detected in the echocardiography during routine cardiological examination. The patient had a history of COVID-19 infection two and a half months ago. Three weeks after first admission, the patient was diagnosed with MIS-C due to persistent high fever, tachycardia, chest pain, and elevated inflammatory markers, according to the criteria of the Centers for Disease Control and Prevention (CDC).<sup>[2]</sup> The patient had received 2 gr/kg intravenous immunoglobulin and 5 mg/kg acetylsalicylic acid (ASA) in another center, and echocardiographs that were taken during this period were not out of the ordinary. Two weeks after the end of MIS-C treatment, the patient was referred to our hospital due to intermittent fever and was evaluated as pneumonia, then was hospitalized for three weeks and received broad-spectrum antibiotherapy. Acetylsalicylic acid treatment started in another center was continued. The patient was discharged, the echocardiographs were normal, and the thorax computed tomography (CT) revealed bacterial consolidation. After 10 days, an echocardiography performed in another center revealed thrombus in the tricuspid valve, and the patient was readmitted to our hospital. The patient had no history of catheterization or family history of

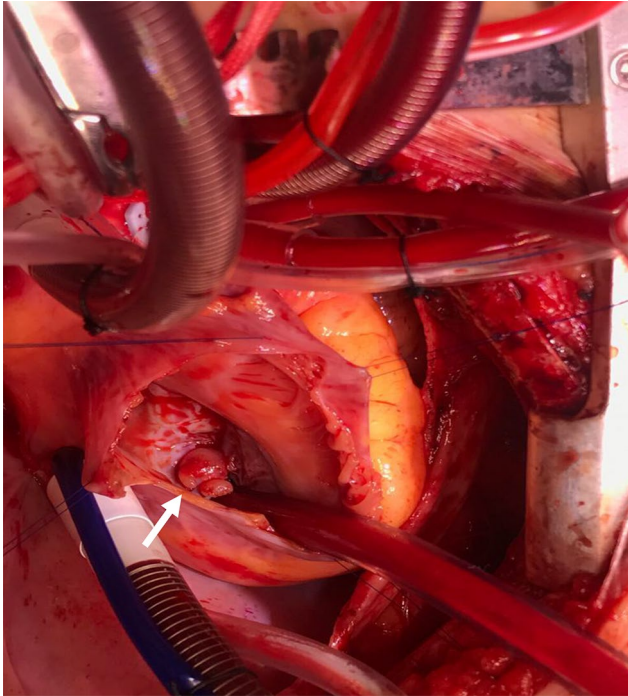
thrombosis. At admission, the physical examination of the patient without active complaints was normal, and the patient was not obese in terms of percentiles (10-25p) with a weight of 43 kg. Laboratory parameters were as follows: leukocyte count, 10,640 cells/mm<sup>3</sup>; lymphocyte count, 4,600 cells/mm<sup>3</sup>; thrombocyte count, 388,000 cells/mm<sup>3</sup>; hemoglobin, 11.1 g/dL; C-reactive protein, 0.2 mg/dL (reference: 0-0.5 mg/dL); erythrocyte sedimentation rate, 27 mm/h; D-dimer, 244 ng/mL (reference: 0-243 ng/mL); fibrinogen, 265 mg/dL (reference: 150-400 mg/dL). No irregular rhythms were observed in the electrocardiography; however, a mobile 12×13 mm hyperechogenic focus originating from the tricuspid valve in the right atrium was detected (Figure 1). Whether it was a thrombus or vegetation could not be differentiated. Blood cultures were taken, and ceftriaxone and clindamycin combination treatment due to the prediagnosis of subacute bacterial endocarditis and 2×100 U/kg low molecular weight heparin (LMWH) for the thrombus were started. Cranial magnetic resonance (MR) imaging and MR angiography were performed after bilateral papillae edema was detected in the fundus examination. The patient's neurological examination was normal, and MR angiography revealed a thrombus in the superior sagittal sinus. Thorax CT angiography revealed pleural-based consolidation in the left lower lobe's lateral and posterior segments, which were evaluated as areas of infarction due to pulmonary embolism (Figure 2). A linear thrombus was detected in the left ventricular apex in the cardiac MR imaging. The renal and portal venous Doppler ultrasonography were normal. The patient, who had multiple thromboses after MIS-C, was investigated in terms of



**Figure 1.** Transthoracic echocardiogram showing a mobile thrombus originating from the right atrium in the tricuspid valve.

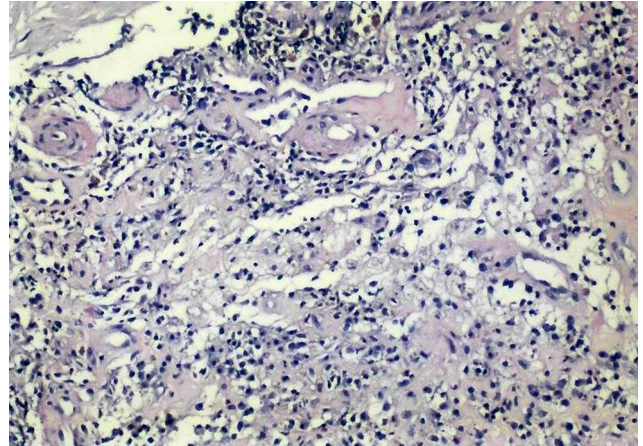


**Figure 2.** Thromboembolic occlusion is seen in descending branch of left pulmonary artery on maximum intensity projection of CT angiography (black arrow). Please note the peripheral wedge shaped lung infarction, defined as Hampton hump, in left lateral basal segment (white arrow).



**Figure 3.** Formation of a 10x8 mm thrombus on the tricuspid cover, area origin from the right atrium.

hereditary tendency to thrombus. Protein C, protein S, homocysteine, and antithrombin III levels were normal; lupus anticoagulant activity and Factor V Leiden mutation were negative. Antiphospholipid antibodies for catastrophic thrombus diagnosis due to multiple thrombi were negative. Antinuclear antibody profile sent for underlying connective tissue diseases was found to be negative, and the pathergy test was interpreted as normal. D-dimer and fibrinogen levels were evaluated, to be normal although there were multiple thrombi and treatment with LMWH (2x100 U/kg) and ASA (3 mg/kg/day). Despite three weeks of treatment, there was no significant regression in the thrombus, and surgery was decided. Following the standard aorta bicaval cannulation under general anesthesia, the cardiopulmonary bypass was started. The temperature of the patient lowered to 34°C on cardiopulmonary bypass. The cold blood cardioplegia (+4°C) was given via antegrade route twice following the aortic cross-clamping. A right atriotomy was performed, and a 10x8 mm floppy mass in the septal leaflet of the tricuspid valve was removed together with 2 mm of tricuspid valve tissue (Figure 3). The tricuspid valve was repaired by two interrupted 6-0 polypropylene sutures (Covidien, Surgipro™ II; Medtronic, Minneapolis, MN, USA). The patient went through the cardiopulmonary bypass uneventfully and



**Figure 4.** Histological analysis of mass: Capillary vessels and chronic inflammatory cell infiltration in the base of fibrinous inflammation (H&E, x100).

was extubated 2 h later. The patient was discharged from the surgical clinic on the third postoperative day. Histological analysis of the mass showed capillary vessels and chronic inflammatory cell infiltration in the base of fibrinous inflammation (Figure 4). The patient was discharged after two weeks in good condition.

## DISCUSSION

Thromboembolic events have been reported in COVID-19 infections in adults, particularly in those with associated comorbidities.<sup>[3]</sup> However, our patient had no underlying condition, previous tendency to a thromboembolic event, or cardiological abnormalities.

Case series on the MIS-C with COVID-19 have reported high D-dimer and fibrinogen levels;<sup>[5]</sup> however, little is known about the exact pathophysiology or the long-term implications of MIS-C, and it is unclear at this time what role SARS-CoV-2 may play in thrombophilia. In an analysis of a national multicenter registry of children and adolescents with MIS-C in the United States, the rate of symptomatic VTE was 7% (3/45) among patients 13 to 21 years of age and 1.3% (1/75) in children 5 to 13 years old.<sup>[4]</sup> A right atrial thrombus was detected in a 12-year-old previously healthy patient treated with extracorporeal membrane oxygenation (ECMO) after MIS-C in a pediatric intensive care unit, and in another 14-year-old intensive care patient, cranial CT demonstrated acute right anterior and middle cerebral artery territory infarctions.<sup>[5]</sup> In these two cases, it was determined that thrombosis developed despite heparin doses that were higher than the average for the ECMO population, and fibrinogen levels were markedly higher than in patients

without MIS-C undergoing ECMO.<sup>[5]</sup> Another case is of an 11-year-old male in whom echocardiography revealed a large thrombus in the right atrium, who was then successfully treated with cardiac surgery.<sup>[6]</sup>

The floppy and pedunculated mass that prolapsed into the right atrium during systole demonstrated by transesophageal echocardiography and the possibility of the migration of this mass were accepted as indications for surgery in our case. In the literature, no other similar case with multiple thrombi and without symptoms has been reported.

In conclusion, there is an increasing concern about hypercoagulation and acute thrombosis in pediatric patients with COVID-19 infection; however, no clinical studies on the efficacy and safety of anticoagulant thromboprophylaxis or antithrombotic therapy in children with COVID-19 or MIS-C have been published. In addition, the long-term effects of MIS-C are not yet thoroughly known; therefore, laboratory parameters and cardiological control follow-ups of these cases must be extended, regardless of the presence of symptoms.

**Acknowledgements:** We thank Mehmet Çoşkun for his valuable contribution to the radiological interpretation and Malik Ergin for his valuable contribution to the pathology images and interpretations.

**Patient Consent for Publication:** A written informed consent was obtained from each patient.

**Data Sharing Statement:** The data that support the findings of this study are available from the corresponding author upon reasonable request.

**Author Contributions:** Contributed to the design and implementation, to the analysis of the results and to the writing of the manuscript - A.A.K., E.K., C.Z., Y.O., M.K.

**Conflict of Interest:** The authors declared no conflicts of interest with respect to the authorship and/or publication of this article.

**Funding:** The authors received no financial support for the research and/or authorship of this article.

## REFERENCES

1. Middeldorp S, Coppens M, van Haaps TF, Foppen M, Vlaar AP, Müller MCA, et al. Incidence of venous thromboembolism in hospitalized patients with COVID-19. *J Thromb Haemost* 2020;18:1995-2002.
2. CDC Health Alert Network. Multisystem Inflammatory Syndrome in Children (MIS-C) Associated with Coronavirus Disease 2019 (COVID-19). Available at: <https://emergency.cdc.gov/han/2020/han00432.asp> [Accessed: February 13, 2021]
3. Klok FA, Kruip MJHA, van der Meer NJM, Arbous MS, Gommers DAMPJ, Kant KM, et al. Incidence of thrombotic complications in critically ill ICU patients with COVID-19. *Thromb Res* 2020;191:145-7.
4. Feldstein LR, Rose EB, Horwitz SM, Collins JP, Newhams MM, Son MBF, et al. Multisystem inflammatory syndrome in U.S. children and adolescents. *N Engl J Med* 2020;383:334-46.
5. Minen F, Hands C, Mustafa MR, Pienaar A, Lillie J. Thrombophilia in pediatric patients with multisystem inflammatory syndrome in children secondary to coronavirus disease 2019 supported on extracorporeal membrane oxygenation. *ASAIO J* 2021;67:7-11.
6. Bigdelian H, Sedighi M, Sabri MR, Dehghan B, Pourmoghaddas Z, Saleh R, et al. Right atrial thrombus in a COVID-19 child treated through cardiac surgery. *Front Cardiovasc Med* 2020;7:579522.