



A systematic review and meta-analysis of minimally invasive surgery in children with occult tethered cord syndrome

Ketao Xu, Jianhua He, Leibo Wang

Pediatric Surgery, the Affiliated Hospital of Medical School, Ningbo University, Ningbo, China

Contributions: (I) Conception and design: K Xu, L Wang; (II) Administrative support: J He; (III) Provision of study materials or patients: K Xu, L Wang; (IV) Collection and assembly of data: K Xu, J He; (V) Data analysis and interpretation: All authors; (VI) Manuscript writing: All authors; (VII) Final approval of manuscript: All authors.

Correspondence to: Leibo Wang. Pediatric Surgery, the Affiliated Hospital of Medical School, Ningbo University. No.247, Renmin Road, Jiangbei District, Ningbo, China. Email: docxkt@163.com.

Background: At present, the surgical treatment of occult tethered cord syndrome (OTCS) in children is mostly two types of minimally invasive surgery: filum terminalis laxity or filum terminalectomy. The clinical efficacy and safety of minimally invasive treatment and conservative treatment are still unclear. Therefore, this study will use the advantages of systematic review and meta-analysis to evaluate the objectivity, and explore the effect of minimally invasive surgery on children with occult tethered cord syndrome.

Methods: A computer search was used to search PubMed, Embase, CNKI, Wanfang Database and other literature search websites about the randomized controlled trials (RCTs) of minimally invasive surgery in children with occult tethered cord syndrome and spinal lipoma. Professional journals were manually searched to avoid omissions. The search keywords were: occult myelolipoma, occult tethered cord syndrome, surgical treatment of tethered cord syndrome, occult tethered cord syndrome.

Results: A total of 6 relevant literatures that could be used for meta-analysis were selected. A total of 425 subjects were included in the article, of which 132 were treated conservatively and 293 were treated surgically. The heterogeneity detection test statistics of the included studies were Chi^2 (Chi-squared test) = 8.18, df (degree of freedom) = 5, $I^2 = 39\% < 50\%$, $Z = 2.53$, and the homogeneity of the included studies was good. The number of unimproved cases under conservative treatment was 40, accounting for 30.30%; the number of unimproved cases under surgical treatment was 33, accounting for 11.26%, and the total unimproved rate of the two groups accounted for 17.17%. The unimproved rate of the experimental group was significantly lower than that of the control group, and the difference was statistically significant ($P = 0.01$). The results of bias analysis showed that there was no significant bias in the literature included in this study.

Discussion: Meta-analysis results confirmed that minimally invasive surgery has a significant effect on the treatment of occult children with tethered cord syndrome. However, due to the small sample size of the included literature, further evaluation of the treatment risk is required.

Keywords: Surgical treatment; occult tethered cord; spinal lipoma; curative effect; meta-analysis

Submitted Feb 16, 2022. Accepted for publication Mar 15, 2022.

doi: 10.21037/tp-22-72

View this article at: <https://dx.doi.org/10.21037/tp-22-72>

Introduction

Tethered cord syndrome (TCS) is a type of spinal cord disease caused by various congenital factors. It is a relatively common disease of neonates and children, it is less common

in adults, and it is more common in females than males (1). Tethered cord syndrome can be divided into conventional tethered cord syndrome (CTCS) and occult tethered cord syndrome (OTCS) according to the location of the conus medullaris. Children with occult tethered cord

syndrome have symptoms similar to those of tethered cord syndrome, especially urinary dysfunction, but MRI shows that the solid cone is in a normal position and shape, and some of these children have a thickened spinal cord or fattening. TCS is a neurological malformation. The nerve plates in the embryo's ectoderm develop dysplasia, and the notochord in the mesoderm also becomes deformed and becomes a spinal canal that surrounds the spinal cord. Deformation of the vertebral column is easy to cause and leads to various clinical manifestations, such as various lower limb movement disorders, weakened skin sensory function, and bladder and rectum dysfunction. Some children have no obvious symptoms in the early stage and do not show obvious symptoms until adulthood (2-4). The etiology is complex and can cause a series of diseases, such as meningocele, myeloid, spinal lipoma, hairless sinus, longitudinal fissure of spinal cord, and filament tension. Spinal lipoma is the most common etiology. There are currently no treatments specifically for TCS, and surgery is often used. However, the effect of treatments after a patient has obvious symptoms is often unsatisfactory (5).

Therefore, before children show obvious symptoms, interventions for OTCS have become a common goal in treatments of the disease at home and abroad. Bademci *et al.* (6) studied 5,499 children and found that 422 showed bed-wetting at night. Only 15 of the children had difficulty walking, and none of them had skin abnormalities. Only 0.1% of all children tested had TCS. Among all the children with TCS, 83.0% had a good therapeutic effect. Experiments have shown that treatments of TCS during the occult period are indeed effective. However, the specific efficacy of treatments needs further testing. A report by Veronesi *et al.* (7) described four cases of TCS treated with minimal skin incision and filamintectomy. Patients recovered well after surgery without other obvious symptoms. At present, a number of experiments and reports at home and abroad have demonstrated that minimally invasive treatment of TCS during occultation can achieve satisfactory treatment results (8-10).

Filament relaxation or termination of the TCS is a minimally invasive procedure with low risk. Spinal cord filament relaxation surgery is a surgical method in which the fused filament is separated through a small incision. Spinal cord terminectomy is a small incision at the end of the spinal cord to cut off the cord terminus. Although the names are different, the procedures are similar. These treatments contact the filament of the spinal cord traction and improve the microcirculation of the spinal cord.

Specific surgical options require personalized analyses of the patients' individual situations by physicians (11-14).

At present, for a new treatment plan, there are a certain number and quality of relevant research reports at home and abroad, and meta-analysis is usually used to provide clinical evidence for evidence-based medicine research. Through meta-analysis, the relevant research data at home and abroad are summarized, and the large sample obtained after the summary is comprehensively evaluated, which not only realizes quantitative synthesis, improves the efficiency of statistical results, but also comprehensively evaluates the existing research results. A repeatable and systematic solution. Therefore, this article will conduct a meta-analysis of minimally invasive surgery in children with occult tethered cord syndrome to determine the therapeutic effect of minimally invasive surgery.

The innovation of this study lies in the use of authoritative search websites to collect relevant research literature, systematic review and meta-analysis to objectively evaluate the difference in clinical efficacy between minimally invasive treatment and traditional treatment of children with occult tethered cord syndrome, so as to provide clinical treatment options. Tethered cord syndrome provides evidence-based evidence. At present, there are few related researches on the postoperative efficacy of minimally invasive surgery for the treatment of children with occult tethered cord syndrome. We present the following article in accordance with the PRISMA reporting checklist (available at <https://tp.amegroups.com/article/view/10.21037/tp-22-72/rc>).

Methods

Article retrieval

In this study, the Chinese and English databases searched were PubMed, Embase, MEDLINE, Science Direct, Cochrane Library, China Hownet, Wanfang Database, and Weipu. A search was conducted for published randomized controlled trials (RCTs) of minimally invasive surgery for OTCS in children between the period from the database establishment to October 1, 2021.

Retrieval strategies

The following study object search words were used: including tethered cord syndrome, TCS, occult tethered cord syndrome, OTCS, occult myelolipoma, minimally

invasive surgery, filumectomy, cutting filum terminale, efficacy analysis, children. Articles were limited to those published in English. For an article to be included in the retrieval process, the subjects of the study were children under 18 years old, the number of cases in a single article was not less than 5, and the article had corresponding conclusions. In this paper, through database search, it was found that the available results of the above search terms were too few, so the search scope was expanded to include the main disease of spinal lipoma.

The following observation index search words were used: tethered cord syndrome, TCS, urodynamic score, urodynamic finding, exacerbation, no change, and disease improvement rate.

Multiple retrievals were conducted by combining subject words and free words to obtain references that could be included. Then, search engines were used to track down each article, and relevant experts and researchers were contacted to obtain the latest study progress. The quality of the included articles was assessed using RevMan 5.3 software provided by Cochrane Collaboration (Website: <https://www.cochrane.org/zh-hans/evidence>; Location: London, UK).

Inclusion and exclusion criteria of the included articles

Articles in this study had to meet the following criteria: the type of study was a prospective RCT; subjects were children with OTC; intervention measures were minimally invasive surgery, such as filumectomy or filumectomy in the surgical group; intervention of the medical team was done with or without general medication; the study was published in English; and outcome index of patient intervention was whether or not the condition of the patient improved.

Articles were excluded from the study if they met the following criteria: were incomplete, such as contents, abstracts, conference reports, reviews, replies from editors, and others; did not contain a surgical intervention of non-filament treatment; had no clear conclusions; or if they contained patients older than 18 years old.

Data extraction

In this study, a special data extraction table was designed according to the research topic. Two experts used Microsoft Excel to independently extract the data, and then cross-checked. If the two experts had inconsistent views, a

consistent conclusion was obtained through discussion. Year of publication, first author, number of literature cases, average follow-up years, average age of patients, treatment methods, pre-intervention status (urodynamic evaluation, limb function, bowel and bladder function, patient experience, skin condition, etc.), intervention Information such as post-follow-up status (improved, unimproved, and deteriorating) were collected and sorted into EXCEL files.

Literature risk of bias and quality assessment

Two investigators used RevMan 5.3 and the Diagnostic Test Accuracy Assessment Tool (QUADAS) to assess the quality of the included literature. When investigators disagree, a third investigator conducts an interventional evaluation, and a consensus recommendation is finally reached through discussion. The evaluation criteria include the selection of cases, the method to be evaluated, the gold standard, the evaluation process, and progress.

When using the QUADAS tool to evaluate the included literature, the tool contains a total of 16 items, and “Yes”, “No” and “Unclear” are used to evaluate the quality of the literature, where “Yes” means compliance with the standard, “No” means not meeting the criteria, defined as “Unclear” when the information is incomplete or only partially meets the criteria. To use RevMan 5.3 to evaluate the quality of literature, the quality should be judged from the following aspects: (I) whether it is a randomized controlled study; (II) whether there is allocation concealment; (III) whether blinded test is used; (IV) results data whether it is complete; (V) there is selective reporting; (VI) whether there is other bias.

Statistical methods

Statistical analysis was performed using Stata SE 12.0 software (College Station, USA). The risk of bias assessment of the included references was assessed using the risk of bias assessment plot of RevMan 5.3 software. The results of continuous variables were measured by mean difference (MD), discrete variables by standardized mean difference (SMD), and non-continuous variables (NOA) by odds ratio (OR). Each effect was expressed using a 95% confidence interval (CI). When $P > 0.01$ and $I^2 < 50\%$, a fixed effect model was used for meta-analysis. When $P < 0.01$ and $I^2 > 50\%$, a random effect model was used for meta-analysis.

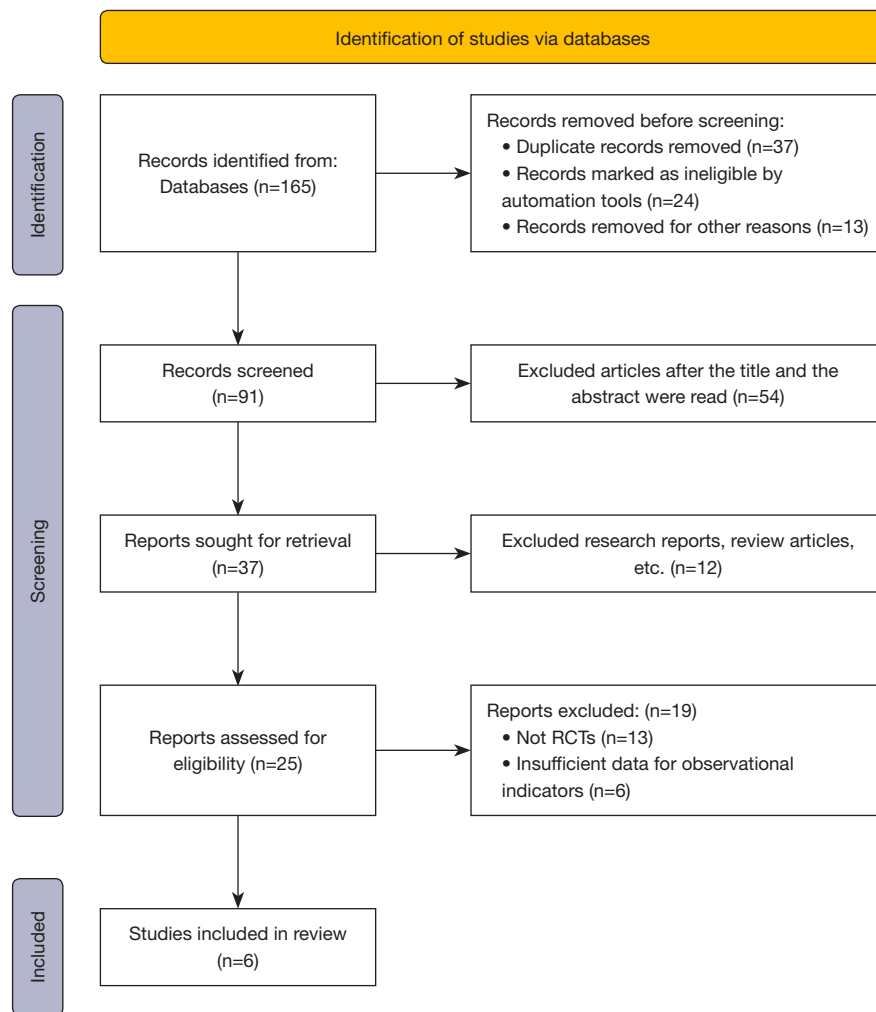


Figure 1 Flow chart of retrieving articles. RCT, randomized controlled trial.

Results

Search results and basic information of included articles

A total of 165 articles were retrieved through database searches in this study. After excluding 37 duplicate publications, 24 unqualified documents automatically screened by the system, and 13 articles for which the full text could not be obtained, the remaining 91 articles were obtained. After that, by reading the abstracts and titles of the literature, 54 articles that did not meet the screening criteria were deleted, leaving 37 articles. In addition, 12 research reports and reviews were excluded, leaving 25 papers. After reading the full text, after excluding 13 papers whose grouping method was not randomised controlled trials, and 6 papers whose relevant information could not be further

extracted, 6 papers were finally included in the meta-analysis. *Figure 1* shows a flow chart of article retrieval and the article selection process, while *Table 1* contains information about the features of the 6 selected articles.

Meta-analysis on minimally invasive surgery for OTCS in children

In all 6 screened articles, patients were randomly assigned to surgery or conservative treatment. After treatment, patients were randomly followed up to collect information about changes in their conditions. The aggravation and stability of the disease was recorded as Events. *Figure 2* shows the forest map of disease changes after treatment in the surgical group and the control group. The heterogeneity test

Table 1 Basic features of the included articles

The first author	Year of publication	Group	Case	Mean follow-up time (years)	Average age (years old)	Outcome indicator
Dushi G (15)	2011	Control group	11	4.3	2.9	Non-improvement rate
		Surgical group	7	10	1.4	Non-improvement rate
Kulkarni AV (16)	2004	Control group	53	4.4	1.8	Non-improvement rate
		Surgical group	100	4.4	1.8	Non-improvement rate
Tu A (17)	2016	Control group	14	8.3	4.1	Non-improvement rate
		Surgical group	10	2.6	0.8	Non-improvement rate
Oi S (18)	2009	Control group	23	2.6	3	Non-improvement rate
		Surgical group	136	2.6	3	Non-improvement rate
Talamonti G (19)	2014	Control group	24	10.4	3.1	Non-improvement rate
		Surgical group	32	9.7	1.9	Non-improvement rate
Steinbok P (20)	2007	Control group	7	3.3	8.2	Non-improvement rate
		Surgical group	8	3.1	8	Non-improvement rate

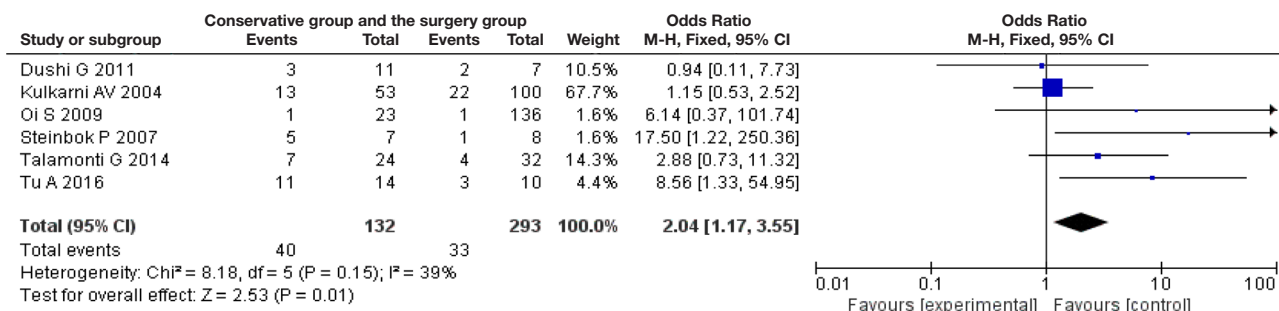


Figure 2 Forest plot of postoperative disease changes of the conservative group and the surgery group. CI, confidence interval.

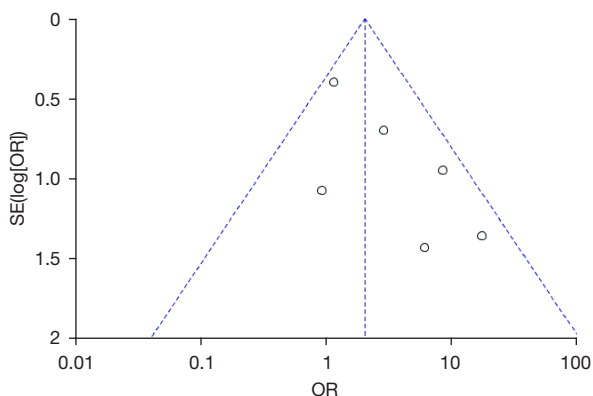


Figure 3 Funnel plot of postoperative improvement in the conservative group and the surgery group. SE, standard error; OR, odds ratio.

statistic ($I^2=39% < 50%$; $P > 0.05$) of the included studies was considered to be homogenous. A total of 425 experimental subjects were included in the selected studies. Of these, 132 cases were treated conservatively, and 293 cases were treated surgically. A total of 40 cases did not show improvement after conservative treatment, accounting for 30.30%. Furthermore, 33 cases did not show improvement after surgical treatment, accounting for 11.26%. The ratio of no change in the two combinations was 17.17%. The unimproved rate of the experimental group was significantly lower than that of the control group, and the difference was statistically significant ($P=0.01$).

Figure 3 shows the funnel plot of disease changes after treatments in the surgical group and the control group.

The circles in the study were distributed on both sides of the center line, but they were not evenly dispersed. This phenomenon might be related to the small number of articles that were eligible to be included in the meta-analysis.

Discussion

TCS, as a neurological malformation disease, has a very complex etiology. Spinal lipoma is the most common type, and its severity increases with age. TCS reduces lower limb mobility inconvenience, causes pain and deformity of the spine and lower limbs, and also causes defecation disorders and incontinence (21-23). However, most TCS is occult in the early stage without any symptoms. TCS can be hidden for years or decades, and some patients do not show symptoms until adulthood. However, TCS can be diagnosed and treated with medical imaging at the occult stage. Currently, there is disagreement about whether surgical treatment is more effective than conservative treatment for OTCS.

Therefore, a comprehensive understanding of the treatment history of the disease can help to fully understand the effect of surgical treatment on OTCS. In this study, PubMed, Google Academic, Embase, and other search engines were used to search for surgical treatment of TCS, but the available results were too few. Therefore, the search was expanded to the main condition, spinal lipoma, which included surgical treatment and conservative treatment. At the same time, a total of 6 articles, totaling 425 patients in RCTs, were included in the meta-analysis. The results of the meta-analysis showed that the incidence of non-improvement after conservative treatment (30.30%) was much higher than non-improvement after surgical treatment (17.17%). This suggested that surgical treatment could improve the patients' symptoms to a certain extent. In particular, the control of lower limb movement ability and urine and feces after operation was improved compared with conservative treatment. However, there might be some errors in experimental results due to the limited 6 articles included in meta-analysis.

Follow-up time for OTCS after treatments can also present some limitations. In a follow-up trial of tether syndrome for up to 31 years, Kobets *et al.* (24) presented a patient with a recurrence of advanced tether syndrome at 11, 26, and 31 years after the initial surgical treatment. Although this patient was an individual case, the average follow-up time reported was 3–10 years, which also caused

some difficulties in data collection. At the same time, the results of some studies did not significantly demonstrate differences between surgical treatment and conservative treatment. Steinbok *et al.* (25) conducted a follow-up study by collecting the data of 21 patients in 8 years. However, the urodynamic improvement rate (2%) of the surgery group was higher than that of conservative treatment. Bowel and bladder improvement (4%) was higher than conservative treatment, and the other differences were not significant. Through a 20-year follow-up study of 315 patients with total resection of spinal lipoma, Pang [2015] (26) concluded that both conservative treatment and partial resection had poor outcomes after treatments for OTCS. The progression-free survival of patients undergoing total resection increased by about 10% after 20 years. These studies showed that surgical treatment for OCTs in children had a slight improvement in patient symptoms, but caution should be taken when basing treatment decisions on the limited amount of existing research.

Conclusions

In this study, articles related to minimally invasive treatment of OCTs in children were screened for meta-analysis to explore the clinical efficacy of surgical treatment of OCTs in children. Meta-analysis results showed that surgical treatment improved patients' conditions compared with conservative treatment. However, due to the small number of articles selected in this study, there were still some controversies about the relevant therapeutic conclusions and caution should be taken when basing clinical decisions on the findings of this study. However, by reviewing surgical treatment of OCTs in children, this study provides support for clinical treatment of OTCS in children.

Acknowledgments

Funding: None.

Footnote

Reporting Checklist: The authors have completed the PRISMA reporting checklist. Available at <https://tp.amegroups.com/article/view/10.21037/tp-22-72/rc>

Conflicts of Interest: All authors have completed the ICMJE uniform disclosure form (available at <https://tp.amegroups.com/article/view/10.21037/tp-22-72/coif>). The authors

have no conflicts of interest to declare.

Ethical Statement: The authors are accountable for all aspects of the work in ensuring that questions related to the accuracy or integrity of any part of the work are appropriately investigated and resolved.

Open Access Statement: This is an Open Access article distributed in accordance with the Creative Commons Attribution-NonCommercial-NoDerivs 4.0 International License (CC BY-NC-ND 4.0), which permits the non-commercial replication and distribution of the article with the strict proviso that no changes or edits are made and the original work is properly cited (including links to both the formal publication through the relevant DOI and the license). See: <https://creativecommons.org/licenses/by-nc-nd/4.0/>.

References

1. Yamada S, Won DJ, Siddiqi J, et al. Tethered cord syndrome: overview of diagnosis and treatment. *Neurol Res* 2004;26:719-21.
2. Tsiptsios D, Sysoev K, Ouranidis A, et al. Occult tethered cord syndrome: a reversible cause of paraparesis not to be missed. *Childs Nerv Syst* 2020;36:1833-4.
3. Tuite GF, Thompson DNP, Austin PF, et al. Evaluation and management of tethered cord syndrome in occult spinal dysraphism: Recommendations from the international children's continence society. *Neurourol Urodyn* 2018;37:890-903.
4. Tu A, Steinbok P. Occult tethered cord syndrome: a review. *Childs Nerv Syst* 2013;29:1635-40.
5. Cayli SR, Koçak A, Onal C. An unusual presentation of occult spinal dysraphism. *J Neurosurg Sci* 2002;46:39-41; discussion 41.
6. Bademci G, Saygun M, Batay F, et al. Prevalence of primary tethered cord syndrome associated with occult spinal dysraphism in primary school children in Turkey. *Pediatr Neurosurg* 2006;42:4-13.
7. Veronesi V, Calderone M, Sacco C, et al. Prone Position Magnetic Resonance Imaging and Transhiatal Approach to Filum Terminale Externum Sectioning in Adolescents with Occult Tethered Cord Syndrome: Report of Four Cases. *Pediatr Neurosurg* 2020;55:432-8.
8. White JT, Samples DC, Prieto JC, et al. Systematic Review of Urologic Outcomes from Tethered Cord Release in Occult Spinal Dysraphism in Children. *Curr Urol Rep* 2015;16:78.
9. Steinbok P, Garton HJ, Gupta N. Occult tethered cord syndrome: a survey of practice patterns. *J Neurosurg* 2006;104:309-13.
10. Metcalfe PD, Luerssen TG, King SJ, et al. Treatment of the occult tethered spinal cord for neuropathic bladder: results of sectioning the filum terminale. *J Urol* 2006;176:1826-9; discussion 1830.
11. Henderson G, Dunham C, Steinbok P. Histopathology of the filum terminale in children with and without tethered cord syndrome with attention to the elastic tissue within the filum. *Childs Nerv Syst* 2016;32:1683-92.
12. Nazar GB, Casale AJ, Roberts JG, et al. Occult filum terminale syndrome. *Pediatr Neurosurg* 1995;23:228-35.
13. Fontes RB, Saad F, Soares MS, et al. Ultrastructural study of the filum terminale and its elastic fibers. *Neurosurgery* 2006;58:978-84; discussion 978-84.
14. Thompson EM, Strong MJ, Warren G, et al. Clinical significance of imaging and histological characteristics of filum terminale in tethered cord syndrome. *J Neurosurg Pediatr* 2014;13:255-9.
15. Dushi G, Frey P, Ramseyer P, et al. Urodynamic score in children with lipomyelomeningocele: a prospective study. *J Urol* 2011;186:655-9.
16. Kulkarni AV, Pierre-Kahn A, Zerah M. Conservative management of asymptomatic spinal lipomas of the conus. *Neurosurgery* 2004;54:868-73; discussion 873-5.
17. Tu A, Hengel R, Cochrane DD. The natural history and management of patients with congenital deficits associated with lumbosacral lipomas. *Childs Nerv Syst* 2016;32:667-73.
18. Oi S, Nomura S, Nagasaka M, et al. Embryopathogenetic surgicoanatomical classification of dysraphism and surgical outcome of spinal lipoma: a nationwide multicenter cooperative study in Japan. *J Neurosurg Pediatr* 2009;3:412-9.
19. Talamonti G, D'Aliberti G, Nichelatti M, et al. Asymptomatic lipomas of the medullary conus: surgical treatment versus conservative management. *J Neurosurg Pediatr* 2014;14:245-54.
20. Steinbok P, Kariyattil R, MacNeily AE. Comparison of section of filum terminale and non-neurosurgical management for urinary incontinence in patients with normal conus position and possible occult tethered cord syndrome. *Neurosurgery* 2007;61:550-5; discussion 555-6.
21. Aldave G, Hansen D, Hwang SW, et al. Spinal column shortening for tethered cord syndrome associated with myelomeningocele, lumbosacral lipoma, and

- lipomyelomeningocele in children and young adults. *J Neurosurg Pediatr* 2017;19:703-10.
22. Rhodes RH. Congenital Spinal Lipomatous Malformations. Part 1. Spinal Lipomas, Lipomyeloceles, and Lipomyelomeningocele. *Fetal Pediatr Pathol* 2020;39:194-245.
 23. Muthukumar N. Congenital spinal lipomatous malformations: part II--Clinical presentation, operative findings, and outcome. *Acta Neurochir (Wien)* 2009;151:189-97; discussion 197.
 24. Kobets AJ, Oliver J, Cohen A, et al. Split cord malformation and tethered cord syndrome: case series with long-term follow-up and literature review. *Childs Nerv Syst* 2021;37:1301-6.
 25. Steinbok P, MacNeily AE, Hengel AR, et al. Filum Section for Urinary Incontinence in Children with Occult Tethered Cord Syndrome: A Randomized, Controlled Pilot Study. *J Urol* 2016;195:1183-8.
 26. Pang D. Total Resection of Complex Spinal Cord Lipomas: How, Why, and When to Operate? *Neurol Med Chir (Tokyo)* 2015;55:695-721.
- (English Language Editor: C. Mullens)

Cite this article as: Xu K, He J, Wang L. A systematic review and meta-analysis of minimally invasive surgery in children with occult tethered cord syndrome. *Transl Pediatr* 2022;11(3):403-410. doi: 10.21037/tp-22-72