



# Trigger elimination of polymorphic ventricular tachycardia and ventricular fibrillation by catheter ablation: trigger and substrate modification

Akihiko Nogami<sup>✉</sup>

Cardiovascular Division, University of Tsukuba, Tsukuba, Ibaraki, Japan.

## Abstract

Ventricular fibrillation (VF) is a malignant arrhythmia, usually initiated by a ventricular premature contraction (VPC) during the vulnerable period of cardiac repolarization. Ablation therapy for VF has been described and increasingly reported. Targets for VF triggers are VPCs preceded by Purkinje potentials or from the right ventricular outflow tract (RVOT) in structurally normal hearts, and VPC triggers preceded by Purkinje potentials in ischemic cardiomyopathy. During the session, mapping should be focused on the earliest activation and determining the earliest potential is the key to a successful ablation. However, suppression of VF can be achieved by not only the elimination of triggering VPCs, but also by substrate modification of possible reentry circuits in the Purkinje network, or between the PA and RVOT. The most important issue before the ablation session is the recording of the 12-lead ECG of the triggering event, which can prove invaluable in regionalizing the origin of the triggering VPC for more detailed mapping. In cases where the VPC is not spontaneous or inducible, ablation may be performed by pace mapping. Further studies are needed to evaluate the precise mechanisms of this arrhythmia.

**Keywords:** catheter ablation, inherited arrhythmias, polymorphic ventricular tachycardia, Purkinje network, right ventricular outflow tract, ventricular fibrillation

## Introduction

While previous studies have shown that ventricular fibrillation (VF) is perpetuated by reentry or spiral waves, recent data suggest the role of specific sources triggering this arrhythmia. Haïssaguerre et al.<sup>[1]</sup> reported that idiopathic VF could be suppressed by catheter ablation of those triggers originating from the Purkinje system or right ventricular outflow tract (RVOT) and the ablation therapy for VF has been increasingly reported during the last decade. In general, this ablation appears to have a high success rate and is relatively easy to perform, although precise mapping is required. However,

little is known about the initiating mechanism of VF. The pathophysiology of VF can be subdivided into three phases: trigger sources, initiation and maintenance or mechanisms of perpetuation. Whether the mechanism of the ablation effect is due to the suppression of the trigger or substrate modification is still unclear.

## RVOT trigger VPCs

The common arrhythmias arising from the RVOT are isolated VPCs or ventricular tachycardia (VT)<sup>[2]</sup>. In patients without structural heart disease, ventricular arrhythmias from the RVOT are generally considered

<sup>✉</sup> Corresponding author: Professor Akihiko Nogami, the Cardiovascular Division, University of Tsukuba, 1-1-1 Tennodai Tsukuba, Ibaraki, 305-8575, Japan. Tel/Fax: +81-29-853-3142/+81-29-853-3143, E-mail: [akihiko-ind@umin.ac.jp](mailto:akihiko-ind@umin.ac.jp).

Received 20 November 2014, Accepted 04 December 2014, Epub 01 January 2015

The author reported no conflict of interests.

to be benign. However, VPCs originating from the RVOT occasionally trigger VF or polymorphic VT (PVT)<sup>[1,3-9]</sup>. Noda and colleagues reported 16 patients with idiopathic VF triggered by RVOT VPCs<sup>[3]</sup>. Of those patients, 7 (44%) were male and 11 (69%) had a history of syncope. VPCs arose from the septal area of the RVOT in most of the patients.

### Difference between malignant and benign VPCs from the RVOT

Patients with PVT/VF had frequent RVOT VPCs but only a few episodes of PVT/VF<sup>[1,3]</sup>. Viskin and colleagues reported 3 patients with no heart disease, RVOT VPCs and PVT/VF whose malignant trigger VPCs had shorter coupling intervals compared to benign VPCs of the same morphology<sup>[7]</sup>. However, this finding is not consistent with Noda et al. who demonstrated no significant difference regarding the total number of VPCs and the coupling interval between RVOT VPCs with PVT/VF and benign RVOT VPCs<sup>[3]</sup>.

Kurosaki and colleagues evaluated the difference in the initial VPCs between PVT/VF and monomorphic VT (MVT) from the RVOT<sup>[8]</sup>. They compared the electrocardiographic and the clinical characteristics between 14 patients with PVT/VF and 77 patients with MVT. The episodes of syncope were more frequent in the PVT/VF group (57%) than in the MVT group (10%). An initial VPC with a positive QRS complex in lead I was observed in 10 (71%) of 14 patients with PVT/VF, and in 27 (35%) of 77 patients with MVT ( $P < 0.05$ ). Although radiofrequency (RF) catheter ablation targeting the trigger VPC often produced a morphological change, PVT/VF was eliminated in 13 (93%) of 14 patients after additional RF energy applications. They concluded that malignant arrhythmias from the RVOT, although rare, should be considered when the patient has a syncopal episode and VPC with a positive QRS complex in lead I.

While most of the previous investigators could not find a difference in the coupling interval between benign VPCs and trigger VPCs of PVT/VF, Igarashi and colleagues demonstrated a significant difference in the ratio of the coupling interval to the preceding R-R interval (prematurity index)<sup>[9]</sup>. They compared the ECG parameters between 18 patients with idiopathic PVT/VF and 21 patients with MVT arising from the RVOT. While the coupling interval of the first VT beat was comparable between the 2 groups, the prematurity index of the first VT beat was significantly smaller in the PVT-group than in the MVT-group. Although the ratio of the coupling interval to the preceding QT interval was also different, the prematurity index was the

only independent determinant of the polymorphic QRS morphology (odds ratio = 2.198).

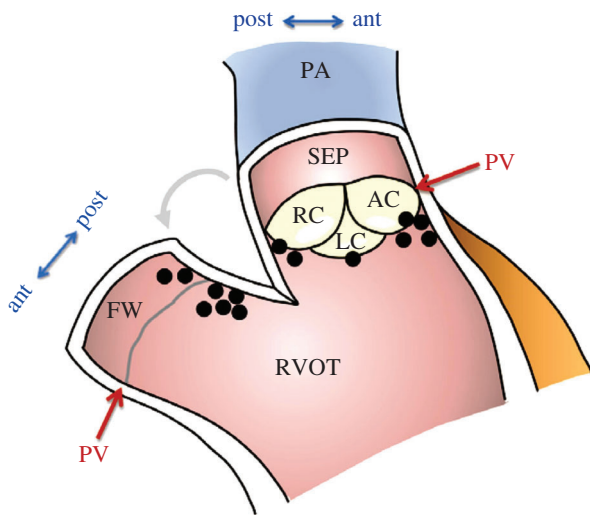
### Ablation of RVOT VPCs

The RVOT is the most common origin of isolated VPCs and MVT in structurally normal hearts. It is also the origin for triggers of PVT, which rapidly degenerate into VF. This type of ablation is essentially no different than the ablation of idiopathic RVOT-VPCs or VT. The ablation targets the site of the earliest activation and a good pace map in the RVOT<sup>[3,8,9]</sup>. In general, this ablation appears to have a high success rate and is relatively easy to perform. Noda and colleagues reported 16 patients who had PVT/VF initiated by VPCs arising from the RVOT<sup>[3]</sup>. The optimal ablation site was determined by the earliest local activation site during the spontaneous target VPC and/or by pace mapping. RF energy was applied at the optimal site (local potential  $17 \text{ ms} \pm 11 \text{ ms}$  before the onset of the QRS). In 11 of 16 patients (63%), other VPCs with a different QRS morphology appeared after ablation of the initial target. Such a morphological change after the RF application was also observed by Kurosaki et al.<sup>[8]</sup> They reported that a morphological change occurred in 71% of the PVT/VF patients during the ablation session, but also in 52% of the MVT patients. Eventually, Noda and colleagues reported that RF catheter ablation was successful in 13 out of 16 patients with PVT/VF (81%) during a mean follow-up of  $54 \pm 39$  months. Kurosaki and colleagues reported that a successful RFCA was achieved in 13 out of 14 patients (93%) in the VF/PVT group and in 65 out of 77 patients (84%) in the MVT group after a mean follow-up period of  $71 \pm 34$  months. Similar good results were reported by other authors in cases treated with the same approach<sup>[1,4,5,6,10]</sup>.

**Fig. 1** shows the distribution of the final successful ablation sites in 14 patients with PVT/VF in the study by Kurosaki et al.<sup>[8]</sup> Trigger VPCs were finally eliminated at the posterior attachment of the free wall in 7, at the posterior attachment of the septum in 2, midway-between the anterior and posterior attachment of the septum in 1, and at the anterior attachment of the septum in 4. In 2 patients (14%) with PVT/VF, the final successful ablation site was above the pulmonary valve. In all patients with VPCs originating from above the pulmonary valve, a sharp potential preceding the QRS onset and a subsequent dull potential were recorded during the VPCs from the ablation catheter.

### Substrate modification for PVT/VF arising from RVOT

The following case demonstrates an unusual patient with suppression of PVT by conduction block between



**Fig. 1** Successful ablation sites in 14 patients with ventricular fibrillation/polymorphic ventricular tachycardia from right ventricular outflow tract. Coronal section image of the ventriculo-pulmonary junction. In 9 of 14 patients, the successful ablation sites were located on the posterior attachment of the right ventricular outflow tract. AC = anterior cusp of pulmonary valve; ant = anterior attachment; FW = free wall; LC = left cusp; PA = pulmonary artery; post = posterior attachment; PV = level of pulmonary valve; RC = right cusp; SEP = septum. (From Kurosaki K, Nogami A, Shirai Y, et al. Positive QRS complex in lead I as a malignant sign in right ventricular outflow tract tachycardia. *Circ J* 2013;77(4):968–974. With permission.)<sup>[8]</sup>

the pulmonary artery (PA) and RVOT<sup>[11]</sup>. A 56-year-old female presented with multiple episodes of syncope and Holter monitoring revealed frequent episodes of PVT (**Fig. 2A**). The mean cycle length of the VT was 220 ms and the morphologies of the first three QRS complexes of the PVT were always the same. Electroanatomical mapping was performed and the propagation map of the first VPC had a centrifugal pattern from the posterior attachment of the RVOT. From that site, pace mapping was performed. Interestingly, pacing at a cycle length of 300 ms created the exact same polymorphic QRS configurations as those created during the clinical PVT (**Fig. 2B** and **Fig. 2C**). After several RF energy applications to the posterior RVOT, the repetitive VPCs disappeared. However, isolated VPCs with a slightly different QRS morphology and a longer coupling interval remained. Therefore, mapping in the pulmonary artery (PA) was performed. From the PA, delayed PA potentials were recorded during sinus rhythm and those potentials preceded the onset of the QRS during the VPC that remained (**Fig. 3A**). Between the PA and RVOT potentials, a tiny bridging potential was recorded. RF energy was delivered at that site in the PA. Just after the RF energy application, the PA potential disappeared (**Fig. 3B**). Repetitive firing from the PA was observed; however, there were no

VPCs. These findings indicate that there was bidirectional conduction block between the PA and RVOT. In this case, the site-of-origin of the triggering beat was in the PA, and the multiple exits or non-uniform conduction to the RVOT might be the mechanism of the polymorphism of the VT. In fact, the change in the QRS configuration was reproduced by pacing at a relatively long cycle length. The electrical isolation of the extracardiac vessel, i.e. PA, suppressed the fibrillatory arrhythmia in the connecting heart chamber, i.e. RV. Interestingly, it is quite similar to the relationship between the pulmonary veins and left atrium in the mechanism of paroxysmal atrial fibrillation.

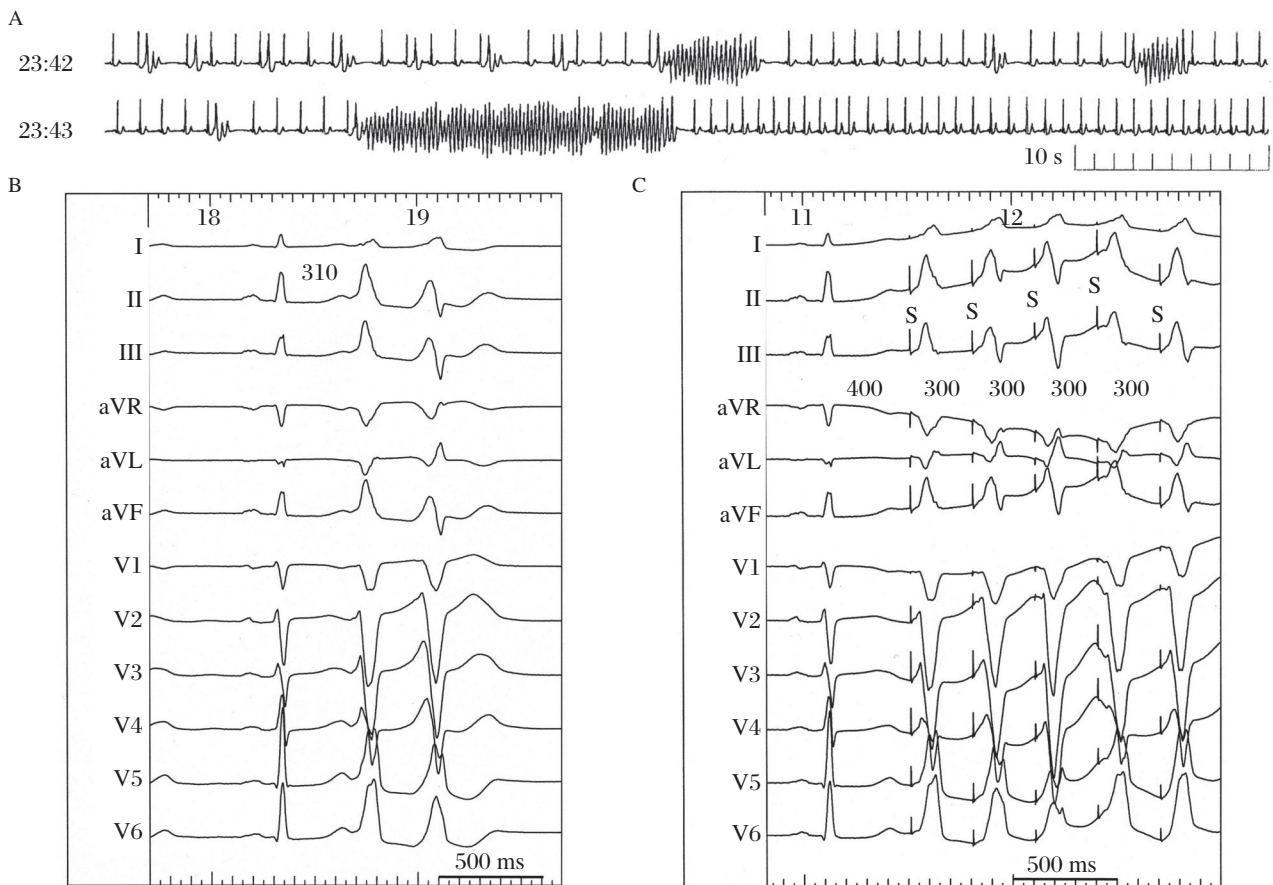
### Trigger from Purkinje system

Another trigger of idiopathic VF is the Purkinje system<sup>[1]</sup>, which can also be a trigger of ischemic VF<sup>[12,13]</sup>. In a multicenter study, including 23 patients with apparently normal hearts, VPCs arising from Purkinje system of the left ventricle were characterized by a right bundle branch block (RBBB) morphology and a relatively short QRS duration ( $115 \pm 11$  ms)<sup>[1]</sup>. The origin of those VPCs is from a wider area compared to the RVOT VPCs<sup>[1]</sup>. Purkinje system VPCs originating in the right ventricle were characterized by a left bundle branch block (LBBB) morphology. VPCs with a right ventricular origin mostly arise from the anterior free wall and display a significantly longer QRS duration ( $143 \pm 10$  ms). The time interval between the local Purkinje potential and the local myocardial potential was  $11 \pm 5$  ms without any significant difference between the left and right sides, indicating the more distal origin of the VPCs in the area of the Purkinje arborization. In the same study, VPCs originating from the Purkinje system were compared with VPCs arising from the RVOT (4 patients). In the former group a significantly shorter QRS duration ( $126 \pm 18$  vs.  $145 \pm 12$  ms) and a shorter VPC coupling interval ( $280 \pm 26$  vs.  $355 \pm 30$  ms) were observed<sup>[1]</sup>.

### Substrate modification of the Purkinje network

Catheter ablation targeting the Purkinje potentials responsible for triggering VF has been shown to be possible and efficacious in a number of conditions such as idiopathic VF (short-coupled variant of torsade de pointes), ischemic VF, and chronic myocarditis. What is still undetermined is whether the mechanism of the ablation effect is due to the elimination of the trigger or substrate modification of the Purkinje network.

During activation mapping of the triggering VPC, attention should be paid to the preceding sharp

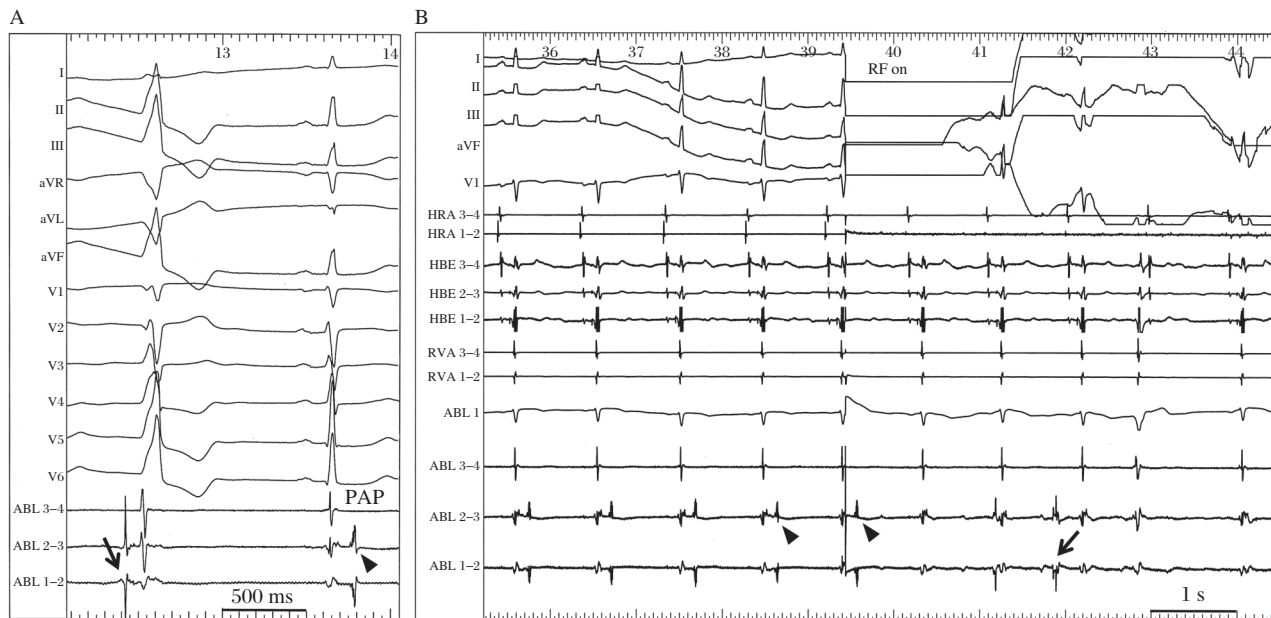


**Fig. 2** Surface 12-lead ECGs in a female patient with an right ventricular outflow tract (RVOT) type polymorphic ventricular tachycardia (PVT). A: Holter monitoring revealed frequent episodes of PVT. The mean cycle length of the VT was 220 ms and the morphologies of the first three QRS complexes of the PVT were always the same. B: Polymorphic ventricular premature contraction (VPC) couplets were recorded during the ablation session. C: Pace mapping at the earliest activation site in the RVOT reproduced the exact the same polymorphic QRS configurations as those during the clinical PVT. (From Nogami A. Mapping and ablating ventricular premature contractions that trigger ventricular fibrillation: Trigger elimination and substrate modification. *J Cardiovasc Electrophysiol* 2014 Sep 12. doi: 10.1111/jce.12547. [Epub ahead of print] PubMed PMID: 25216244. With permission.)<sup>[11]</sup>

Purkinje-like signals. Mapping should be focused on the earliest activation of this potential and determining the earliest potential is the key to a successful ablation. However, the potential may sometimes be seen to occur with intra-Purkinje block to the myocardium and not produce a VPC. This means that there is the possibility that not only the elimination of the triggering VPC, but also conduction block in the Purkinje network can suppress the triggering VPC and VF. In fact, dissociated firing from the Purkinje network is sometimes seen after a successful ablation. The following case is an example of the successful suppression of VF by the modification of the Purkinje network.

A 54-year-old man with idiopathic VF (short-coupled variant of torsade de pointes) underwent catheter ablation for frequent episodes of defibrillator (ICD) shocks<sup>[14]</sup>. A nonsustained PVT with the same QRS

morphology as the clinical PVT was repeatedly inducible by atrial pacing after an intravenous administration of cibenzoline (**Fig. 4A**). The first VPC (VPC1) had an RBBB configuration with right-axis deviation and the second one (VPC2) had an RBBB pattern with a northwest axis. The coupling interval of VPC1 to the preceding normally conducted QRS complex was 250 ms. During the PVT, diastolic and presystolic Purkinje potentials were recorded from an octapolar electrode catheter with 1.25-mm electrode widths and 2-mm inter-electrode spacing placed on the left ventricular septum (**Fig. 4A** and **Fig. 4B**). Diastolic Purkinje potentials were recorded earlier from the proximal than the distal electrodes and fused presystolic Purkinje potentials were recorded earlier from the distal than the proximal electrodes. During sinus rhythm, recording at the same site demonstrated fused Purkinje potentials before the onset of the QRS. Because the



**Fig. 3 Successful ablation in the pulmonary artery (PA).** A: From the PA, a delayed PA potential was recorded during sinus rhythm (arrow head) and this potential preceded the onset of the QRS during the remaining VPC (arrow). Between the PA and RVOT potentials, a tiny bridging potential was recorded. B: Just after the RF energy application in the PA, the PA potential (arrow heads) disappeared. Repetitive firing from the PA was observed (arrow); however, there were no VPCs. These findings indicate that bidirectional conduction block occurred between the PA and RVOT. HBE = His-bundle electrogram; HRA = high right atrium; PAP = pulmonary artery potential; RF = radiofrequency energy. (From Nogami A. Mapping and ablating ventricular premature contractions that trigger ventricular fibrillation: Trigger elimination and substrate modification. *J Cardiovasc Electrophysiol* 2014 Sep 12. doi: 10.1111/jce.12547. [Epub ahead of print] PubMed PMID: 25216244. With permission.)<sup>(11)</sup>

earliest Purkinje activation site before VPC1 could not be determined and seemed to be a more proximal site than the site of electrodes 7–8, RF energy was delivered to the site of electrodes 3–4. A Purkinje potential from this site preceded the onset of VPC1 by 15 ms and VPC2 by 60 ms. The intracardiac electrograms recorded after the ablation showed the abolition of the local Purkinje potentials at the middle portion and a slight delay in the occurrence of the local ventricular electrogram during sinus rhythm (**Fig. 4C**). The PVT became noninducible and only an isolated VPC was inducible. The morphology of this isolated VPC differed from the previous triggering VPCs (VPC1 or VPC2). Further, Purkinje firing was observed before this VPC and intra-Purkinje block occurred. The patient was followed without any drugs, episodes of syncope or VF recurrences during a follow-up period of 14 years. These observations suggest that the VF initiation was caused by activity from the Purkinje tissue. However, the suppression of the VF was achieved with catheter ablation of the Purkinje network, not at the earliest Purkinje activation site in this patient.

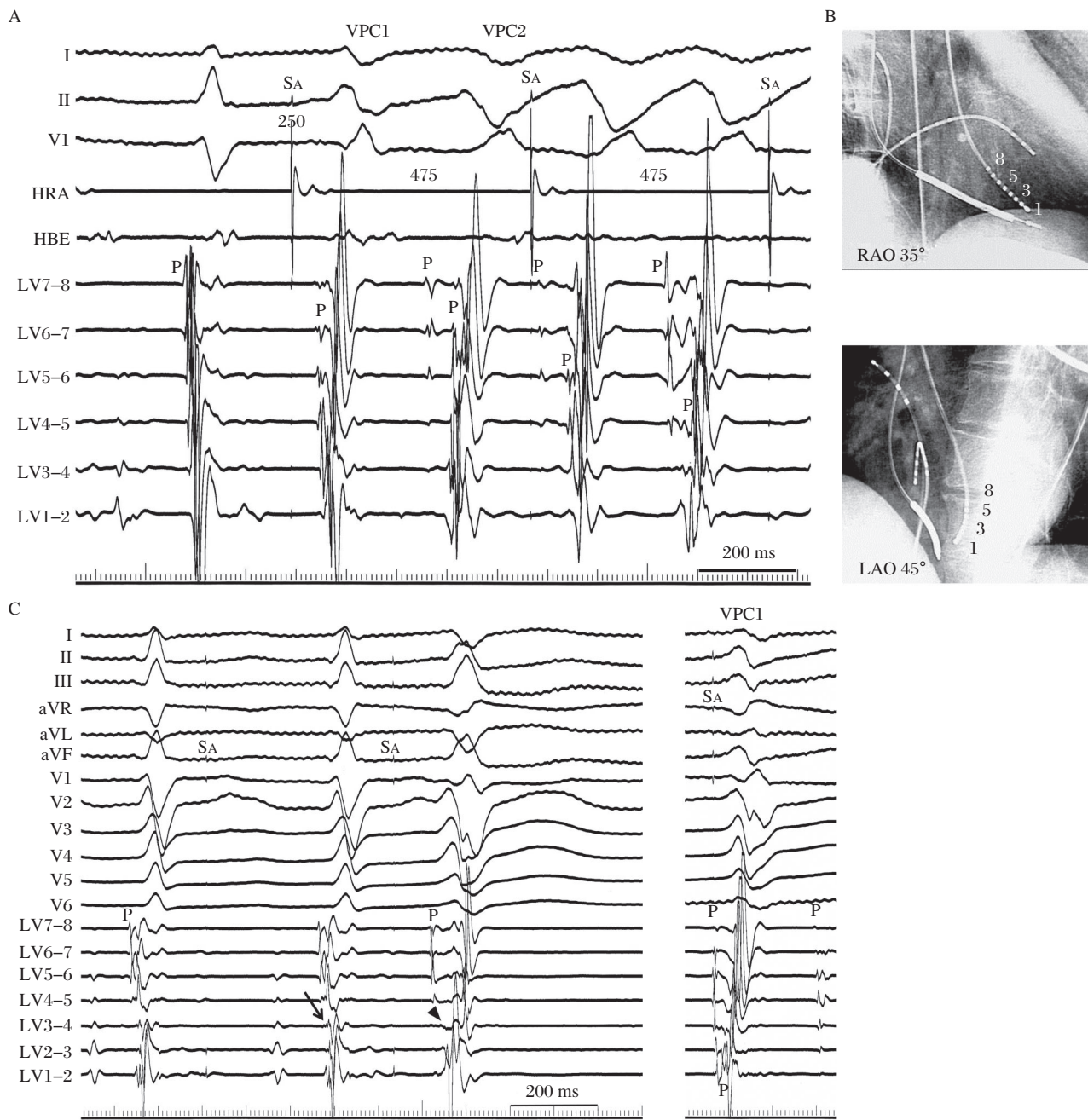
In the report by Haïssaguerre et al.<sup>(11)</sup>, electrocardiograms recorded after ablation showed the abolition of the local Purkinje potentials and a slight delay in the occurrence of the local ventricular electrogram.

However, they did not determine how much of the complex Purkinje network was involved in each patient and the issue of multiple foci versus differing activation routes from limited foci remains unsolved. In our case, catheter mapping revealed that the constantly changing polymorphic QRS morphology resulted from the changing propagation in the Purkinje arborization and the PVT became noninducible after the catheter ablation of the Purkinje network. We did not ablate the earliest site of the Purkinje activation, and the isolated VPC with diastolic Purkinje activation was still inducible after the catheter ablation.

Of course, the earliest activation site of the Purkinje activation during the triggering VPC should be sought and ablated; however, a modification of the Purkinje network might be applied when the earliest site cannot be determined or is located close to the atrio-ventricular node.

### Importance of twelve-lead recording of triggering VPCs

Recording the 12-lead ECG of the triggering event can prove invaluable in regionalizing the origin of the triggering VPC for more detailed mapping and an effort to record such a trigger should be routine. The



**Fig. 4** Catheter mapping during the PVT in a male patient with a short-coupled variant of torsade de pointes. A: During the PVT which was induced by rapid atrial pacing after the administration of intravenous cibenzoline, diastolic Purkinje potentials and presystolic Purkinje potentials were recorded from the left ventricular septum. During sinus rhythm, fused Purkinje potentials were recorded before the onset of the QRS. B: Representation of an octapolar electrode catheter placed on the left ventricular septum. C: Intracardiac electrograms recorded after ablation showing the abolition of the local Purkinje potential (P) at the middle portion and a slight delay in the occurrence of the local ventricular electrogram during sinus rhythm (arrow). The PVT became noninducible and only an isolated VPC was inducible. The morphology of this VPC differed from the previous triggering VPC1 and intra-Purkinje block was also observed before this VPC (arrowhead). HBE = His-bundle electrogram; HRA = high right atrium; LAO = left anterior oblique view; LV = left ventricle; P = Purkinje potential; RAO = right anterior oblique view; SA = atrial pacing stimulus. (From Nogami A, Sugiyasu A, Kubota S, et al. Mapping and ablation of idiopathic ventricular fibrillation from Purkinje system. *Heart Rhythm* 2005;2(6): 646–649. With permission.)<sup>[14]</sup>

target site can be speculated with the 12-lead ECG documentation; RVOT, right distal Purkinje, left posterior Purkinje, left anterior Purkinje, or right Purkinje system. In patients without ectopy during the RF abla-

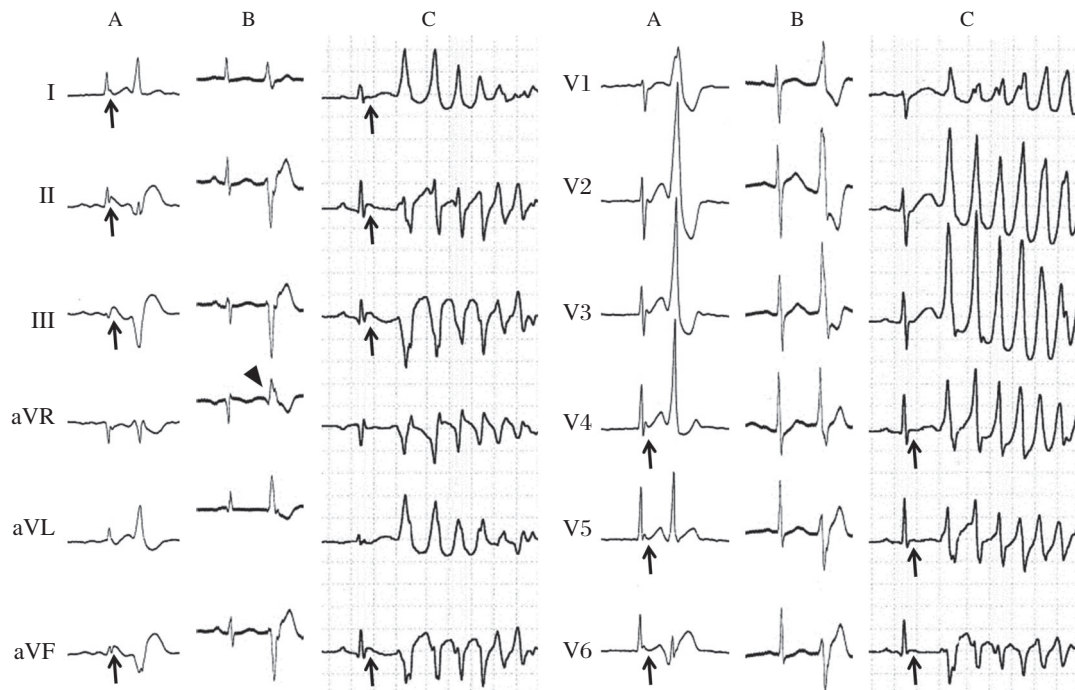
tion session, the putative source of the VPC can be ablated in sinus rhythm based on pace mapping followed by RF energy delivery. In patients with multifocal VPCs, the true triggering VPC that initiates VF, or

nonsustained PVT, has to be confirmed. It is essential that there is accurate documentation of the triggering VPC with a 12-lead ECG.

**Fig 5** shows ECGs from a 59-year-old female patient with early repolarization associated with VF<sup>[15]</sup>. Each panel shows the QRS complexes during sinus rhythm and the VPC. In the emergency room, significant J-ST elevation in the infero-lateral leads and VPC bigeminy with an RBBB configuration and superior axis were observed after the spontaneous termination of the PVT (**Fig. 5A**). One month after the implantation of an ICD, a triggering VPC ablation was performed due to frequent ICD shocks. During the ablation session, frequent monofocal VPCs were observed (**Fig. 5B**), and Purkinje potentials on the posterior left ventricular septum preceded the onset of the VPC by 65 ms. An RF energy application at that site immediately eliminated the VPC. However, a few days after the session, VF recurred. A 12-lead Holter recording could record the initiation of the VF (**Fig. 5C**). The “true” triggering VPC was similar to the ablated VPC, but different (especially lead aVR).

Interestingly, while J-ST elevation was recorded in the emergency room and during the VF recurrence, it was not observed during the ablation session. There was a possibility that the true triggering VPC appeared only during the J-ST elevation. The patient did not prefer to undergo a re-ablation session and the oral administration of disopyramide successfully suppressed the VF episode.

In the intensive care unit, a synthesized 12-lead ECG from the signals recorded using three to five electrodes is sometimes used. In our experience, the limb leads in the synthesized 12-lead ECG are similar to the Mason-Likar lead configuration, in which the limb lead electrodes are placed on the torso rather than the distal extremities and can be used for the morphology analysis of VPCs. However, the chest lead information is less useful because of its inaccuracy. Twelve-lead Holter monitoring also uses a Mason-Likar lead configuration similar to the limb leads and the real six chest electrodes for the chest leads. It appears to be highly reliable and useful for the diagnosis of “true” triggering VPCs.



**Fig. 5** Surface 12-lead ECGs from a female patient with early repolarization associated with VF. A: In the emergency room, significant J-ST elevation in the infero-lateral leads and VPC bigeminy with an RBBB configuration and superior axis were observed after the spontaneous termination of PVT. B: During the ablation session, frequent monofocal VPCs with an RBBB configuration and superior axis were observed. C: A 12-lead Holter recording could record the VF recurrence. The “true” triggering VPC is similar to the ablated VPC, but is different (especially lead aVR) (arrowhead). Interestingly, while J-ST elevation was recorded in the emergency room and during the VF recurrence (arrows), it was not observed during the ablation session. (From Nogami A. Mapping and ablating ventricular premature contractions that trigger ventricular fibrillation: Trigger elimination and substrate modification. *J Cardiovasc Electrophysiol* 2014 Sep 12. doi: 10.1111/jce.12547. [Epub ahead of print] PubMed PMID: 25216244. With permission.)<sup>[11]</sup>

## Concluding remarks

RF catheter ablation of VF is feasible and can be used as a bailout therapy for drug-refractory electrical storms. Suppression of VF can be achieved by not only the elimination of triggering VPCs, but also the creation of conduction block between the PA and RVOT, or of the Purkinje network. However, VF ablation has not yet been recognized as a Class I indication by the current guidelines<sup>[16]</sup>. Ablation is recommended as a Class IIb recommendation only for VF triggered by Purkinje system VPCs. Further studies are needed to evaluate the precise mechanisms of this arrhythmia.

## References

- [1] Haïssaguerre M, Shoda M, Jais P, et al. Mapping and ablation of idiopathic ventricular fibrillation. *Circulation* 2002;106(8): 962–967.
- [2] Lerman BB, Stein KM, Markowitz SM, et al. Ventricular arrhythmias in normal hearts. *Cardiol Clin* 2000;18(2): 265–291, vii.
- [3] Noda T, Shimizu W, Taguchi A, et al. Malignant entity of idiopathic ventricular fibrillation and polymorphic ventricular tachycardia initiated by premature extrasystoles originating from the right ventricular outflow tract. *J Am Coll Cardiol* 2005;46(7):1288–1294.
- [4] Ashida K, Kaji Y, Sasaki Y. Abolition of torsade de pointes after radiofrequency catheter ablation at right ventricular outflow tract. *Int J Cardiol* 1997;59(2):171–175.
- [5] Kusano KF, Yamamoto M, Emori T, et al. Successful catheter ablation in a patient with polymorphic ventricular tachycardia. *J Cardiovasc Electrophysiol* 2000;11(6): 682–685.
- [6] Betts TR, Yue A, Roberts PR, et al. Radiofrequency ablation of idiopathic ventricular fibrillation guided by noncontact mapping. *J Cardiovasc Electrophysiol* 2004;15(8):957–959.
- [7] Viskin S, Rosso R, Rogawski O. The “short coupled” variant of right ventricle outflow ventricular tachycardia: a not-so-benign form of benign ventricular tachycardia? *J Cardiovasc Electrophysiol* 2005;16(8):912–916.
- [8] Kurosaki K, Nogami A, Shirai Y, et al. Positive QRS complex in lead I as a malignant sign in right ventricular outflow tract tachycardia. *Circ J* 2013;77(4):968–974.
- [9] Igarashi M, Tada H, Kurosaki K, et al. Electrocardiographic Determinants of the Polymorphic QRS Morphology in Idiopathic Right Ventricular Outflow Tract Tachycardia. *J Cardiovasc Electrophysiol* 2012;23(5):521–526.
- [10] Takatsuki S, Mitamura H, Ogawa S. Catheter ablation of a monofocal premature ventricular complex triggering idiopathic ventricular fibrillation. *Heart* 2001;86(1):e3.
- [11] Nogami A: Mapping and ablating ventricular premature contractions that trigger ventricular fibrillation: Trigger elimination and substrate modification. *J Cardiovasc Electrophysiol* 2014 Sep 12. doi: 10.1111/jce.12547. [Epub ahead of print] PubMed PMID: 25216244.
- [12] Bänsch D, Oyang F, Antz M, et al. Successful catheter ablation of electrical storm after myocardial infarction. *Circulation* 2003;108(24):3011–3016.
- [13] Szumowski L, Sanders P, Walczak F, et al. Mapping and ablation of polymorphic ventricular tachycardia after myocardial infarction. *J Am Coll Cardiol* 2004;44(8): 1700–1706.
- [14] Nogami A, Sugiyasu A, Kubota S, et al. Mapping and ablation of idiopathic ventricular fibrillation from Purkinje system. *Heart Rhythm* 2005;2(6):646–649.
- [15] Haïssaguerre M, Derval N, Sacher F, et al. Sudden cardiac arrest associated with early repolarization. *N Eng J Med* 2008;358(8):2016–2023.
- [16] Zipes DP, Camm AJ, Borggrefe M, et al. ACC/AHA/ESC 2006 guidelines for management of patients with ventricular arrhythmias and the prevention of sudden cardiac death: a report of the American College of Cardiology/American Heart Association Task Force and the European Society of Cardiology Committee for Practice Guidelines (Writing Committee to Develop Guidelines for Management of Patients with Ventricular Arrhythmias and the Prevention of Sudden Cardiac Death). *Circulation*. 2006; 114(5):e385–484.