

## Pulmonary hemorrhage in dengue: differential diagnosis with acute viral respiratory syndromes including COVID-19

Leonardo Antonio Aguiar<sup>1</sup>, Ana Carolina de Moraes Oliveira-Scusiel<sup>1</sup>, Jerônimo Coelho de Menezes<sup>1</sup>, Priscila Barbosa Idaló<sup>1</sup>, Lara Élica Guazzeli de Freitas<sup>1</sup>, Luzia Beatriz Ribeiro Zago<sup>1</sup>, Cristina da Cunha Hueb Barata de Oliveira<sup>1</sup>, Naiara Clemente Tavares<sup>2</sup>, Edward José de Oliveira<sup>2</sup>, Marcos Vinícius da Silva<sup>1</sup>, Luciana de Almeida Silva Teixeira<sup>1</sup>

### ABSTRACT

Clinical similarities among viral diseases become even more relevant considering the current scenario, especially in Brazil, where there is a high incidence of these diseases and overlapping seasonality. We report the case of a patient with acute clinical manifestations composed of predominant respiratory symptoms and alveolar hemorrhage in which three etiologies (dengue, influenza and COVID-19) were investigated concomitantly. Only the diagnosis of dengue was confirmed. Then, the patient's immunological profile in response to stimulation of mononuclear cells with dengue virus antigen was analyzed in an attempt to identify specific characteristics that could be associated with the clinical manifestation.

**KEYWORDS:** Dengue. Pulmonary hemorrhage. Viral respiratory syndromes. SARS-COV-2.

### INTRODUCTION

Diffuse alveolar hemorrhage is characterized by the accumulation of intra-alveolar red blood cells that most commonly originate from the alveolar capillaries. This condition can manifest clinically in different ways, including cough, hemoptysis, dyspnea, anemia and acute respiratory failure<sup>1</sup>. Identification of the etiology of diffuse alveolar hemorrhage is always necessary as it potentially affects patient management and can prevent unfavorable outcomes. The causes can be infectious or non-infectious and both, immunodeficient and immunocompetent patients can develop this condition. In immunocompetent patients, the most common infectious causes are influenza (H1N1), dengue, leptospirosis, malaria and *Staphylococcus aureus* pneumonia<sup>1</sup>. In addition, the new coronavirus (SARS-CoV-2) infection is currently another possible cause of alveolar hemorrhage<sup>2</sup>.

Among viral etiologies, the overlapping clinical manifestations of dengue, influenza and SARS-CoV-2 infections are particularly important. The early phase of these diseases is characterized by nonspecific signs and symptoms such as fever, myalgia and headache. In dengue, pulmonary manifestations are usually mild and, when they are present, most affected patients only have upper airway symptoms. However, diffuse alveolar hemorrhage may occur in severe dengue. Influenza virus can also cause severe pulmonary involvement, including hemorrhagic bronchitis, especially in risk groups. Lung involvement by SARS-CoV-2 is potentially serious and can strongly contribute to progression to death. Post-mortem biopsies performed

<sup>1</sup>Universidade Federal do Triângulo Mineiro, Uberaba, Minas Gerais, Brazil

<sup>2</sup>Instituto René Rachou, Belo Horizonte, Minas Gerais, Brazil

**Correspondence to:** Luciana de Almeida Silva Teixeira

Universidade Federal do Triângulo Mineiro, R. Getúlio Guaritá, s/n, CEP 38025-180, Uberaba, MG, Brazil

**E-mail:** [luciana.teixeira@uftm.edu.br](mailto:luciana.teixeira@uftm.edu.br)

**Received:** 1 October 2021

**Accepted:** 10 January 2022

to elucidate the pathological effects of SARS-CoV-2 on lung parenchyma demonstrated diffuse alveolar damage that can progress to alveolar hemorrhage in more advanced cases<sup>3,4</sup>. Clinical similarity among these viral diseases become even more relevant considering the current scenario, especially in Brazil where there is a high incidence of these diseases and overlapping seasonality. We report the case of a patient with acute clinical manifestations, predominant respiratory symptoms and alveolar hemorrhage in which the three etiologies (dengue, influenza, and COVID-19) were investigated concomitantly. Only the diagnosis of dengue was confirmed. Then, the patient's immunological profile in response to stimulation of mononuclear cells with dengue virus antigen was analyzed in an attempt to identify specific characteristics that could be associated with the clinical manifestation.

## MATERIALS AND METHODS

### Clinical data, tests and blood collection

The patient sought an Emergency Department in Minas Gerais, Brazil. Clinical and laboratory parameters were obtained from the medical record. The study was approved by the Ethics Committee on Research Involving Humans of the institution (CAAE N° 34721120.3.0000.5154) and the patient agreed to participate in the study by signing the informed consent form. Afterwards, a peripheral blood sample was collected for *in vitro* antigen stimulation and evaluation of cytokine production, as described below.

### Peripheral blood mononuclear cells (PBMCs) *in vitro* stimulation with dengue virus antigen

#### *Preparation of dengue virus antigen*

Samples of different dengue virus serotypes (DENV-1 strain Mochizuki, DENV-2 strain New Guinea, DENV-3 strain H87 and DENV-4 strain BEH) were used at a final concentration of  $1 \times 10^6$  pfu/mL. DENV antigen stock solutions were prepared as previously described, with modifications (Kurane *et al.*<sup>5</sup>). Briefly, cell culture flasks containing  $3 \times 10^6$  Vero cells in 5% RPMI (Gibco, Thermo Fisher Scientific, Waltham, MA, USA) were prepared for each viral serotype and cultured in a humidified incubator at 37 °C in 5% CO<sub>2</sub>. After 48 h, 100 µL of each virus serotype were inoculated into the respective culture flask and allowed to adsorb for 1 h. Next, 5% RPMI medium was added to the flasks and the cultures were incubated at 37 °C in 5% CO<sub>2</sub> for 7 days and observed daily under an inverted microscope to monitor the development of cytopathic effects (presence of cellular syncytium) resulting from dengue virus infection.

After this period, the flasks were washed with sterile PBS and 2.5 mL trypsin were added for 3 min for cell lysis and release of viral particles. The suspension was centrifuged at 400 ×g for 10 min at 4 °C. Then, supernatants were transferred, 20% fetal bovine serum was added, and the antigen solutions were stored at -80 °C until the time of use. All DENV-1, 2, 3 and 4 stock solutions were inactivated for 1 h at 60 °C before use.

#### *Separation of peripheral blood mononuclear cells (PBMCs)*

Peripheral blood samples were collected by venipuncture into heparinized tubes. The PBMCs were isolated on a Ficoll-Hypaque density gradient (GE Healthcare, Uppsala, Sweden) by centrifugation at 400 ×g for 30 min at 21 °C. Then, cells were re-suspended in RPMI 1640 medium (GE) containing 5% inactivated fetal bovine serum (Gibco), at a final concentration of  $2 \times 10^6$  cells/mL.

#### *Culture of PBMCs*

For culture, PBMCs ( $1 \times 10^6$  cells) were re-suspended in RPMI medium and added to 48-well culture plates (Corning, New York, USA). The cells were stimulated in the presence or absence of 2.5 µL viral antigen (DENV 1-4). Thereafter, cells were incubated for 5 days at 37 °C in 5% CO<sub>2</sub>. These culture supernatants were then collected and stored at -80 °C for subsequent cytokine measurement.

#### *Determination of cytokines in serum and PBMC culture supernatants*

Cytokines IL-1β, IL-4, IL-6, IL-8, IL-10, IL-17, IFN-γ and TNF-α were quantified by flow cytometry using the BD Cytometric Bead Array (CBA) Human Th1/Th2/Th17 and Inflammatory Cytokine Kit (BD Bioscience Pharmingen, San Diego, USA). Then, data were analyzed using the FCAP Array 2.0 software (SoftFlow Ltda., Pécs, Hungary) and the cytokine concentrations were calculated and compared to a standard curve. Data were expressed as pg/mL, and the graph was assembled with the GraphPad Prism 7.0 software (GraphPad, San Diego, CA, USA).

#### *RNA extraction, reverse transcription and in house RT-qPCR*

#### *Extraction of total RNA*

Total RNA was extracted from two serum samples collected on days 8 and 11 after the onset of symptoms, using the QIAamp Viral RNA Mini Kit (QIAGEN GmbH, Hilden, Germany), following the manufacturer's instructions.

### Reverse transcription

10 µL of total RNA from each serum sample were added to 10 µL of RT master mix (2.0 µL of 10 × RT Buffer; 0.8 µL of 25 × dNTP Mix (100 mM); 2.0 µL of 10 × RT Random Primers; 1.0 µL of MultiScribe™ Reverse Transcriptase 1.0 and 4.2 µL of Nuclease-free H<sub>2</sub>O) from the High-Capacity cDNA Reverse Transcription Kit. The preparations were submitted to incubation at 25 °C by 10 min, 37 °C by 2 h, 85 °C by 5 min and were cooled at 4 °C.

The qPCR assay: amplifications were carried out in a final volume of 10 µL, using primers and probes that amplify the four DENV serotypes. The assays were prepared with 5 µL of TaqMan® Universal PCR Master Mix (Life Technologies, Thermo Fisher Scientific, Waltham, MA, USA), specific primers at 0.1 µM, the probe at 0.1 µM and 2 µL of cDNA. In addition, two controls were used for each amplification, a positive control (PCR mix plus DENV cDNA) and a negative control consisting of RT-qPCR mix (no template control). The assays were performed in triplicate using microplates (MicroAmp® Fast Optical/Applied Biosystems, Foster City, CA, USA), sealed with adhesive film (Optical Adhesive Covers, Applied Biosystems) on the ViiA™ 7 Real-Time PCR System (Thermo Fisher Scientific, Waltham, MA, USA) and amplified by an universal cycling program composed of 40 cycles and an annealing temperature of 60 °C.

## RESULTS

### Case report

A 62-year-old male patient from Minas Gerais State, Brazil, presented with a 7-day history of mild myalgia, headache and arthralgia. The patient developed diffuse petechiae and purpura on the fourth day, especially on the upper and lower limbs, accompanied by enanthema in the buccal mucosa and gingival bleeding on the sixth day. As a morbid condition, the patient had systemic arterial hypertension that was treated with losartan 50 mg a day.

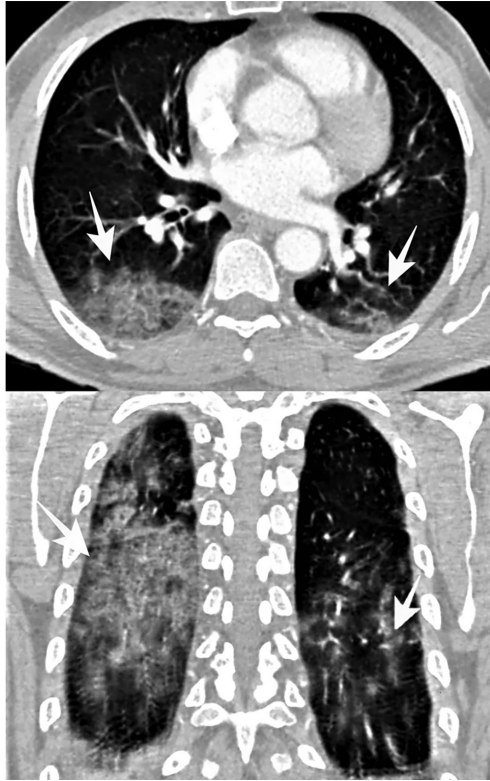The patient was admitted in April 2, 2020 to the Emergency room of the Hospital in regular general condition, conscious and oriented, hydrated, normal colored, anicteric, acyanotic, afebrile, without edema. He had petechiae on the face, chest, upper and lower limbs, a slight bleeding in the cheek mucosa and 96% of saturation in ambient air. Laboratory tests on admission showed intense thrombocytopenia (platelets 1,000/mm<sup>3</sup>) in the absence of other important alterations (red blood cells: 4.24 × 10<sup>9</sup>/mm<sup>3</sup>; hemoglobin: 13.3 g/dL; hematocrit: 36.5%; leukocytes: 6,200/mm<sup>3</sup>; neutrophils: 74%; eosinophils: 1%; lymphocytes: 19%; monocytes: 6%; urea: 14 mg/dL;

creatinine: 0.7 mg/dL; AST: 17 U/L; ALT: 10 U/L; alkaline phosphatase: 61 U/L; gamma-GT: 17 U/L; LDH: 233 U/L; total protein: 6.0 g/dL; albumin: 3.5 g/dL; fibrinogen: 403 mg/dL; prothrombin activity: 100%; INR: 1; aPTT (patient/control ratio): 1.26; vitamin B12: 329 pg/mL; TSH: 1.668 mIU/L; free T4: 1.040 ng/dL; folic acid: 6.3 ng/mL; HBsAg: non-reactive; anti-HBs: reactive; anti-HCV: non-reactive; VDRL: non-reactive; anti-HIV 1 and 2: non-reactive; ANA HEP-2: non-reactive; rheumatoid factor: 10.5 IU/mL. Abdominal ultrasonography and chest radiography showed no alterations.

The initial suspicion was dengue and a combined assessment by the Infectology and Hematology teams was defined. Based on the patient's clinical and laboratory presentation, a platelet transfusion was given and thrombocytopenic purpura triggered or not by an infectious process was suspected. Considering the initial absence of a defined etiology, as well as the patient's hemodynamic stability, the patient received no additional treatments for purpura.

By the second day of hospitalization, the patient exhibited fever spikes and developed cough, hemoptoic sputum, gingival bleeding and epistaxis. Saturation remained above 95% and hemodynamic stability was maintained. The laboratory tests revealed worsening of thrombocytopenia despite transfusions (platelets 0/mm<sup>3</sup>) and the chest computed tomography showed ground-glass opacities in both lungs suggestive of alveolar hemorrhage (Figure 1). The other tests remained without further significant changes and there was no evidence of hemoconcentration in any of the blood counts. Intravenous human immunoglobulin, corticotherapy (prednisone) and antibiotics (ceftriaxone and clarithromycin) were added to the therapeutic management. The list of diagnostic hypotheses was expanded and the investigation included RT-PCR for influenza and other hemorrhagic fevers. During this period, our hospital had limited capacity for the routine molecular investigation of COVID-19. Thus, the hypothesis of COVID-19 was investigated 10 days after the onset of symptoms by a rapid test (IgM and IgG) and subsequently by IgM and IgG serology. The results of these specific tests were negative for influenza A and B, yellow fever, COVID-19 IgM and IgG (rapid test) and COVID-19 IgM and IgG (serology). The only positive results in two different samples was MAC-ELISA for dengue, with reactive IgM and a RT-qPCR that detected dengue virus (Table 1).

Progressive clinical improvement and remission of bleeding started on day 10 of hospitalization. The patient was discharged on day 13 after admission (20 days after the onset of symptoms) with a platelet count of 103,000/mm<sup>3</sup>. Thereafter, outpatient reassessments showed the complete



**Figure 1** - Chest tomography scans obtained on the second day of hospitalization, showing ground glass opacities (white arrows) in both lungs, suggestive of alveolar hemorrhage.

remission of symptoms and normalization of laboratory parameters.

**Cytokines in serum samples**

The measurement of cytokines from the patient’s serum samples during the acute phase of the disease showed a low concentration of all cytokines. IL-1 $\beta$  was not detectable and the levels of IL-4, IL-17, IFN- $\gamma$ , IL-10, TNF, IL-6 and IL-8 were 0.29, 0.39, 0.68, 1.06, 2.68, 4.98 and 6.99 pg/mL, respectively. Therefore, there was a predominance of proinflammatory cytokines IL-8 and IL-6.

**In vitro antigen response**

We evaluated the response of PBMCs stimulated with antigens of different dengue virus serotypes and also with anti-CD3/anti-CD28 ( $\alpha$ CD3/ $\alpha$ CD28), a polyclonal lymphocyte activator. The results showed an increase in the production of all cytokines evaluated after the polyclonal stimulation, indicating a preserved function of the lymphocyte reservoir. Regarding the antigen-induced response, there was a substantial increase in the production of proinflammatory cytokines such as IL 1 $\beta$  and IL-8, while there was a reduction in IL-10 and TNF- $\alpha$  when compared

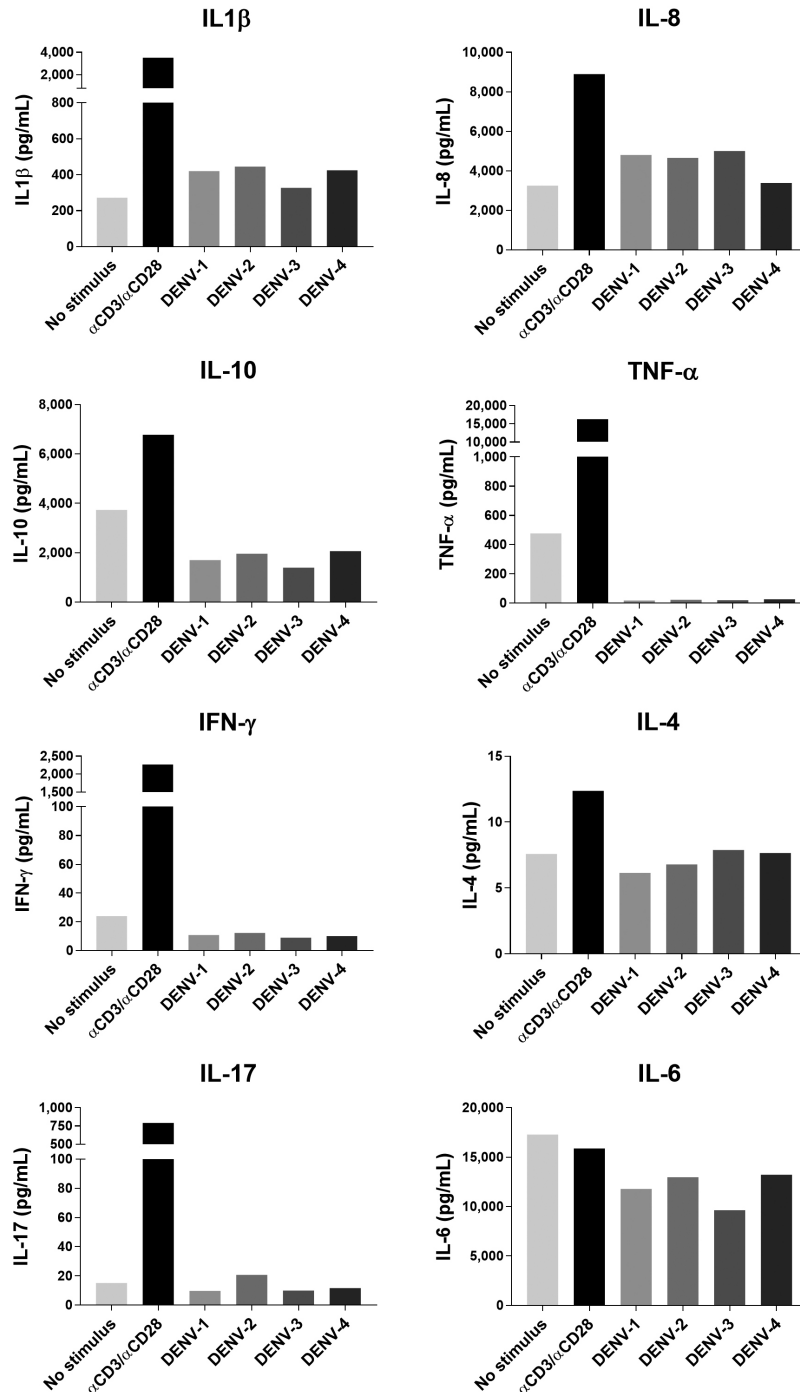
**Table 1** - Diagnostic tests performed in this case report.

Etiological agent	Diagnostic Test	Symptoms (day)	Results	Test information (laboratory)
Dengue	RT-qPCR	8 and 11	Detected	RT-qPCR <i>in house</i> (IRR/Fiocruz, Belo Horizonte, MG)
	MAC-ELISA	8	Positive D.O./C.O.: 12.570 U Cut-off: 8.5U	Kit Novagnost (FUNED, Belo Horizonte, MG)
		11	Positive D.O.: 0.400 Cut-off: 0.200	MAC-ELISA CDC Protocol (FUNED, Belo Horizonte, MG)
	Rapid test cassette IgM/IgG	11	Negative	VIDA Biotecnologia® kit (UFTM, Uberaba, MG)
SARS-CoV-2	Chemiluminescence immunoassay (IgM/IgG anti S-Spike)	20	Negative IgG: 4.8 Cut-off: 33.8 IgM: 0.7 Cut-off: 1.1	LIAISON SARS-CoV-2 DiaSorin® kit (Laboratório Sabin®, Uberaba, MG)
Influenza A and B	Real time RT-PCR	8	Undetected	Influenza A e B Protocol CDC (FUNED/Belo Horizonte, MG)
Respiratory Syncytial Virus	Real time RT-PCR	8	Undetected	Respiratory Viruses Protocol CDC (FUNED, Belo Horizonte, MG)
Yellow Fever	MAC-ELISA	8	Negative DO: 0.112 Cut-off: 0.300	Yellow Fever Protocol CDC (FUNED, Belo Horizonte, MG)

to non-stimulated cells with dengue virus antigens. No difference in the production of IFN- $\gamma$ , IL-4, IL-17 or IL-6 was observed between stimulated and non-stimulated cells. The response to the viral antigens was very similar regardless of the serotype, and the homogeneity of antigen components and of the immunological repertoire were observed (Figure 2).

## DISCUSSION

Dengue is a disease whose public health importance is growing, considering its incidence, associated morbidity and mortality and economic impact. Pulmonary hemorrhage is uncommon in patients with dengue, with few reports in the literature. Furthermore, dengue is important as a



**Figure 2** - Levels (pg/mL) of IL-1 $\beta$ , IL-4, IL-6, IL-8, IL-10, IL-17, IFN- $\gamma$  and TNF- $\alpha$  produced by the patient's PBMCs stimulated or not with  $\alpha$ CD3/ $\alpha$ CD28 or with viral antigen (DENV 1-4). Cytokines were quantified by flow cytometry using the BD Cytometric Bead Array (CBA) Human Th1/Th2/Th17 and Inflammatory Cytokine Kit (BD Bioscience Pharmingen, San DiegoCA, USA).



differential diagnosis with other acute viral respiratory syndromes such as influenza and COVID-19.

We found two case reports of pulmonary hemorrhage in patients with dengue<sup>6,7</sup>. In cases of thrombocytopenic purpura, the first therapeutic option is high-dose corticoid pulse therapy (40 mg dexamethasone/day for 4 days) and if there is no response, immunoglobulin is used. As the patient had dengue fever accompanied by severe manifestations compatible with pulmonary hemorrhage, it was decided to administer 1 mg/kg of immunoglobulin and prednisone, in agreement with the experience in the literature<sup>8</sup>. However, controversy exists regarding the indication of corticosteroids in patients with dengue, with some studies reporting a lack of efficacy<sup>9</sup>.

Severe manifestations of dengue virus infection such as hemorrhagic fever are associated with an aggressive inflammatory response in which the simultaneous release of high levels of proinflammatory cytokines causes a “cytokine storm”. This event increases vascular permeability accompanied by plasma extravasation<sup>10-12</sup>. Many proinflammatory cytokines such as IL-6, IL-1 $\beta$  and IL-8 and immunosuppressive cytokines such as IL-10 are elevated in dengue infection and are associated with the severity of clinical disease<sup>10</sup>. The present patient exhibited a substantial increase in the production of proinflammatory cytokines IL-1 $\beta$  and IL-8 and, at the same time, a reduction of IL-10 and TNF- $\alpha$ . This IL-10 reduction may be associated with exacerbation of the inflammatory response, favoring the expression of a severe form such as pulmonary hemorrhage.

Imad *et al.*<sup>13</sup> demonstrated that, during the acute phase of dengue infection, patients with bleeding had significantly higher levels of IL-8 compared to patients without bleeding. In addition, among patients with dengue hemorrhagic fever (DHF), during the acute phase, the levels of IL-8 and IL-6 were significantly higher in DHF grade II–IV patients than in DHF grade I patients. Therefore, the cytokines IL-6 and IL-8 can be markers of severity of dengue infection, including bleeding, and in this study the result of the patient’s serum cytokine showed the same profile.

Given the current situation in Brazil, this case report alerts to the differential etiological diagnosis of pulmonary clinical manifestations. In fact, COVID-19 has drawn more attention to this issue because of the expressiveness and potential severity of its pulmonary manifestations, which are responsible for the large number of deaths due to COVID-19. In this context, in addition to the individual expression of dengue and COVID-19, the possibility of coinfection is also a matter of concern. Coinfection cases have been reported in the literature. Carosela *et al.*<sup>14</sup> described 13 patients with COVID-19 and dengue; most patients were young (mean 37 years) and 54% were males. All patients had febrile illness

on admission, with an average of 7 days and headache was the most prevalent symptom. In a study carried out in Singapore, the differentiation between COVID-19 and dengue was made on the basis of higher lymphocyte counts that were predictive of COVID-19, patients with cough and higher platelet counts were at increased risk of COVID-19, while headache, joint pain, skin rash and vomiting/nausea were more indicative of dengue<sup>15</sup>. According to Henrina *et al.*<sup>16</sup>, similar to COVID-19, the hallmark of dengue hemorrhagic fever is the endothelial dysfunction. The three main pathophysiological mechanisms, which are T cell immunology, antibody-dependent enhancement (ADE) of the virus and complement factors activation are attributed to the resulting aberrant immunological response.

Henrina *et al.*<sup>16</sup> also highlighted the possibility of serological cross-reactivity between the two diseases, a fact that may contribute to a misdiagnosis. In the present study, the patient had a negative serological test for COVID-19 using an anti-spike protein chemiluminescence assay. However, some studies have shown that serology for COVID-19 can exhibit cross-reactivity with dengue even when protein S is used<sup>17,18</sup>. On the other hand, in the initial phase of both diseases, in which viremia peaks, the RT-PCR diagnostic tests for COVID-19 and the NS1 detection for dengue diagnosis have been identified as tools with good discriminatory capacity between these diseases<sup>19,20</sup>.

## CONCLUSION

This study reports the case of a patient with dengue whose clinical presentation with pulmonary hemorrhage highlighted the difficulty of differentiating dengue from COVID-19. The inflammatory response mainly mediated by IL-1 $\beta$  and IL-8, with a reduction of IL-10 and TNF- $\alpha$ , seems to participate in this clinical manifestation. Prospective studies including patients with acute pulmonary symptoms who live in endemic areas where the two infections coexist are needed to further elucidate the diagnosis and immunological implications associated with the diversity of manifestations.

## FUNDING

This study was supported by FAPEMIG REDE Mineira, process N° 0313-16.

## REFERENCES

1. von Ranke FM, Zanetti G, Hochhegger B, Marchiori E. Infectious diseases causing diffuse alveolar hemorrhage in immunocompetent patients: a state-of-the-art review. *Lung*. 2013;191:9-18.

2. Tian S, Xiong Y, Liu H, Niu L, Guo J, Liao M, et al. Pathological study of the 2019 novel coronavirus disease (COVID-19) through postmortem core biopsies. *Mod Pathol*. 2020;33:1007-14.
3. Almeida RR, Paim B, Oliveira SA, Souza Jr AS, Gomes AC, Escuissato DL, et al. Dengue hemorrhagic fever: a state-of-the-art review focused in pulmonary involvement. *Lung*. 2017;195:389-95.
4. Taubenberger JK, Morens DM. The pathology of influenza virus infections. *Annu Rev Pathol*. 2008;3:499-522.
5. Kurane I, Innis BL, Nisalak A, Hoke C, Nimmannitya S, Meager A, et al. Human T cell responses to dengue virus antigens: proliferative responses and interferon gamma production. *J Clin Invest*. 1989;83:506-13.
6. Marchiori E, Ferreira JL, Bittencourt CN, Araujo Neto CA, Zanetti G, Mano CM, et al. Pulmonary hemorrhage syndrome associated with dengue fever, high-resolution computed tomography findings: a case report. *Orphanet J Rare Dis*. 2009;4:8.
7. Marchiori E, von Ranke F, Zanetti G, Hochegger B. Dengue hemorrhagic fever: another cause of diffuse alveolar hemorrhage in immunocompetent patients. *Respir Med*. 2012;106:1807-8.
8. Tejo AM, Dias NB, Inácio MV, Del Tedesco Jr. WL. Púrpura trombocitopênica imune associada a infecção pelo vírus da dengue. *Brazilian J Infect Dis*. 2021;25 Suppl 1:101078.
9. Kularatne SA, Walathara C, Mahindawansa SI, Wijesinghe S, Pathirage MM, Kumarasiri PV, et al. Efficacy of low dose dexamethasone in severe thrombocytopenia caused by dengue fever: a placebo controlled study. *Postgrad Med J*. 2009;85:525-9.
10. Dayarathna S, Jeewandara C, Gomes L, Somathilaka G, Jayathilaka D, Vimalachandran V, et al. Similarities and differences between the 'cytokine storms' in acute dengue and COVID-19. *Sci Rep*. 2020;10:19839.
11. Kuczera D, Assolini JP, Tomiotto-Pellissier F, Pavanelli WR, Silveira GF. Highlights for dengue immunopathogenesis: antibody-dependent enhancement, cytokine storm, and beyond. *J Interf Cytokine Res*. 2018;38:69-80.
12. Malavige GN, Huang LC, Salimi M, Gomes L, Jayaratne SD, Ogg GS. Cellular and cytokine correlates of severe dengue infection. *PLoS One*. 2012;7:e50387.
13. Imad HA, Phumratanaprapin W, Phonrat B, Chotivanich K, Charunwatthana P, Muangnoicharoen S, et al. Cytokine expression in dengue fever and dengue hemorrhagic fever patients with bleeding and severe hepatitis. *Am J Trop Med Hyg*. 2020;102:943-50.
14. Carosella LM, Pryluka D, Maranzana A, Barcan L, Cuini R, Freuler C, et al. Characteristics of patients co-infected with severe acute respiratory syndrome Coronavirus 2 and dengue virus, Buenos Aires, Argentina, March–June 2020. *Emerg Infect Dis*. 2021;27:348-51.
15. Thein TL, Ang LW, Young BE, Chen MI, Leo YS, Lye DC. Differentiating coronavirus disease 2019 (COVID-19) from influenza and dengue. *Sci Rep*. 2021;11:19713.
16. Henrina J, Putra IC, Lawrensia S, Handoyono QF, Cahyadi A. Coronavirus disease of 2019: a mimicker of dengue infection? *SN Compr Clin Med*. 2020 In Press.
17. Lustig Y, Keler S, Kolodny R, Ben-Tal N, Atias-Varon D, Shlush E, et al. Potential antigenic cross-reactivity between severe acute respiratory syndrome Coronavirus 2 (SARS-CoV-2) and dengue viruses. *Clin Infect Dis*. 2021;73:e2444-9.
18. Harapan H, Ryan M, Yohan B, Abidin RS, Nainu F, Rakib A, et al. Covid-19 and dengue: double punches for dengue-endemic countries in Asia. *Rev Med Virol*. 2021;31:e2161.
19. Lokida D, Lukman N, Salim G, Butar-Butar DP, Kosasih H, Wulan WN, et al. Diagnosis of COVID-19 in a dengue-endemic area. *Am J Trop Med Hyg*. 2020;103:1220-2.
20. Stringari LL, Souza MN, Medeiros Junior NF, Goulart JP, Giuberti C, Dietze R, et al. Covert cases of severe acute respiratory syndrome Coronavirus 2: an obscure but present danger in regions endemic for dengue and Chikungunya viruses. *PLoS One*. 2021;16:e0244937.