

Colectomy for porto-systemic encephalopathy: is it still topical?

Rym Ennaifer,¹ Romdhane Hayfa,¹
Rania Hefaiedh,¹ Lobna Marsaoui,²
Najet Bel Hadj,¹ Tahar Khalfallah²

¹Department of Hepato-gastro-enterology;

²Department of Surgery, Mongi Slim
Universitary Hospital, Tunis, Tunisia

Abstract

Hepatic encephalopathy (HE) is a common long term complication of porto-systemic shunt. We report herein the case of a 59-year-old man with Child-Pugh A cirrhosis treated successfully 9 years earlier with distal splenorenal shunt for uncontrolled variceal bleeding. In the last year, he developed a severe and persistent hepatic encephalopathy secondary to the shunt, which was resistant to medical therapy. As liver transplantation was not available and obliteration of the shunt was hazardous, we performed subtotal colectomy in order to reduce ammonia production. This therapeutic option proved successful, as the grade of encephalopathy decreased and the patient improved. Our experience indicates that colonic exclusion should be considered as an option in the management of HE refractory to medical treatment in highly selected patients when liver transplantation is not available or even as a bridge given the long waiting time on lists.

Introduction

The treatment options for the patient with variceal bleeding and portal hypertension have changed dramatically during the past decade.¹ Refinement in endoscopic and pharmacological therapies, and more recently, the development of transjugular intrahepatic portosystemic shunt (TIPS) led to a decreased number of patients treated with surgical shunt procedures.¹ However, selective porto-systemic shunting, especially distal splenorenal shunt (DSRS) can be considered for patients with relative preservation of hepatic function, this later is associated with decreased hepatic encephalopathy (HE) and improved survival relative to less selective shunt.² Nevertheless, in the long term complications, HE occurs in 9-15%, sometimes refractory to medical treatment.^{1,2} In these cases, modifying porto-systemic shunts are the main therapeutic procedures.³ Surgical options directed towards the reduction of ammonia production are less common.

We report the case of a man with persistent and severe HE following DSRS treated with colectomy.

Case Report

A 59-year-old man, was diagnosed as having cirrhosis of unknown etiology since 1993. Viral serology and auto-antibodies were negative. There was neither iron overload, nor alcohol consumption, nor signs of metabolic syndrome. Copper tests were normal. He had 3 episodes of esophageal bleeding between 1993 and 2003 treated successfully with sclerotherapy. The Child-Pugh score was A.

In 2003, he had an uncontrolled variceal bleeding refractory to medical and endoscopic therapy. As TIPS was not available, salvage therapy with DSRS was performed in emergency. There was no post-operative complications. Until 2010, he had no recurrent variceal bleeding, no HE and no ascites.

In 2010, he developed a slight tremor of the upper extremities, predominating on the right, but he did not consult.

One year later, he presented recurrent episodes of agitation, disorientation, amnesia, stupor and slurred speech. Physical examination disclosed asymmetrical tremor predominating on the right and temporo-spatial disorientation. There was neither focal deficit, nor extra-pyramidal rigidity, nor muscular incoordination. Biochemical analysis revealed normal glycemia and renal function, absence of severe liver dysfunction, no thyroidal disorders, no hypoxia. Ammonemia was not available in our unit. Cerebral computed tomography (CT) scan showed no abnormalities whereas magnetic resonance (MR) disclosed hyperintensity of the globus pallidus on T1 (Figure 1). Electroencephalogram demonstrated slowing of alpha rhythm. abdominal doppler ultrasound and CT scan showed patency of the spleno-renal shunt, partial portal thrombosis, no signs of hepato-cellular carcinoma.

This picture led to the diagnosis of HE associated with porto-systemic shunt. Treatment with lactulose and rifaximin allowed transient resolution of disorientation but tremor persisted. Anticoagulation for portal thrombosis was not effective and dangerous because of mistakes in doses.

A few weeks later, he presented recurrent episodes of gross disorientation, ideo-motor apraxia and loss of consciousness requiring repeated admissions in intensive care unit. He never became free from symptoms. Lactulose, rifaximin and flumazenil allowed only temporary improvement.

We were in front of a persistent and severe HE refractory to medical therapy. The risk of rebleeding after reduction of the shunt was

Correspondence: Rym Ennaifer, Department of Hepato-gastro-enterology, Mongi Slim University Hospital, Tunis, Tunisia.
Tel. +216.22.764.106 - Fax. +216.70.938.616.
E-mail: rym.ennaifer@yahoo.fr

Key words: hepatic encephalopathy, porto-systemic shunt, distal splenorenal shunt, ammonia, colectomy.

Conflict of interests: the authors declare no potential conflict of interests.

Received for publication: 17 September 2012.

Revision received: 22 November 2012.

Accepted for publication: 6 December 2012.

Conflict of interest: the authors declare no potential conflicts of interest.

This work is licensed under a Creative Commons Attribution NonCommercial 3.0 License (CC BY-NC 3.0).

©Copyright R. Ennaifer et al., 2013
Licensee PAGEPress, Italy
Clinics and Practice 2013; 3:e4
doi:10.4081/cp.2013.e4

obvious, hepatic transplantation was not available, so we performed a subtotal colectomy with ileo-rectal anastomosis in order to reduce ammonia production. The patient was operated by laparotomy, without intra-operative bleeding. Post-operative course was uneventful, in particular, no postoperative ascites and no need for transfusion. Neurological examination disclosed normal consciousness, intellectual function and behavior while a slight tremor persisted in the right hand. Ten days after the operation, the patient was able to be discharged home.

In the follow-up, 17 months later, he was still improved, keeping only the slight tremor of the right hand, and liver function did not worsen. He did not have a recurrence of disorientation, intellectual function and behavior remained normal.

Discussion

HE is a well recognized long term complication after a porto-systemic shunt, with a rate about 28%.⁴ The DSRS provides selective decompression of gastroesophageal varices, with maintenance of portal hypertension and hepatopetal flow.⁵ By preserving hepatopetal flow, the DSRS may delay and prevent HE associated with less selective shunt. However, its selectivity is neither uniform nor durable, and prevalence of HE in the long term has been reported in 9-15% of cases.^{1,2,6}

HE is a neuropsychiatric syndrome due to hepatic dysfunction and porto-systemic shunting. Clinical manifestations may vary widely and there are several other differential diagnoses for the development of cognitive dysfunction in cirrhotics, especially intra-cranial events, electrolytes abnormalities and sepsis.^{3,7,8} In some cases, neurological manifestations are unusual, as for our patient, because tremor was asymmetrical, we had to exclude other causes of focal neurological signs. The best option in patients with complex neurological manifestation is to exclude alternatives diagnoses, obtain a psychiatric and neurological consultation, and then perform MR imaging.⁸ Indeed, in HE, deposition of paramagnetic substances in the basal ganglia causes a high signal intensity on T1 weighted imaging, characteristically at the globus pallidus, as for our patient. The absence of the T1 intensity in a patient with cirrhosis and neurological manifestations suggest that they are not related to HE.⁸ For our patient, diagnosis of HE was confirmed by MR and electroencephalogram which detected abnormalities characteristic present in HE.

Many factors have been implicated in the development of HE, including ammonia and other intestinal neurotoxins and alteration in neurotransmission. Ammonia produced in the colon by intestinal bacteria is the main toxic substance implicated.³ Therefore, therapeutic options for HE directed towards the reduction of ammonia production are the most commonly used, followed by action on neurotransmission and modifying porto-systemic collaterals.^{3,9} Particularly, in cases of chronic HE post-porto-systemic shunt, reduction or obliteration of the shunt by surgery or angiographic techniques are therapeutic options.^{10,11} In all cases, liver transplantation should be evaluated and remains the most radical therapy.^{3,9} However, colonic exclusion is a possibility reported earlier with good results in selected patients.³ As far back as the sixties, treatment of HE by exclusion or total resection of the colon has already been successfully reported.^{12,13} While brief, other reports after the hepatic transplantation era showed similar good results.^{14,15}

Our patient had persistent HE resistant to medical therapy, obliteration of the shunt was associated with an increased risk of rebleeding and liver transplantation was not available. So we choose colectomy, which improved HE. Notwithstanding, secondary bacterial colonization of the remaining intestine may lead to recurrence of increased ammonia levels. Moreover, major abdominal surgery remains a challenge in patients with cirrhosis, associat-

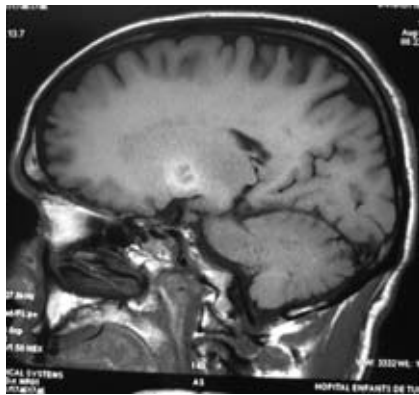


Figure 1. Cerebral magnetic resonance showing hyperintensity of the globus pallidus on T1.

ed with high morbidity and mortality rates, notably greater risk of bleeding, infection and ascites.^{16,17} In the mean time, it is known that portosystemic shunt, whether concomitant, whether preliminary, improves the prognosis of abdominal surgery in these patients.¹⁶ We believe that the portosystemic shunt and low Child-Pugh score of our patient may have facilitated surgery and improved post-operative outcome.

Finally, at this present time, 17 months after colectomy, we can think that colonic exclusion is an option to consider for the management of HE refractory to medical therapy in Child-Pugh A cirrhosis in the absence of liver transplantation or as a bridge to transplantation given the long waiting time on lists.

Conclusions

Colonic exclusion should be considered as an option in the management of HE refractory to medical treatment in highly selected patients, when liver transplantation is unavailable or delayed due to long waiting lists.

References

1. Jenkins RL, Gedaly R, Pomposelli JJ, et al. Distal splenorenal shunt. *Arch Surg* 1999; 134:416-20.
2. Livingstone AS, Koniaris L, Perez EA, et al. 507 Warren-Zeppa distal splenorenal

shunts. *Ann Surg*, 2006;243:884-94.

3. Mas A. Hepatic encephalopathy: from pathophysiology to treatment. *Digestion* 2006;73:86-93.
4. Rikkers LF, Sorrel WT, Jin G. Which portosystemic shunt is best? *Gastroenterol Clin North Am* 1992;21:179-96.
5. Henderson JM. The distal splenorenal shunt. *Surg Clin North Am* 1990;70:405-23.
6. Gusberg RJ. Distal splenorenal shunt: premise, perspective, practice. *Dig Dis* 1992;10:84-93.
7. Quero Guillen JC, Herrerias Gutierrez JM. Diagnosis methods in hepatic encephalopathy. *Clinica Chimica Acta* 2006;365:1-8.
8. Cordoba J. New assessment of hepatic encephalopathy. *J Hepatol* 2011;54:1030-40.
9. Bajaj JS. The modern management of hepatic encephalopathy. *Aliment Pharmacol Ther* 2010;31:537-47.
10. Matake K, Tajima T, Yoshimitsu K, et al. Hepatic encephalopathy from dual splenorenal shunts treated with balloon-occluded retrograde transvenous obliteration by using a double-balloon technique. *J Vasc Interv Radiol* 2007;18:1436-40.
11. Uflacker R, d'Albuquerque LA, de Oliveira e Silva A, et al. Embolization to reverse severe recurrent hepatic encephalopathy. *Arq Gastroenterol* 1988;25:21-5.
12. Leger L, Fourestier M, D Etrie P, Neveux JY. Treatment of porto-caval encephalopathy by exclusion or total resection of the colon. *Presse Med* 1963;71:2181-4.
13. Singer H, Harrison AW, Aggett PW. The treatment of hepatic encephalopathy by colectomy: case report and review of the literature. *Can Med Assoc J* 1965;93:954-6.
14. Dagenais MH, Bernard D, Marleau D, et al. Surgical treatment of severe postshunt hepatic encephalopathy. *World J Surg* 1991;15:109-13.
15. Hebbard GS, Jenney AW, Gibson PR, et al. Chronic hepatic encephalopathy following portacaval shunt: management by loop ileostomy. *Aust N Z J Surg* 1993;63:231-4.
16. Azoulay D, Buabse F, Damiano I, et al. Neoadjuvant transjugular intrahepatic portosystemic shunt: a solution for extrahepatic abdominal operation in cirrhotic patients with severe portal hypertension. *J Am Coll Surg* 2001;193:46-51.
17. Goletti O, Battini A, Capria A, et al. Laparoscopic left hemicolectomy in a patient with cirrhosis scheduled for liver transplantation. *Surg Endosc* 2003;17:834.