

Technique for All-Inside Repair of Bucket-Handle Meniscus Tears



Wen Loong Paul Yuen, M.B.B.S., M.R.C.S.,
Chung Liang Kuo, M.B.B.S., F.R.C.S. (Tr & Ortho),
Keng Meng Jeremy Goh, M.B.B.S., M.R.C.S., and
Yee Han Dave Lee, M.B.B.S., F.R.C.S. (Tr & Ortho)

Abstract: Bucket-handle meniscal tears (BHMT) remain a challenge to treat due to their complex pathology and technical difficulty. Subtotal meniscectomy has shown to improve symptoms early but leads to accelerated osteoarthritis in the affected compartment and poor long-term outcomes. BHMT repair and meniscal preservation is the preferred option. This can be performed with inside-out, all-inside, or hybrid meniscus repair techniques. All-inside meniscus repair avoids the need for additional safety incisions, trained assistants for suture passing, and reduce concerns of soft-tissue and neurovascular complications. In this Technical Note, we detail our all-inside technique for BHMT technique and share tips for a successful repair.

Bucket-handle meniscal tears (BHMT) account for approximately 10% of meniscus tears.¹ These tears are vertical longitudinal tears in the red–red or red–white zone of the meniscus, with displacement of torn central fragment into the intercondylar notch. They can be challenging to treat due their complex nature, size of the central fragment, tissue quality of the meniscus, difficulty with fragment reduction, and stable fixation for healing. These tears do display good propensity for healing after repair, especially if they occur in the peripheral zone, with rich blood supply.¹

The treatment options for displaced BHMT are meniscectomy or meniscal repair. Partial or subtotal meniscectomy for BHMT can improve early symptoms but leads to accelerated arthritis in the affected

compartment, as the meniscus plays an key role in force transmission and maintaining joint stability.² From cadaveric studies, it has been shown that failure to repair BHMT within anterior cruciate ligament (ACL) injuries can result in increased tibia–femoral contact pressures.³ Therefore, the preservation of the BHMT fragment is necessary to better restore native tibiofemoral biomechanics.

Many authors have reported good postoperative outcomes after BHMT repairs.^{2,4,5} All-inside and inside-out techniques have been described for BHMT repairs. Inside-out techniques were considered to be the gold standard for repairs but require extra trained assistants for passing sutures, safety incisions, and have neurovascular, soft-tissue complication concerns.^{5,6} The all-inside technique negates some of these concerns, and with improved designs of newer generation all-inside

From the Department of Orthopaedic Surgery, Changi General Hospital, Singapore.

The authors report the following potential conflicts of interest or sources of funding: Y.H.D.L. reports grants and personal fees from Smith & Nephew and DePuy Mitek; personal fees from Arthrex; and grants from Zimmer Biomet, outside the submitted work. Full ICMJE author disclosure forms are available for this article online, as [supplementary material](#).

Received September 18, 2020; accepted October 28, 2020.

Address correspondence to Wen Loong Paul Yuen, M.B.B.S., M.R.C.S., Department of Orthopaedics, Changi General Hospital, 2 Simei St. 3, Singapore 5298892. E-mail: Paulyuen.nushs@gmail.com

© 2020 by the Arthroscopy Association of North America. Published by Elsevier. This is an open access article under the CC BY-NC-ND license (<http://creativecommons.org/licenses/by-nc-nd/4.0/>).

2212-6287/201600

<https://doi.org/10.1016/j.eats.2020.10.063>

Table 1. Technical Considerations for All-Inside BHMT Repair

1. Size of the central fragment and zone of the tear (typically red–red or red–white)
2. Tissue quality of the meniscus (looking for meniscal intrasubstance degeneration on preoperative magnetic resonance imaging)
3. Extent of tear and involvement of anterior or posterior meniscus root (complex tears are harder to repair)
4. Difficulty with fragment reduction and maintaining reduction
5. Ability to obtain stable fixation for healing

BHMT, bucket-handle meniscal tear.

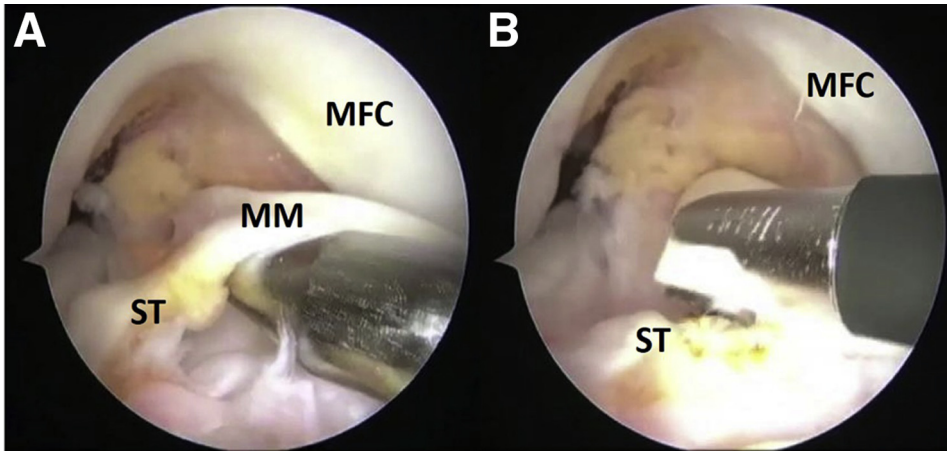


Fig 1. Right knee, viewing from the arthroscopic anterolateral portal. (A) Perimeniscal ST around the displaced medial bucket-handle meniscal tear fragment holding the fragment back and preventing reduction, demonstrated with a probe. (B) Release of the ST by ablation performed with a VAPR radiofrequency wand (Mitek) before subsequent reduction and repair. (MFC, medial femoral condyle; MM, medial meniscus; ST, scar tissue.)

meniscus repair devices, it is now used for a large proportion of meniscus repairs.

The aim of this paper is to describe a technique for all-inside BHMT repair. We share the various tips that can be used to achieve a successful BHMT repair. We detail the arthroscopic portals, tips to reduce the displaced meniscal fragment, use of different stitch patterns, and setting the depth limiter appropriately for different locations in the meniscus.

Indication

The indication for BHMT repair is for both symptomatic medial and lateral BHMT that can be reduced successfully, which stable fixation of the reduced meniscus fragment can be achieved and have good potential to heal.

Surgical Technique (With Video Illustration)

Preoperative Assessment

The preoperative assessment includes an appropriate history, physical examination, and magnetic resonance imaging (MRI) of the affected knee. The patient usually complains of knee instability, pain in the compartment of the displaced BHMT, locking, and inability to achieve full extension. A displaced BHMT is likely to present with significant laxity, increased anterior drawer for displaced medial meniscus tears, and a positive pivot shift for a displaced lateral bucket handle tear.⁷

MRI is used to evaluate tear extent, the size of the displaced fragment, tissue quality (evidence of meniscus intrasubstance degeneration), and complexity of the tear. A complex tear is one that involves the

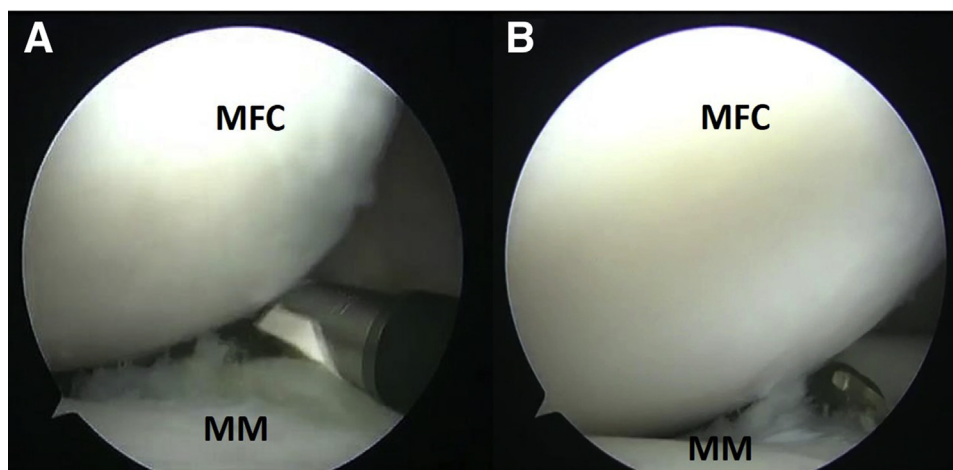


Fig 2. Right knee, viewing from the arthroscopic anterolateral portal. Removal of scar tissue between the medial BHMT fragment and peripheral rim performed by (A) VAPR radiofrequency wand (Mitek) and (B) arthroscopic shaver (Smith & Nephew) shaver. Both devices were introduced through the anteromedial portal. The tissue debridement was performed to assist with tear reduction, as the scar tissue prevented accurate BHMT fragment reduction. (BHMT, bucket-handle meniscal tear; MFC, medial femoral condyle; MM, medial meniscus.)

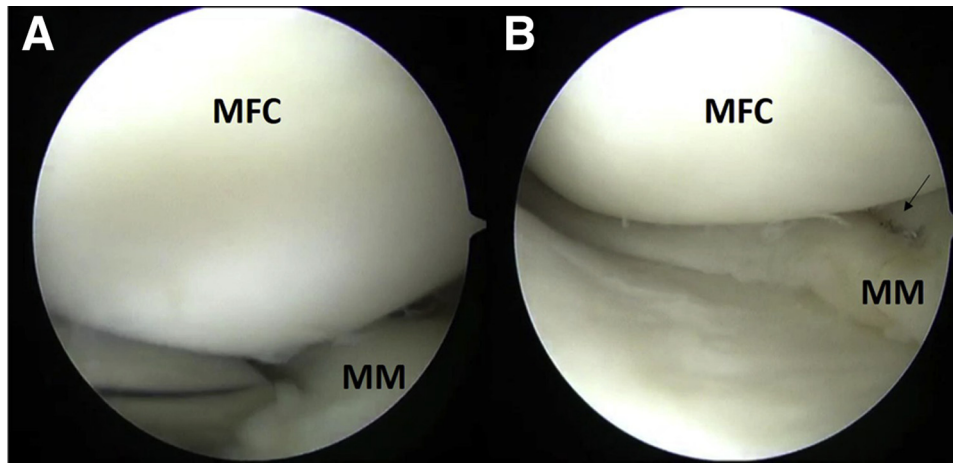


Fig 3. Right knee, viewing from the arthroscopic anteromedial portal. (A) A 30° zone-specific cannula used to place a reduction stitch in the mid-body of the medial meniscus. This is introduced through the anterolateral portal. (B) Deployed inside-out suture in a horizontal stitch configuration (arrow). The limbs of the reduction stitch are subsequently held under tension for reduction of the BHMT so that an all-inside meniscus repair can be performed on the reduced BHMT. (BHMT, bucket-handle meniscal tear; MFC, medial femoral condyle; MM, medial meniscus.)

meniscus roots, or tears that extend into the horizontal or radial plane of the meniscus, making repairs more challenging.

Patient Positioning and Preparation

The patient is placed in the supine position with a thigh tourniquet applied, and the operated leg holder is placed hanging off the table to allow free access to both sides and the back of the knee. The repair of the medial BHMT is done with the knee in near full extension. A medial collateral ligament piecrust may be required to improve access, aid reduction, and allow good stitch placement, especially for tears in the posterior horn.⁸ For repairs in the body of the medial meniscus, this can be performed in 60° to 90° of knee flexion.

The repair of lateral BHMT is done in a figure of 4 position. The foot can be placed on a small side trolley to reduce the need for an assistant to hold the limb. The lateral compartment of the knee can be further opened up with a downward force medially at the knee joint in a figure of four position. The lateral compartment has more space than the medial compartment, and release is not required.

Table 2. Tips for Reduction of Displaced BHMT

1. MCL piecrust to open up a tight medial compartment
2. Figure of 4 position for lateral BHMT repair to open up lateral compartment
3. Adequate soft-tissue release and removal of scar tissue
4. Use of an inside-out reduction stitch

BHMT, bucket-handle meniscal tear; MCL, medial collateral ligament.

Diagnostic Arthroscopy

Standard anterolateral (AL) and anteromedial (AM) portals are used. The 30° arthroscope is inserted through the AL portal to evaluate the BHMT. The BHMT is then assessed to determine pattern, extent, complexity, and reducibility of tear. Preliminary reduction is checked with attempts to reduce the fragment toward the desired anatomical position with probe. [Table 1](#) shows the considerations for assessing a BHMT.

In a BHMT that is in the red–white zone or has a small displaced fragment, the option is to excise it. However, should the central fragment involve the meniscus anterior or posterior root or both, then it would necessitate repair. In such small fragments, repair with inside-out sutures that are smaller in caliber and allow for placement of more sutures may be necessary.

Anatomical Reduction of Tear

The visualized BHMT is first prepared by mechanical rasping of both sides of the tear to promote healing and debridement of perimeniscal synovial tissue with a meniscal rasp and the arthroscopic shaver. In more chronic tears, scar tissue around the displaced tear fragment may hold the fragment back and prevent reduction ([Fig 1](#), [Video 1](#)). Scar tissue in the gutter between the peripheral rim and the tear fragment also can block reduction. This scar tissue has to be adequately excised with a shaver or radiofrequency device to allow manipulation and reduction ([Fig 2](#)).

For BHMT where reduction cannot be maintained anatomically to allow placement of the all-inside stitch, an inside-out reduction stitch can be used. Choosing

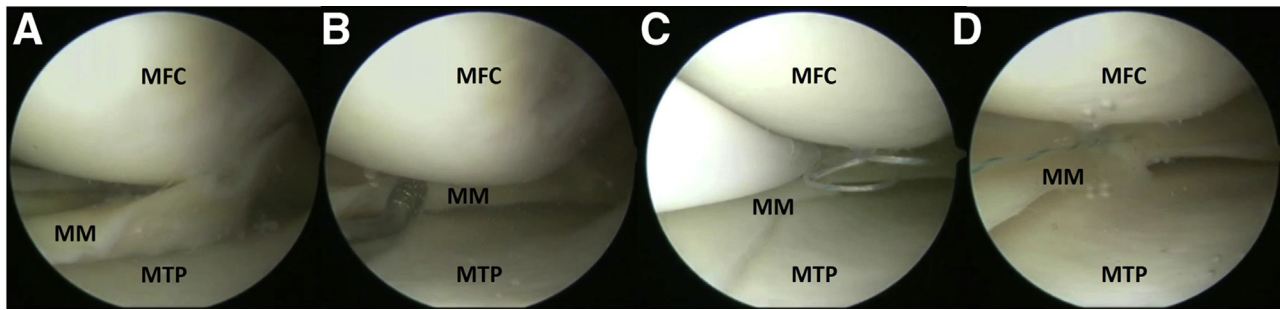


Fig 4. Left knee, viewing from the arthroscopic anterolateral portal, arthroscopic images showing the stepwise repair of a medial BHMT. (A) Displaced unstable medial BHMT from posterior horn to midbody. (B) Rasping of BHMT to promote healing. (C) Placement of the first stitch with all-inside meniscus device, FAST-FIX 360, introduced through the anteromedial portal. This is in a horizontal configuration placed at the junction of the posterior horn and body of the MM with depth limiter set at 18 mm. (D) Subsequent tightening of the horizontal stitch configuration. (BHMT, bucket-handle meniscal tear; MFC, medial femoral condyle; MM, medial meniscus; MTP, medial tibial plateau.)

zone-specific cannula (angle of 30–45°), the inside-out holding stitch (Mitek, Raynham, MA) can be placed in the mid-body of the meniscus. The exit point is in the medial side of the knee for the medial meniscus and anterior to the biceps tendon on the lateral side. This poses no risk to the posterior neurovascular structures, as the stitch is not in the posterior horn. This holding stitch is tensioned to keep the meniscus fragment reduce as the all-inside device sutures are placed, for example, in the posterior horn of the meniscus (Fig 3, Video 1). This reduction suture can be subsequently removed or can be used as an additional fixation point, a hybrid combined inside-out and all-inside meniscus repair. Table 2 summarizes tips to reduce a BHMT.

Viewing and Working Portals, and Depth Setting

Following reduction of the BHMT, all-inside repair can then be performed with an all-inside repair device of the choice of the surgeon. Each all-inside meniscus

device has its own intricacy of use, such as the safe depth for deployment and use of the device, that the surgeon must understand. In this technique, we demonstrate the use of FAST-FIX 360 Meniscal Repair System (Smith & Nephew, London, United Kingdom).

The meniscal depth probe can be used to determine the optimal depth limit by placing it at the meniscosynovial junction and measuring the width of the meniscus at the needle entry point. Most devices come with 18 mm as a pre-set depth on opening the package. In total, 18 mm will be sufficient for most tears except when placing the stitch in the central part of the meniscus. In situations in which the posterior horn tear is displaced slightly forwards, the depth limiter has to be set at 20 mm to ensure adequate penetration pass the capsule to deploy the implant.

For medial BHMT, viewing is performed through the AL portal to place the stitch in the posterior horn via the AM portal. For the best access to the posterior horn of

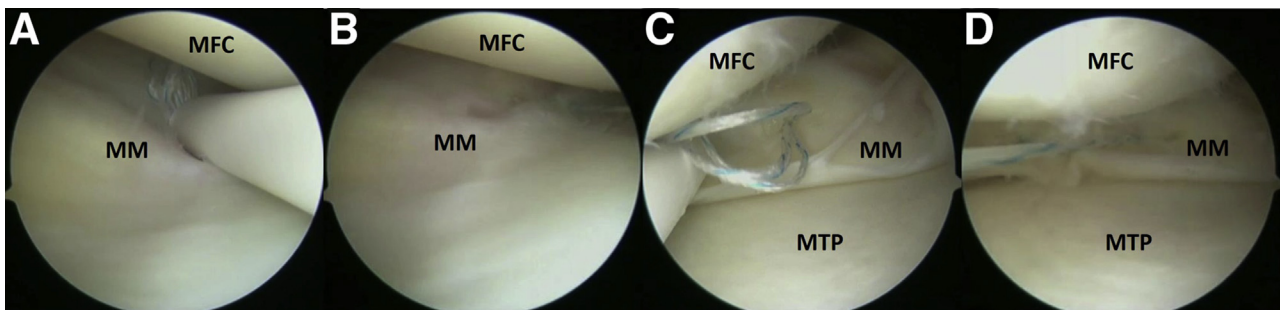


Fig 5. Arthroscopic images showing continuation of repair from Figure 4. (A) Viewing from the AM portal, placement of the second stitch with all-inside meniscus device, FAST-FIX 360, introduced through the AL portal. This is a vertical stitch configuration in the body of the MM with depth limiter set at 16 mm. The first pass of the device is in the peripheral rim of the meniscus and the second is in the red–red zone of the meniscus. (B) Subsequent tightening of the vertical stitch with closure of the tear. (C) Viewing from the AL portal, placement of the third stitch with the all-inside meniscus device, FAST-FIX 360, introduced through the AM portal. This is a horizontal configuration in the posterior horn of the MM with depth limiter set at 18 mm. (D) Subsequent tightening of the horizontal stitch. (AL, anterolateral; AM, anteromedial; MFC, medial femoral condyle; MM, medial meniscus; MTP, medial tibial plateau.)

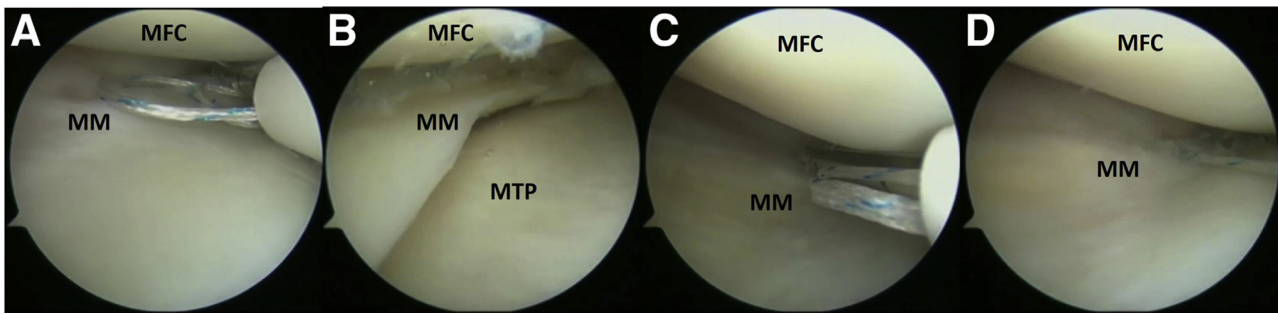


Fig 6. Arthroscopic images showing continuation of repair from [Figure 5](#). (A) Viewing from the AM portal, placement of the fourth stitch with the all-inside meniscus device, FAST-FIX 360, introduced through the AL portal. This is a vertical stitch configuration in the body of the MM with depth limiter set at 16 mm. (B) Subsequent tightening of the vertical stitch with closure of the tear. (C) Viewing from the AM portal, placement of the fifth stitch with the all-inside meniscus device, FAST-FIX 360, introduced through the AL portal. This is a vertical stitch configuration in the body of the MM with depth limiter set at 16 mm. (D) Subsequent tightening of the vertical stitch with closure of the tear. This stitch helps to prevent tear extension. (AL, anterolateral; AM, anteromedial; MFC, medial femoral condyle; MM, medial meniscus; MTP, medial tibial plateau.)

the medial meniscus, the AM portal should be placed as close to the patella tendon as possible especially for tears close to the posterior horn meniscus root.

To place stitches in the body of the medial meniscus, viewing can be from the AM portal with the device coming from the AL portal. In this region, the depth limiter has to be set appropriately, and care should be observed to watch deployment of the implants outside the skin.

For lateral BHMT tears, viewing is performed through the AL portal to place the stitch with the all-inside meniscus device in the posterior horn through the AM portal. For the best access to the posterior horn of the lateral meniscus root, the viewing can be switched to the AM portal and the device placed through the AL portal. This should be done with adequate knowledge depth limit, as this viewing and working portal combination has been shown to bring the all-inside meniscus repair device closest to the posterior neurovascular structures based on cadaveric studies.⁹

Safe Entry of Device Into the Joint, Stitch Configuration, and Placement

A slotted cannula is used to safely deliver the all-inside meniscus repair device into the knee joint. The meniscus repair device needle is pointed downwards along this cannula as it is introduced into the knee joint. The slotted cannula helps entry of device into the joint by clearing portal soft tissue and also guide the device safely past the condyle and reduce the risk of chondral injury.

The first all-inside stitch is placed to hold the reduction and prevent re-displacement ([Fig 4](#), [Video 1](#)). A horizontal stitch in the posterior horn of the meniscus can usually achieve this when accurate reduction has been done. In cases with incomplete reduction, a horizontal stitch in the junction of the body and the posterior horn can help with reduction and holding the reduction.

Meniscus sutures should be directed perpendicular to the tear. The stitches can be placed in a vertical

Fig 7. (A) Viewing from the arthroscopic anterolateral portal, inspection of the stable completed all-inside repair of the medial BHMT repair. (B) Stable repaired BHMT during arthroscopy when the second-stage anterior cruciate ligament reconstruction was performed after 6 weeks. (BHMT, bucket-handle meniscal tear; MFC, medial femoral condyle; MM, medial meniscus; MTP, medial tibial plateau.)

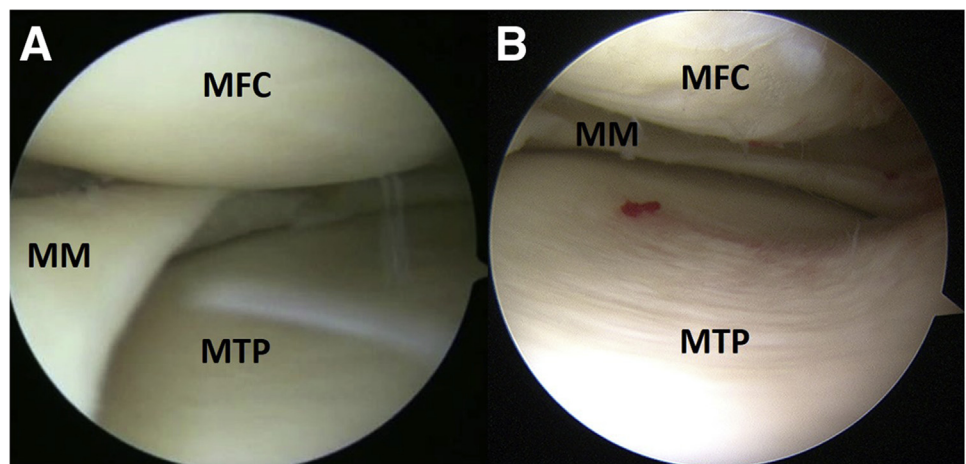


Table 3. Tips for Stable Repair of BHMT

1. Careful placement of portals—portals placed close to the patella tendon allow good access to the posterior horn, especially near the posterior root
2. Use of accessory medial or lateral portals to achieve the best trajectory to the body of the meniscus
3. Use of a slotted cannula to reduce cartilage damage during introduction of delivery needle
4. Identifying optimal and healthy meniscus tissue for stitch deployment
5. Reduction of the unstable meniscal fragment to stable tissue, by deploying the first implant in the capsule to bring the unstable fragment to it with the second implants
6. Placing a vertical stitch at edge of tear to prevent tear extension
7. Placing a stitch on the under surface of the meniscus to flip and reduce the meniscus downward
8. Using a combination of horizontal and vertical stitches to achieve stable repair

BHMT, bucket-handle meniscal tear.

configuration or horizontal mattress configuration. Vertical stitches are biomechanically stronger but tend to flip the meniscus upwards and would require an undersurface stitch to flip the meniscus down.¹⁰ Horizontal stitches, although often considered biomechanically weaker, tend to preserve anatomy. A variety of suture patterns should be placed to achieve optimal fixation for tear repair (Figs 4-6, Video 1).

Another tip is to choose to place stitches in the meniscus tissue of the best quality. When placing a vertical stitch in unstable or mobile tissue, place the first stitch in the peripheral region/capsule and then bring the unstable fragment to be reduced back to the periphery.

In general, at least 5 to 6 all-inside stitches at intervals of 3 to 5 mm are required for adequate repair of the BHMT. A vertical stitch should be placed at the edge of the tear to prevent tear propagation. After completion of the meniscal repair, stability of the repair is checked (Fig 7, Video 1). There should be no fear to hyperflex the knee should it be required for concomitant ACL reconstruction if a stable BHMT repair has been achieved. Table 3 summarizes the tips for BHMT repair.

Postoperative Protocol

After BHMT repair, patients are placed in a knee brace and allowed range of motion of 0° to 90° for 6 weeks. This is to limit deep knee flexion. Patients are kept on non-weight-bearing or protected weight-bearing for 6 weeks. Thereafter, they are allowed weight-bearing as

Table 4. Advantages of All-Inside BHMT Repair

1. Shorter surgery time
2. Less need for surgical assistance
3. Fewer and smaller skin incisions
4. Lower risk of nerve entrapment (no need to tie sutures)
5. Lower risk of wound infections

BHMT, bucket-handle meniscal tear.

tolerated and full range of motion after 6 weeks. Sports activities are generally permitted about 9 to 9 months post repair, depending on patient's progress in strength and agility recovery.

Discussion

BHMT should be repaired to restore meniscus function and preserve native knee biomechanics. Logan et al.³ demonstrated that the resection of a medial BHMT in a concurrent ACL reconstruction results in significant increase in mean peak contact pressures in both the medial and lateral compartments of the knee. Studies also have shown that patients who undergo BHMT repair have less knee pain and improved outcomes compared with patients who undergo meniscectomy.¹¹

Good long-term outcomes for BHMT repairs have been demonstrated for both inside-out and all-inside techniques. Samuelsen et al.⁵ have shown 80% clinical success rates for both inside-out and all-inside repairs and did not find any difference in clinical success rates, clinical outcome scores, or complication rates between the 2 techniques.

Cetinkaya et al.¹ reported a clinical healing rate of 77% and radiologic healing rate of 81% with MRIs for 26 patients with chronic BHMT repaired with all-inside or inside-out techniques at 6 months after surgery. It is also pertinent to note that a 70% to 80% success can still be achieved in neglected BHMT.

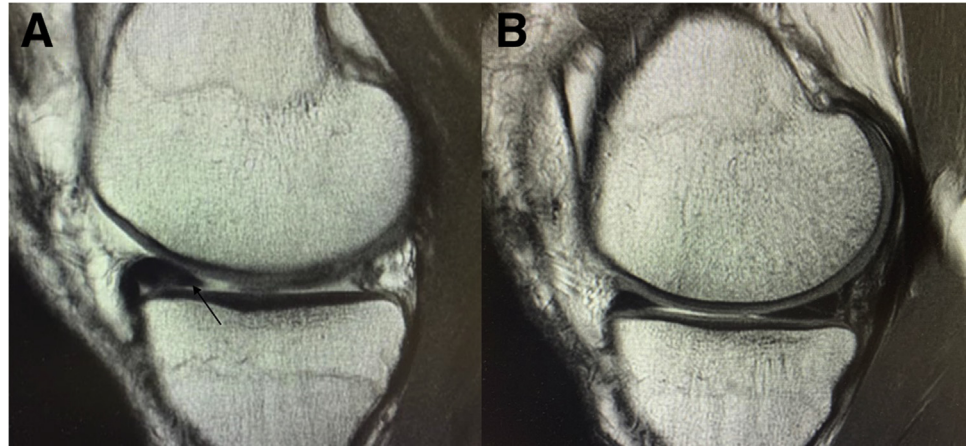
In their systematic review of all-inside repair BHMT, Ardizzone et al.¹² reported failure rates of 29.3% at 13 months postoperatively based on reoperation. They also found that the overall failure rate for all-inside devices was greater than that of inside-out. It is important to note in their study that the all-inside device implants used were varied and from early generations of all-inside devices, some of which are seldom used now.

All-inside techniques are used more frequently due to their ease of use with improved implant design. With the introduction of new all-inside meniscal repair devices that have better design and biomechanical data, this technique has becoming increasingly performed with good clinical outcomes. The advantages to the use of all-inside repair for bucket handle tears are shorter surgery times, fewer skin incisions, and less surgical assistant requirements. The use of inside-out meniscus

Table 5. Limitations of All-Inside BHMT Repair

1. High cost of all-inside devices, which can limit number of sutures placed
2. Learning curve with implant usage
3. Competent deployment of implants required to prevent misfiring and implants pull-out
4. Proper education of setting of depth limiter safe introduction trajectory from both arthroscopic portals for safe use

Fig 8. T1-weighted sagittal MRI images (A) Preoperative MRI with displaced medial BHMT (arrow). (B) Two-year postoperative MRI showing healed medial BHMT after all-inside repair technique. (BHMT, bucket-handle meniscal tear; MRI, magnetic resonance imaging.)



repair techniques requires an additional surgical assistant for passage and retrieval of the inside-out needle as well as incisions to protect the posterior knee structures and to tie the sutures. With all-inside meniscus repair, there is almost no risk of nerve entrapment, which can occur during tying of the inside-out or outside-in meniscus sutures. These additional wounds created for suture tying, which are necessary for inside-out and outside-in meniscus repairs, also pose an increased wound infection risk. Table 4 summarizes the advantages of using all-inside repair techniques for BHMT.

The limitations to all-inside repair of bucket handle meniscus tears are the high costs of each meniscus repair device, which may influence the number of stitches placed to repair the meniscus tear. Another limitation is the technical learning curve for the competent use of the meniscus repair device. The familiarity of meniscus repair device used will determine the successful deployment of the implants, prevent implant pull-out, and prevent device misfiring.

Proper education on the use of all-inside devices for meniscus repair also is crucial to limit potential complications like neurovascular injury and iatrogenic chondral injury. Surgeons using these devices for the first time should be taught the proper setting on the device depth limiter as well as the safe insertion trajectory of the device from both arthroscopic portals. Table 5 summarizes the limitations of all-inside BHMT repair.

We describe an all-inside repair of BHMT and present the tips for technical success. The key to successful meniscal repair is good anatomical reduction and stable fixation. This would then achieve an all-inside BHMT repair with good outcomes (Fig 8).

Summary

All-inside repair of BHMT can achieve good outcomes. We present our technique for all-inside BHMT, emphasizing good reduction and stable fragment

fixation. This will shorten surgery time, reduce complications, and provide predictable outcomes.

References

1. Cetinkaya E, Gursu S, Gul M, Aykut US, Ozcafer R. Surgical repair of neglected bucket-handle meniscal tears displaced into the intercondylar notch: Clinical and radiological results. *J Knee Surg* 2018;31:514-519.
2. Saltzman BM, Cotter EJ, Wang KC, et al. Arthroscopically repaired bucket-handle meniscus tears: Patient demographics, postoperative outcomes, and a comparison of success and failure cases. *Cartilage* 2020;11:77-87.
3. Logan CA, Aman ZS, Kemler BR, Storaci HW, Dornan GJ, LaPrade RF. Influence of medial meniscus bucket-handle repair in setting of anterior cruciate ligament reconstruction on tibiofemoral contact mechanics: A biomechanical study. *Arthroscopy* 2019;35:2412-2420.
4. Moatshe G, Cinque ME, Godin JA, Vap AR, Chahla J, LaPrade RF. Comparable outcomes after bucket-handle meniscal repair and vertical meniscal repair can be achieved at a minimum 2 years' follow-up. *Am J Sports Med* 2017;45:3104-3110.
5. Samuelsen BT, Johnson NR, Hevesi M, et al. Comparative outcomes of all-inside versus inside-out repair of bucket-handle meniscal tears: A propensity-matched analysis [published online June 15, 2018]. *Orthop J Sport med.* <https://doi.org/10.1177/2325967118779045>.
6. Fillingham YA, Riboh JC, Erickson BJ, Bach BR, Yanke AB. Inside-out versus all-inside repair of isolated meniscal tears: An updated systematic review. *Am J Sports Med* 2017;45:234-242.
7. Magnussen RA, Reinke EK, Huston LJ, et al. Factors associated with high-grade lachman, pivot shift, and anterior drawer at the time of anterior cruciate ligament reconstruction. *Arthroscopy* 2016;32:1080-1085.
8. Polat B, Aydin D, Sarl E, et al. Objective measurement of medial joint space widening with percutaneous pie crust release of medial collateral ligament during knee arthroscopy. *J Knee Surg* 2020;33:94-98.
9. Mao DW, Upadhyay U, Thalanki S, Lee DYH. All-inside lateral meniscal repair via anterolateral portal increases

- risk of vascular injury: A cadaveric study. *Arthroscopy* 2020;36:225-232.
10. Lee SS, Lee MC, Lee JH, Kim TW. Biomechanical comparison of suture techniques in radial meniscal tears using gap configuration analysis. *Orthopedics* 2019;42:e443-e448.
 11. Roemer FW, Kwoh CK, Hannon MJ, et al. Partial meniscectomy is associated with increased risk of incident radiographic osteoarthritis and worsening cartilage damage in the following year. *Eur Radiol* 2017;27:404-413.
 12. Ardizzone CA, Houck DA, McCartney DW, Vidal AF, Frank RM. All-inside repair of bucket-handle meniscal tears: Clinical outcomes and prognostic factors. *Am J Sports Med* 2020;48:3386-3393.