

# Dynamic—Anatomical Reconstruction of Medial Patellofemoral Ligament in Open Physis



Roberto Negrín, M.D., Nicolas O. Reyes, M.D., Magaly Iñiguez, M.D., Nicolas Gaggero, M.D., Rodrigo Sandoval, M.D., Nicolas Jabes, M.D., and Magdalena Mendez

**Abstract:** Patellar dislocation is a common knee problem, 10 times more frequent in childhood and adolescence. Medial patellofemoral ligament is injured up to 94% of the time, and its reconstruction is effective in terms of stabilization of the patella. However, distal femoral physis can be damaged with different techniques of reconstruction, due to the location of the femoral footprint. The purpose of this Technical Note is to describe a quasi-anatomical and dynamic reconstruction of the medial patellofemoral ligament, using no tunnel in the femur, passing the graft behind the adductor tendon, and fixing it with one tunnel in the patella and one passage through the quadriceps tendon.

Patellar dislocation during musculoskeletal development is a common knee problem. The incidence reaches 29 to 43/100,000 persons per year during childhood and adolescence, which is up to 10 times the occurrence in adults.<sup>1</sup> The medial patellofemoral ligament (MPFL) is the main passive restrictor to the lateral patellar translation and it is injured in up to 78% to 94% of first dislocation episodes,<sup>2,3</sup> with its chronic injury being one of the main factors in the recurrent patellar instability. Recently, a component of the MPFL has been described, the medial quadriceps tendon—femoral ligament (MQTFL), and has gained importance since its anatomy and functions have become better known.<sup>3,4</sup> Its fibers have the same origin as the MPFL, where is described an inferior straight bundle with an insertion on the patella (57.3% of total fibers) and another bundle of superior oblique fibers,

the MQTFL with a quadriceps tendon insertion, with a mean angle of 25.1° between these 2 bundles.

MPFL reconstruction has gained great importance due to its effectiveness in the stabilization of the patella, its technical simplicity, and good results. Different techniques have been described that seek to reconstruct the ligament, which vary according to the graft choice, form and method of fixation, tension, and anatomic insertion site.<sup>5-8</sup> The latter is the point of most controversy, describing multiple locations at the level of the patella and the femur.

The MPFL site of origin in the femur undergoes great variation during development, and a finished study of the anatomy and its relation to growth has not yet been achieved due to the limited access to pediatric cadaveric models for their study. In 86% of the cases, 5 mm distal to the physis is described and the remaining 14% would vary its location reaching up to 7.5 mm proximal.<sup>9-11</sup> Besides the difficulty of identifying the appropriate place of origin, the femur of the skeletally immature patient presents even greater challenges at the time of MPFL reconstruction since there is high risk of damage to the physis if a bone tunnel is performed, due to the variations that it may suffer during development and its proximity to the anatomical femoral origin. There are different patterns described for patellar insertion. They all involve insertion in the proximal third of the patella and include up to 45% junction to the middle third and 36% junction to the quadriceps tendon with inconstant adhesions to the tendon at the vastus medialis obliques<sup>4,10,11</sup> (Fig 1). Another controversial factor concerns the tension in which the graft is fixed and the potential for medial patellofemoral compartment

From the Department of Orthopedics and Traumatology, Clinica Las Condes, Santiago, Chile.

The authors report the following potential conflicts of interest or sources of funding: R.N. reports personal fees from Zimmer-Biomet and personal fees and nonfinancial support from Smith & Nephew, outside the submitted work. N.O.R. reports nonfinancial support from Smith & Nephew, outside the submitted work. Full ICMJE author disclosure forms are available for this article online, as supplementary material.

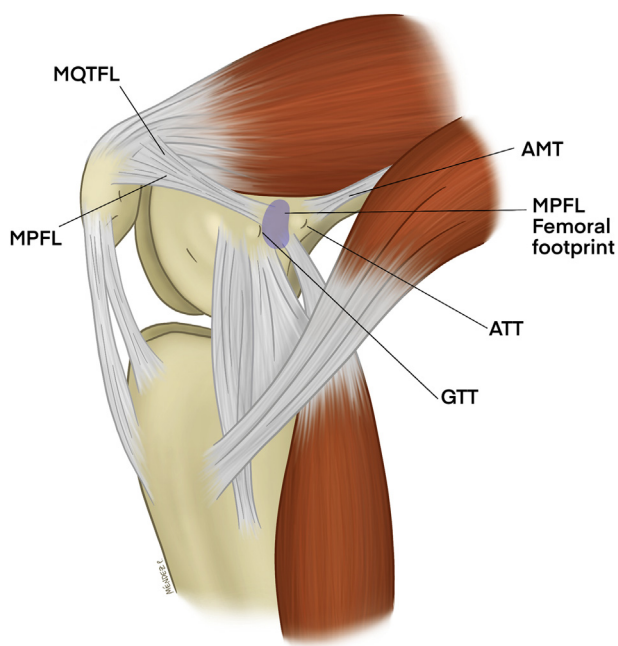
Received January 15, 2020; accepted March 29, 2020.

Address correspondence to Nicolás O. Reyes M.D., Lo Fontecilla 441, Santiago 6772610, Chile. E-mail: nicoreyes1@gmail.com

© 2020 by the Arthroscopy Association of North America. Published by Elsevier. This is an open access article under the CC BY-NC-ND license (<http://creativecommons.org/licenses/by-nc-nd/4.0/>).

2212-6287/20101

<https://doi.org/10.1016/j.eats.2020.03.018>



**Fig 1.** Medial view of a flexed knee is shown. Anatomy of the MPFL. (AMT, adductor magnus tendon; ATT, adductor tendon tubercle; GTT, gastrocnemius tendon tubercle; MPFL, medial patellofemoral ligament; MQTFL, medial quadriceps tendon–femoral ligament.)

overconstriction presented by traditional techniques. This is why we find it of special interest to develop dynamic fixation techniques that would have the potential to reduce this risk by reconstruction through a construct with less stiff fixation.

Due to the frequency of presentation, the potential for negative effects, and the importance of an adequate MPFL reconstruction, we have decided as a team to present a surgical technique of dynamic reconstruction of the MPFL, which is reproducible, simple, and without invasion of the physis.

### Surgical Technique (With Video Illustration)

The technique is shown in [Video 1](#), and its pearls and pitfalls are described in [Table 1](#).

#### Patient Positioning

The patient should be placed in the supine position on a surgical table with both knees bent at 90° hanging toward the floor with the knee to intervene in the leg holder with enough space on the medial side to perform the approaches and the reconstruction of the MPFL.

The procedure can also be done with both extremities on an extended surgical table, with a distal block that allows limb support with a 90° bent knee and lateral support.

#### Diagnostic Arthroscopy

Through a classic anterolateral portal, a diagnostic arthroscopy is performed assessing the patellofemoral,

medial, lateral, and intercondylar notch compartments to evaluate and eventually resolve associated injuries or remove intra-articular loose bodies. It is also recommended to perform a superolateral portal, through which the patellar tracking can be evaluated before and after reconstruction and also evaluate the absence of intra-articular neoligament.

#### Graft Selection

In case an autograft is used, a 3-cm longitudinal approach is performed medial to the tibial tubercle until identification of the sartorius fascia. An upside-down L-shaped incision may be used, and the gracilis tendon is identified and extracted from the bone and through the use of a tendon stripper, the harvest is done. The graft is then prepared on a side table, removing the muscular remains and performing tubularization with VICRYL 1.0 suture (Ethicon, Somerville, NJ) on the 2 ends of the tendon with Krakow sutures or similar.

#### MPFL Reconstruction

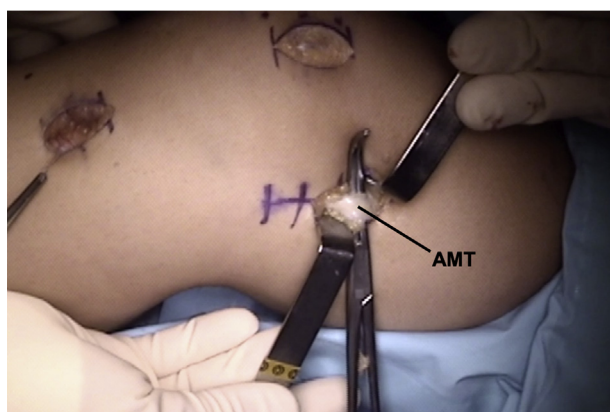
##### Step 1: Approaches

An approach to the medial skin is performed through minimally invasive surgery, first to the upper third of the patella, 3 to 4 cm in a longitudinal direction. Dissection is performed by planes without crossing the joint capsule. The bony border of the upper third of the patella and the medial distal insertion of the quadriceps tendon should be identified. Then, by palpation at the level of the medial epicondyle, a 3- to 4-cm longitudinal incision is made and dissected with a blunt-edge clamp until the tendon and adductor tubercle are identified. Then, it is carefully released at 5 to 10 mm proximal and posterior to the tubercle and a suture is passed to mark the future graft passage ([Fig 2](#)).

**Table 1.** Pearls and Pitfalls

Pearls	Pitfalls
1. Always perform a diagnostic arthroscopy previous to the MPFL reconstruction to assess intra-articular lesions.	1. Not identifying the adductor magnus tendon, or confusing it with another structure, can lead to an incorrect femoral fixation.
2. Approaches must be performed over the anatomic landmarks. Palpate the proximal third of the patella and the adductor tubercle	2. Using tunnels in femoral footprint can lead to physis injury.
3. Pass the graft between the second and third layers.	3. Not suturing both graft ends can lead to graft loosening.
4. Fixation is recommended to be done at 60° of knee flexion, suturing both ends of the graft, anterior to the patella.	4. A too-anterior or too-proximal patellar tunnel can increase the risk of patellar fracture.

MPFL, medial patellofemoral ligament.



**Fig 2.** Medial view of a right knee. The medial longitudinal femoral approach. Identification of the adductor magnus tendon, dissected in its insertion site in the adductor tubercle. (AMT, adductor magnus tendon.)

### Step 2

The upper third on the medial edge of the patella is identified, passing a 2.4-mm guide needle in a lateral and anterior direction. The position of the needle in the frontal and lateral planes can be checked by radioscopy. The needle must be correctly visualized at the anterior patellar edge, without exceeding 50% of its width. Then, a patellar tunnel is made in the same position with a 4.5-mm cannulated drill bit (Fig 3). Once the tunnel is made, the guide needle is transfixed, leaving a VICRYL 1.0 suture for the subsequent graft passage.

### Step 3

Then, the insertion of the quadriceps tendon is identified and it is transfixed with a clamp at least 1 cm in a lateral and anterior direction. The space between the second and third layers of medial tissues is identified with a Kelly clamp and dissection is performed until the anterior and medial approaches are connected. Once done, the graft, which has been previously prepared, is passed behind the adductor tubercle (Fig 4 A and B) and both ends are gently pulled between the second and third anterior layers. Care must be taken so that the end that passes behind the adductor tendon be the proximal and the one that passes in front be the distal. Then, the distal end is passed through the patellar tunnel, from medial to lateral and anterior, and the proximal end, through the quadriceps tendon, from medial to lateral and anterior (Fig 5).

### Step 4

At this point one can still decide on the length of both ends, and it is recommended that they be a similar length. Therefore, returning to the graft passage behind the adductor tendon, the suture of the distal end of the graft is made with 2 to 4 single sutures with VICRYL 1.0, as close to the adductor tubercle as possible (the anatomical area where the MPFL origin is found).

### Step 5

Then, with the knee in 60° flexion, pulling and joining both ends, the fixation is decided, while allowing a +1 or +2 glide of the patella.<sup>3,12-14</sup> The proximal end is sutured with the distal end, anterior to the patella with the VICRYL 1.0 suture and passing the stitches over the remaining tissue of the retinaculum and anterior fibers of the quadriceps tendon (Fig 6).

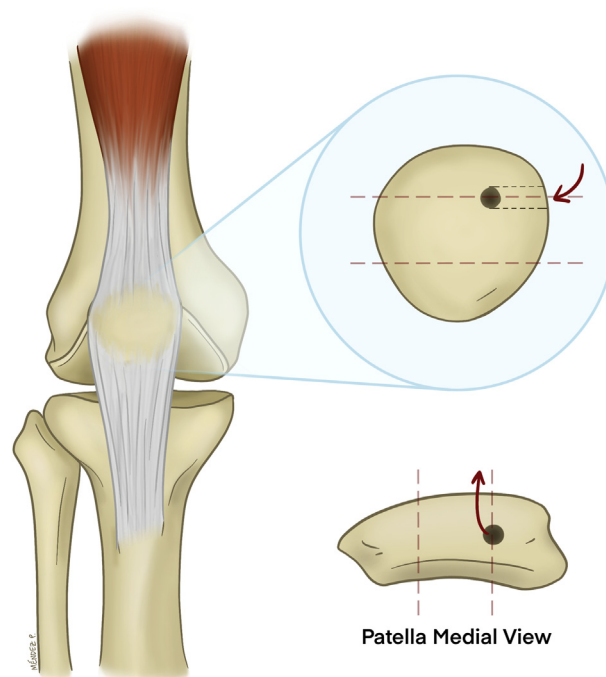
Fascia closure and subsequent arthroscopy are performed to check patellar tracking and absence of the intra-articular neoligament. Skin closure is performed with the preferred method.

## Discussion

The reconstruction of the MPFL is a widely used resource for the treatment of patella instability and continues to be one of the main pillars of this kind of surgical treatment.

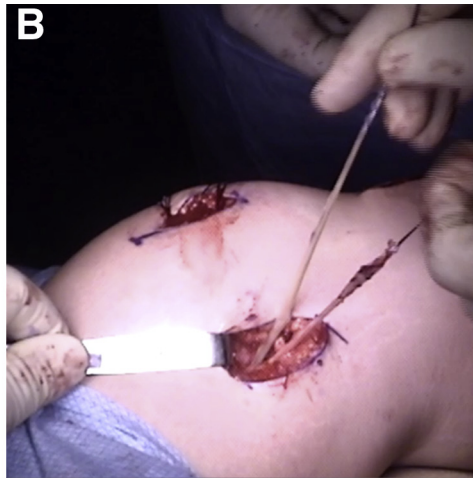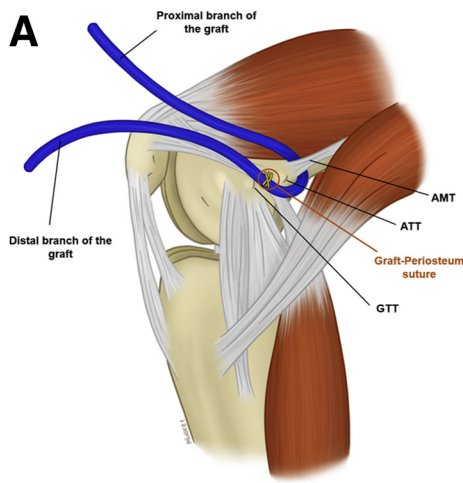
With complications of the procedure at 26%, re-dislocation is the most frequent (32%), followed by anterior knee pain caused by hyperpressure in the medial patellofemoral compartment, caused by an inadequate surgical technique.

Regardless of the failures of MPFL reconstruction due to poor indication of surgery, patient selection, and/or inadequate surgical techniques, special care must be taken in the position of the femoral tunnel, since it is



**Fig 3.** Patellar tunnel. The junction of the middle and upper third of the medial edge of the patella is identified, passing a 2.4-mm guidewire in the lateral and anterior direction, without exceeding 50% of its width. Then, a tunnel is made in the same position with a 4.5-mm cannulated drill bit.



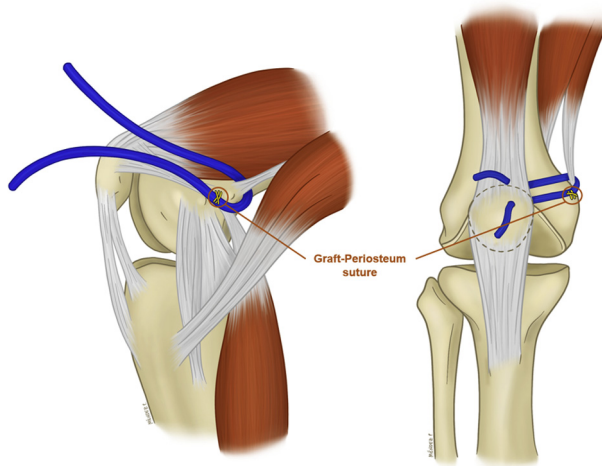


**Fig 4.** Medial view of a right knee. (A) Graft passing behind the adductor tendon, and the distal branch is fixed in the periosteum with a 1.0 suture, as close to the ATT as possible (anatomical area of MPFL). (B) Medial surgical view with minimally invasive approaches. (AMT, adductor magnus tendon; ATT, adductor tendon tubercle; MPFL, medial patellofemoral ligament; GTT, gastrocnemius tendon tubercle.)

the most critical step in relation to the anatomical reconstruction of the ligament.

This is why it is essential to know in detail the femoral anatomical structures, since associated with the difficulty of real lateral fluoroscopic radiograph during the surgical procedure there is inaccuracy in the location of the Schöettle point,<sup>15</sup> leading to nonanatomical femoral fixation of the graft.

Discrepancies at the 5-mm insertion site increase graft elongation by up to 12 mm during flexion extension,<sup>12,16</sup> which is reflected in increased patellofemoral contact pressures<sup>13,17</sup> and clinically in pain, joint cartilage wear and eventually future repeated surgical intervention of the patient. If the graft is fixed in a more proximal position it will lead to an increase in the distance between the femoral anchor point and the patella during knee flexion, increasing tension and with it the pressure on the medial aspect of the patellofemoral joint. In fact, if



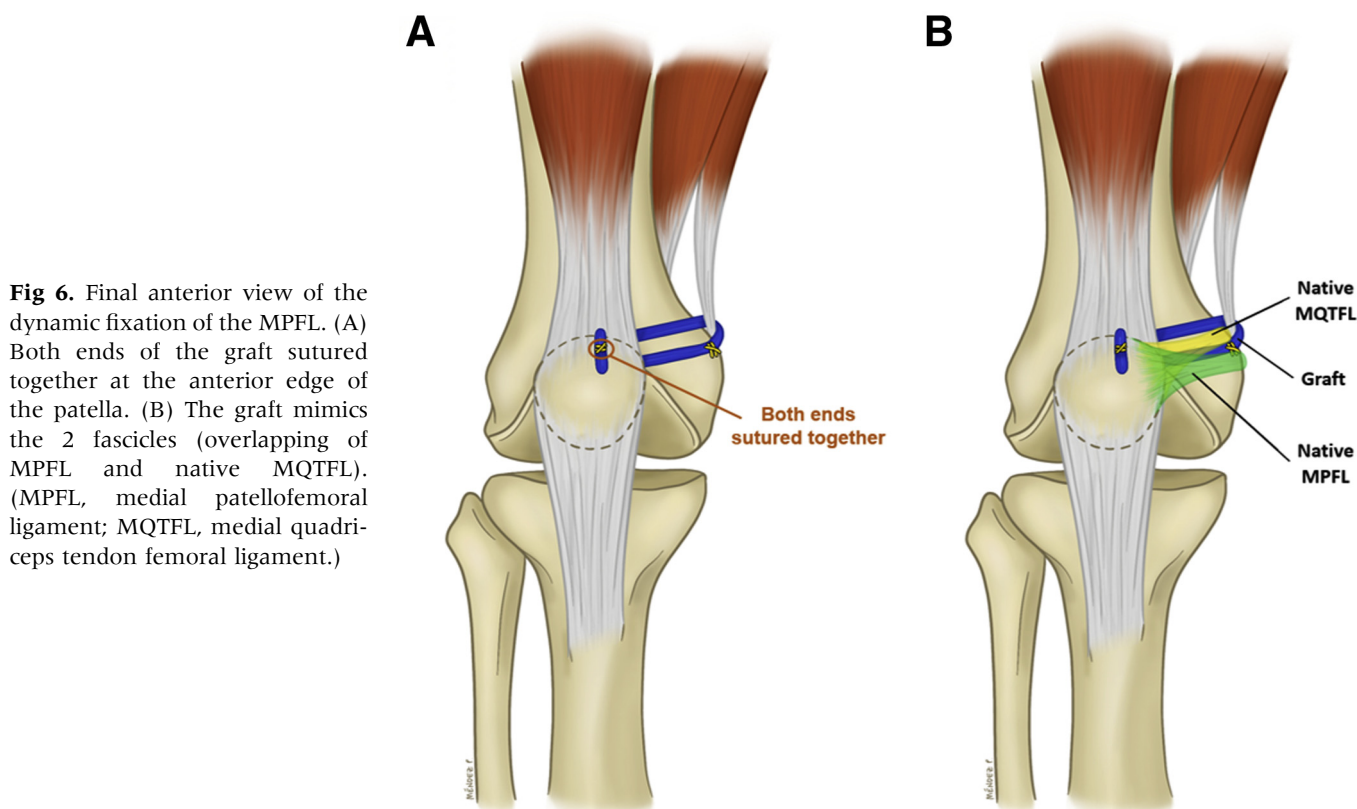
**Fig 5.** Medial and anterior views of the graft passing through the patellar tunnel and between the fibers of the quadriceps tendon. It is already fixed in the adductor tubercle.

the reconstruction is performed statically, the increase in pressure in the patellofemoral joint in flexion from 60° to 110° is increased by 3 to 5 times compared with the native MPFL. If the nonanatomical fixation is performed in the adductor tubercle, it results in a quasi-isometric fixation, avoiding overload of the patellofemoral joint, as described by Panagopoulos et al.<sup>18</sup>

In relation to dynamic fixation, the pressure during flexion remains unchanged with respect to the native knee; therefore, this type of reconstruction would be a safer option for stabilizing the patella.<sup>19</sup> On our team, just like what was published by Monllau et al.<sup>20</sup> and Lind et al.,<sup>21</sup> decided to use a dynamic reconstruction technique in those patients with open physis, where we seek to restore patellofemoral mechanics, without overloading the joint and without the risk of damaging the femoral physis with the tunnel required by other techniques to fix the graft in the femur. In contrast, our technique differs from those described by Monllau et al.<sup>20</sup> and Lind et al.<sup>21</sup> because we reconstruct the MQFL, replicating anatomy and associating a new point of dynamism with the construct.<sup>12</sup> In addition, the most distal arm of the graft is fixed to the femoral periosteum with VICRYL replicating the insertion in the anatomical site (Tables 1 and 2).

McNeilan et al.<sup>22</sup> showed in a recent publication that there is no biomechanical difference in the use of auto or allograft, justified in the low resistance (217 N) of the native MPFL and it would be enough to have a graft 240 mm long and 5 to 6 mm diameter for proper reconstruction. Regarding the use of cryopreserved or lyophilized allograft, Negrín et al.<sup>23</sup> in 2016 demonstrated in a study, conducted on 36 swine knees, that there would be no difference in maximum tensile resistance, elongation, area of failure, graft strength or histology.

With the publication of this Technical Note, our team seeks to make known a dynamic–anatomic alternative



**Fig 6.** Final anterior view of the dynamic fixation of the MPFL. (A) Both ends of the graft sutured together at the anterior edge of the patella. (B) The graft mimics the 2 fascicles (overlapping of MPFL and native MQTFL). (MPFL, medial patellofemoral ligament; MQTFL, medial quadriceps tendon femoral ligament.)

for MPFL that is reproducible, simple, dynamic, and where the femoral physis is not at risk; the MPFL has an insertion area that would be covered by the graft, which is anatomically fixed in the insertion area of MPFL with the periosteal suture. Nevertheless, this technique does not allow a completely anatomical reconstruction, but it can be considered a “quasi-anatomical reconstruction,” since the MPFL and MQTFL bundles are positioned and fixed in the anatomical footprints in the patella and quadriceps tendon, respectively, they have their correct

course between the layers, but their femoral origin is not the anatomical, being approximately 5 mm posterior to the footprint. Considering this point, if the adductor tubercle is not correctly identified, it can lead to a far more distant femoral footprint, and graft failure. We consider that the MPFL tendon would act as a pulley, close to the isometric point, maintaining constant tension in the graft successfully managing the patella instability. Furthermore, this technique takes into account the fixation of the graft at the level of quadriceps tendon and the proximal third of the patella, bringing reconstruction closer to the native anatomy of the knee. However, care must be taken with the patellar tunnel, since it can lead to a patellar fracture if it's done too anterior or too proximal.

**Table 2.** Advantages and Disadvantages

Advantages	Disadvantages
1. Dynamic fixation is more similar to normal biomechanics.	1. Requires a deep understanding of anatomy.
2. This technique includes the reconstruction of the MQTFL bundle.	2. Femoral fixation is not 100% anatomical.
3. Diminishes the risk of medial patellofemoral overconstraint.	3. Greater risk of patellar fracture than techniques that use anchors.
4. Does not use fixation devices.	4. It cannot be used in multiligament injuries with avulsion of the adductor tendon.
5. Does not compromises the physis.	5. It is a new technique that requires future clinical studies.
6. Can be used in adult patients as well.	

MQTFL, medial quadriceps tendon femoral ligament.

## References

1. Hoetzel J, Preiss A, Heitmann MA, Frosch K-H. Knee injuries in children and adolescents. *Eur J Trauma Emerg Surg* 2014;40:23-36.
2. Seeley M, Bowman KF, Walsh C, Sabb BJ, Vanderhave KL. Magnetic resonance imaging of acute patellar dislocation in children: Patterns of injury and risk factors for recurrence. *J Pediatr Orthop* 2012;32:145-155.
3. Chahla J, Smigielski R, LaPrade RF, Fulkerson JP. An updated overview of the anatomy and function of the proximal medial patellar restraints (medial patellofemoral

- ligament and the medial quadriceps tendon femoral ligament). *Sports Med Arthrosc Rev* 2019;27:136-142.
4. Tanaka MJ, Chahla J, Farr J 2nd, et al. Recognition of evolving medial patellofemoral anatomy provides insight for reconstruction. *Knee Surg Sports Traumatol Arthrosc* 2019;27:2537-2550.
  5. Schottle PB, Fucentese SF, Romero J. Clinical and radiological outcome of medial patellofemoral ligament reconstruction with a semitendinosus autograft for patella instability. *Knee Surg Sports Traumatol Arthrosc* 2005;13:516-521.
  6. Schneider DK, Grawe B, Magnussen RA, et al. Outcomes after isolated medial patellofemoral ligament reconstruction for the treatment of recurrent lateral patellar dislocations: A systematic review and meta-analysis. *Am J Sports Med* 2016;44:2993-3005.
  7. Chouteau J. Surgical reconstruction of the medial patellofemoral ligament. *Orthop Traumatol Surg Res* 2016;102(1 suppl):S189-S194.
  8. Hendawi T, Godshaw B, Flowers C, Stephens I, Haber L, Waldron S. Autograft vs allograft comparison in pediatric medial patellofemoral ligament reconstruction. *Ochsner J* 2019;19:96-101.
  9. Kepler CK, Bogner EA, Hammoud S, Malcolmson G, Potter HG, Green DW. Zone of injury of the medial patellofemoral ligament after acute patellar dislocation in children and adolescents. *Am J Sports Med* 2011;39:1444-1449.
  10. Shea KG, Styhl AC, Jacobs JC Jr, et al. The relationship of the femoral physis and the medial patellofemoral ligament in children: A cadaveric study. *Am J Sports Med* 2016;44:2833-2837.
  11. Kruckeberg BM, Chahla J, Moatshe G, et al. Quantitative and qualitative analysis of the medial patellar ligaments: An anatomic and radiographic study. *Am J Sports Med* 2018;46:153-162.
  12. Sanchis-Alfonso V, Ginovart G, Alastruey-López D, et al. Evaluation of patellar contact pressure changes after static versus dynamic medial patellofemoral ligament reconstructions using a finite element model. *J Clin Med* 2019;8:E2093.
  13. Decante C, Geffroy L, Salaud C, Chalopin A, Ploteau S, Hamel A. Descriptive and dynamic study of the medial patellofemoral ligament (MPFL). *Surg Radiol Anat* 2019;41:763-774.
  14. Elias JJ, Jones KC, Lalonde MK, Gabra JN, Rezvanifar SC, Cosgarea AJ. Allowing one quadrant of patellar lateral translation during medial patellofemoral ligament reconstruction successfully limits maltracking without overconstraining the patella. *Knee Surg Sports Traumatol Arthrosc* 2018;26:2883-2890.
  15. Ziegler CG, Fulkerson JP, Edgar C. Radiographic reference points are inaccurate with and without a true lateral radiograph: The importance of anatomy in medial patellofemoral ligament reconstruction. *Am J Sports Med* 2016;44:133-142.
  16. Sanchis-Alfonso V, Ramirez-Fuentes C, Montesinos-Berry E, Domenech J, Martí-Bonmatí L. Femoral insertion site of the graft used to replace the medial patellofemoral ligament influences the ligament dynamic changes during knee flexion and the clinical outcome. *Knee Surg Sports Traumatol Arthrosc* 2017;25:2433-2441.
  17. Stephen JM, Kittl C, Williams A, et al. Effect of medial patellofemoral ligament reconstruction method on patellofemoral contact pressures and kinematics. *Am J Sports Med* 2016;44:1186-1194.
  18. Panagopoulos A, van Niekerk L, Triantafillopoulos IK. MPFL reconstruction for recurrent patella dislocation: A new surgical technique and review of the literature. *Int J Sports Med* 2008;29:359-365.
  19. Rood A, Hannink G, Lenting A, et al. Patellofemoral pressure changes after static and dynamic medial patellofemoral ligament reconstructions. *Am J Sports Med* 2015;43:2538-2544.
  20. Monllau JC, Erquicia JI, Ibañez M, et al. Reconstruction of the medial patellofemoral ligament. *Arthrosc Tech* 2017;6:e1471-e1476.
  21. Lind M, Enderlein D, Nielsen T, Christiansen SE, Faunø P. Clinical outcome after reconstruction of the medial patellofemoral ligament in paediatric patients with recurrent patella instability. *Knee Surg Sports Traumatol Arthrosc* 2016;24:666-671.
  22. McNeilan RJ, Everhart JS, Mescher PK, Abouljoud M, Magnussen RA, Flanigan DC. Graft choice in isolated medial patellofemoral ligament reconstruction: A systematic review with meta-analysis of rates of recurrent instability and patient-reported outcomes for autograft, allograft, and synthetic options. *Arthroscopy* 2018;34:1340-1354.
  23. Negrín R, Duboy J, Olavarría F, et al. Biomechanical and histological comparison between the cryopreserved and the lyophilized Gracilis tendon allograft for MPFL reconstruction, a cadaveric experimental study. *J Exp Orthop* 2016;3:20.