


# Detection of peste des petits ruminants virus in pneumonic lungs from clinically apparently healthy camels slaughtered at Tambul slaughterhouse, Central Sudan

Nahid A. S. Abdalla<sup>1</sup> | Alaa E. M. Alhussain<sup>1</sup> | Sana I. Mohammed<sup>2</sup> | Mihad Hakeem<sup>3</sup> | Ihsan H. Ahmed<sup>4</sup> | Galal E. Mohammed<sup>5</sup> | Nussieba A. Osman<sup>1</sup> 

<sup>1</sup>Department of Pathology, Parasitology and Microbiology, College of Veterinary Medicine, Sudan University of Science and Technology, Khartoum-North, Sudan

<sup>2</sup>Virology Department, Central Veterinary Research Laboratory (CVRL), Khartoum, Sudan

<sup>3</sup>Epidemiology Department, Central Veterinary Research Laboratory (CVRL), Khartoum, Sudan

<sup>4</sup>Viral Vaccine Production Department, Central Veterinary Research Laboratory (CVRL), Khartoum, Sudan

<sup>5</sup>Department of Veterinary Medicine and Surgery, College of Veterinary Medicine, Sudan University of Science and Technology, Khartoum-North, Sudan

## Correspondence

Nussieba A. Osman, Department of Pathology, Parasitology and Microbiology, College of Veterinary Medicine, Sudan University of Science and Technology, P.O. Box 204 Kuku, Khartoum-North, Sudan.  
Email: nussieba@yahoo.com

## Funding information

The research in this study was funded by a research project for Nussieba A. Osman from the Republic of the Sudan, Sudanese Ministry of Higher Education and Scientific Research, Commission of Scientific Research and Innovation (grant no. 2017/972).

## Abstract

The study investigated the presence and prevalence of peste des petits ruminants (PPR) viral antigens among camels in Tambul area, Gezira State, Central Sudan, regardless of its sex, age and breed, and their possible contribution in the epidemiology of the disease in the Sudan. Hundred pneumonic lung tissues were aseptically collected from clinically apparently healthy camels showed no signs of illness at ante-mortem examination, from Tambul slaughterhouse, Tambul area, Gezira State, Central Sudan, between November and December 2018. Samples were collected based on presence of the pneumonic signs, at the tissue level, including congestion of the lungs, presence of abscesses, fragility, changes in colour and thickness of the tissue. In order to detect PPR viral antigen, haemagglutination (HA) test was employed on lung tissue homogenate, using chicken RBCs suspension, which gave a positive reaction in 17–19 min. PPRV antigen was detected in 98 of camel samples with an overall antigenic prevalence of 98%. Of note, the HA titres achievable ranged from 4 to 256 HA units (HAU) with mean titre of 14.4 HAU, whereas apparently most of the samples achieved HA titres of 8 HAU. The results demonstrated presence of PPR viral antigens associated with pneumonia in camels indicating exposure of these camels to PPRV and probably presence of subclinical infection. Infection of species other than small ruminants suggests the fact that camels are potential hosts for PPRV and might play a role (or not) in the epidemiology of the disease. Further studies are needed to demonstrate if camels are able to transmit PPRV for in-contact small ruminants or other animal species.

## KEYWORDS

Camels, haemagglutination test (HA), peste des petits ruminants (PPR), pneumonic lungs, PPRV, Sudan

This is an open access article under the terms of the Creative Commons Attribution-NonCommercial-NoDerivs License, which permits use and distribution in any medium, provided the original work is properly cited, the use is non-commercial and no modifications or adaptations are made.

© 2021 The Authors. *Veterinary Medicine and Science* Published by John Wiley & Sons Ltd

## 1 | INTRODUCTION

Peste des petits ruminants (PPR) or sheep and goat plague is a highly contagious animal viral disease affecting domestic and wild small ruminants with high morbidity and mortality. Once it appears in the herd, the virus can infect up to 90% of the animals and the disease kills anywhere from 30% to 70% of infected animals (FAO, 2015). PPR was first described in Côte d'Ivoire in West Africa (Gargadennec & Lalanne, 1942; OIE, 2019).

Peste des petits ruminants is caused by peste des petits ruminants virus (PPRV), a member of the *Small Ruminant Morbillivirus* species, in the *Morbillivirus* genus, of the *Paramyxoviridae* family, in the *Mononegavirales* order (Gibbs et al., 1979; Maes et al., 2019). Sheep and goats are the main natural hosts for PPRV (OIE, 2019; Parida et al., 2015), although many reports mentioned goats as the most sensitive host species for PPRV (Diallo, 2003). Based on the fact that PPR has been reported in camels and buffaloes, those animal species are considered to be susceptible hosts (OIE, 2019).

In the Sudan, outbreaks of PPR-like disease in camels were first reported in Kassala State, Eastern Sudan in 2004. The existence of PPRV was demonstrated on tissue specimens from affected and dead animals (Khalafalla et al., 2010). PPRV infection in camels appeared as per-acute fatal respiratory disease characterized by sudden death with 0%–50% mortality in clinically apparently healthy camels, while diarrhoea, respiratory signs and abortion were presented in pregnant she-camels (Khalafalla et al., 2010). Later, PPRV strains from camels were identified as PPRV lineage IV (Kwiatk et al., 2011). A mixed infection

of PPRV and other respiratory viruses was reported in dromedary camels in different regions of the Sudan (Saeed et al., 2015).

Due to previous reports describing PPR infection of camels in the Sudan, the present study was designed to investigate the presence of PPR viral antigens among camels slaughtered at Tambul slaughterhouse in Gezira State, Central Sudan.

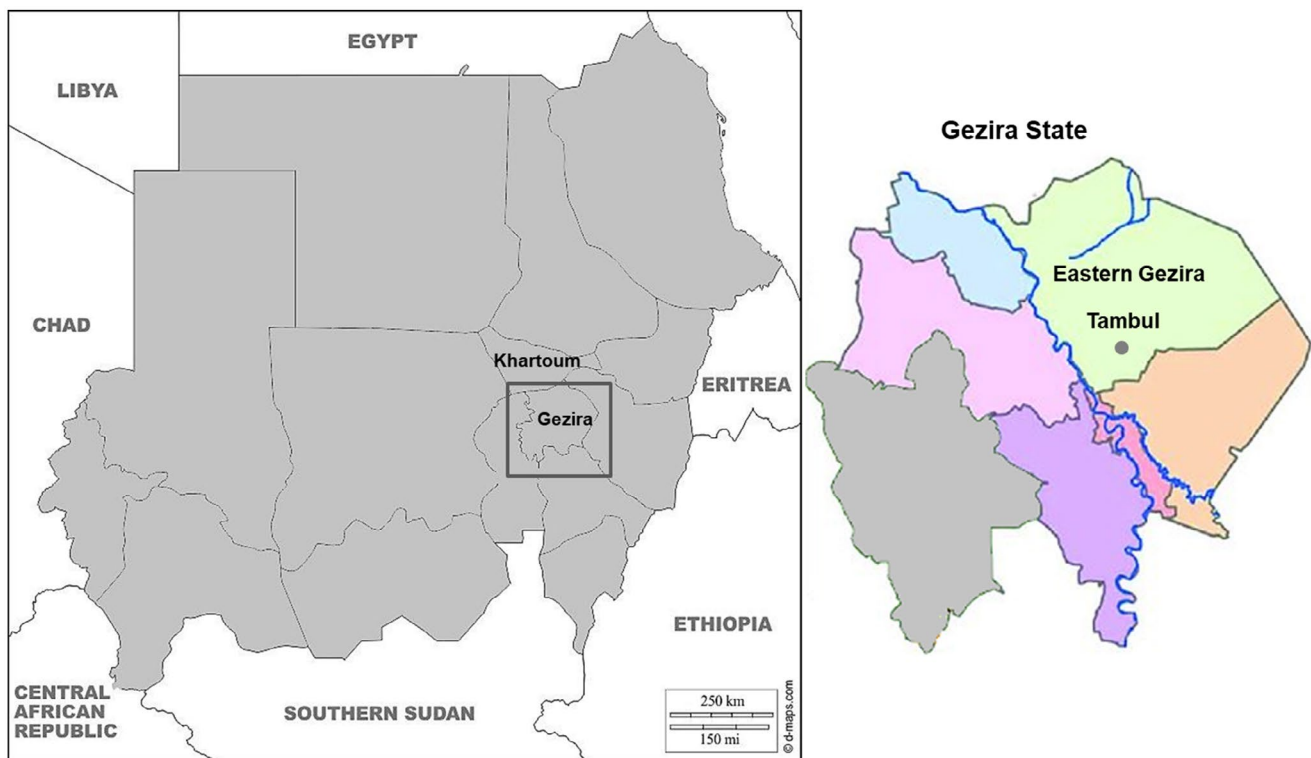## 2 | MATERIALS AND METHODS

### 2.1 | Study area

Gezira State is a small region in Central Sudan which covers an area of 27,549 square kilometres (km<sup>2</sup>) and divided into seven localities. The study was conducted in Tambul area which is located at the coordinates 14°56'0" North and 33°24'0" East in Eastern Gezira locality, Gezira State (Figure 1). The samples for this study were collected from Tambul slaughterhouse which is located near the market. Slaughtering of camels along with other animal species was performed early in the morning at 3:00 a.m. on each Saturday and Tuesday every week while the ante-mortem was performed the day before.

### 2.2 | Reference virus

The live attenuated PPRV Nigeria 75/1 vaccine strain was obtained as a freeze-dried preparation (kindly provided by the Viral Vaccine



**FIGURE 1** Map of the Sudan showing the study area “Tambul in Gezira State, Central Sudan”. The map was retrieved from: ©2007–2020 d-maps.com “[http://www.d-maps.com/carte.php?num\\_car=1310&lang=en](http://www.d-maps.com/carte.php?num_car=1310&lang=en)” with some modifications

Department, CVRL, Soba, Khartoum), then dissolved into 0.5 ml of sterile distilled water, kept at  $-20^{\circ}\text{C}$ . PPRV vaccine was the positive control PPRV antigen used in the study.

### 2.3 | Sample collection and preparation

Pneumonic lung samples were collected from clinically apparently healthy camels, showed no signs of illness at ante-mortem examination, from Tambul slaughterhouse during the period from November to December, 2018. Hundred lung samples were collected from camels regardless of their sex, age and breed, despite the fact that most of the camels brought to the slaughterhouse were females. Lung samples were collected aseptically based on presence of the pneumonic signs at the tissue level, preserved into sealed plastic bags and kept frozen at  $-20^{\circ}\text{C}$ .

Subsequently, 20% tissue homogenate containing the viral antigen was prepared from camel pneumonic lung samples in phosphate buffer saline (PBS; pH 7.2–7.4), supplemented with antibiotics (1 ml of Penicillin [200 IU/ml], 1 ml of Streptomycin [100  $\mu\text{g}/\text{ml}$ ], 1 ml of Gentamycin [10,000  $\mu\text{g}/\text{ml}$ ]) and antifungal (0.5 ml of Fungizone [50,000 IU/ml]), following the standard procedure, distributed into Eppendorf tubes and stored at  $-20^{\circ}\text{C}$ . The homogenate was used as an antigen source for PPRV.

### 2.4 | Preparation of red blood cells suspension

Whole blood was collected, from healthy non-immunized chickens, in vacutainers containing anticoagulant "Alsever's solution", red blood cells (RBCs) were washed three times and 1% of chicken RBCs suspension was prepared in PBS (pH 6.8) following the standard procedure. RBCs suspension was used as an indicator for demonstrating the haemagglutination (HA) properties of PPRV.

### 2.5 | Haemagglutination test

The HA test was used for identification of PPRV antigen and for quantifying the HA titre of the virus in the 20% tissue suspension. The procedure of the HA test for detection of PPRV antigen specifically was as described previously by Ezeibe et al. (2004) and Osman (2005) with some modifications for the test conditions. The HA test was performed in 96-well V-bottom microtitre HA plates using PBS (pH 6.8) as diluent.

Results of the HA test were optimized, for the camel samples, by employing 1% of chicken RBCs suspension, using PBS of pH 6.8 and the HA plate was incubated in a refrigerator at  $4^{\circ}\text{C}$  and observed for 15–20 min. When performing the HA test using these conditions, the HA results took 17–18 min, and elution quickly followed leading to the formation of the red button in the 19th min. Accordingly, the results must be taken within a strict time range between 17 and 18 min or the HA result will have disappeared (Figure 2). The

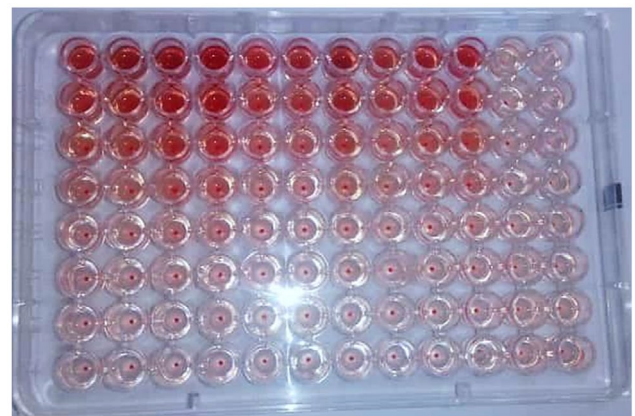
presence of a diffused sheet or film representing agglutinating RBCs caused by PPRV is considered a positive HA result. In contrast, negative HA result appeared as a sharp red button of non-agglutinated sediment RBCs formed due to absence of the haemagglutinating virus (Figure 2). RBCs control as well appeared as a sharp red button (Figure 2). The end-point dilution for the haemagglutinating virus was determined as the last well that showed complete HA of RBCs, and the end-point dilution is equal to one HA unit (1 HAU) which is the minimum amount of the virus that will cause complete agglutination of the RBCs. The HA titre of the virus in the homogenate was determined as the reciprocal of the end-point dilution and expressed as HAU.

## 3 | RESULTS

The majority of camels in the slaughterhouse showed no pneumonic signs at ante-mortem while some showed signs varying from mild to moderately severe in some cases. These signs included nasal discharges, an increased respiratory rate associated with severe emaciation. However, at post-mortem, regardless of the ante-mortem status, there were pneumonic lesions in the lungs including congestion of the lungs, fragility, changes in colour and thickness of the tissue and in some cases many abscesses were present.

Of the total 100 pneumonic camel lung samples screened using the HA test for the presence of PPRV antigen, 98 (98%) of the samples were positive while only 2 (2.0%) samples remained negative (Table 1). Results revealed the highest overall antigenic prevalence (98%) of PPRV in tested pneumonic camel lungs from Tambul slaughterhouse indicating exposure of these camels to PPRV or probably presence of subclinical infection.

Moreover, PPRV antigen detected from pneumonic camel lung samples revealed variable HA titres ranging between 4 and 256 HAU with mean titre of 14.4 HAU. Of note, one sample only



**FIGURE 2** Haemagglutination test plate for detection of peste des petits ruminants virus (PPRV) antigen showing positive haemagglutination (HA) result as a diffused sheet or film and negative HA result as a sharp red button of sediment red blood cells (RBCs). PPRV Control (Column 1), antigen samples (Columns 2–11) and RBCs control (Column 12), samples are in vertical position

End-point	HA Titre (HAU)	+ve (%)	-ve (%)
0	0	0 (0.0)	2 (2.0)
1/2	2	0 (0.0)	0 (0.0)
1/4	4	9 (9.0)	0 (0.0)
1/8	8	57 (57.0)	0 (0.0)
1/16	16	19 (19.0)	0 (0.0)
1/32	32	12 (12.0)	0 (0.0)
1/64	64	0 (0.0)	0 (0.0)
1/128	128	0 (0.0)	0 (0.0)
1/256	256	1 (1.0)	0 (0.0)
Total		98 (98.0)	2 (2.0)

**TABLE 1** Detection of peste des petits ruminants virus antigen in pneumonic camel lung samples by haemagglutination (HA) test

(1.0%) showed a very high HA titre of 256 HAU and apparently most of the samples (57.0%) achieved titre of 8 HAU (Table 1; Figure 3).

## 4 | DISCUSSION

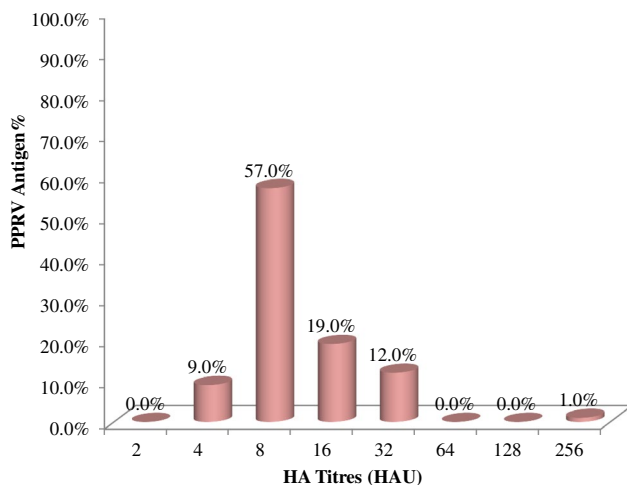
Peste des petits ruminants virus infection in camels was described as an epizootic disease that affected dromedaries at the beginning of the year 2000 in Ethiopia (Roger et al., 2000, 2001). The first report of PPRV infection in camels in the Sudan, and the global second after Ethiopia, was in 2004 (Khalafalla et al., 2010). Some PPRV-infected camels showed clinical signs while others were sub-clinically affected with detected antibodies to PPRV (Roger et al., 2001). In addition, PPRV antigens and nucleic acid were detected in samples from infected animals (Khalafalla et al., 2010). Both reports of PPRV outbreaks in camels in Ethiopia and the Sudan are in agreement with this study that camels can be infected with PPRV and harbour the viral antigen in their bodies. The presence of PPRV antibodies in Nigerian and Libyan camel's populations was also documented (EI-Dakhly, 2015; Woma et al., 2015). This survey was designed mainly to investigate the

possibility of camel infection with PPRV in Tambul area, regardless of its sex, age and breed, despite the fact that most of the camels brought to the slaughterhouse were females. Moreover, the aim of the study was to demonstrate the prevalence of PPRV antigens in camel lungs from Tambul slaughterhouse, Gezira State, Central Sudan.

In this study, generally some clinical signs were observed in camels at the ante-mortem examination including nasal discharges, an increased respiratory rate associated with severe emaciation. However, at post-mortem pneumonic lesions in the lungs included congestion of the lungs, fragility, changes in colour and thickness of the tissue and in some cases many abscesses were observed. Khalafalla et al. (2010) reported these necropsy findings of PPR in camels such as congestion and consolidation on the lung tissue, paleness and fragility of the liver, enlargement of lymph nodes, congestion and haemorrhage of the small intestines and stomach. Additionally, Zakian et al. (2016) reported presence of keratoconjunctivitis, congestion and consolidation of the lungs, paleness of the liver and enlargement and oedema of lymph nodes. In this study, few post-mortem lesions were observed which is attributed to presence of subclinical infection, however, in these studies more prominent lesions were observed in clinically infected camels.

A previous study to determine the role played by PPRV in causing respiratory infections in camels and its association with other respiratory viruses was performed using lung specimens showing pneumonia collected from clinically healthy camels in slaughterhouses at five different areas in the Sudan (Saeed et al., 2015). The highest prevalence of PPRV antigen (59.9%) was found in Central Sudan then in Northern Sudan (56.6%) and in Eastern Sudan (26.6%). This study agreed with that of Saeed et al. (2015).

In this study, the HA test was the diagnostic tool of choice for its rapidity and simplicity (Ezeibe et al., 2004; Osman et al., 2008; Wosu, 1985, 1991). In addition, the tools are commercially available to be conducted in a field condition not to mention its relatively cheap costs compared to other diagnostic tests which also require experienced personnel. It was previously proved that the test is useful in detecting PPRV antigen from tissue homogenate (Osman, 2005; Osman et al., 2008). Recently, the HA test was proved to be as sensitive as an immuno-capture enzyme-linked immunosorbent assay (IC-ELISA) for detection of PPRV in nasal swabs and fecal samples from clinically



**FIGURE 3** Peste des petits ruminants virus (PPRV) antigen detected at different haemagglutination titres by haemagglutination (HA) test

PPR suspected camels in Pakistan (Rahman et al., 2020). The HA test can be done using samples from dead or live animals including swabs (ocular, nasal and oral), faecal and various tissue samples to detect the presence of PPRV antigen (Abubakar et al., 2012; Latif et al., 2014; Liu et al., 2013; Manoharan et al., 2005; Zakian et al., 2016).

Higher haemagglutination titres were recorded with the use of 1% chicken RBCs suspension as described previously by Latif et al. (2014) instead of using 0.6% as described earlier by Ezeibe et al. (2004), Osman et al. (2008) and Wosu (1985, 1991). In addition, higher HA titres were obtained by incubating the plates at 4°C and at time ranging from 17 to 18 min as reported by Osman et al. (2008) and Wosu (1985, 1991).

The survey revealed that 98/100 of the camel samples reacted positively in the HA test with very high prevalence (98%) which is consistent with that published by Saeed et al. (2015) using IC-ELISA as a diagnostic tool. The findings also indicated that camels may have a transient PPRV infection and, therefore, could be involved in the epidemiology of the disease as had been described in many countries including Ethiopia, Sudan, Nigeria, Iran, Libya, Kenya and Pakistan (El-Dakhly, 2015; Khalafalla et al., 2010; Omani et al., 2019; Rahman et al., 2020; Roger et al., 2000, 2001; Saeed et al., 2015; Woma et al., 2015; Zakian et al., 2016). Considering that camels are clinically apparently healthy while harbouring PPRV thus can serve as a carrier for the disease and might transmit the virus to in-contact susceptible small ruminants in shared grazing areas. However, an experimental infection of dromedary camels in Morocco with a virulent strain of PPRV showed no clinical signs or viraemia and no virus was detected in the animal secretions. This result suggests that camels cannot be experimentally infected with PPRV which may be attributable to the type of the samples used (Fakri et al., 2019). In contrast, in animals with no clinical signs observed, the virus was demonstrated severally from camel lungs and tissues, with histological changes, suggesting an evidence of PPRV ability to infect camels in an in-apparent or subclinical form. Moreover, beside identification of PPRV as a causative agent of PPR associated with pneumonia in camels (Khalafalla et al., 2010; Roger et al., 2000, 2001), there are other possibilities that other infectious agents "bacteria, other respiratory viruses or parasites" or a combination of factors are the cause of the pneumonic lesions in the lung tissues of camels (cited in Ayelet et al., 2013; Saeed et al., 2015). A study on the histopathology of pneumonic lungs of camels in the Sudan showed that the cause of the pneumonia in camels is a viral agent, suggesting the fact that camel's pneumonia is mostly due to viral factor (Muna et al., 2015).

In recent years, PPRV infection in camels caused in-apparent subclinical or severe disease associated with high morbidity and mortality rates among camel populations and in some cases the virus could be isolated from clinically apparently healthy animals. PPRV is a member of RNA virus groups which are characterized by high mutation rates, high yields and short replication time giving the virus the chance to mutate and convert into a high virulence strain. This feature sometimes can explain the fatality nature of the disease (Domingo & Holand, 1997).

Future research studies are need to investigate the role that camels may play as a transmitter and/or a reservoir of the disease,

for the possibility of virus transmission from camels to susceptible in-contact small ruminants and other animal species in order to determine the role of camels in the epidemiology of PPR in the Sudan.

## 5 | CONCLUSION

Results indicated the highest overall antigenic prevalence (98%, 98/100 lung tissues) of PPRV in pneumonic lungs from clinically apparently healthy camels from Tambul slaughterhouse indicating exposure of these camels to PPRV. The findings of this study concluded that PPRV-infected camel species in an in-apparent or subclinical form led to pneumonia. The disease in camels is characterized by appearance of many pathological lesions on the lung tissue including congestion of the tissue, abscesses, fragility and change in colour.

Infection of species other than small ruminants suggests the fact that camels are potential hosts for PPRV and might play a role (or not) in the epidemiology of the disease. Further studies are needed to demonstrate if camels are able to transmit PPRV for in-contact small ruminants or other animal species.

## ACKNOWLEDGEMENTS

We are grateful to the staff of the Camel Research Center, Tambul, for helping in samples collection, to the staff of the departments of Virology; Molecular Biology and the Viral Vaccine Production, the Central Veterinary Research Laboratory, Soba for assistance with the laboratory experiment.

## CONFLICT OF INTERESTS

The authors declare that there is no conflict of interest.

## AUTHOR CONTRIBUTION

**Nahid A.S. Abdalla:** Formal analysis; Investigation; Methodology; Writing-original draft. **Alaa E.M. Alhussain:** Methodology. **Sana I. Mohammed:** Methodology. **Mihad Hakeem:** Methodology. **Ihsan H. Ahmed:** Methodology. **Galal E. Mohammed:** Writing-review & editing. **Nussieba A. Osman:** Data curation; Formal analysis; Funding acquisition; Investigation; Methodology; Project administration; Supervision; Writing-original draft; Writing-review & editing.

## ETHICAL STATEMENT

The authors confirm that the ethical policies of the journal, as noted on the journal's author guidelines page, have been adhered to. No ethical approval was required for samples collected from slaughter house.

## PEER REVIEW

The peer review history for this article is available at <https://publons.com/publon/10.1002/vms3.457>.

## ORCID

Nussieba A. Osman  <https://orcid.org/0000-0001-6224-8376>

## REFERENCES

- Abubakar, M., Arshed, M. J., Zahur, A. B., Ali, Q., & Banyard, A. C. (2012). Natural infection with peste des petits ruminants virus: A pre and post vaccinal assessment following an outbreak scenario. *Virus Research*, 167(1), 43–47. <https://doi.org/10.1016/j.virusres.2012.03.018>
- Ayelet, G., Negash, W., Sisay, T., Jenberie, S., & Gelaye, E. (2013). Investigation of respiratory viruses in camel slaughtered at Addis Ababa Akaki Abattoir, Ethiopia. *African Journal of Agricultural Research*, 8(37), 4580–4587. <https://doi.org/10.5897/ajar12.1590>
- Diallo, A. (2003). Peste des petits ruminants. Retrieved from [www.india-nveterinarycommunity.com](http://www.india-nveterinarycommunity.com)
- Domingo, E., & Holland, J. J. (1997). RNA virus mutations and fitness for survival. *Annual Review of Microbiology*, 51, 151–178. <https://doi.org/10.1146/annurev.micro.51.1.151>
- El-Dakhly, A. T. (2015). Serological survey for peste des petits ruminants virus (PPRV) in camel from different regions in the west of Libya. *International Journal of Science and Research*, 4(3), 1455–1459.
- Ezeibe, M. C. O., Wosu, L. O., & Erumaka, I. G. (2004). Standardisation of the haemagglutination test for peste des petits ruminants (PPR). *Small Ruminant Research*, 51(3), 269–272. [https://doi.org/10.1016/S0921-4488\(03\)00123-8](https://doi.org/10.1016/S0921-4488(03)00123-8)
- Fakri, F. Z., Bamouh, Z., Jazouli, M., Omari Tadlaoui, K., & Elharrak, M. (2019). Experimental infection of dromedary camels with virulent virus of Peste des Petits Ruminants. *Veterinary Microbiology*, 235, 195–198. <https://doi.org/10.1016/j.vetmic.2019.07.004>
- FAO. (2015). *Peste des petits ruminants*. Food and Agricultural Organization for the United Nation. Retrieved from <http://www.fao.org/ppr/en/>
- Gargadennec, L., & Lalanne, A. (1942). La peste des petits ruminants. *Bulletin des Services Zootechniques et des Epizooties de L'Afrique Occidentale Française*, 5(1), 16–21.
- Gibbs, E. P. J., Taylor, W. P., Lawman, M. J. P., & Bryant, J. (1979). Classification of peste des petits ruminants virus as the fourth member of the genus morbillivirus. *Intervirology*, 11, 268–274. <https://doi.org/10.1159/000149044>
- Khalafalla, A. I., Saeed, I. K., Ali, Y. H., Abdurrahman, M. B., Kwiatek, O., Libeau, G., Obeida, A. A., & Abbas, Z. (2010). An outbreak of peste des petits ruminants (PPR) in camels in the Sudan. *Acta Tropica*, 116(2), 161–165. <https://doi.org/10.1016/j.actatropica.2010.08.002>
- Kwiatek, O., Ali, Y. H., Saeed, I. K., Khalafalla, A. I., Mohamed, O. I., Obeida, A. A., Abdelrahman, M. B., Osman, H. M., Taha, K. M., Abbas, Z., El Harrak, M., Lhor, Y., Diallo, A., Lancelot, R., Albina, E., & Libeau, G. (2011). Asian lineage of peste des petits ruminants virus, Africa. *Emerging Infectious Diseases*, 17(7), 1223–1231. <https://doi.org/10.3201/eid1707.101216>
- Latif, A., Akhtar, Z., Ullah, R. W., Zahur, A. B., Ullah, A., Irshad, H., Malik, A. R., Hussain, M., Mahboob, K., & Afzal, S. (2014). Evaluation of haemagglutination assay (HA) for the detection of peste des petits ruminants virus (PPRV) in faecal samples of recovered goats. *Research Journal for Veterinary Practitioners*, 2(1), 11–13.
- Liu, W., Wu, X., Wang, Z., Bao, J., Li, L., Zhao, Y., & Li, J. (2013). Virus excretion and antibody dynamics in goats inoculated with a field isolate of peste des petits ruminants virus. *Transboundary and Emerging Diseases*, 60(2), 63–68.
- Maes, P., Amarasinghe, G. K., Ayllón, M. A., Basler, C. F., Bavari, S., Blasdel, K. R., Briese, T., Brown, P. A., Bukreyev, A., Balkema-Buschmann, A., Buchholz, U. J., Chandran, K., Crozier, I., de Swart, R. L., Dietzgen, R. G., Dolnik, O., Domier, L. L., Drexler, J. F., Dürwald, R., ... Kuhn, J. H. (2019). Taxonomy of the order Mononegavirales: Second update. *Archives of Virology*, 164(4), 1233–1244. <https://doi.org/10.1007/s00705-018-04126-4>
- Manoharan, S., Jayakumar, R., Govindarajan, R., & Koteeswaran, A. (2005). Haemagglutination as a confirmatory test for peste des petits ruminants diagnosis. *Small Ruminant Research*, 59, 75–78. <https://doi.org/10.1016/j.smallrumres.2004.12.002>
- Muna, E. A., Ali, Y. H., Zakia, A. M., Abeer, A. M., Halima, M. O., & Manal, H. S. (2015). Histopathology of multiple viral infections in lung of camel (*Camelus dromedaries*) in Sudan. *IOSR Journal of Agriculture and Veterinary Science*, 8(11), 89–94.
- OIE. (2019). Peste des petits ruminants (Infection with peste des petits ruminants virus). In *Manual of diagnostic tests and vaccines for terrestrial animals* (7th edn., Chapter 3.7.9). Paris: Office international des Epizooties (OIE). <https://www.oie.int/standard-setting/terrestrial-manual/access-online/>
- Omani, R. N., Gitao, G. C., Gachohi, J., Gathumbi, P. K., Bwihangane, B. A., Abbey, K., & Chemweno, V. J. (2019). Peste Des Petits Ruminants (PPR) in Dromedary Camels and Small Ruminants in Mandera and Wajir Counties of Kenya. *Advances in Virology*, 1–6. <https://doi.org/10.1155/2019/4028720>
- Osman, N. A. (2005). *Peste des petits ruminants in Sudan: Detection, virus isolation and identification, pathogenesis and serosurveillance*. Thesis for master degree, University of Khartoum, Sudan.
- Osman, N. A., A/Rahman, M. E., Ali, A. S., & Fadol, M. A. (2008). Rapid detection of peste des petits ruminants (PPR) virus antigen in Sudan by agar gel precipitation (AGPT) and haemagglutination (HA) tests. *Tropical Animal Health and Production*, 40(5), 363–368. <https://doi.org/10.1007/s11250-007-9106-1>
- Parida, S., Muniraju, M., Mahapatra, M., Muthuchelvan, D., Buczkowski, H., & Banyard, A. C. (2015). Peste des petits ruminants. *Veterinary Microbiology*, 181(1–2), 90–106. <https://doi.org/10.1016/j.vetmic.2015.08.009>
- Rahman, H., Kamboh, A. A., Abro, S. H., & Abubakar, M. (2020). An investigation on the prevalence of peste des petits ruminants in the camels of Sindh, Pakistan. *Tropical Animal Health and Production*, 52(4), 1863–1867. <https://doi.org/10.1007/s11250-020-02202-z>
- Roger, F., Guebre Yesus, M., Libeau, G., Diallo, A., Yigezu, L. M., & Yilma, T. (2001). Detection of antibodies of rinderpest and peste des petits ruminants viruses (Paramyxoviridae, Morbillivirus), during a new epizootic disease in Ethiopian camels (*Camelus dromedarius*). *Revue de Médecine Veterinaire*, 152(3), 265–268.
- Roger, F., Yigezu, L. M., Hurard, C., Libeau, G., Mebratu, G. Y., Diallo, A., & Faye, B. (2000). Investigations on a new pathological condition of camels in Ethiopia. *Journal of Camel Practice and Research*, 7(2), 163–165.
- Saeed, I. K., Ali, Y. H., AbdulRahman, M. B., Mohammed, Z. A., Osman, H. M., Taha, K. M., Musa, M. Z., & Khalafalla, A. I. (2015). Mixed infection of peste des petits ruminants virus (PPRV) and other respiratory viruses in dromedary camels in Sudan, an abattoir study. *Tropical Animal Health and Production*, 47(5), 995–998. <https://doi.org/10.1007/s11250-015-0798-3>
- Woma, T. Y., Kalla, D. J. U., Ekong, P. S., Ularanu, H. G., Chollom, S. C., Lamurde, I. I., Bajehson, D. B., Tom, N. D., Aaron, G. B., Shamaki, D., Bailey, D., Diallo, A., & Quan, M. (2015). Serological evidence of camel exposure to peste des petits ruminants virus (PPRV) in Nigeria. *Tropical Animal Health and Production*, 47, 603–606. <https://doi.org/10.1007/s11250-014-0747-6>
- Wosu, L. O. (1985). Agglutination of red blood cells by peste des petits ruminants (PPR) virus. *Nigerian Veterinary Journal*, 14, 56–58.
- Wosu, L. O. (1991). Haemagglutination test for diagnosis of peste des petits ruminants disease in goats with samples from live animals. *Small Ruminant Research*, 5, 169–172. [https://doi.org/10.1016/0921-4488\(91\)90041-N](https://doi.org/10.1016/0921-4488(91)90041-N)
- Zakian, A., Nouri, M., Kahroba, H., Mohammadian, B., & Mokhber-Dezfouli, M. R. (2016). The first report of peste des petits ruminants (PPR) in camels (*Camelus dromedarius*) in Iran. *Tropical Animal Health and Production*, 48, 1215–1219. <https://doi.org/10.1007/s11250-016-1078-6>

**How to cite this article:** Abdalla NAS, Alhussain AEM, Mohammed SI, et al. Detection of peste des petits ruminants virus in pneumonic lungs from clinically apparently healthy camels slaughtered at Tambul slaughter house, central Sudan. *Vet Med Sci*. 2021;7:1166–1171. <https://doi.org/10.1002/vms3.457>