

Iliosacral screw corridors in Japanese subjects: a study using reconstruction CT scans

Toru Iga, MD

Abstract

Objectives: To investigate the characteristics of iliosacral (IS) screw corridors of Japanese pelvises.

Methods: Computer tomography images of 42 adult Japanese subjects without any pelvic injury were analyzed at a workstation. Using the manual reconstruction function, the width of a simulated horizontal corridor for an IS screw on the true coronal and true axial planes in the upper (S1), second (S2), and the third (S3) sacral segments was measured. For pelvises without an adequate S1 corridor, a cranially tilted corridor was sought. A corridor was defined as “adequate” if its width on both planes was 10mm or more.

Results: An adequate horizontal corridor was found in S1 in 17 (40.5%) subjects, in S2 in 29 (69.0%) subjects, and in S3 in no subject. An independent factor affecting the adequacy of the S1 corridor was the adequacy of the S2 corridor (OR: 0.09). Similarly, an independent factor affecting S2 adequacy was S1 adequacy (OR: 0.10). A tilted, 10mm diameter corridor was found in all 25 subjects who did not have an adequate horizontal corridor in the S1 segment. The angle required to obtain a 10mm diameter corridor inversely correlated with the diameter of a horizontal corridor on the true coronal plane ($R = -0.713$, $P = .000$).

Conclusions: The characteristics of IS screw corridors in the 42 Japanese subjects were similar to those reported in previous studies conducted in the West. The importance of preoperative planning using reliable techniques, such as three-dimensional reconstruction, should be emphasized.

Level of evidence: Diagnostic Level III. See Instructions for Authors for a complete description of level of evidence.

Keywords: iliosacral screw, pelvic fracture, sacral dysmorphism

1. Introduction

Iliosacral (IS) screw fixation is widely practiced for posterior stabilization of unstable pelvic ring fractures.^[1,2] The merit of this procedure is that the surgical insult is smaller than with open surgery. Thus, it has also been used to treat fragility fractures of the pelvis in elderly patients.^[3] A screw can be directed horizontally or antero-cranially in the upper sacral (S1) segment, depending on the fracture configuration and sacral morphology. When a screw is inserted horizontally, its tip can be advanced to the outer cortex of the contralateral ilium (transiliac-transsacral screw [TITS]). A TITS provides better stability than unilateral fixation owing to the distribution of the vertical shear load and engagement of more threads in the bone.^[4,5] When a screw is inserted antero-cranially, its trajectory is perpendicular to the

joint. This fixation is preferred for sacroiliac dislocations. In the second sacral (S2) segment, the screw direction is limited to the horizontal, but TITS insertion is possible. Fixation is just as commonly practiced in the S2 segment as in the S1 segment.^[4,6] Recently, a number of studies suggested the availability of the third sacral (S3) segment for this purpose.^[7,8] In each segment, a screw is placed into the intraosseous corridor in the posterior pelvic ring. The boundary of the S1 corridor is formed by the iliac fossa, iliac cortical density, sacral ala, anterior cortex of the sacral body, sacral root foramina, and spinal canal.^[9–11] The S2 corridor is defined by the upper and second sacral foramina as well as the anterior sacral cortex and spinal canal. The border of the S3 corridor is similar to that of the S2 corridor inside the sacrum, but it should be noted that the ilium does not reach this level in all pelvises.^[7,12] A corridor must be wide enough to accommodate a 6.5mm or 7.3mm screw generally used for iliosacral fixation. However, since sacral morphology varies, a corridor is not always available. In patients with a dysmorphic sacrum characterized by an acute alar slope, horizontal screw insertion in the S1 segment is essentially impossible.^[9,13–15] Similarly, the width of the S2 varies, and its availability is inconsistent.^[13] Thus, the presence of corridors accommodating a screw should be confirmed preoperatively by computed tomography (CT).^[13,15,16] One or more screws are inserted surgically based on preoperative planning following the established technique under fluoroscopic control. Currently, more precise techniques using intraoperative CT or a navigation system have also been introduced.^[17,18] Either way, a screw must be placed inside the corridor to avoid iatrogenic damage to the surrounding neurovascular structures.^[19–22] Although the anatomy of sacral corridors has been described in detail elsewhere,^[13,19,23] few reports have focused on the relatively smaller

The author has no conflicts of interest to disclose.

Department of Orthopaedic Surgery, Tokyo Metropolitan Tama Medical Center, Fuchu, Tokyo

Corresponding author. Address: Department of Orthopaedic Surgery, Tokyo Metropolitan Tama Medical Center, 2-8-29 Musashidai, Fuchu, Tokyo 183-8524, Japan. E-mail: toru_iga@tmhp.jp (T. Iga).

Copyright © 2021 The Authors. Published by Wolters Kluwer Health, Inc. on behalf of the Orthopaedic Trauma Association.

This is an open access article distributed under the terms of the Creative Commons Attribution-Non Commercial-No Derivatives License 4.0 (CCBY-NC-ND), where it is permissible to download and share the work provided it is properly cited. The work cannot be changed in any way or used commercially without permission from the journal.

OTA (2021) e145

Received: 27 March 2021 / Accepted: 21 June 2021

Published online 6 August 2021

<http://dx.doi.org/10.1097/OI9.000000000000145>

body size of Asians.^[7] The aim of the present study was to identify safe IS screw corridors by analyzing the characteristics of uninjured pelvis in Japanese subjects. The hypothesis of the present, retrospective study was that the iliosacral screw corridor is less frequently available in Japanese patients than in patients of other ethnicities reported in previous studies conducted in the West. Recognition of ethnic differences in anatomy may help surgeons avoid inadvertent complications caused by orthopaedic implants.^[24,25]

2. Materials and methods

2.1. Materials

Patients who were transferred to our emergency department and underwent pelvic CT between April 2015 and March 2017 were identified. All the patients were Japanese. Those with a current or previous pelvic injury were excluded. The patients were categorized by age into the third (i.e., 20–29 years old) to the ninth (80–89 years old) decades of life. Three female and 3 male patients in each decade were selected in the order of their arrival date. Thus, 42 Japanese patients with an average age of 53.5 years comprising an even number of subjects for each gender and age group were enrolled for analysis. Their mean height was 161.7 (137–180) cm, and their mean body mass index was 21.9 (16.0–29.4) kg/m². The present study was approved by the institutional review board of Tokyo Metropolitan Tama Medical Center.

2.2. Measurement of corridors using CT images

Measurement was performed at a workstation (Shade Quest/View R, Yokogawa Medical Inc, Tokyo) where three-dimensional images were created manually out of 1-mm-slice volume data, and the axis was adjusted manually while maintaining a reciprocal 90° relationship, that is, the X-Y-Z axis (Figs. 1 and 2). An accurate mid-sagittal image was obtained first with reference to the pubic symphysis and the sacral median crest. On this image, the standard axis was determined in line with the S1-S2 body. In the present study, the upper sacral segment was represented as S1 regardless of the sacralized lumbar element observed in some subjects.^[15] Next, in accordance with previous reports,^[13,14] the conventional coronal plane was rotated on the

mid-sagittal image to obtain a true coronal image parallel to the standard axis resembling a fluoroscopic outlet view. At this point, the true axial image perpendicular to the true coronal image was displayed automatically. On the true coronal and true axial images, creation of an S1 horizontal screw corridor was simulated while avoiding screw penetration into the iliac fossa, iliac cortical density, sacral ala, sacral root foramina, and spinal canal.^[9] The corridor width was maximized and measured on each true coronal and true axial plane (Fig. 1). Similarly, the creation of S2 and S3 horizontal screw corridors for a TITS screw was simulated, and their width was measured.^[4,5,13] A corridor was defined as “adequate” if its width on both planes was 10 mm or more on the assumption that a 6.5 or 7.3 mm screw was to be inserted.^[13] For pelvis without an adequate S1 corridor, an antero-cranial corridor, which is wider than a horizontal corridor,^[11,13] was simulated by tilting the trajectory cranially on the true coronal plane. The trajectory was tilted cranially in a stepwise fashion until it achieved a 10 mm diameter, at which point the tilting angle (the minimal tilting angle [MTA] required to obtain a 10 mm diameter corridor) was measured (Fig. 2). Thus, the MTA represents the minimum inclination against the horizontal axis on the true coronal plane required to obtain a 10 mm corridor. The corridor was measured to confirm that its anteroposterior diameter was 10 mm or more and that its end passed the midline of the S1 body before penetrating the upper endplate.^[2] All measurements were done in triplicate for each subject by an attending surgeon with 25 years’ experience of orthopaedic trauma surgery, and the final measurement was used for analysis to eliminate the learning curve bias.

2.3. Statistical analysis

Statistical data were analyzed using SPSS version 21 (SPSS Inc, Chicago, Illinois). The relationship of gender with the adequacy of the corridor in each sacral segment was analyzed using a Fisher exact test. Similarly, the relationship of height with the adequacy of the corridors was analyzed by comparing the mean height of the subjects with an adequate and non-adequate corridor using a Student 2-tailed *t* test. The relationship of S1 adequacy to S2 adequacy in a pelvis was analyzed using a Fisher exact test. Binary logistic regression analysis was used to identify the weight of variables for adequacy. In pelvis without an adequate

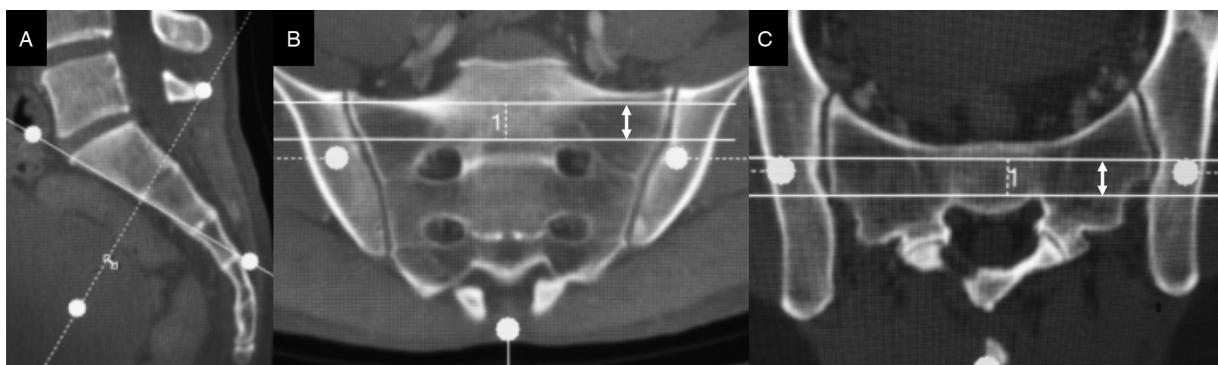


Figure 1. (A–C) Measurement of the horizontal corridor in the upper sacral segment on reconstructed CT images. As the standard axis was aligned with the anterior cortex in the mid-sagittal section (A), the true coronal images (B), and the true axial images (C), which were parallel and perpendicular, respectively, to the standard axis, were displayed automatically. On true coronal and true axial images, a corridor with the maximum width was sought while avoiding screw penetration outside the intraosseous corridor. The width on each plane was recorded (B and C, double-headed arrows). The same measurement was performed for the second and third horizontal corridors.

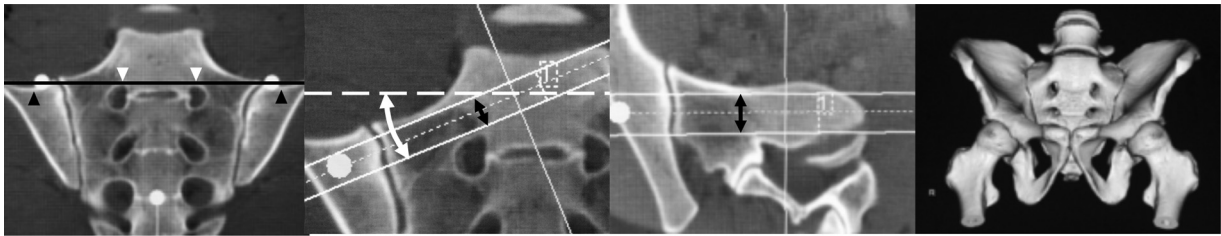


Figure 2. (A–D) Measurement of a cranially tilted corridor in subjects without an adequate horizontal corridor in the upper segment. (A) In this subject, a line tangent to the superior border of the upper sacral foramina (dashed line) passes antero-cranially to the iliac cortical density (ICD, arrowheads), indicating that the corridor was not measurable. (B) In such subjects, the trajectory of the corridor was tilted cranially on the true coronal plane, that is, antero-cranially to the longitudinal body axis, in a stepwise fashion until its width reached 10 mm. The angle between this tilted corridor and the horizontal axis was defined as the minimal tilting angle (MTA, double-headed arrow). (C) The width of the corridor was also measured on the tilted axial plane. (D) Three-dimensional image of the same subject.

horizontal corridor, the correlation between the MTA and width on the true coronal plane was evaluated using a correlation coefficient. If a measurable horizontal corridor did not exist, the width of the corridor was represented as 0. The statistical significance level was $P < .05$.

3. Results

3.1. Width and adequacy of each corridor

In the S1 segment, a measurable horizontal corridor was not able to be found in 4 subjects (9.5%). In the remaining 38 subjects, the mean width of the S1 horizontal corridor was 9.2 (2–19.8, SD 4.8) mm and 13.8 (7.4–21.8, SD 3.5) mm on the true coronal and the true axial planes, respectively. All the subjects had a measurable horizontal corridor in the S2 and S3 segments. The width of the S2 corridor was 11.2 (6.3–16.2, SD 2.2) and 11.0 (6.3–14.7, SD 1.9) mm, and the width of the S3 corridor was 4.7 (1.3–8.7, SD 1.7) and 6.3 (2.8–10.4, SD 2.0) mm on the true coronal and the true axial planes, respectively (Table 1). An adequate horizontal corridor was found in S1 in 17 (40.5%) subjects, in S2 in 29 (69.0%) subjects, and in S3 in none (Table 1).

3.2. Relationship of gender or height to the adequacy of the S1 or S2 corridor

Neither gender nor height was related to S1 corridor adequacy, but male gender ($P = .043$) and greater height ($P = .033$) were related to S2 corridor adequacy (Table 2).

3.3. Relationship of S1 and S2 corridor adequacy

Of the 17 pelvises with an adequate S1 horizontal corridor, 8 (47.1%) had an adequate S2 corridor whereas of 25 pelvises

without an adequate S1 corridor, 21 (84.0%) had an adequate S2 corridor. The pelvises without an adequate S1 corridor had a statistically higher frequency of an adequate S2 corridor ($P = .018$, Table 3).

3.4. Analysis of weight in factors affecting S1 and S2 corridor adequacy

One of the independent factors affecting S1 corridor adequacy was S2 adequacy (odds ratio [OR]: 0.09, 95% confidence interval [CI]: 0.02–0.6). Similarly, an independent factor affecting S1 corridor adequacy was S2 adequacy (OR: 0.1, 95% CI: 0.02–0.6). Neither gender nor height was an independent factor in S1 or S2 adequacy (Table 4).

3.5. Antero-cranially tilted corridor in subjects without an adequate S1 horizontal corridor

A tilted, 10 mm-wide corridor was able to be found in all 25 subjects without an adequate horizontal corridor in the S1 segment. All these tilted corridors passed the midline of the S1 body without penetrating the upper endplate of the S1 body, and their anteroposterior diameter was greater than 10 mm, indicating that they were capable of accommodating a screw.

The mean MTA in the 25 subjects without an adequate S1 corridor was 12.7 (1.0–27.1, SD 6.4) degrees. There was a strong negative correlation between the MTA and the width of the corridor on the true coronal plane ($R = -0.713$, $P = .000$).

4. Discussion

It is widely known that sacral morphology varies among individuals. In a dysmorphic sacrum, screw insertion in the S1 segment is hindered by an acute ala slope and an indentation in

Table 1

Width and adequacy of the upper, second, and the third sacral horizontal corridors

	Nonmeasurable	Average diameter (range, SD) (mm)		Adequate corridor
		True coronal plane	True axial plane	
S1	4 (9.5%)	9.2 (2–19.8, 4.8)*	13.8 (7.4–21.8, 3.5)*	17 (40.5%)
S2	0	11.2 (6.3–16.2, 2.2)	11.0 (6.3–14.7, 1.9)	29 (69.0%)
S3	0	4.7 (1.3–8.7, 1.7)	6.3 (2.8–10.4, 2.0)	0

A corridor was defined as "adequate" if its diameter on both planes was 10 mm or more.

S1 = upper sacral segment; S2 = second sacral segment; S3 = third sacral segment.

*Four sacra with a nonmeasurable S1 corridor were excluded.

Table 2
Comparison of demographic data in terms of upper and second sacral corridor adequacy

	Gender		Height	
	Male	Female	Average	SD
S1				
Adequate	9	12	164.8	-9.1
Inadequate	8	13	159.6	-9.3
P	1	.823		
S2				
Adequate	18	3	163.9	-8.6
Inadequate	11	10	156.8	-9.7
P	.043	.033		

A corridor was defined as "adequate" if its diameter on both planes was 10 mm or more. S1 = upper sacral segment; S2 = second sacral segment; SD = standard deviation.

the anterior cortex of the alae.^[9] Accordingly, a horizontal corridor for TITS is virtually impossible, but an antero-cranial corridor may be available.^[13,14,23] The frequency of dysmorphic sacra is reportedly as high as 28% to 53%.^[9,13,26] Surgeons should therefore account for this anatomic variability to achieve safe screw placement.

The dysmorphic sacrum is characterized by 6 radiographic findings: absence of sacral recession within the pelvis, mamillary processes, dysmorphic sacral foramen, acute alar slope, residual disc space between the S1 and S2 segments, and specific sacroiliac articulations.^[9] Knowledge of these characteristics helps predict difficulties with screw insertion in the S1 segment prior to surgery and is used universally in screening for a narrow S1 corridor in clinical practice.^[13] However, in this study, the author refrained from attempting to determine the frequency of dysmorphic sacra for the following reasons. First, identifying dysmorphic sacra on the basis of these findings can depend heavily on the surgeon's experience since it is unclear how many of these radiographic findings need to be present to satisfy the criteria.^[9,13,23] Thus, classifying sacra with a transitional morphology between normal and dysmorphic is difficult. Secondly, even in sacra classified as non-dysmorphic by expert surgeons, a horizontal corridor capable of accommodating a screw may not be present in as many as 25% of cases,^[13] indicating that the adequacy of a corridor should be evaluated by using CT even when a sacrum is not diagnosed as dysmorphic with the aforementioned radiographic characteristics. Therefore, in practice, CT is eventually necessary to verify the adequacy of the screw. Based on these considerations, the present study refrained from attempting to evaluate pelvic dysmorphism using the radiographic criteria mentioned above and instead focused on the adequacy of the

Table 3
Relationship of upper and second sacral segment adequacy

	S2	
	Adequate	Inadequate
S1		
Adequate	8	9
Inadequate	21	4

A corridor was defined as "adequate" if its diameter on both planes was 10 mm or more. Sacra without an adequate S1 corridor were more frequently accompanied by an adequate S2 corridor. S1 = upper sacral segment; S2 = second sacral segment. (P=.018, Fisher exact test).

Table 4
Binary logistic regression analysis of patient-related variables with respect to upper and the second sacral segment adequacy

	Gender	Height
	S1	
Odds ratio (95% CI)	3.6 (0.5-28.1)	1.0 (0.9-1.1)
P	.215	.879
S2		
Odds ratio (95% CI)	5.7 (0.6-54.3)	1.0 (0.8-1.1)
P	.129	.413

CI = confidence interval; S1 = upper sacral segment; S2 = second sacral segment.

corridors as defined by measurements on CT reconstruction images.

The width or adequacy of corridors has been evaluated using several methods. Gardner et al^[13] described measuring the true coronal and axial planes with the axes parallel to the sacral body based on reconstruction technology and simulations of the intraoperative fluoroscopic outlet and inlet views, a method which was also used by other authors.^[14,15] This method has proved to be capable of providing a more accurate measurement of corridor diameter than conventional CT imaging^[16] and has the potential as the standard modality for preoperative planning due to its accessibility and accuracy. Another report described using sagittal images for a quick evaluation of screw adequacy.^[5] Recently, three-dimensional (3D) analysis with transparent CT^[7,15] or a novel computer script^[15] was introduced for precision analysis of corridors and apparently provides the most accurate measurements although the modality is not available at every facility.

A previous report by Gardner et al^[13] using the same measurements and cut-off values for adequate corridors as the present study, i.e., a diameter equal to or greater than 10 mm on both the true coronal and true axial planes, found that the frequency of adequate S1 and S2 horizontal corridors was 42% and 72%, respectively. Our findings agreed with their data. In another study by Wagner et al^[7] using transparent CT, the frequency of S1 and S2 horizontal corridors with a cut-off value of 12 mm was 48% and 78%, respectively. This relatively higher frequency of adequate corridors despite the stricter cut-off value in the latter study may be attributed to the greater accuracy of transparent CT, suggesting that there may have been a tendency to underestimate the diameter on the 3D sectional images used in the present study. In terms of ethnic differences, Wagner reported that a horizontal S1 corridor with a diameter of 12 mm or less was more frequently observed in Japanese subjects (63%) than in European subjects (45%).^[7] Although these findings are affected by different measurement apparatuses and cut-off values, they suggest that an S1 horizontal corridor is less feasible in Japanese subjects. With regard to the S3 segment, a horizontal corridor with a diameter > 8 mm was observed in only 15% of pelvis even on transparent CT. Our study identified no adequate horizontal corridors, suggesting that the S3 horizontal corridor may be unfeasible.

On univariate analysis, the adequacy of S1 corridors was not related to either gender or height. This finding was consistent with the fact that S1 adequacy depends on the sacral morphology itself, that is, the presence of dysmorphisms.^[9,13] In contrast, adequate S2 corridors were related to male gender and greater height, implying that S2 corridor adequacy is affected by skeletal size. However, a statistically significant inverse relationship

between S1 and S2 adequacy was also found. This was in line with the results of previous studies demonstrating that the S2 corridor is wider in dysmorphic than normal sacra^[13,23] and that the width of the S1 corridor is inversely correlated to that of the S2 corridor,^[7] that is, morphology affects the S2 corridor as well as the S1 corridor. Multivariate analysis performed to identify the independent factors in the adequacy of each corridor found that S2 adequacy was the only independent factor in S1 adequacy and vice versa.

In the 25 pelves without an adequate S1 horizontal corridor, which were virtually equivalent to dysmorphic sacra,^[26] presence of an oblique corridor was sought by tilting their trajectory cranially on the true coronal plane. As a result, all the sacra were found to have a 10 mm oblique corridor capable of accommodating a screw and reaching at least the midline of the S1 body. Thus, in the present series, there were no pelves without an adequate S1 corridor in any direction. In a previous study, a 10 mm diameter corridor in any direction in the S1 segment was detected in 96% of the cases, with the remaining 4% having a corridor < 10 mm.^[13] Overall, it can be said that a corridor with 10 mm width in any direction is present in almost all pelves. To evaluate the obliquity of the corridors, the MTA, the angle needed to obtain a 10 mm diameter corridor on the true coronal plane against the horizontal axis, was used instead of the angle at the center of the corridor. Therefore, this study did not seek to ascertain the maximum diameter of a tilted S1 corridor. The advantage of using the MTA is that its definition is clearer than that of the center of the corridor. Moreover, surgeons can use the MTA intraoperatively because the true coronal plane simply simulates the fluoroscopic outlet view. In practice, the trajectory can be adjusted on the true axial plane as well by the surgeon's decision. The MTA ranged from 1.0° to 27.1° (average: 12.7°, SD: 6.4) and was inversely correlated with the width of the corridor on the true coronal plane, indicating morphological variety and need for patient-specific planning. In a previous study, safe corridors were assessed using simulations by tilting on both the true coronal and true axial planes. In dysmorphic sacra, the average tilt of the angle on the true coronal and true axial planes was 30.3° cranially (SD: 4.6) and 14.9° anteriorly (SD: 9.0), respectively.^[13]

Based on all the findings of the present study, the following protocol for preoperative planning may be recommended: True coronal and true axial images resembling the fluoroscopic outlet and inlet views are reconstructed from one-millimeter-slice volume CT data. A 10 mm, horizontal corridor of each segment is tested using these images. If the width of the S1 corridor is < 10 mm, the trajectory is tilted cranially on the true coronal plane in a stepwise fashion. Once the width reaches 10 mm, the angle is documented for use intraoperatively.

The limitations of this study were the small sample size and lack of comparative data. Ideally, a comparative study with an ample subject pool is needed to identify morphological differences in ethnicity. Since most of the patients in our facility were Japanese, a comparative study was not able to be done. Also, it was not possible to compare our results statistically with that of other studies due to the inability to obtain individual subject data or differences in the measurement apparatuses and cut-off values. Another limitation may be that there was only one examiner. No matter how reliable the measurements used in this study are,^[13–15] multiple examiners would have been able to provide more precise data. Nonetheless, the present study was the first to examine IS screw corridors in Japanese subjects and may contribute to identifying morphological variations in ethnicity if a

similar study is performed in the future with subjects of a different ethnicity.

In conclusion, a surgically adequate, safe, horizontal corridor for IS screw placement was present in less than half of 42 Japanese subjects at S1, in two-thirds of subjects at S2, and in none of the subjects at S3 when using standard, orthogonal screw orientation based on reconstructed CT images. S2 adequacy was the only independent factor in S1 adequacy and vice versa. In 25 subjects without an adequate S1 horizontal corridor, there was a safe corridor for an oblique screw path, indicating that all the subjects in the present study had an adequate S1 corridor in some direction. These results were broadly in line with the findings of previous studies conducted in the West. Recognition of morphological variations and the importance of preoperative planning using reliable equipment, such as a 3D reconstruction, should be emphasized.

Acknowledgment

The author thank Mr. James R Valera, our in-house editor, for his assistance with editing the manuscript in English.

The present study used a modified version of a measurement technique described in “Quantification of the Upper and Second Sacral Segment Safe Zones in Normal and Dysmorphic Sacra,” which was previously published in the *Journal of Orthopaedic Trauma*. Some data from the above-mentioned source were used in the present study when discussing the findings of previous studies.

References

1. Matta JM, Saucedo T. Internal fixation of pelvic ring fractures. *Clin Orthop Relat Res*. 1989;242:83–97.
2. Routt MLC, Meier MC, Kregor PJ, et al. Percutaneous iliosacral screws with the patient supine technique. *Oper Tech Orthop*. 1993;31:35–45.
3. Rommens PM, Arand C, Hofmann A, et al. When and how to operate fragility fractures of the pelvis? *Indian J Orthop*. 53;1:128–137.
4. Gardner MJ, Routt MLC. Transiliac—transsacral screws for posterior pelvic stabilization. *J Orthop Trauma*. 2011;25:378–384.
5. Lucas JF, Lee M, Routt C, et al. A useful preoperative planning technique for transiliac—transsacral screws. *J Orthop Trauma*. 2017; 31:25–31.
6. Moed BR, Geer BL. S2 iliosacral screw fixation for disruptions of the posterior pelvic ring: a report of 49 cases. *J Orthop Trauma*. 2006; 20:378–383.
7. Wagner D, Kamer L, Sawaguchi T, et al. Critical dimensions of trans-sacral corridors assessed by 3D CT models: relevance for implant positioning in fractures of the sacrum. *J Orthop Res*. 2017;35:2577–2584.
8. Dilogo IH, Fiolin J. Surgical technique of percutaneous iliosacral screw fixation in S3 level in unstable pelvic fracture with closed degloving injury and morrell lavallee lesion: two case reports. *Int J Surg Case Rep*. 2017;38:43–49.
9. Routt ML, Simonian PT, Agnew SG, et al. Radiographic recognition of the sacral alar slope for optimal placement of iliosacral screws: a cadaveric and clinical study. *J Orthop Trauma*. 1996;10:171–177.
10. Wagner D, Kamer L, Sawaguchi T, et al. Morphometry of the sacrum and its implication on trans-sacral corridors using a computed tomography data-based three-dimensional statistical model. *Spine J*. 2017;17:1141–1147.
11. Carlson DWA, Scheid DK, Maar DC, et al. Safe placement of S1 and S2 iliosacral screws: the “Vestibule” concept. *J Orthop Trauma*. 2000; 14:264–269.
12. Radetzki F, Wohlrab D, Goehre F, et al. Anatomical conditions of the posterior pelvic ring regarding bisegmental transverse sacroiliac screw fixation: a 3D morphometric study of 125 pelvic CT datasets. *Arch Orthop Trauma Surg*. 2014;134:1115–1120.
13. Gardner MJ, Morshed S, Nork SE, et al. Quantification of the upper and second sacral segment safe zones in normal and dysmorphic sacra. *J Orthop Trauma*. 2010;24:622–629.

14. Morshed S, Choo K, Kandemir U, et al. Internal fixation of posterior pelvic ring injuries using iliosacral screws in the dysmorphic upper sacrum. *J Bone Joint Surg Am.* 2015;96:1–13.
15. Lee JJ, Rosenbaum SL, Martusiewicz A, et al. Transsacral screw safe zone size by sacral segmentation variations. *J Orthop Res.* 2015;33:277–282.
16. McAndrew CM, Merriman DJ, Gardner MJ, et al. Standardized posterior pelvic imaging: use of CT Inlet and CT outlet for evaluation and management of pelvic ring injuries. *J Orthop Trauma.* 2014;28:665–673.
17. Pieske O, Landersdorfer C, Trumm C, et al. CT-guided sacroiliac percutaneous screw placement in unstable posterior pelvic ring injuries: accuracy of screw position, injury reduction and complications in 71 patients with 136 screws. *Injury.* 2015;46:333–339.
18. Takao M, Nishii T, Sakai T, et al. Iliosacral screw insertion using CT-3D-fluoroscopy matching navigation. *Injury.* 2014;45:988–994.
19. Routt MLC, Kregor PJ, Simonian PT, et al. Early results of percutaneous iliosacral screws placed with the patient in the supine position. *J Orthop Trauma.* 1995;9:207–214.
20. Routt MLC, Simonian PT, Inaba J. Iliosacral screw complications. *Oper Tech Orthop.* 1997;7:206–220.
21. Routt MLC, Simonian PT, Mills WJ. Iliosacral screw fixation: early complications of the percutaneous technique. *J Orthop Trauma.* 1997; 11:584–589.
22. Sagi HC, Lindvall EM. Inadvertent intraforaminal iliosacral screw placement despite apparent appropriate positioning on intraoperative fluoroscopy. *J Orthop Trauma.* 2005;19:130–133.
23. Conflitti JM, Graves ML, Routt MLC. Radiographic quantification and analysis of dysmorphic upper sacral osseous anatomy and associated iliosacral screw insertions. *J Orthop Trauma.* 2010;24:630–636.
24. Roberts JW, Libet LA, Wolinsky PR. Who is in danger? Impingement and penetration of the anterior cortex of the distal femur during intramedullary nailing of proximal femur fractures: preoperatively measurable risk factors. *J Trauma Acute Care Surg.* 2012;73:249–254.
25. Sintini I, Burton WS, Sade P, et al. Investigating gender and ethnicity differences in proximal humeral morphology using a statistical shape model. *J Orthop Res.* 2018;36:3043–3052.
26. Kaiser SP, Gardner MJ, Liu J, et al. Anatomic determinants of sacral dysmorphism and implications for safe iliosacral screw placement. *J Bone Joint Surg Am.* 2014;120:1–8.