



Case report

Transient extremely shallow anterior chamber caused by ciliochoroidal detachment in a patient with *Mycobacterium chelonae* keratitis

Issei Nishiyama^a, Yoshinori Oie^{a,*}, Kenji Matsushita^a, Shizuka Koh^a, Andrew Winegarner^b, Kohji Nishida^a

^a Department of Ophthalmology, Osaka University Graduate School of Medicine, Suita, Osaka, Japan

^b Department of Ophthalmology, University of Kansas Medical Center, School of Medicine, Kansas City, KS, USA

ARTICLE INFO

Keywords:

Mycobacterium chelonae keratitis
Ciliochoroidal detachment
Anterior segment optical coherence tomography

ABSTRACT

Purpose: To report a case of *Mycobacterium chelonae* keratitis that resulted in a transient reduction of anterior chamber depth.

Observations: A 46-year-old man with keratoconus and reduced visual acuity (20/286) in his left eye presented with ciliary injection 16 months after femtosecond laser-assisted penetrating keratoplasty (PK). A slit-lamp examination showed a corneal ulcer with infiltrates and edema in both the host and graft between the 3 o'clock and 6 o'clock positions. Microbiologic tests confirmed the presence of *M. chelonae*. Topical arbekacin and moxifloxacin, erythromycin/colistin ointment, and oral clarithromycin were prescribed. We monitored anterior chamber depth by anterior segment optical coherence tomography (AS-OCT) throughout the recovery period. The anterior chamber depth was normal before treatment, with an intraocular pressure (IOP) of 7 mmHg. Although ciliary injection and infiltrates were gradually resolved, slit-lamp examination and AS-OCT revealed an extreme reduction of anterior chamber depth without corneal perforation, 1 month after beginning treatment. The IOP was 5 mmHg, and ciliochoroidal detachment (CCD) was present. The anterior chamber increased with the resolution of CCD and keratitis. Although hypotony continued despite the resolution of CCD and keratitis, the IOP eventually recovered to ≥ 10 mmHg at 1 month after remission. Onset and resolution of transient reduction of anterior chamber depth presumably occurred by anterior rotation and recovery of the ciliary body, respectively. Subsequent PK triple surgery enabled visual recovery to 20/100.

Conclusions and importance: severe anterior segment inflammation due to infectious keratitis may cause CCD and subsequent reduction of anterior chamber depth due to anterior rotation. AS-OCT is a non-invasive and efficient tool for the evaluation of iridociliary structure and the anterior chamber in patients with infectious keratitis.

1. Introduction

Mycobacterium species are prevalent in the environment, and include some pathogenic species that can cause infectious diseases of the eye. *Mycobacterium chelonae* can cause keratitis following various types of ocular surgery.^{1–4}

Herein, we describe transient reduction in anterior chamber depth due to ciliochoroidal detachment (CCD) in a patient with *M. chelonae* keratitis after femtosecond laser-assisted penetrating keratoplasty (PK). To the best of our knowledge, this is the first report of a reduction of anterior chamber depth due to infectious keratitis-related CCD.

2. Case report

A 46-year-old man with keratoconus presented with ciliary injection and reduced visual acuity in his left eye (20/286) at 16 months after femtosecond laser-assisted PK. He was using topical betamethasone and levofloxacin at that time. Slit-lamp examination showed a corneal ulcer with infiltrates and edema in both the host and graft between the 3 o'clock and 6 o'clock positions (Fig. 1a). Corneal scraping was performed for microbiological analysis. Anterior segment optical coherence tomography (AS-OCT) (SS-1000, Tomey, Nagoya, Japan) revealed corneal edema and normal anterior chamber depth (Fig. 1b). An Icare tonometer (Icare, Helsinki, Finland) showed that intraocular pressure (IOP) was 7 mmHg.

Based on the presence of multifocal lesions, a history of

* Corresponding author. Department of Ophthalmology, Osaka University Graduate School of Medicine, Room E7, Yamadaoka 2-2, Osaka, 565-0871, Japan.
E-mail address: yoie@ophthal.med.osaka-u.ac.jp (Y. Oie).

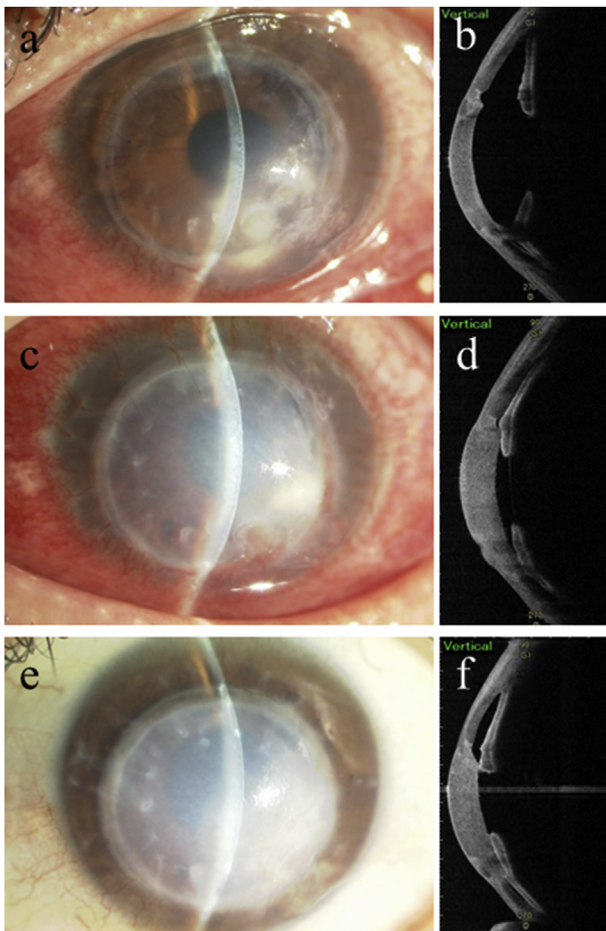


Fig. 1. Depictions of corneal ulcer and anterior chamber.

- a. A corneal ulcer with infiltrates and edema was observed in both the host and graft between the 3 o' clock and 6 o'clock positions.
 b. Anterior segment optical coherence tomography (AS-OCT; SS-1000) revealed normal anterior chamber depth.
 c, d. Despite gradual resolution of inflammation, transient reduction of anterior chamber depth was observed (c. slit-lamp photo, d. AS-OCT image).
 e, f. After inflammation had subsided, the anterior chamber recovered partially with residual posterior synechiae.

keratoplasty, and the use of steroid eye drops, the patient was initially treated for *Candida* keratitis: oral voriconazole and topical voriconazole, fluconazole, levofloxacin, and pimaricin ointments. One week later, severe hyperemia and exacerbation of infiltrates were observed; microbiologic testing confirmed the presence of *M. chelonae*. Therefore, the patient was treated with topical arbekacin and moxifloxacin, erythromycin/colistin ointment, and oral clarithromycin; this led to gradual improvement of hyperemia and infiltration.

However, approximately 1 month later, slit-lamp examination and AS-OCT revealed reduction in anterior chamber depth without corneal perforation (Fig. 1c and d), as well as bullous keratopathy. The patient's IOP was 5 mmHg, and visual acuity was counting fingers. We then used the Visante (Carl Zeiss, Jena, Germany) to perform AS-OCT examination of the enlarged suprachoroidal space and the anterior rotation caused by anterior dislocation of the ciliary body; we observed CCD, as shown in Fig. 2a. Atropine eye drops were applied twice per day to relax the ciliary body and stabilize the anterior chamber depth.

Inflammation of the anterior segment subsided with CCD resolution. Although hypotony continued despite the resolution of CCD and keratitis, IOP eventually recovered to ≥ 10 mmHg at 1 month after remission. Anterior chamber had partially recovered within 6 months (Fig. 1e, f, and 2c); IOP was 21 mmHg at that time. Bullous keratopathy

remained after resolution of the infection; thus, PK triple surgery was performed. Corrected distance visual acuity recovered to 20/100 with a clear graft at 6 months after keratoplasty.

3. Discussion

We have described a patient with *M. chelonae* keratitis following femtosecond laser-assisted PK, which was successfully treated with a previously reported antibiotic cocktail of macrolide, aminoglycoside, and fluoroquinolone.² Although this form of keratitis is rare, appropriate medical treatment is essential.

We observed severe anterior segment inflammation, as well as a transient extremely shallow anterior chamber even without corneal perforation, which may have been caused by CCD. CCD is known to occur with posterior segment inflammation during surgery and photocoagulation or with primary angle-closure glaucoma.^{5,6} This report shows that CCD can occur in patients with severe anterior segment inflammation. If focal anterior segment inflammation due to infectious keratitis is sufficient to reduce aqueous humor production or tissue resistance, CCD may occur. The onset and resolution of the reduction of anterior chamber depth may be due to anterior rotation and recovery of the ciliary body, respectively (Fig. 2b and d).

Our findings show that AS-OCT is effective for determining ciliary body position within the suprachoroidal space when the anterior chamber depth is reduced without corneal perforation. Notably, topical steroids can reduce inflammation and CCD, but can cause recurrence of infectious keratitis. Thus, administration of topical steroids should be carefully considered only if complete remission of infection is confirmed.

CCD was revealed by AS-OCT in the current case. AS-OCT showed Transient CCD in 42% of eyes after ab interno trabeculotomy,⁷ and in 63.3% of patients who underwent microincision vitrectomy surgery.⁸ Although ultrasound biomicroscopy can be used to detect CCD, AS-OCT has the advantages of higher resolution and reduced invasiveness without physical contact.^{5,8}

4. Conclusions

We have described transient reduction of anterior chamber depth due to CCD in a patient with *M. chelonae* infectious keratitis. Severe anterior segment inflammation due to infectious keratitis can cause CCD and subsequent reduction of anterior chamber depth. Furthermore, AS-OCT is a non-invasive and efficient technique for evaluating anatomical changes in the anterior segment.

Patient consent

The patient provided written consent to publish the case report.

Funding

No funding or grant support.

Conflicts of interest

The following authors have no financial disclosures: IN, YO, KM, AW, KN.

Authorship

All authors attest that they meet the current ICMJE criteria for Authorship.

Availability of data and materials

All data supporting our findings are provided within the

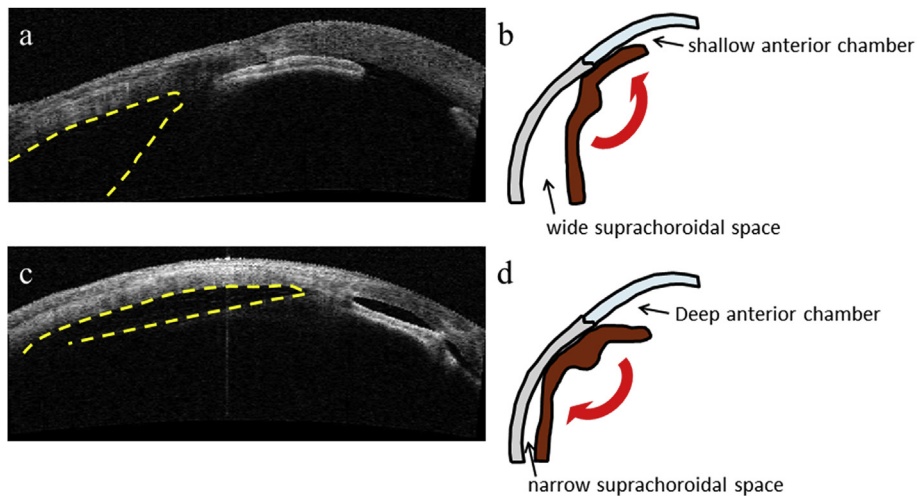


Fig. 2. Depictions of ciliary body rotation.

a, c. Anterior segment optical coherence tomography (Visante) revealed ciliochoroidal detachment, indicated by yellow dotted line.

b. Ciliary body rotation due to wide suprachoroidal space caused reduction of anterior chamber depth.

d. Resolution of ciliary body rotation due to a narrow suprachoroidal space caused enlargement of anterior chamber. (For interpretation of the references to colour in this figure legend, the reader is referred to the Web version of this article.)

manuscript.

Acknowledgements

None.

Appendix A. Supplementary data

Supplementary data to this article can be found online at <https://doi.org/10.1016/j.ajoc.2019.100530>.

References

- Freitas D, Alvarenga L, Sampaio J, et al. An outbreak of *Mycobacterium chelonae* infection after LASIK. *Ophthalmology*. 2003;110(2):276–285.
- Yamaguchi T, Bissen-Miyajima H, Hori-Komai Y, et al. Infectious keratitis outbreak after laser in situ keratomileusis at a single laser center in Japan. *J Cataract Refract Surg*. 2011;37(5):894–900.
- Ramaswamy AA, Biswas J, Bhaskar V, Gopal L, Rajagopal R, Madhavan HN. Postoperative *Mycobacterium chelonae* endophthalmitis after extracapsular cataract extraction and posterior chamber intraocular lens implantation. *Ophthalmology*. 2000;107(7):1283–1286.
- Murthy SI, Jain R, Swarup R, Sangwan VS. Recurrent non-tuberculous mycobacterial keratitis after deep anterior lamellar keratoplasty for keratoconus. *BMJ Case Rep*. 2013;2013 bcr2013200641.
- Kawano Y, Tawara A, Nishioka Y, Suyama Y, Sakamoto H, Inomata H. Ultrasound biomicroscopic analysis of transient shallow anterior chamber in Vogt-Koyanagi-Harada syndrome. *Am J Ophthalmol*. 1996;121(6):720–723.
- Martinez-Bello C, Capeans C, Sanchez-Salorio M. Ultrasound biomicroscopy in the diagnosis of supraciliochoroidal fluid after trabeculectomy. *Am J Ophthalmol*. 1999;128(3):372–375.
- Akagi T, Nakano E, Nakanishi H, Uji A, Yoshimura N. Transient ciliochoroidal detachment after Ab interno trabeculectomy for open-angle glaucoma: a prospective anterior-segment optical coherence tomography study. *JAMA Ophthalmol*. 2016;134(3):304–311.
- Yamane S, Inoue M, Arakawa A, Kadonosono K. Early postoperative hypotony and ciliochoroidal detachment after microincision vitrectomy surgery. *Am J Ophthalmol*. 2012;153(6):1099–1103.e1.