

# Long-term efficacy and safety of verteporfin photodynamic therapy in combination with anti-vascular endothelial growth factor for polypoidal choroidal vasculopathy

Prashant Jain, Giridhar Anantharaman, Mahesh Gopalakrishnan, Anubhav Goyal

**Purpose:** The aim of the study was to analyze the outcomes of photodynamic therapy (PDT) with intravitreal anti-vascular endothelial growth factor (anti-VEGF) for patients with polypoidal choroidal vasculopathy (PCV) having visual acuity (VA) better than 20/60 in a real-world scenario in India. **Methods:** Retrospective review of 42 eyes of 40 patients (mean age 64.3 years) with best-corrected VA (BCVA) 20/60 or better and mean follow-up of 40 months (median 38 months; range 12–71 months) treated with PDT and anti-VEGF or triamcinolone for indocyanine green angiography (ICGA)-proven subfoveal PCV. **Results:** Mean BCVA improved from 0.22 logMAR at baseline to 0.15 at last visit ( $P < 0.001$ ). On ICGA, polyp was observed in 42 eyes (100%) and branching vascular network (BVN) in 37 eyes (88.1%). Polyp regressed in 33 (78.6%) of 42 eyes and BVN in 26 (70.3%) of 37 eyes after combined therapy at 3 months. Mean greatest linear diameter reduced significantly ( $P < 0.001$ ) from 7.22 mm to 4.11 mm. Standard-fluence PDT was performed in 35 eyes and reduced-fluence in 7 eyes. The mean number of PDT was 1.17 with mean number of injections being 6.38 at the end of follow-up. In five eyes, more than one PDT was administered. Of 42 eyes, 40 showed complete resolution of serous macular detachment (SMD) after the combined therapy at 3 months; 17 (42.5%) of the 40 eyes showed no recurrence of fluid on spectral domain optical coherence tomography till the last visit with a mean follow-up of 27 months. On long-term follow-up, SMD reoccurred in 23 eyes with a mean follow-up period of  $9.64 \pm 5.24$  months. Of 38 eyes having a double-layer sign (DLS) on optical coherence tomography at baseline, 37 eyes were having regression of the DLS, that is, it either reduced or resolved at the final visit. At the final visit, 66.7% ( $P < 0.001$ ) eyes were having fluid-free retina. No complication of subretinal hemorrhage was noted. Of the 42 eyes, only one eye had BCVA worse than 20/60 on the final visit. **Conclusion:** To the best of our knowledge, this is the first study to look into the long-term effect of combined PDT with anti-VEGF in PCV in eyes having good VA. Long-term effect of combined PDT appears to be a safe and effective treatment for PCV in eyes having good VA with better outcomes in real-world setting. This study further strengthens the superiority of the combined treatment modality for treatment of subfoveal PCV with no or minimal risk of complication on long-term follow-up.

**Key words:** Long-term efficacy, photodynamic therapy, polypoidal choroidal vasculopathy

Polypoidal choroidal vasculopathy (PCV) was first described by Yannuzzi *et al.* as having two distinct components of branching vascular network (BVN) and terminal aneurysmal dilations or polyps associated with or without serous/hemorrhagic detachment of retinal pigment epithelium (RPE).<sup>[1]</sup> It is a question that has been controversial in ophthalmology over many years: Is PCV a subtype of neovascular age-related macular degeneration (AMD) or a separate clinical entity? Even more important, does this distinction affect treatment and outcomes? Genetic studies suggest that PCV is a type of choroidal neovascularization, and other research has shown that the anti-vascular endothelial growth factor (VEGF) therapies used for AMD may improve vision in patients with PCV. Recent studies indicate that the combination of photodynamic therapy (PDT) and anti-VEGF agent provides added benefit in the treatment of PCV.

Department of Vitreo-Retina, Giridhar Eye Institute, Kochi, Kerala, India

**Correspondence to:** Dr. Anantharaman Giridhar, Department of Vitreoretina, Giridhar Eye Institute, Ponneth Temple Road, Kadavanthra, Kochi - 682 020, Kerala, India. E-mail: giridhareye@gmail.com

Manuscript received: 07.12.17; Revision accepted: 17.04.18

The prevalence of PCV varies among different ethnic groups and has a higher prevalence in Asians and people of African descent compared to Caucasians.<sup>[2]</sup> PCV accounts for 25%–50% of Asian patients presenting with presumed neovascular AMD,<sup>[3–6]</sup> whereas it is observed in only 5%–10% of Caucasian patients with neovascular AMD.<sup>[4,7,8]</sup> There is a marked male preponderance of 63%–78.5% and only 5.9%–24.1% have bilateral disease.<sup>[2,9–11]</sup>

The Beijing Eye Study 2011, a population-based study in Northern China, attempted to estimate the prevalence of PCV using a combined clinical and optical coherence

This is an open access journal, and articles are distributed under the terms of the Creative Commons Attribution-NonCommercial-ShareAlike 4.0 License, which allows others to remix, tweak, and build upon the work non-commercially, as long as appropriate credit is given and the new creations are licensed under the identical terms.

**For reprints contact:** reprints@medknow.com

**Cite this article as:** Jain P, Anantharaman G, Gopalakrishnan M, Goyal A. Long-term efficacy and safety of verteporfin photodynamic therapy in combination with anti-vascular endothelial growth factor for polypoidal choroidal vasculopathy. *Indian J Ophthalmol* 2018;66:1119–27.

Access this article online

Website:

www.ijo.in

DOI:

10.4103/ijo.IJO\_1222\_17

Quick Response Code:



tomography (OCT) criteria to define the presence of PCV. In this study, PCV was defined as an elevated orange-red lesion on fundus photographs, characterized by a double-layer sign (DLS) and high dome-shaped pigment epithelial detachment (PED) on the images. With this definition, the authors found a PCV prevalence of  $0.3\% \pm 0.1\%$ .<sup>[10]</sup>

The gold standard for diagnosing PCV is by indocyanine green angiography (ICGA), which shows the presence of a branching choroidal vascular network and/or clusters of dilated polyp.<sup>[12,13]</sup>

The treatment options for PCV include anti-VEGF and verteporfin PDT. Anti-VEGF agents improve visual function by restoring normal retinal thickness, reducing the serous macular detachment (SMD), taking care of BVN, and reducing reuptake of VEGF after PDT, while PDT facilitates polyp regression. The efficacy of these treatments as monotherapy versus combination therapy was previously evaluated in a randomized controlled trial (EVEREST).<sup>[13]</sup> The results showed that PDT, used in combination with ranibizumab or used alone, is superior to ranibizumab monotherapy in achieving polyp regression. However, there are very few studies in literature on the efficacy of combined therapy with PDT from the Indian subcontinent. To the best of our knowledge, till date, none of the studies has looked into the long-term results of combined PDT in PCV in eyes having good visual acuity (VA). The aim of this study was to analyze the outcomes of combined PDT in PCV in patients having good VA on initial presentation in a real-world population.

## Methods

This was a single-center retrospective case study that included 42 symptomatic eyes of 40 patients having best-corrected VA (BCVA) better than 20/60 at baseline with ICGA-proven subfoveal PCV treated with either standard-fluence or reduced-fluence verteporfin PDT along with intravitreal anti-VEGF or triamcinolone at Department of Vitreo Retina, Giridhar Eye Institute, Kochi, India, between January 2011 and December 2015. All patients received a comprehensive ocular examination including BCVA and dilated fundus examination. The diagnosis of PCV was confirmed by clinical examination, spectral domain OCT (SD-OCT; Spectralis; Heidelberg Engineering, Inc., Heidelberg, Germany), fundus fluorescein angiography (FFA), ICGA, and fundus autofluorescence imaging (Heidelberg Retina Angiograph 2; Heidelberg Engineering).

Patients who were ICGA-proven cases of PCV and BCVA 20/60 or better at the time of combined therapy were included in the study. Only the patients who were followed for at least 12 months were included in the study (four patients were excluded). Patients who were previously treated with anti-VEGF for PCV and did not respond to three loading doses of monotherapy treatment were also included in the study. Eyes with the presence of RPE tear or other maculopathies such as AMD, diabetic macular edema, or high myopia were excluded from the study. Patients in whom ICGA was not performed at 3-month visit after combined PDT were also excluded (one patient) from the study.

Diagnosis was based on the presence of polyp along with BVN observed on ICGA in early frames. The presence

of early subretinal nodular hyperfluorescence or cluster of hyperfluorescence appearing within the first 6 min after injection of indocyanine green with or without the presence of BVN is treated as criteria for the diagnosis of PCV. Leakage in the form of stippled hyperfluorescence on FFA was also observed. The ICGA-based greatest linear diameter (GLD) of the lesion was determined to cover the polyp and surrounding BVN. PDT was carried out using light energy of  $50 \text{ J/cm}^2$  for 83 s ( $600 \text{ mW/cm}^2$ ) after administering  $6 \text{ mg/m}^2$  verteporfin injection. For reduced-fluence PDT, light energy of  $25 \text{ J/cm}^2$  with  $300 \text{ mW/cm}^2$  power was used. Choice between standard-fluence and reduced-fluence PDTs was made at the discretion of treating surgeon. It was followed by 1.25 mg bevacizumab (Avastin; Genentech Inc., South San Francisco, CA, USA), 0.05 mg ranibizumab (Lucentis; Genentech Inc.), or 0.05 mg triamcinolone given intravitreal 3.5 mm from limbus using a 30-gauge needle under topical anesthesia with strict aseptic precautions within 24 h after PDT.

Outcome measures included resolution of SMD on SD-OCT at 3 months and at last visit and regression of polyp/BVN on ICGA conducted at 3 months after combined PDT. Comparison of the baseline VA and BCVA at 3 months, 6 months, and at final visit was carried out. The number of PDT and anti-VEGF injections required was recorded. Any ocular or systemic adverse event was noted. The intravitreal anti-VEGF injection was repeated at 4–6-week intervals if persistent SMD was observed on OCT. If there was persistence of SMD on follow-up OCT after anti-VEGF, then ICGA was repeated and if active polyp associated with SMD was observed on ICGA at follow-up visits, retreatment with PDT combined with intravitreal anti-VEGF or triamcinolone was performed at the discretion of the treating surgeon.

SPSS software, version 16.0 (SPSS Inc., Chicago, IL, USA), was used to perform statistical analysis for comparing the logarithm of the minimal angle of resolution VA at presentation and final follow-up.  $P < 0.05$  was considered statistically significant. The differences between quantitative variables were analyzed using Wilcoxon signed-rank test.

As our study was a retrospective analysis of the patient data from the electronic medical records, consent was not obtained, but general consent was recorded from each patient at the time of ICGA regarding research purpose. The study was conducted in accordance with the tenets of the Declaration of Helsinki and was approved by the Institutional Review Board.

## Results

The mean age of the patient was  $64.29 \pm 8.72$  years. Of 40 patients, only one was aged  $< 50$  years. There were 21 women and 19 men. The mean follow-up period was  $40.02 \pm 10.21$  months with median 38 months (range 12–71 months). Demographic profile of the patients is given in Table 1.

The mean BCVA at baseline was  $0.23 \pm 0.17$  logMAR unit (mean Snellen 20/33). PCV was classified as serosanguineous (26 eyes; 61.9%), hemorrhagic (7 eyes; 16.7%), and mixed (9 eyes; 21.4%) based on biomicroscopy. On ICGA, subfoveal polyp was observed in all eyes (100%). Of 42 eyes, BVN was found in 37 (88.1%). The ICGA-based mean GLD of the lesion (polyp and BVN) was  $7.22 \pm 4.98$  mm. On FFA, stippled leakage was found in 26 eyes (61.9%). On SD-OCT, SMD

was present in 100% of cases at baseline. The mean central choroidal thickness (CCT) measured on EDI mode of SD-OCT was  $275.12 \pm 84.9 \mu\text{m}$ . DLS was found in 38 eyes (90.5%) on SD-OCT. The baseline characteristics of the study group are given in Table 2.

Of 42 eyes, primary modality of treatment of combined PDT was used in 19 eyes (45.2%) and remaining 23 eyes (54.8%) were switched to combined PDT after nonresponsive to three loading doses of intravitreal anti-VEGF monotherapy (bevacizumab or ranibizumab). Standard-fluence PDT was carried out in 35 and reduced-fluence PDT in 7 eyes. Intravitreal bevacizumab was administered in 17 eyes (40.4%) and ranibizumab in

13 (31.0%). In 12 eyes, triamcinolone was administered along with PDT.

If we look at the PCV status 3 months after combined therapy, of 42 eyes who were having polyp at baseline, 33 (78.6%) showed regression of polyp. Seven of nine eyes that showed residual polyp on ICGA at 3 months were having inactive polyp as no activity was observed on SD-OCT. When we compared the polyp regression rate between two groups of standard and reduced-fluence PDT, the *P* value was not statistically significant (*P* = 0.3). BVN was regressed in 26 of 37 eyes (70.27%) having BVN at baseline. The *P* value (0.30) was not statistically significant between the two groups [Table 3]. The size of the GLD was reduced significantly (*P* < 0.001) at 3 months and at last visit after combined therapy. On FFA, none of the patients was having leakage 3 months after combined PDT.

The CCT was significantly reduced over a period of time after combined PDT, which is shown in Fig. 1. When CCT between baseline and at 3 months and final visit was assessed, the *P* value was found to be statistically significant (*P* < 0.001), which is shown in Tables 4a and b. The comparison of reduction of CCT between standard and reduced-fluence PDT was found to be statistically not significant (*P* = 0.17) shown in Table 5.

If we analyze the fluid-free retina, that is, the presence of SMD on OCT at follow-up visit, SMD was found to be resolved in 40 eyes (95.2%) at 3 months, and at final visit, 28 eyes (66.7%) were having fluid-free retina. The status of SMD at every visit is shown in Fig. 2. On assessing the SMD status between baseline and at 3 months and final visit, *P* value was found to be statistically significant (*P* < 0.001), which is shown in Tables 6a and b.

When we closely looked into the SMD status throughout the study, we found that, out of 42 eyes, 40 was not having any fluid at 3 months, but on long-term follow-up, there was reappearance of SMD in 23 eyes with a mean follow-up period of  $9.64 \pm 5.24$  months [Table 7]. In 23 eyes with recurrence, 23 had polyp and 19 had BVN on initial presentation. Two eyes

**Table 1: Demographic characteristics of the population**

Characteristics	Summary details (n=42)
Age (years), mean±SD	64.29±8.719
Age category (years), n (%)	
<50	1 (2.5)
≥50 and <65	39 (97.5)
Gender, n (%)	
Male	19 (47.5)
Female	21 (52.5)
Follow-up (months), mean±SD	40.02±10.21; range (12-71 months)
Systemic illness, n (%)	
Diabetes	6 (14.3)
Hypertension	8 (19.0)
Both	5 (11.9)
Nil	23 (54.8)

SD: Standard deviation

**Table 2: Baseline characteristics of the study population**

Characteristics	Summary details (n=42)
BCVA logMAR, mean±SD	0.23±0.165; mean Snellen 20/33
Type of PCV, n (%)	
Hemorrhagic	7 (16.7)
Mixed	9 (21.4)
Serosanguineous	26 (61.9)
Presence of polyp on ICGA, n (%)	
No	Nil
Yes	42 (100)
Presence of BVN on ICGA, n (%)	
No	5 (11.9)
Yes	37 (88.1)
GLD of lesion (mm), mean±SD	7.22±4.98
CCT (μm), mean±SD	275.12±84.975
Presence of SMD, n (%)	42 (100)
Presence of DLS on OCT, n (%)	
No	4 (9.5)
Yes	38 (90.5)

BVN: Branch vascular network, SMD: Serous macular detachment, ICGA: Indocyanine green angiography, GLD: Greatest linear diameter, CCT: Central choroidal thickness, DLS: Double-layer sign, BCVA: Best-corrected visual acuity, LogMAR: Logarithm of the minimum angle of resolution, SD: Standard deviation, PCV: Polypoidal choroidal vasculopathy, OCT: Optical coherence tomography

**Table 3: Branch vascular network regression rate between two photodynamic therapy groups**

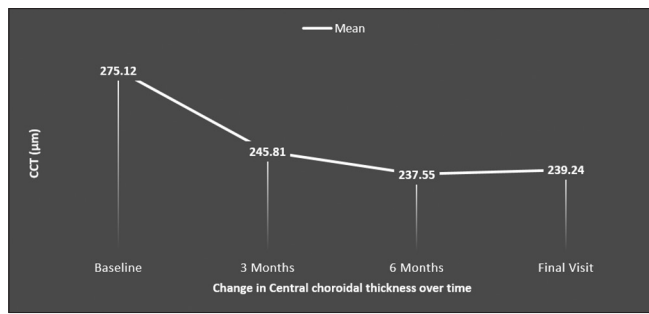
BVN	PDT			<i>P</i>
	SF PDT	RF PDT	Total	
Yes	22	4	26	0.296
No	11	0	11	
Total	33	4	37	

Fisher's exact test. BVN: Branch vascular network, PDT: Photodynamic therapy, SF PDT: Standard-fluence PDT, RF PDT: Reduced-fluence PDT

**Table 4a: Assessment of central choroidal thickness-baseline and postphotodynamic therapy at 3 months**

Variable	Descriptive statistics (n=42)	<i>P</i>
Initial CCT (μm), mean±SD	275.12±84.975	<0.001**
CCT 3 months, mean±SD	245.81±73.257	

\*\*Significant association (*P*<0.05); paired *t*-test. CCT: Central choroidal thickness, SD: Standard deviation



**Figure 1:** Assessment of central choroidal thickness over period of time in study group

**Table 4b: Assessment of central choroidal thickness-baseline and final visit**

Variable	Descriptive statistics (n=42)	P
Initial CCT (µm), mean±SD	275.12±84.975	<0.001**
Final CCT, mean±SD	239.24±68.613	

\*\*Significant association (P<0.05); Wilcoxon signed-rank test. CCT: Central choroidal thickness, SD: Standard deviation

**Table 5: Assessment of change of central choroidal thickness between two photodynamic therapy group**

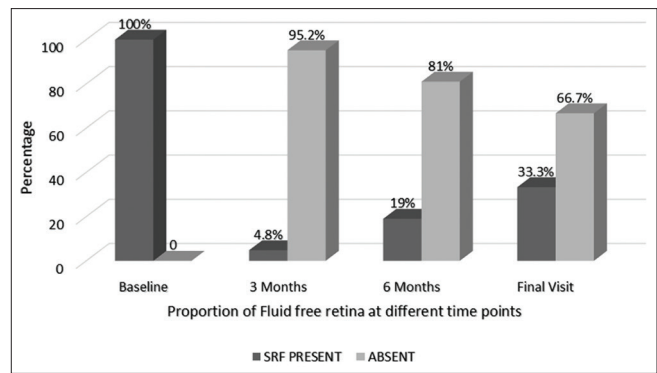
Variable	Descriptive statistics (n=42)	P
Change in CCT in SF, mean±SD	-41.14±70.174	0.170
Change in CCT in RF, mean±SD	-9.57±34.98	

Mann-Whitney U-test. CCT: Central choroidal thickness, PDT: Photodynamic therapy, SF PDT: Standard-fluence PDT, RF PDT: Reduced-fluence PDT, SD: Standard deviation

showed the persistence of SMD on long-term follow-up after combined therapy.

Of 42 eyes, 40 showed resolution of SMD after combined therapy at 3 months. Of these 40 eyes, 17 (42.5%) showed no recurrence of fluid on OCT till the last visit with mean follow-up of 27 months. Fig. 3 showed case example of one of our patients in whom after combined PDT; there is no disease activity after follow-up of 36 months and patient maintaining BCVA of 20/40 at last visit. Of 38 eyes having DLS on OCT at baseline, 37 eyes were having reduction of DLS at final visit.

The mean number of PDT received in the study group was 1.17 ± 0.54 with a median of 1 [Table 8a]. Mean number for standard-fluence was 1.17 and reduced-fluence was 1.14. Thirty-seven patients (88.1%) received only one PDT. In five eyes, more than one PDT was given. In three out of five eyes, choroidal perfusion was decreased on ICGA after PDT, but there was no significant correlation between the fluence used and severity of choroidal ischemia. A total number of injections given throughout the study were 268 with a mean of 6.38 ± 6.15 and a median of 4.50 [Table 8b]. Before PDT, that is, in the group that received anti-VEGF monotherapy and was nonresponder, the number of total injections given was 100 with a mean of 4.35 ± 2.93 and a median of four injections. In



**Figure 2:** Proportion of patients with serous macular detachment over period of time in study group

**Table 6a: Assessment of serous macular detachment-baseline and postphotodynamic therapy at 3 months**

SMD	Summary details (n=42)	P
Baseline, n (%)		
Present	42 (100)	<0.001**
Absent	0	
SMD 3 months, n (%)		
Present	2 (4.8)	
Absent	40 (95.2)	

\*\*Significant association (P<0.05); McNemar's test. SMD: Serous macular detachment

**Table 6b: Assessment of serous macular detachment-baseline and final visit**

SMD	Summary details (n=42)	P
Baseline		
Present	42 (100)	<0.001**
Absent	0	
Final SMD		
Present	14 (33.3)	
Absent	28 (66.7)	

\*\*Significant association (P<0.05); McNemar's test. SMD: Serous macular detachment

21 eyes (50%), ≤4 intravitreal injections were administered, and in 8 eyes (19.04%), ≥10 injections were administered.

The BCVA logMAR value at baseline and at subsequent visit at 3 months, 6 months, and at last visit is shown in Table 9. On assessing the BCVA between baseline and at 3 months, the P value was significant (P = 0.001) with improvement in BCVA. Vision was stable without any deterioration between baseline and final visit (P = 0.64). Out of 42 eyes, one eye has BCVA worse than 20/60 on final visit and has BVN with polyp on initial ICGA and underwent standard-fluence PDT.

In one of the patients, four sittings of standard-fluence PDT were done, and on the last visit, no activity was present and the patient was maintaining a BCVA of 20/20 after follow-up of 96 months [Fig. 4]. In one of the patients, after PDT, there was the presence of residual BVN with extra-large PED and

**Table 7: Time taken for recurrence of serous macular detachment in each eye**

<i>n</i>	Reappearance of SMD in months
1	4
2	4
3	5
4	5
5	5
6	5
7	6
8	8
9	9
10	9
11	9
12	9
13	9
14	9
15	11
16	12
17	12
18	13
19	16
20	17
21	18
22	20
23	20
Mean±SD	9.64±5.24

SD: Standard deviation, SMD: Serous macular detachment

**Table 8a: Number of photodynamic therapy received in the study group**

Characteristics	Summary details ( <i>n</i> =42)
PDT needed	
1	37 (88.1)
≥2	5 (11.9)
Mean±SD	1.17±0.54
Median	1

SD: Standard deviation, PDT: Photodynamic therapy

SMD, which was not settling down after repeated intravitreal anti-VEGF. Therefore, focal laser was applied to feeder vessel shown on ICGA and BVN, which completely resolved the issue with flattening of PED and no disease activity was observed after 41 months of follow-up with a BCVA of 20/30.

In our study, none of the patients developed foveal atrophy with a minimum follow-up of 12 months and mean of 40 months. In none of the patient, subretinal hemorrhage developed. Although choroidal thickness reduced on long term but no adverse effect noted.

### Discussion

The aim of this study was to investigate the efficacy and long-term effects of combined PDT as treatment for PCV in eyes having good VA at baseline in an Indian population. We

**Table 8b: Number of intravitreal injections received in the study group**

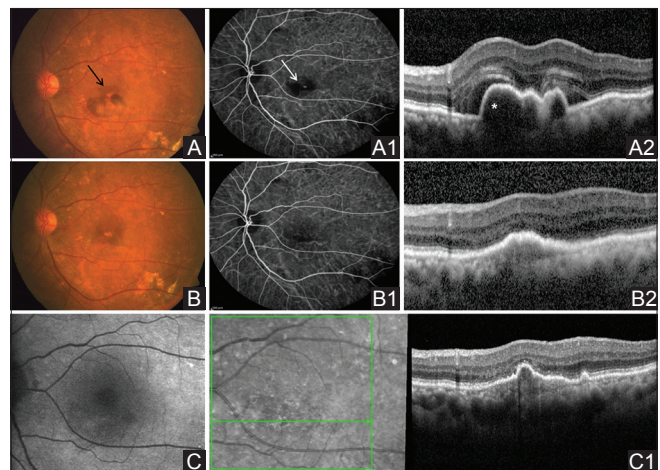
Intravitreal injections	Summary details ( <i>n</i> =42)
Total number of injections	268
Mean±SD	6.38±6.152
Median	4.50

SD: Standard deviation

**Table 9: Assessment of best-corrected visual acuity over a period of time in the study group**

Variable	Descriptive statistics ( <i>n</i> =42)
Initial BCVA, mean±SD	0.22±0.165; Snellen 20/33
BCVA 3 months, mean±SD	0.15±0.130; Snellen 20/28
BCVA 6 months, mean±SD	0.18±0.155; Snellen 20/30
Final BCVA, mean±SD	0.21±0.194; Snellen 20/32

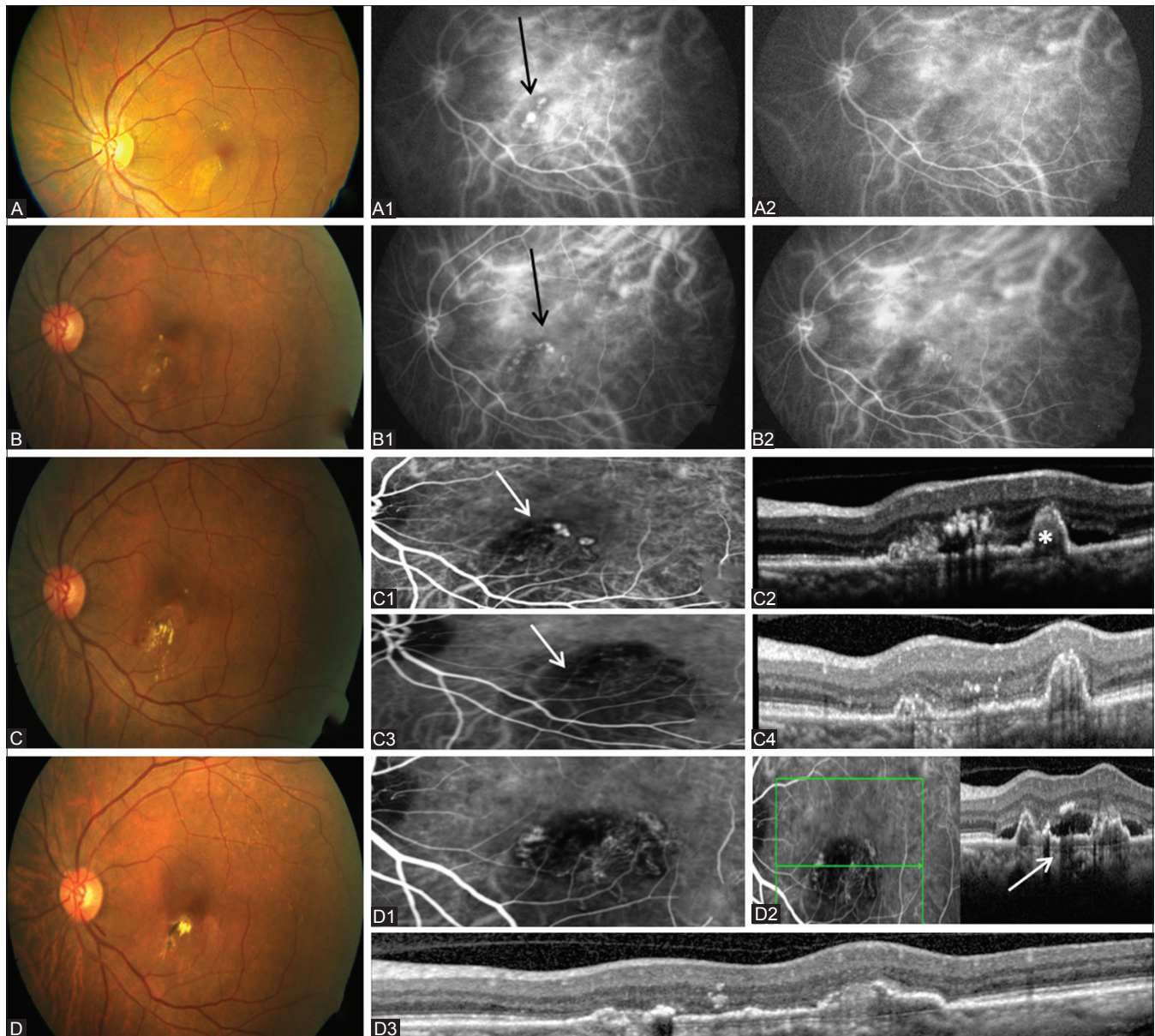
BCVA: Best-corrected visual acuity, SD: Standard deviation



**Figure 3:** A 65-year-old female with best-corrected visual acuity 20/40; (A) fundus shows hemorrhage with serous macular detachment and orange reddish nodule (black arrow), (A1) indocyanine green angiography shows subfoveal polyp (white arrow), (A2) optical coherence tomography shows notched pigment epithelial detachment (asterisk) with serous macular detachment; (b) 3-month postcombined photodynamic therapy with ranibizumab fundus shows absorption of hemorrhage and fluid, (B1) indocyanine green angiography shows complete resolution of polyp at 3 months, (B2) optical coherence tomography shows fluid-free retina and reduction in size of pigment epithelial detachment; (C) normal fundus autofluorescence picture 36-month postcombined photodynamic therapy, (C1) no disease activity on spectral domain-optical coherence tomography at last visit after 36 months of follow-up

performed this study as there is a lot of skepticism among retina specialists that PDT can result in worsening of VA due to choriocapillaris occlusion and therefore may not be a safe modality of treatment in patient having good vision. The result of our study showed that PDT *per se* does not result in worsening of VA and therefore can be considered in eyes having good VA.

There are various treatment options for PCV, which include thermal laser, standard-fluence PDT, reduced-fluence PDT, and anti-VEGF.



**Figure 4:** A 61-year-old female in whom four sittings of standard-fluence combined photodynamic therapy was given with follow-up of 96 months and best-corrected visual acuity 6/6; (A) In 2009 fundus shows serous macular detachment with exudates, (A1) Indocyanine green angiography shows polyp, (A2) post combined photodynamic therapy shows resolution of polyp; (B) In 2011 fundus shows serous macular detachment, (B1) Indocyanine green angiography shows saccular dilatations (arrow), (B2) post combined photodynamic therapy shows resolution of polyp; (C) In 2013 fundus shows serous macular detachment with polyp and exudates, (C1) Indocyanine green angiography shows polyp (white arrow), (C2) thumb-like polyp (asterisk) with serous macular detachment on optical coherence tomography, (C3) post combined photodynamic therapy indocyanine green angiography shows resolution of polyp, (C4) optical coherence tomography shows resolution of serous macular detachment; (D) In 2017 fundus shows serous macular detachment with exudates, (D1) Polyp with branching vascular network on indocyanine green angiography, (D2) double-layer sign with thumblike polyp on optical coherence tomography, (D3) post combined photodynamic therapy shows resolution of serous macular detachment

In recent years, thermal laser photocoagulation has been superseded by the superior efficacy of PDT and subsequently anti-VEGF agents, and it is mainly restricted to patients having extrafoveal polyp.

Most studies on PDT monotherapy for PCV have reported favorable short-to-mid-term results, with stable or improved vision and regression of polyps achieved in 80%–95% of eyes.<sup>[14–18]</sup> Although the short-term visual outcome of PDT monotherapy for PCV appears promising, a 5-year multicentered prospective

study of 65 patients with PCV showed that the patients had a mean decline of 0.21 logMAR units in BCVA from baseline to 5 years after the initiation of PDT monotherapy.<sup>[19]</sup>

The standard dose of PDT might be associated with possible adverse effects on the choriocapillaris surrounding the treatment zone due to upregulation of VEGF.<sup>[20,21]</sup> As a result, variations in PDT techniques including reduced-fluence PDT (300 mW/cm<sup>2</sup>, light dose 25 J/cm<sup>2</sup>) or even quarter-fluence PDT have been reported.<sup>[22]</sup>

Yamashita *et al.*<sup>[23]</sup> showed that the use of reduced-fluence PDT (light dose 25 J/cm<sup>2</sup>) in 38 PCV patients resulted in significant improvement in mean logMAR BCVA from a baseline of 0.43–0.28 at 12 months and that mean VA remained at 0.29 logMAR after 24 months. Improved or stable vision was achieved in 95% of the treated patients at 24 months. Sen *et al.*<sup>[24]</sup> showed that reduced-fluence PDT with anti-VEGF is safe and effective with polyp regression with visual improvement seen in 80% of cases. In their study, none of the patients developed subretinal hemorrhage. In our study, we had used standard- as well as reduced-fluence PDT modality and no significant difference in the outcomes was observed. None of our patients in whom we applied standard-fluence PDT (35 eyes of 42) developed any complication including hemorrhage or chorioretinal atrophy. One of our patients took four sittings of standard-fluence PDT, and after a follow-up of 96 months, the patient is maintaining a BCVA of 20/20.

The beneficial effects of combined PDT and anti-VEGF therapy have been confirmed by the EVEREST study, a phase 3, double-blind, multicenter, randomized controlled trial, which evaluated the efficacy of intravitreal ranibizumab monotherapy versus verteporfin PDT monotherapy versus combined therapy with PDT and intravitreal ranibizumab for the treatment of PCV.<sup>[13]</sup> The study showed that both combination therapy and PDT monotherapy resulted in a significantly higher proportion of PCV eyes having complete regression of polyps on ICGA than ranibizumab alone at 6 months (77.8% vs. 71.4% vs. 28.6%, respectively).<sup>[13]</sup> A retrospective study by Anantharaman *et al.* showed that, in 34 PCV patients, 11 were treated with combined PDT and all the patients showed a significant improvement with regression of polyp at 3 months.<sup>[25]</sup>

There are a few studies that have specifically examined the long-term efficacy of the combined treatment in PCV. Wang *et al.*<sup>[26]</sup> in meta-analysis suggests that combination of PDT and anti-VEGF therapy results in better long-term visual outcomes and lower incidence rates of retinal hemorrhage than PDT monotherapy. To the best of our knowledge, none of the studies has looked into the long-term effects of combined PDT in eyes having good VA. In this study, we had shown that ICGA-guided combined PDT stabilizes or improves the vision on long-term follow-up in eyes having good VA.

Kurashige *et al.*<sup>[27]</sup> reported that PDT is not a perfect long-term therapy for PCV patients. According to them, it is an effective treatment over short term, but VA prognosis may not be the same in long term and VA deterioration occurs on long-term follow-up. Similarly, Akaza *et al.*<sup>[28]</sup> reported that, although the standard-fluence PDT improved the vision on short-term follow-up, the VA decreased in conjunction with an increased duration of follow-up. In contrast to these studies, our study suggests that, even on long-term follow-up in PCV patients, VA improves or maintains after combined PDT. In our studies, we have included patients having good VA and except one, all patients maintained the VA on long-term follow-up.

Many other studies concluded that combined PDT shows favorable visual outcomes and significant visual improvement in patients with PCV on long-term follow-up. Kang *et al.*,<sup>[29]</sup> reporting long-term follow-up results of PDT, showed good visual outcomes during more than 5 years, avoiding significant visual loss in 88.1% patients. Similarly, Kang *et al.*<sup>[30]</sup> concluded

that combined therapy in PCV showed 88.2% of the patients avoided visual loss at 3 years after treatment.

Our study is meaningful in several aspects. This study evaluated the long-term efficacy of combined PDT in PCV in eyes having good VA. It also showed the possible benefit of administration of anti-VEGF injection after initial PDT, which might be beneficial for decreasing the extent of PCV. In few of our patients, we used triamcinolone along with PDT as triamcinolone helps to counter inflammatory effect of PDT. It helps in reduction of size of polyp and also reduces the occlusive effect of PDT on the choriocapillaris at the treated area.<sup>[31]</sup>

By using FFA, ICGA, and SD-OCT to accurately assess PCV recurrence, we were able to avoid unnecessary retreatment of PDT in eyes with PCV, and anti-VEGF injections were used against persistent leakage from BVNs. In eyes that were not responding to anti-VEGF after recurrence and were having polyp on ICGA, repeat PDT was carried out. Our study also showed the importance of long-term follow-up as we have noticed that, during the course of long follow-up, there are periods of long interval showing recurrences.

Through this study, we tried to analyze the real-world experience of combined verteporfin PDT in eyes having good VA at baseline in an Indian population. In our study, demographically, the mean age at presentation was 64.3 years without preponderance of any gender. If we look at the type of PCV, it was mainly serosanguineous with unilateral presentation. In 54.8% of our patients, initially, anti-VEGF was used as primary treatment, and after no response, we switched to the combined therapy. We used both forms of PDT, that is, standard-fluence and reduced-fluence, and the result was comparative in both groups. In majority of our patients, we used standard-fluence PDT, and even after a mean follow-up of 40.02 months, all patients except one maintained a good VA.

After 3 months of therapy, SMD was resolved in 95.2% of patients. There was a significant improvement in logMAR BCVA at 3 months ( $P = 0.001$ ), and at final visit, BCVA was comparable with baseline vision. Mean follow-up in our study was 40.02 months with a range of 12–71 months. There was a marked reduction in CCT and DLS on OCT and polyp and BVN regression with reduction in GLD diameter on ICGA. It was found that 66.7% of the patients were having fluid-free retina on their last visit on SD-OCT with DLS regression observed in 88.1%. The mean number of injections administered was 6.38 and that of PDT was 1.17. In one of our patients, standard-fluence PDT was used four times with no chorioretinal atrophy observed at the last visit after a follow-up of 96 months.

Another important finding of our study is that, out of 40 eyes that showed resolution of SMD after the combined therapy at 3 months, 17 showed no recurrence of fluid on OCT till the last visit with a mean follow-up of 27 months. All these 17 patients maintained good VA till last visit without any sign of disease activity on SD-OCT.

In real-world setting, we found out that, after the combined PDT with a mean follow-up of 40.02 months, the patients were maintaining good VA (mean Snellen 20/32 at the last visit) on long term. In our study, surprisingly, none of the patients developed subretinal hemorrhage or any other complication till

**Table 10: Comparison with previous study of combined photodynamic therapy for polypoidal choroidal vasculopathy**

Study	Treatment	Number of eyes	Interval between PDT and anti-VEGF	Visual acuity (logMAR)			Mean number of PDT	Mean number of injections	Polyp regression at 3 months	Mean follow-up (M)
				Initial	3 months	12 months				
Sato <i>et al.</i> <sup>[33]</sup>	PDT + R	40	2 days before PDT	0.46	0.32	0.27	1.10	1.23	85.0%	12
Gomi <i>et al.</i> <sup>[34]</sup>	PDT + B	61	1 day before PDT	0.48	0.36	0.36	1.43	NA	78.7%	12
Ricci <i>et al.</i> <sup>[35]</sup>	RF PDT + R	17	2 days after PDT	0.45	NA	0.29	1.2	2.9	94.1% (at 12 months)	12
Gomi <i>et al.</i> <sup>[36]</sup>	PDT + R	37	7 days before PDT	0.51	0.38	0.29	NA	6.8	69.7%	12
Hata <i>et al.</i> <sup>[37]</sup>	PDT + R	95	3 days after PDT	0.62	0.56	0.53	1.34	NA	63.2% (at 12 months)	24
Saito <i>et al.</i> <sup>[38]</sup>	PDT + R	25	1-2 days before PDT	0.30	0.52	0.59	1.4	4.5	100%	60
Sakurai <i>et al.</i> <sup>[39]</sup>	PDT + R	17	1 day before PDT	0.35	NA	0.38	1	NA	82.3%	12
Lee <i>et al.</i> <sup>[40]</sup>	PDT + B	36	7 days after PDT	0.75	0.53	0.54	2.25	3.4	NA	24
EVEREST <sup>[13]</sup>	PDT + R	18	<24 h after PDT	56.6 letters ETDRS	Gain 7.4 letters	Gain 10.9 letters (6 months)	1.4	3.9	72.2%	6
Our study	PDT + R/B/T	42	<24 h after PDT	0.22	0.15	0.21	1.2	6.4	78.6%	40

VEGF: Vascular endothelial growth factor, PDT: Photodynamic therapy, LogMAR: Logarithm of the minimum angle of resolution, ETDRS: Early Treatment Diabetic Retinopathy Study, R: Ranibizumab, B: Bevacizumab, T: Triamcinolone

the last follow-up visit after PDT in contrast to other reported study.<sup>[32]</sup> Except one, all our patients were maintaining BCVA better or equal to 20/60. Although choroidal thickness reduced on long term, no adverse effect developed.

Our study is comparable with the studies conducted in the rest of world [comparison chart is shown in Table 10] and further strengthens the superiority of the combined treatment modality for subfoveal PCV with no or minimal risk of complication on long-term follow-up in Indian population. The added advantage of our study is long-term follow-up (mean follow-up 40.02 months and median 38 months) over other studies where mean follow-up was of 12–24 months. In this study, PCV subclassification done by single observer and this could be one of the drawbacks of our study.

## Conclusion

This real-world experience in our study suggests that, in the long term, combined PDT appears to be a safe and effective treatment for PCV in eyes having good VA with better outcomes. To the best of our knowledge, till date, none of the studies has looked into the long-term follow-up of the combined PDT in PCV patients having good VA. Hence, this study is unique in that way and proves that combined PDT is safe, effective, and superior in every aspect in eyes having good VA even on long-term follow-up.

## Financial support and sponsorship

Nil.

## Conflicts of interest

There are no conflicts of interest.

## References

- Yannuzzi LA, Sorenson J, Spaide RF, Lipson B. Idiopathic polypoidal choroidal vasculopathy (PCV). *Retina* 1990;10:1-8.
- Byeon SH, Lee SC, Oh HS, Kim SS, Koh HJ, Kwon OW, *et al.* Incidence and clinical patterns of polypoidal choroidal vasculopathy in Korean patients. *Jpn J Ophthalmol* 2008;52:57-62.
- Liu Y, Wen F, Huang S, Luo G, Yan H, Sun Z, *et al.* Subtype lesions of neovascular age-related macular degeneration in Chinese patients. *Graefes Arch Clin Exp Ophthalmol* 2007;245:1441-5.
- Sho K, Takahashi K, Yamada H, Wada M, Nagai Y, Otsuji T, *et al.* Polypoidal choroidal vasculopathy: Incidence, demographic features, and clinical characteristics. *Arch Ophthalmol* 2003;121:1392-6.
- Maruko I, Iida T, Saito M, Nagayama D, Saito K. Clinical characteristics of exudative age-related macular degeneration in Japanese patients. *Am J Ophthalmol* 2007;144:15-22.
- Lafaut BA, Leys AM, Snyers B, Rasquin F, De Laey JJ. Polypoidal choroidal vasculopathy in Caucasians. *Graefes Arch Clin Exp Ophthalmol* 2000;238:752-9.
- Yannuzzi LA, Wong DW, Sforzolini BS, Goldbaum M, Tang KC, Spaide RF, *et al.* Polypoidal choroidal vasculopathy and neovascularized age-related macular degeneration. *Arch Ophthalmol* 1999;117:1503-10.
- Scassellati-Sforzolini B, Mariotti C, Bryan R, Yannuzzi LA, Giuliani M, Giovannini A, *et al.* Polypoidal choroidal vasculopathy in Italy. *Retina* 2001;21:121-5.
- Cheung CM, Li X, Mathur R, Lee SY, Chan CM, Yeo I, *et al.* A prospective study of treatment patterns and 1-year outcome of Asian age-related macular degeneration and polypoidal choroidal vasculopathy. *PLoS One* 2014;9:e101057.
- Li Y, You QS, Wei WB, Xu J, Chen CX, Wang YX, *et al.* Polypoidal choroidal vasculopathy in adult Chinese: The Beijing eye study. *Ophthalmology* 2014;121:2290-1.



11. Uyama M, Matsubara T, Fukushima I, Matsunaga H, Iwashita K, Nagai Y, *et al.* Idiopathic polypoidal choroidal vasculopathy in Japanese patients. *Arch Ophthalmol* 1999;117:1035-42.
12. Spaide RF, Yannuzzi LA, Slakter JS, Sorenson J, Orlach DA. Indocyanine green videoangiography of idiopathic polypoidal choroidal vasculopathy. *Retina* 1995;15:100-10.
13. Koh A, Lee WK, Chen LJ, Chen SJ, Hashad Y, Kim H, *et al.* EVEREST study: Efficacy and safety of verteporfin photodynamic therapy in combination with ranibizumab or alone versus ranibizumab monotherapy in patients with symptomatic macular polypoidal choroidal vasculopathy. *Retina* 2012;32:1453-64.
14. Chan WM, Lam DS, Lai TY, Liu DT, Li KK, Yao Y, *et al.* Photodynamic therapy with verteporfin for symptomatic polypoidal choroidal vasculopathy: One-year results of a prospective case series. *Ophthalmology* 2004;111:1576-84.
15. Mauget-Fayssse M, Quaranta-El Maftouhi M, De La Marnière E, Leys A. Photodynamic therapy with verteporfin in the treatment of exudative idiopathic polypoidal choroidal vasculopathy. *Eur J Ophthalmol* 2006;16:695-704.
16. Spaide RF, Donsoff I, Lam DL, Yannuzzi LA, Jampol LM, Slakter J, *et al.* Treatment of polypoidal choroidal vasculopathy with photodynamic therapy. *Retina* 2002;22:529-35.
17. Akaza E, Yuzawa M, Matsumoto Y, Kashiwakura S, Fujita K, Mori R, *et al.* Role of photodynamic therapy in polypoidal choroidal vasculopathy. *Jpn J Ophthalmol* 2007;51:270-7.
18. Silva RM, Figueira J, Cachulo ML, Duarte L, Faria de Abreu JR, Cunha-Vaz JG, *et al.* Polypoidal choroidal vasculopathy and photodynamic therapy with verteporfin. *Graefes Arch Clin Exp Ophthalmol* 2005;243:973-9.
19. Miki A, Honda S, Kojima H, Nishizaki M, Nagai T, Fujihara M, *et al.* Visual outcome of photodynamic therapy for typical neovascular age-related macular degeneration and polypoidal choroidal vasculopathy over 5 years of follow-up. *Jpn J Ophthalmol* 2013;57:301-7.
20. Schmidt-Erfurth U, Michels S, Barbazetto I, Laqua H. Photodynamic effects on choroidal neovascularization and physiological choroid. *Invest Ophthalmol Vis Sci* 2002;43:830-41.
21. Schmidt-Erfurth U, Schlötzer-Schrehard U, Cursiefen C, Michels S, Beckendorf A, Naumann GO, *et al.* Influence of photodynamic therapy on expression of vascular endothelial growth factor (VEGF), VEGF receptor 3, and pigment epithelium-derived factor. *Invest Ophthalmol Vis Sci* 2003;44:4473-80.
22. Potter MJ, Claudio CC, Szabo SM. A randomised trial of bevacizumab and reduced light dose photodynamic therapy in age-related macular degeneration: The VIA study. *Br J Ophthalmol* 2010;94:174-9.
23. Yamashita A, Shiraga F, Shiragami C, Shirakata Y, Fujiwara A. Two-year results of reduced-fluence photodynamic therapy for polypoidal choroidal vasculopathy. *Am J Ophthalmol* 2013;155:96-102.e1.
24. Sen P, Bhende M, Sachidanandam R, Bansal N, Sharma T. Reduced-fluence photodynamic therapy and anti-vascular endothelial growth factor for polypoidal choroidal vasculopathy in an Indian population. *Indian J Ophthalmol* 2016;64:908-13.
25. Anantharaman G, Ramkumar G, Gopalakrishnan M, Rajput A. Clinical features, management and visual outcome of polypoidal choroidal vasculopathy in Indian patients. *Indian J Ophthalmol* 2010;58:399-405.
26. Wang W, He M, Zhang X. Combined intravitreal anti-VEGF and photodynamic therapy versus photodynamic monotherapy for polypoidal choroidal vasculopathy: A systematic review and meta-analysis of comparative studies. *PLoS One* 2014;9:e110667.
27. Kurashige Y, Otani A, Sasahara M, Yodoi Y, Tamura H, Tsujikawa A, *et al.* Two-year results of photodynamic therapy for polypoidal choroidal vasculopathy. *Am J Ophthalmol* 2008;146:513-9.
28. Akaza E, Mori R, Yuzawa M. Long-term results of photodynamic therapy of polypoidal choroidal vasculopathy. *Retina* 2008;28:717-22.
29. Kang HM, Kim YM, Koh HJ. Five-year follow-up results of photodynamic therapy for polypoidal choroidal vasculopathy. *Am J Ophthalmol* 2013;155:438-47.e1.
30. Kang HM, Koh HJ, Lee CS, Lee SC. Combined photodynamic therapy with intravitreal bevacizumab injections for polypoidal choroidal vasculopathy: Long-term visual outcome. *Am J Ophthalmol* 2014;157:598-606.e1.
31. Mukai R, Kishi S, Sato T, Watanabe G, Matsumoto H. Protective effect of intravitreal bevacizumab and sub-tenon triamcinolone acetonide against occlusion of choriocapillaris induced by photodynamic therapy. *Ophthalmologica* 2010;224:267-73.
32. Rishi P, Rishi E, Sharma M, Maitray A, Bhende M, Gopal L, *et al.* Incidence, outcomes, and risk factors for hemorrhagic complications in eyes with polypoidal choroidal vasculopathy following photodynamic therapy in Indian subjects. *Indian J Ophthalmol* 2017;65:712-8.
33. Sato T, Kishi S, Matsumoto H, Mukai R. Comparisons of outcomes with different intervals between adjunctive ranibizumab and photodynamic therapy for polypoidal choroidal vasculopathy. *Am J Ophthalmol* 2013;156:95-105.e1.
34. Gomi F, Sawa M, Wakabayashi T, Sasamoto Y, Suzuki M, Tsujikawa M, *et al.* Efficacy of intravitreal bevacizumab combined with photodynamic therapy for polypoidal choroidal vasculopathy. *Am J Ophthalmol* 2010;150:48-54.e1.
35. Ricci F, Calabrese A, Regine F, Missiroli F, Ciardella AP. Combined reduced fluence photodynamic therapy and intravitreal ranibizumab for polypoidal choroidal vasculopathy. *Retina* 2012;32:1280-8.
36. Gomi F, Oshima Y, Mori R, Kano M, Saito M, Yamashita A, *et al.* Initial versus delayed photodynamic therapy in combination with ranibizumab for treatment of polypoidal choroidal vasculopathy: The Fujisan study. *Retina* 2015;35:1569-76.
37. Hata M, Tsujikawa A, Miyake M, Yamashiro K, Ooto S, Oishi A, *et al.* Two-year visual outcome of polypoidal choroidal vasculopathy treated with photodynamic therapy combined with intravitreal injections of ranibizumab. *Graefes Arch Clin Exp Ophthalmol* 2015;253:189-97.
38. Saito M, Iida T, Kano M, Itagaki K. Five-year results of photodynamic therapy with and without supplementary antivascular endothelial growth factor treatment for polypoidal choroidal vasculopathy. *Graefes Arch Clin Exp Ophthalmol* 2014;252:227-35.
39. Sakurai M, Baba T, Kitahashi M, Yokouchi H, Kubota-Taniai M, Bikbova G, *et al.* One-year results of intravitreal ranibizumab combined with reduced-fluence photodynamic therapy for polypoidal choroidal vasculopathy. *Clin Ophthalmol* 2014;8:235-41.
40. Lee YA, Yang CH, Yang CM, Ho TC, Lin CP, Huang JS, *et al.* Photodynamic therapy with or without intravitreal bevacizumab for polypoidal choroidal vasculopathy: Two years of follow-up. *Am J Ophthalmol* 2012;154:872-80.