



Nonsustained ventricular tachycardia during outpatient anesthesia: a case report

Keoungah Kim¹, Seungoh Kim²

¹Department of Dental Anesthesiology, Dankook University Dental Hospital, Cheonan, Korea

²Department of Dental Anesthesiology, College of Dentistry, Dankook University, Cheonan, Korea

During the perioperative period, anesthesiologists frequently observe cardiac tachyarrhythmia. Ventricular tachycardia is very rare in non-cardiac surgeries. However, it can be fatal when it occurs. Therefore, anesthesiologists should be watchful so as to not to miss ventricular tachycardia and take the appropriate steps to manage it promptly. We present a case, with a review of related literature, in which a non-sustained ventricular tachycardia was observed in a patient who visited the hospital for dental treatment.

Keywords: Dental Care; Disabled Persons; Nonsustained Ventricular Tachycardia; Outpatient Anesthesia.



This is an Open Access article distributed under the terms of the Creative Commons Attribution Non-Commercial License (<http://creativecommons.org/licenses/by-nc/4.0/>) which permits unrestricted non-commercial use, distribution, and reproduction in any medium, provided the original work is properly cited.



INTRODUCTION

Cardiac tachyarrhythmia is commonly encountered during the perioperative period. Several pharmacological and non-pharmacological stimuli during anesthesia can result in cardiac arrhythmia [1]. Therefore, anesthesiologists must promptly identify and manage the disease appropriately.

Nonsustained ventricular tachycardia (NSVT) is a rare type of arrhythmia in noncardiac surgery. It has been defined as runs of ≥ 16 beats with a rate ≥ 125 beats/min [2] or >120 beats/min [3] using a time cutoff of 15 seconds [4], and at times, without strictly demarcated diagnostic criteria [5]. The exact prevalence of this disorder is not known because of the various diagnostic criteria used, but it is believed that no special treatment is required for it during surgery, under the premise that it does not involve heart disease. In this paper, we make

the point, however, that anesthesiologists should be careful not to miss occult cardiac disease in patients who have not undergone a cardiac evaluation. We report on NSVT observed in a patient who visited the hospital for dental treatment and review the related literature.

CASE REPORT

The patient was an 18-year-old woman who had been diagnosed with severe (grade 1) intellectual disability. She was 160 cm tall and weighed 34 kg. With the exception of taking anticonvulsants twice a day, she had no other medical history. General anesthesia was advised for oral examination and treatment because of poor cooperation.

A chest X-ray and blood tests performed preoperatively showed no specific findings. Preoperative electrocardiography (ECG) could not be performed because of

Received: June 17, 2021 • Revised: July 9, 2021 • Accepted: July 12, 2021

Corresponding Author: Seungoh Kim, Department of Dental Anesthesiology, College of Dentistry, Dankook University, 119 Dandae-ro, Dongnam-gu, Cheonan-si, Chungnam, 31116, Korea

Tel: +82-41-550-1863 Fax: +82-41-550-1863 E-mail: ksomd@naver.com

Copyright© 2021 Journal of Dental Anesthesia and Pain Medicine

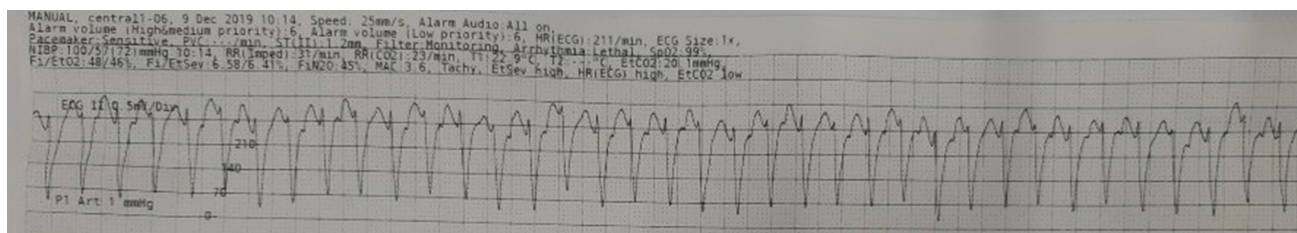


Fig. 1. Patient's Ventricular tachycardia electrocardiogram.

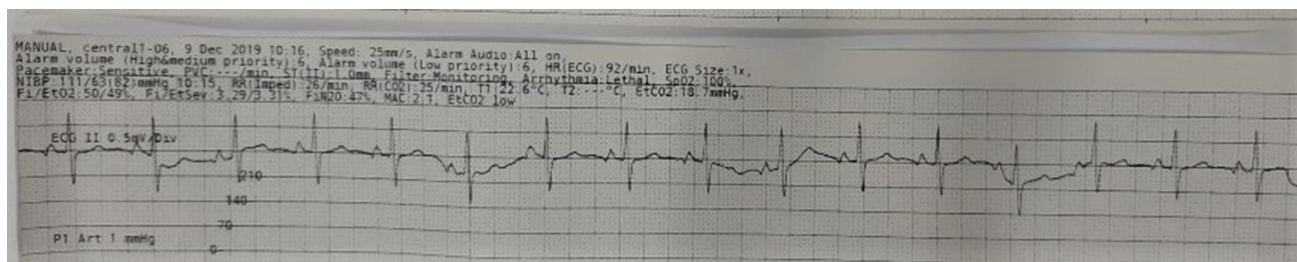


Fig. 2. Normal sinus rhythm at 3 min later.

the patient's lack of cooperation. Although her mouth opening was 3 finger breadths, and there was no limitation of neck extension, she had class II malocclusion, in terms of the American Society of Anesthesiologists (ASA) physical status classification 2. The patient had a history of general anesthesia for previous dental treatment, and no complications had occurred at that time.

The patient refused to sit on the dental chair; thus, rapid mask induction (8% sevoflurane, nitrous oxide (N₂O) 4 L/min, oxygen (O₂) 4 L/min) for anesthesia for loss of consciousness under body restraint was performed. Immediately after loss of consciousness, monitoring was initiated. Patient monitors for evaluating blood pressure (BP) in a noninvasive manner, temperature, pulse oximetry, and electrocardiography were attached simultaneously. Since it was difficult to maintain spontaneous breathing, positive pressure ventilation was provided with 4 vol% sevoflurane, N₂O 2 L/min, O₂ 2 L/min to the oropharyngeal airway, and manual ventilation was easily performed. While attempting intravenous catheterization (IV), her heart rate (HR) suddenly rose to 220; the ECG waveform at that time is shown in Figure 1. BP was found to be 100/57 mmHg, O₂ saturation was well maintained as assessed by the

pulse oximeter, and end-tidal carbon dioxide (EtCO₂) was confirmed to be approximately 50 mmHg.

Three types of management were considered by repeatedly trying IV. Since it was a regular wide QRS and blood pressure was in the normal range, a vagal maneuver of ocular compression was performed, a manual defibrillator was prepared to perform synchronized cardioversion to be used in the case of hemodynamic instability, and adenosine was prepared for administration as soon as an IV was secured.

After a heart rate of about 200 beats/min for about 3 min, her heart rate spontaneously recovered to a normal sinus rhythm, as shown in Figure 2. At that time, her vital signs, including blood pressure, were stable. After the rhythm recovered spontaneously, we had to decide whether to continue the treatment. The planned treatment was necessary for the patient, and we were prepared for manage the recurrence of ventricular tachycardia and other possible emergencies. After discussion with the attending dentist, we decided to proceed with anesthesia and treatment. Rocuronium (20 mg) was injected as a neuromuscular drug, and nasotracheal intubation was performed. Because epinephrine can cause tachycardia, we did not apply cotton soaked with epinephrine into the nasal cavity of the patient to induce nasal mucosa

vasoconstriction.

After intubation using the right nostril, and after fixing the tube at 23 cm, based on the naris, anesthesia was maintained with 50% N₂O, O₂, and 2-3 vol% of sevoflurane. The peak airway pressure was between 15 and 17 cmH₂O, and the partial pressure of EtCO₂ was maintained at approximately 30 mmHg, using the volume control mode.

Local anesthesia was performed by a dentist using a lidocaine ampule that did not contain epinephrine; then, No.38 tooth extraction and the scaling teeth were performed. The dental treatment procedure lasted 95 min, while 120 min was the duration of anesthesia, including the induction period. No recurrence of NSVT was observed during the remainder of the treatment.

After the dental procedure ended, an neuromuscular blocker antagonist was administered, and extubation was performed in the operating room after the respiration and consciousness of the patient was fully restored. No complications associated with general anesthesia or surgery were noted. To determine the cause and evaluate the possibility of further treatment, she was advised to undergo a cardiac evaluation prior to discharge. However, no further diagnostic issues were identified.

DISCUSSION

Herein, we report a case of an 18-year-old woman with NSVT who was scheduled for oral examination under general anesthesia. NSVT can be seen in a wide range of people, from apparently healthy people to patients with significant heart disease [6]. Usually, ventricular arrhythmias during anesthesia are caused by previous cardiac disease, electrolyte disturbances, or in relation to drugs used intraoperatively [7]. After major cardiac surgery, NSVT occurs in 50% of patients [2]. However, it is rare in non-cardiac surgeries. This is the first reported case of a ventricular tachycardia at this center since 2009. In those aged 40 years and under, the likelihood of congenital anomalies should be prioritized over ischemic

heart disease. Congenital anomalies include latent hypertension and valve disease, cardiomyopathies, and inherited channelopathies such as long QT syndrome, catecholaminergic polymorphic VT, Brugada syndrome, and other early repolarization syndromes that usually present with polymorphism [6].

According to the Advanced Cardiac Life Support guideline 2020 ACLS tachycardia algorithm, if hemodynamic compromise occurs in VT patients, synchronized cardioversion should be performed immediately [8] (supplement1). In patients who are otherwise stable, the clinical benefits of prompt cardioversion in the emergency department are less clear [9]. In this case, when VT was detected, we prepared an Automatic External Defibrillator (AED). However, the patient was hemodynamically stable; therefore, so we attempted IV access and used a vagal maneuver of ocular compression. However, before IV access could be achieved, normal sinus rhythm was noted.

Induction was performed using sevoflurane in our case. There are some reports of arrhythmias following sevoflurane induction [10,11]. These studies describe conversion to supraventricular tachycardia, polymorphic and monomorphic ventricular tachycardia, and bradycardia, occasionally progressing to supraventricular tachycardia. Although documented, cases such as those reported herein appear to be rare; in a previous study, there was a strong association between halothane and ventricular arrhythmias, especially ventricular tachycardia. However, sevoflurane has not been significantly associated with arrhythmia in the literature [12]. Although sevoflurane does not induce arrhythmias by stimulating the sympathetic nervous system like desflurane, it has been shown to sensitize the heart and reduce the threshold of epinephrine concentration. A low threshold of epinephrine is likely to cause arrhythmia [13]. It may, therefore, be inferred that arrhythmia might occur if sevoflurane is administered when the concentration of catecholamine is increased. In this case, the patient was irritable at the time of induction, and we used a high concentration of sevoflurane (8% sevoflurane N₂O 4

L/min, O₂ 4 L/min) for rapid mask induction. We, therefore, suspect that the catecholamine level of the patient was increased and that the high concentrations of sevoflurane could have been the cause for VT. A previous report explained the case of a 4-year-old child experiencing pulseless VT after the induction of anesthesia. The patient also did not have any congenital heart deformities. In that case, cardiac arrest suddenly occurred after inducing anesthesia with 8% sevoflurane and changing to 1.5% isoflurane to start surgery. Recovery of spontaneous circulation (ROSC) was noted after two cardioversions [14]. Arrhythmia caused by sevoflurane is very rare, but arrhythmia has been reported to occur during anesthesia induction. In patients with long QT syndrome, QT prolongation may worsen and cause ventricular tachycardia [15]. In our case, QT prolongation was not observed on the recovered ECG; hence, the arrhythmia may have been caused by the high concentration of sevoflurane, as there were no other risk factors [16].

This case is meaningful in terms of understanding instances where VT has occurred in patients without heart problems who have been diagnosed using sevoflurane, which was believed to not possess arrhythmia-causing characteristics. NSVT, which occurs in non-cardiac surgery, is rare and requires no special treatment. However, anesthesiologists should consider the possibility of arrhythmia being caused during induction with sevoflurane. Therefore, anesthesia should be performed with awareness of this possibility, and suitable preparations need to be taken to manage it if it does occur.

AUTHOR ORCID*s*

Keoungah Kim: <https://orcid.org/0000-0002-4924-1046>

Seungoh Kim: <https://orcid.org/0000-0001-7288-8457>

AUTHOR CONTRIBUTIONS

Keoungah Kim: Supervision, Visualization, Writing - original draft, Writing - review & editing

Seungoh Kim: Conceptualization, Project administration, Supervision, Validation

DECLARATION OF CONFLICTS OF INTEREST: The authors declare no conflicts of interest.

CONSENT: The present study obtained informed consent from patient for publish by the legal representative.

REFERENCES

- Alexander JP. Reflex disturbances of cardiac rhythm during ophthalmic surgery. *Br J Ophthalmol* 1975; 59: 518-24.
- Bloch Thomsen PE, Jons C, Raatikainen MJ, Moerch Joergensen R, Hartikainen J, et al. Long-term recording of cardiac arrhythmias with an implantable cardiac monitor in patients with reduced ejection fraction after acute myocardial infarction: the Cardiac Arrhythmias and Risk Stratification After Acute Myocardial Infarction (CARISMA) study. *Circulation* 2010; 122: 1258-64.
- Grimm W, Christ M, Bach J, Müller HH, Maisch B. Noninvasive arrhythmia risk stratification in idiopathic dilated cardiomyopathy: results of the Marburg Cardiomyopathy Study. *Circulation* 2003; 108: 2883-91.
- Caruso AC, Marcus FI, Hahn EA, Hartz VI, Mason JW. Predictors of arrhythmic death and cardiac arrest in the ESVEM trial. *Electrophysiologic Study Versus Electro-magnetic Monitoring*. *Circulation* 1997; 96: 1888-92.
- Teerlink JR, Jalaluddin M, Anderson S, Kukin ML, Eichhorn EJ, Francis G, et al. Ambulatory ventricular arrhythmias in patients with heart failure do not specifically predict an increased risk of sudden death. PROMISE (Prospective Randomized Milrinone Survival Evaluation) Investigators. *Circulation* 2000; 101: 40-6.
- Katritsis DG, Zareba W, Camm AJ. Nonsustained ventricular tachycardia. *J Am Coll Cardiol* 2012; 60: 1993-2004.
- Katz RL, Bigger JT Jr. Cardiac arrhythmias during anesthesia and operation. *Anesthesiology* 1970; 33: 193-213.
- Advanced Cardiac Life Support 2020, ACLS Tachycardia Algorithm for Managing Stable Tachycardia. Available from

- <https://www.acls.net/acls-tachycardia-algorithm-stable.htm>
9. Parida S, Thangaswamy CR. Cardiac tachyarrhythmias and anaesthesia: General principles and focus on atrial fibrillation. *Indian J Anaesth* 2017; 61: 712-20.
 10. Abe K, Takada K, Yoshiya I. Intraoperative torsade de pointes ventricular tachycardia and ventricular fibrillation during sevoflurane anesthesia. *Anesth Analg* 1998; 86: 701-2.
 11. Jellish WS, Lien CA, Fontenot HJ, Hall R. The comparative effects of sevoflurane versus propofol in the induction and maintenance of anesthesia in adult patients. *Anesth Analg* 1996; 82: 479-85.
 12. Blayney MR, Malins AF, Cooper GM. Cardiac arrhythmias in children during outpatient general anaesthesia for dentistry: a prospective randomised trial. *Lancet* 1999; 354: 1864-6.
 13. Hayashi Y, Sumikawa K, Tashiro C, Yamatodani A, Yoshiya I. Arrhythmogenic threshold of epinephrine during sevoflurane, enflurane, and isoflurane anesthesia in dogs. *Anesthesiology* 1988; 69: 145-7.
 14. Orr TM, Orr DL 2nd. Pulseless ventricular tachycardia during office-based anesthetic in a four-year-old child. *Anesth Prog* 2015; 62: 162-5.
 15. Kumakura M, Hara K, Sata T. Sevoflurane-associated torsade de pointes in a patient with congenital long QT syndrome genotype 2. *J Clin Anesth* 2016; 33: 81-5.
 16. Bhananker SM, Ramamoorthy C, Geiduschek JM, Posner KL, Domino KB, Haberkern CM, et al. Anesthesia-related cardiac arrest in children: update from the Pediatric Perioperative Cardiac Arrest Registry. *Anesth Analg* 2007; 105: 344-50.