

Acquired Cutis Laxa in a Patient with Type I Diabetes and Renal Failure under Immunosuppressive Therapy for Transplantation

Dear editor,

We herein describe a case of localized acquired cutis laxa without evidence of antecedent inflammation in a patient with type I diabetes and renal failure, who underwent transplantation followed by immunosuppressive therapy.

A 50-year-old man was hospitalized for the purpose of simultaneous pancreas and left kidney transplantation for uncontrolled type I diabetes. During admission, he was referred to our department, complaining of skin loosening on the trunk with unknown duration. He denied having any prior inflammatory conditions such as urticaria, contact dermatitis, and eczema. After transplantation, he received oral prednisolone (20 mg/d), tacrolimus (5 mg/d), and mycophenolate mofetil (2000 mg/d) to prevent graft versus host disease. He had no family history of similar skin conditions. Physical examination showed ill-defined lax, wrinkled, furrowed skin on the right back and buttock [Figure 1a-c]. There were several irregular vertical lines and also fine wrinkles on the surface. Skin laxity and sagging were not observed at other sites. Laboratory tests, including complete blood cell counts, immunoglobulins, and antinuclear antibodies were normal. Histopathological examination showed normal collagen fibers with scarcely scattered mononuclear cells around the folliculosebaceous units. Elastica van Gieson staining revealed a number of fragmented and shortened elastic fibers throughout the dermis in the lesional skin [Figure 1d, e]. There were no abnormalities in the subcutaneous fat tissue. Expression of matrix metalloproteinase-2 (MMP-2) was detected in the fibroblasts in the dermis [Figure 1e]. No systemic diseases such as connective tissue diseases, hematologic diseases, or autoimmune disorders were found after a detailed examination.

The present case presented with peculiar clinical features on the right back and buttock. Several diseases or conditions should be differentiated, *i.e.*, pseudoxanthoma elasticum-like papillary dermal elastolysis, mid-dermal elastolysis, anetoderma, and granulomatous slack skin; however, all of them were excluded by clinical and histopathological findings. The areas of skin laxity with wrinkled surface were observed restricted to the unilateral back but not the whole body. No prior inflammatory skin conditions such as urticaria, angioedema, eczema, erythema multiforme, and insect bite were observed, and the case was considered to be idiopathic; however, the reason why the back was exclusively involved was unknown. Transplantation was performed without problems, and the patient was referred

to us 3 weeks after the transplantation. There has been a rare postsurgical case in which localized acquired cutis laxa in the abdomen was induced by cesarean section.^[1] Our patient had surgical scars on the abdomen, whereas ill-defined lax, wrinkled, furrowed skin was seen on the right back and buttock. Although the surgically incised sites were not the same as the lax areas, our patient had taken immunosuppressive drugs.

Acquired cutis laxa is classified into type 1 and type 2 forms. Type 1 acquired cutis laxa commonly begins in adulthood, and the cutaneous involvement may be localized or generalized, with variable systemic involvement.^[2] On the other hand, type 2, also known as Marshall syndrome or postinflammatory elastolysis and cutis laxa, occurs in infancy or early childhood. The cutaneous involvement is predominantly localized and rarely generalized, without any systemic involvement. In the present case, the cutaneous involvement had been localized with an onset in adulthood, so we diagnose this case as acquired cutis laxa type 1 without any systemic involvement. There have been several cases of acquired cutis laxa in association with hematologic diseases, sarcoidosis, lupus erythematosus, rheumatoid arthritis, glomerulonephritis, IgA nephropathy, reaction to isoniazid

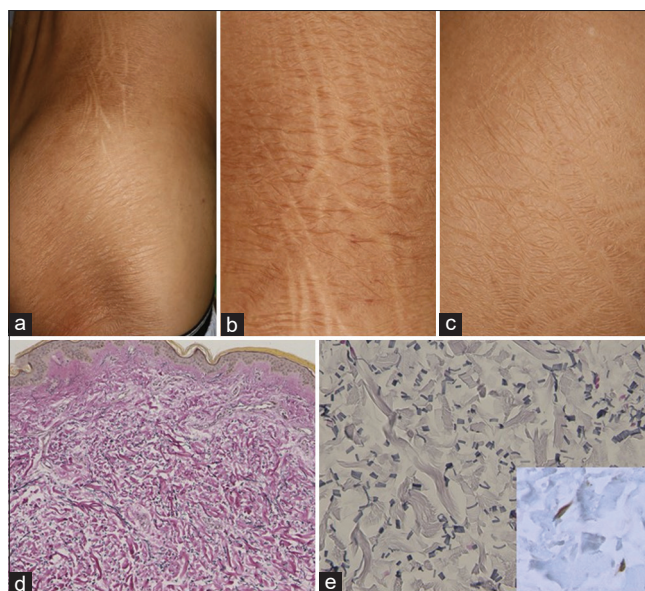


Figure 1: Loose, wrinkled, furrowed skin on the right back and buttock (a). Close-up view showed several vertical lines (b) and fine wrinkles on the surface (c). Skin biopsy showing loss of elastic fibers in the dermis of lesional skin (d) (Elastica van Gieson stain, original magnification $\times 100$). Higher magnification showed shortened and fragmented elastic fibers (e, $\times 200$), and MMP-2 expression on the fibroblasts in the dermis (insert ($\times 400$))

therapy, *Borrelia burgdorferi* infection, varicose veins, and alpha-1-antitrypsin deficiency.^[3-5] We speculate that the inflammatory reaction associated with either diabetes or renal failure may result in the destruction of the elastic fibers although there are no reports on the association of acquired cutis laxa and type I diabetes. Another possibility that laxed skin already existed prior to transplantation could not be excluded because the involved areas were on the back, where the patient would not have noticed. In the present case, histological examination revealed fragmented elastic fibers in the dermis without cellular infiltration, which correspond to the stage one of the four divided stages.^[5] Elastin is metabolized by proteolytic enzymes secreted by neutrophils, macrophages, and fibroblasts as well as by MMPs.^[3] In the present case, cellular infiltrates were scarce, but MMP-2 expression was detected on fibroblasts, which may play a role in degrading the elastic fibers. In conclusion, we report herein a case of localized acquired cutis laxa in a patient who underwent transplantation followed by immunosuppressive therapy. Further research is necessary to elucidate the mechanism of acquired cutis laxa.

Declaration of patient consent

The authors certify that they have obtained all appropriate patient consent forms. In the form, the patient(s) has/have given his/her/their consent for his/her/their images and other clinical information to be reported in the journal. The patients understand that their names and initials will not be published and due efforts will be made to conceal their identity, but anonymity cannot be guaranteed.

Financial support and sponsorship

Nil.

Conflicts of interest

There are no conflicts of interest.

Mai Endo, Toshiyuki Yamamoto

Department of Dermatology, Fukushima Medical University, Hikarigaoka, Fukushima, Japan


Address for correspondence:

Dr. Mai Endo,
Department of Dermatology, Fukushima Medical University
School of Medicine, Hikarigaoka-1, Fukushima, 960-1295, Japan.
E-mail: enmai04@fmu.ac.jp

References

1. Gverić T, Barić M, Bulat V, Situm M, Pusić J, Huljev D, *et al.* Clinical presentation of a patient with localized acquired cutis laxa of abdomen: A case report. *Dermatol Res Pract* 2010;2010:402093. doi: 10.1155/2010/402093.
2. Kumar P, Savant SS, Das A. Generalized acquired cutis laxa type 1: A case report and brief review of literature *Dermatol Online J* 2016;22:13030/qt8rb7f7w1.
3. Lewis KG, Bercovitch L, Dill SW, Robinson-Bostom L. Acquired disorders of elastic tissue: Part I. increased elastic tissue and solar elastotic syndromes. *J Am Acad Dermatol* 2004;51:1-21.
4. Garcia-Patos V, Pujol RM, Barnadas MA, Pérez M, Moreno A, Condomines J, *et al.* Generalized acquired cutis laxa associated with coeliac disease: Evidence of immunoglobulin A deposits on the dermal elastic fibers. *Br J Dermatol* 1996;135:130-4.
5. Lewis KG, Bercovitch L, Dill SW, Robinson-Bostom L. Acquired disorders of elastic tissue: Part II. Decreased elastic tissue. *J Am Acad Dermatol* 2004;51:165-85.

This is an open access journal, and articles are distributed under the terms of the Creative Commons Attribution-NonCommercial-ShareAlike 4.0 License, which allows others to remix, tweak, and build upon the work non-commercially, as long as appropriate credit is given and the new creations are licensed under the identical terms.

Access this article online	
Website: www.idoj.in	Quick Response Code 
DOI: 10.4103/idoj.idoj_504_21	

How to cite this article: Endo M, Yamamoto T. Acquired cutis laxa in a patient with type I diabetes and renal failure under immunosuppressive therapy for transplantation. *Indian Dermatol Online J* 2022;13:530-1.

Received: 08-Aug-2021. **Revised:** 08-Oct-2021.

Accepted: 11-Dec-2021. **Published:** 24-Jun-2022.

© 2022 Indian Dermatology Online Journal | Published by Wolters Kluwer - Medknow