

Successful embolization and long-term follow-up of a rare neonatal diaphragmatic hemangioma

SAGE Open Medical Case Reports
3: 2050313X15615471
© The Author(s) 2015
Reprints and permissions:
sagepub.co.uk/journalsPermissions.nav
DOI: 10.1177/2050313X15615471
sco.sagepub.com


Lin Wu¹, Ji Mei Wang², Zhong Wei Qiao³, Ying Liu Yan⁴
and Lai Shuan Wang⁵

Abstract

Background: Congenital hemangioma of the diaphragm is an extremely rare disease in childhood.

Methods: We report a newborn presenting with progressive respiratory distress and massive right hydrothorax due to congenital diaphragmatic hemangioma, requiring sustained ventilation support and chest drainage. The angiography revealed that the giant diaphragmatic hemangioma was supplied by the right internal thoracic, inferior diaphragmatic, and intercostal arteries. The selective embolization of the main feeding vessels was successfully achieved using the Embosphere particulates.

Results: The clinical long-term follow-up demonstrated the resolution of the symptoms, pleural effusion, and nearly complete regression of the hemangioma at 18 months of age.

Conclusion: Transcatheter embolization can provide an efficient therapy for symptomatic diaphragmatic hemangioma.

Keywords

Hemangioma, diaphragm, newborn, embolization, follow-up

Date received: 25 May 2015; accepted: 30 September 2015

Introduction

Congenital hemangiomas of the diaphragm are extremely rare, especially those diagnosed in newborn. We have found only five cases of a primary hemangioma in neonate.¹⁻⁵ One was reported by our radiologists with interest in the characteristics of multidetector computed tomography (MDCT) and magnetic resonance imaging (MRI). This is a neonate with right diaphragmatic hemangioma presenting with massive pleural effusion and respiratory distress, which underwent successful embolization. We continuously followed this baby up to 18 months of age and everything was going well. Here, we report this case for a second write-up, as the previous brief imaging report did not include the discussion about the clinical differential diagnosis (from prenatal to postnatal), detail and long-term outcome of the embolization procedure of this special rare case.

Case report

A prenatal ultrasound, performed at 33 weeks of gestation, showed moderate right hydrothorax. And follow-up ultrasound at 34.5 weeks revealed massive right-sided pleural effusion displacing the fetal heart to the left (Figure 1). A cesarean

delivery was performed after the failure of fetal thoracocentesis. The birth weight was 2825 g, and both of 1- and 5-min Apgar scores were 9. Shortly after birth, the girl required ventilation support by nasal continuous positive airway pressure (CPAP) and thoracocentesis for significant dyspnea and decreased pulse oxygen saturation (SPO₂) around 80%. A right chest tube was placed at 12 days of age, draining a total

¹Catheterization Laboratory, Children's Hospital of Fudan University, Shanghai, People's Republic of China

²Department of Prenatal Diagnosis Center and Department of Neonatology, Gynecology and Obstetrics Hospital of Fudan University, Shanghai, People's Republic of China

³Department of Radiology, Children's Hospital of Fudan University, Shanghai, People's Republic of China

⁴Ultrasound Laboratory, Gynecology and Obstetrics Hospital of Fudan University, Shanghai, People's Republic of China

⁵Department of Neonatology, Children's Hospital of Fudan University, Shanghai, People's Republic of China

Corresponding Author:

Lai Shuan Wang, Department of Neonatology, Children's Hospital of Fudan University, 399 Wanyuan Road, Shanghai 201102, People's Republic of China.

Email: laishuanwang@yahoo.com



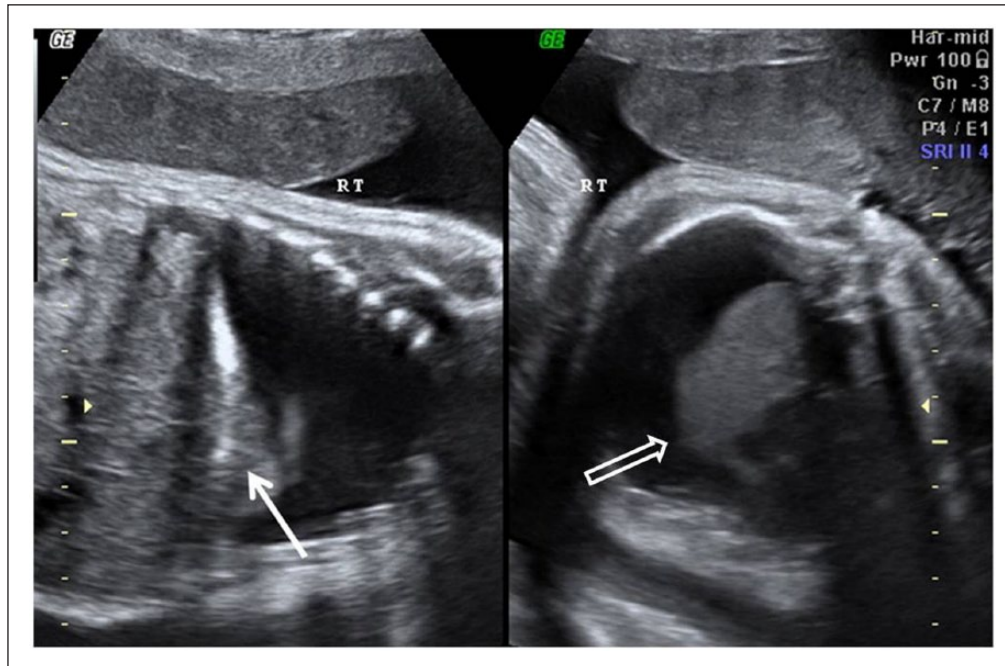


Figure 1. Prenatal ultrasound at 34.5 weeks of gestation age shows a large right hydrothorax, reaching 77mm × 49mm × 29mm with the right lung being compressed (open arrow), and the hyperechogenic mass (closed arrow) is recognized in the retrospection of the images.

amount of 677 mL of nonspecific clear and yellow pleural exudates for 15 days. Culture and cytology were negative for microorganism and malignancy.

The thoracic and abdominal ultrasound after birth suggested a mass in the right lower hemithorax, possibly developing from the right diaphragm, with extensive vascularization on color Doppler. Echocardiography showed no cardiac dysfunction or pericardial effusion. MDCT performed at 10 days of life confirmed a contrast-enhancing mass, invading mainly the right diaphragm and extending into the subdiaphragmatic space, indenting the liver. The characteristics of the lesion were consequently confirmed by MRI, which displayed the invasion into the right chest wall and right-sided pericardium as well. A rarely congenital diaphragmatic hemangioma was the suggested diagnosis.

In order to visualize the feeding vessels and possibly carry out embolization, angiography was performed on day 28. The patient was placed in a state of general anesthesia, and a 4-Fr sheath was placed in her right femoral artery by percutaneous puncture. At angiography, the enlarged right internal thoracic and inferior diaphragmatic arteries were demonstrated to be the main feeding vessels of the mass. Inferior vena cavogram showed significant compression at the diaphragm level, leading to the dependent patency of azygos vein draining part of blood to superior vena cava (Figure 2). After super-selective catheterization of each feeding vessel using a 3.0-Fr microcatheter over a micro-guidewire (COOK, USA), Embosphere particulates suspension was slowly injected (particle sizes of 300–500 μm, suspended in 3 mL contrast medium; BioSphere Medical) until complete occlusion was achieved. After initial

embolization, repeat angiography revealed that the right 8th, 9th, and 10th intercostal arteries had an increased width and contributed to the vascularity of the lesion. Considering the small amount of blood supplied by the intercostal arteries, embolization was not undertaken. During the procedure, a total of 22 mL of the nonionic low-osmolar contrast medium (iopamidol, 370 mgI/mL; China) was administered, and the total radiation exposure time and dose were 17.57 min and 209 mGy. The girl was extubated 4 days and discharged completely well 19 days after the procedure. At discharge, her SPO₂ was stable at 96%. The thoracic ultrasound showed the pleural effusion was well resolved. Symptoms improved and her weight increased to 3110 g.

The girl was quite well until 3 months of age; 53 days after embolization, she presented acutely with cough and recurrent tachypnea. Chest radiography showed pneumonia and moderate right hydrothorax. Antibiotics infusion was given for 6 days and a puncture of the pleural effusion was performed and yielded 110 mL of clear and yellow fluid. After pneumonia being resolved, she still presented with mild tachypnea associated with moderate right hydrothorax on chest X-ray film. However, the girl tolerated the feeding well with stable SPO₂ around 95%. We decided to take close follow-up on her. At 5 months of age, the child was doing well, demonstrating good catch-up growth without any complications, and ultrasound demonstrated the disappearance of pleural effusion. The ultrasound at 12 months confirmed the tremendous reduction in the size of the hemangioma, and the MRI at 18 months demonstrated nearly complete regression of the mass (Figure 3).

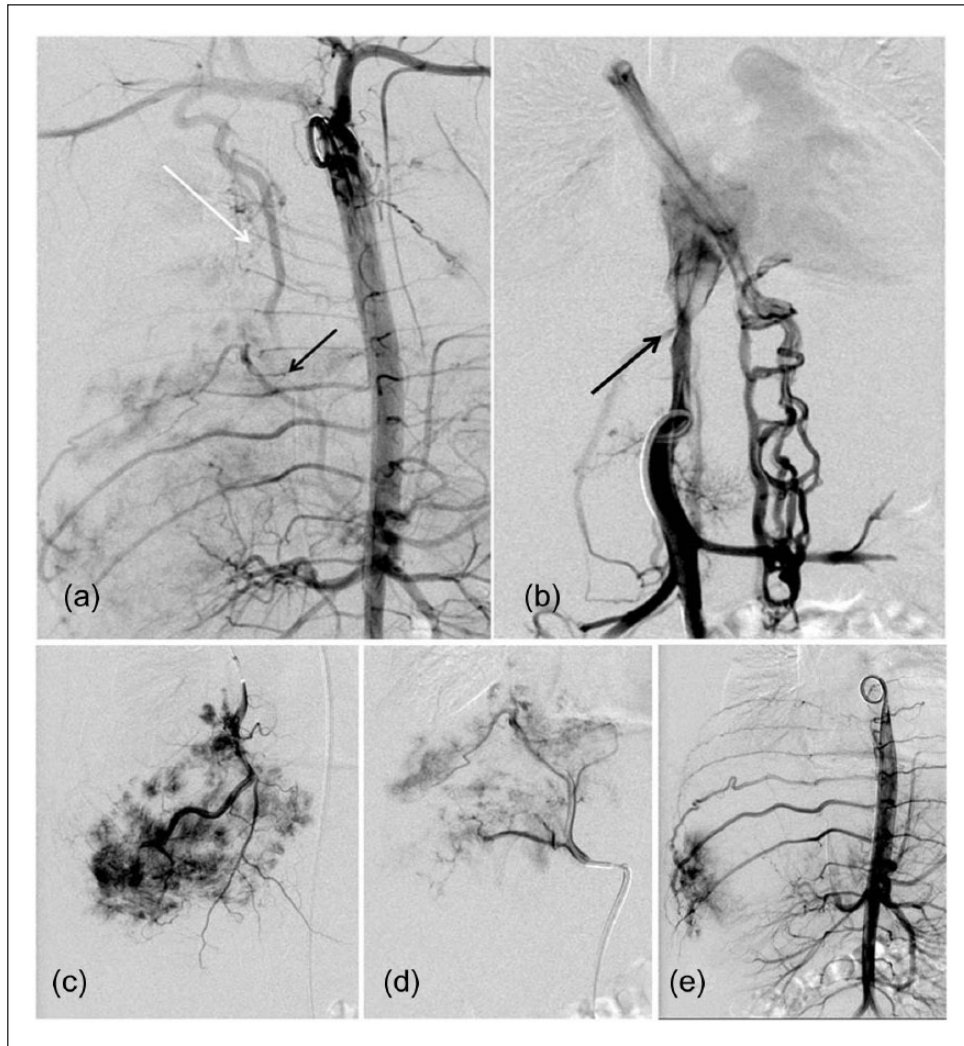


Figure 2. (a) Aortography shows a well-vascularized mass fed by the enlarged right internal thoracic (white arrow) and inferior diaphragmatic arteries (black arrow). (b) Inferior vena cavogram shows significant IVC compression at the diaphragm level (arrow), leading to the dependant patency of azygos vein. (c, d) The selective angiography of the right internal thoracic and inferior diaphragmatic arteries clearly shows a highly vascularized lesion without early filling venous branches. (e) After initial embolization, repeat angiography reveals that the right 8th, 9th, and 10th intercostal arteries have an increased width and contributed slightly to the vascularity of the lesion.

Given the rarity of the congenital neonatal diaphragmatic hemangioma, the point of our report is to present our experience of diagnosis and interventional embolization approach to obtain more awareness of physicians in their clinic practices. The publication was not only approved by the ethic committee of Children's Hospital of Fudan University but also consented by the child's parents.

Discussion

Hemangiomas are the most common vascular tumors in childhood. They usually affect the skin, extremities, and liver, whereas the hemangiomas of the diaphragm are extremely rare. To the best of our knowledge, diaphragmatic hemangioma in the literature to date has only been

described in six pediatric cases.^{1-4,6,7} In the present case, the diagnosis of a rapid involuting congenital diaphragmatic hemangioma was established mainly by the clinical manifestation and radiographic characteristics of the tumor. Initially, it was defined as an infantile hemangioma (IH) by our radiologists.⁵ However, in retrospection of the fetal ultrasound images, we had to admit that the hyperechoic giant mass adjacent to the right diaphragm was totally missed by our prenatal diagnosis. Therefore, the solitary lesion, which showed early intense enhancement and late diffuse homogeneous hypervascularization on MDCT and MRI, was large and fully formed antenatally, eventually involuted almost completely at 18 months without a significant postnatal proliferative phase. From the clinical view, the diagnosis of a rapid involuting congenital hemangioma

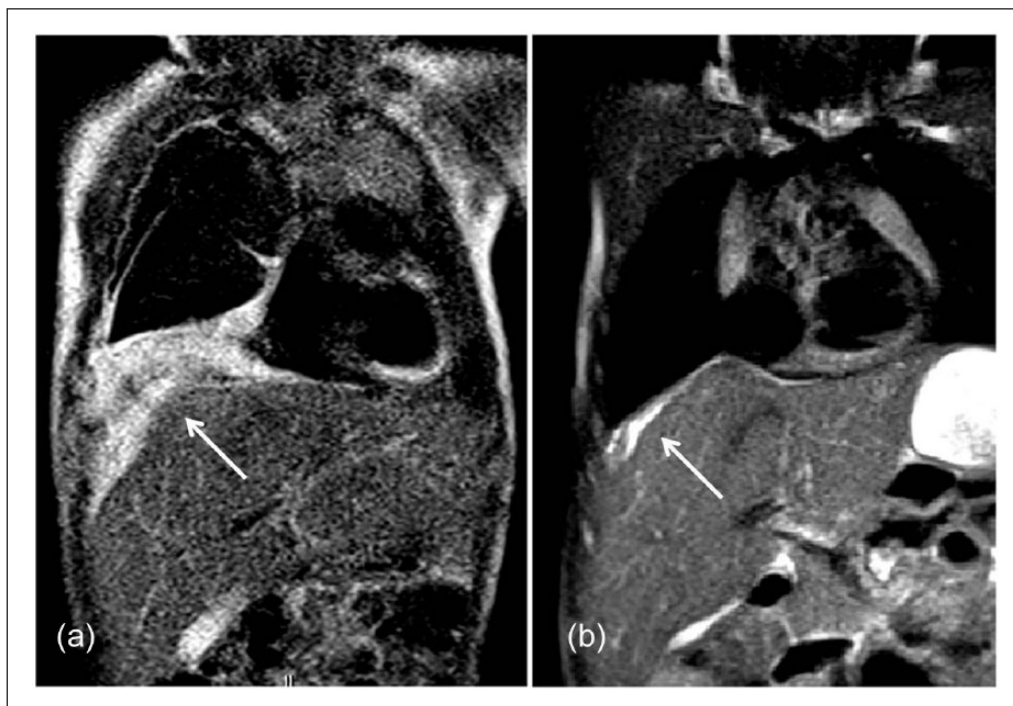


Figure 3. MRI shows the right diaphragmatic hemangioma. (a) The right diaphragmatic hemangioma shows a pattern of intense hyperintensity on T₂-weighted image (arrow). (b) The follow-up MRI examination at 18 months confirms the tremendous regression of the hemangioma (arrow) and the disappearance of pleural effusion.

(RICH) is preferable to IH in this case, although histological diagnosis was not obtained.

Diaphragmatic hemangioma might be asymptomatic; however, in our case, the baby girl presented with significant respiratory distress due to abundant hydrothorax. In the reported cases of neonatal diaphragmatic hemangiomas, three babies presented with significant ipsilateral hydrothorax, all of which were disclosed by prenatal ultrasonography.^{1,3,4} The possible pathophysiological mechanism of the pleural effusion has not been explained by any of the previous authors. We might speculate the obstructed venous return with increased venous pressure due to a space-occupying lesion in the thorax has mainly contributed to this grave situation.⁸ Thus, with the current widespread use of obstetric ultrasonography, the diaphragmatic hemangioma might be added as a differential diagnosis for fetal unilateral hydrothorax.

The general principle of management of hemangiomas in children has been fully discussed in our radiologists' report.⁵ In the present case, the baby required sustained ventilation support and chest drainage accompanied with incomplete feeding due to abundant hydrothorax; therefore, rapid removal of the lesion was indicated. After the risks and benefits of possible therapy options for a premature baby were weighed carefully, including long duration treatment of steroids or propranolol, interventional embolization, or surgical excision, we chose the embolization of the major feeding vessels as the initial therapy. In our case, because no evidence of arteriovenous shunt was shown on angiograms, super-selective injection of small size

particulate embolic agents was attempted to achieve distal devascularization at a terminal arteriolar level in order to minimize the risk of recanalization. As confirmation of the short-term palliation provided by embolization, the clinical signs of hydrothorax and respiratory distress improved immediately after the procedure. Nevertheless, recurrence of hydrothorax 2 months after embolization indicated the new collaterals might develop. Fortunately, the symptoms were shortly resolved by the subsequent spontaneous regression of the hemangioma to avoid repeated intervention, which were confirmed by follow-up Doppler ultrasound and MRI. In the previous pediatric cases of primary diaphragmatic hemangioma, surgical resection was performed in four patients and interventional embolization in one.^{1-3,6,7} In 2001, Curros et al. reported a neonate who was clinically asymptomatic and underwent embolization of the partly regressed diaphragmatic hemangioma at 6 months of life.¹ For the first time, we reported interventional embolization as an initial treatment for large symptomatic diaphragmatic hemangioma in a neonate. Compared with embolization procedure, which allows preservation of the native diaphragmatic tissue and function as well, the surgical excision of the very large hemangioma of the diaphragm in neonate may encounter difficulties in primary closure of the defect produced, probably leading to diaphragmatic dysfunction after operation, particularly in the early postoperative period.⁷ The efficacy of the embolization depends on better targeting of the feeding artery and the expertise of the team.

Acknowledgements

Lin Wu and Ji Mei Wang contributed equally to this article.

Declaration of conflicting interests

The author(s) declared no potential conflicts of interest with respect to the research, authorship, and/or publication of this article.

Funding

The author(s) received no financial support for the research, authorship, and/or publication of this article.

References

1. Curros F and Brunelle F. Prenatal thoracoabdominal tumor mimicking pulmonary sequestration: a diagnosis dilemma. *Eur Radiol* 2001; 11(1): 167–170.
2. Cacciaguerra S, Vasta G, Benedetto AG, et al. Neonatal diaphragmatic hemangioma. *J Pediatr Surg* 2001; 36(1): 21–22.
3. Tsang FHF, Lun KS and Cheng LC. Hemangioma of the diaphragm presenting with cardiac tamponade. *J Card Surg* 2011; 26(6): 620–623.
4. Cambonie G, Saguintaah M, Masson F, et al. Rapidly involuting congenital diaphragmatic hemangioma. *European Journal of Radiology Extra* 2009; 72(1): e125–e128.
5. Yao Q, Hu X, Huang G, et al. A case of diaphragmatic infantile hemangioma. *J Perinatol* 2013; 33: 576–577.
6. Kaniklides C and Dimopoulos PA. Diaphragmatic hemangioma: a case report. *Acta Radiol* 1999; 40(3): 329–332.
7. Olsen L, Gustafsson G, Kreuger A, et al. An unusual case of hemangioma of the left diaphragm in a child: successful use of Lyodura S for repair of the diaphragmatic defect. *Pediatr Surg Int* 1995; 10(3): 259–260.
8. Rocha G. Pleural effusion in the neonate. *Curr Opin Pulm Med* 2007; 13(4): 305–311.