



## Bilateral Fracture Clavicles occurring Simultaneously and treated with Intramedullary Fixation

Raghavendra S Kulkarni<sup>1</sup>, Rachana M Kulkarni<sup>1</sup>, Pankush Arora<sup>2</sup>, Shyam A K<sup>2,3</sup>

### ABSTRACT

**Introduction:** The standard treatment for clavicle fractures non operative but surgical management is essential in certain specific indications. The purpose of this study is to report a not very commonly seen bilateral fracture of a clavicle in a young female patient treated with intramedullary fixation

**Case report:** A 23 year old female patient sustained a bilateral clavicle fracture as a result of direct blow to shoulder and was treated with intramedullary K wires on both sides in single sitting. Postoperatively arm was maintained in a sling for 3 weeks. The implant was removed after a month when radiographs showed good bridging callus. After 8 weeks of fixation, she achieved full range of motion in both shoulders without any pain and was thus subsequently allowed to return to her daily activities.

**Conclusion:** For bilateral fractures clavicle, intramedullary fixation with K wire is a safe and effective modality for good pain relief and rapid recovery of range of motion. We did not encounter any complications.

**Keywords:** bilateral clavicle fracture, intramedullary fixation.

### INTRODUCTION:

Clavicle fractures are common and represent 5–10% of all fractures of the human skeletal system [1,2]. Epidemiological studies show that 70–82% of all clavicle fractures are located in the middle third, 10–

16% in the lateral and only 3% are found in the medial third [2,3]. The mechanism of injury in majority is axial loading due to insult to shoulder girdle directly and fall on outstretched hand in remaining cases [4]. The standard treatment though is conservative but recent literature shows increasing rates of delayed union and non unions with it [2,5,6]. Comminuted fractures, displaced fractures and increasing age are important causes for non union which can be avoided by using surgical line of management either in the form of plates and screws or intramedullary fixation though indications remain controversial [2,7,8]. Another indication for open reduction and internal fixation as highlighted by Schwarz et al [9] in 1992 was bilateral clavicular fractures though literature revealed that bilateral involvement of clavicle fracture is reported in a few studies [10] and distal bilateral fractures are even rarer [11]. These distal clavicle fractures are reported to be treated non operatively [12-15] or with internal fixation with plating [9,16,17] or rarely with external fixation [10] [Table 1]

In our case of bilateral distal clavicular fracture was fixed with intramedullary K wire with good results.

### CASE PRESENTATION:

A 23 year old female, house wife was admitted with history of fall from height with direct blow to both shoulders. The x-rays showed displaced fracture clavicle on both sides. Both the fractures were of type III b according to Allman classification [18,19].

After the base line investigations, under general anaesthesia, open reduction and intramedullary K wire fixation was done on both sides in one sitting. After fixation the fracture showed a good anatomic reduction. Post operatively both shoulders were immobilized in a collar and cuff sling for three weeks. Active assisted physiotherapy started from the first day of surgery with complete load reduction of both arms. The implant was removed at the end of four weeks under local anaesthesia.

<sup>1</sup> Civil Hospital, Sindhudurg, Sindhudurnagari, Maharashtra

<sup>2</sup> Sancheti Institute for Orthopaedics and Rehabilitation, Pune

<sup>3</sup> Indian Orthopaedic Research Group

### \*Address of Correspondance

Dr RS Kulkarni

District Civil Surgeon, Sindhudurg,

Maharashtra, India

Email - cssindhudurg@gmail.com



**Table 1:** Literature review of bilateral clavicular fractures

Reference No.	Author	No. of cases	Mode of injury	Treatment modality	Age / sex	Complications	Result
12	Marya KM et al 2002	5	High velocity trauma	Non operatively	NA	Nil	Healed
13	Sutherland et al 2000	2	Direct trauma to shoulders	Non operatively	71/ F	Nil	Healed (8 weeks)
14	H. Mullett et al 2001	1	Road traffic accident	Non operatively	51/F	Non union	Internal fixation done later
15	Hargan B et al 1981	1	Road traffic accident	Non operatively	39/F	Non union (at 13 weeks)	Internal fixation done later
16	Puranik et al 2007	1	Road traffic accident	Plating	45/F	Nil	Healed
9	Schwarz et al 1992	1	NA	Plating and non operative on other side	NA	Nil	Healed
17	Hart R et al 2004	1	Road traffic accident	Plating	24/F	Nil	Healed
10	N. Bonneville et al 2010	1	Road traffic accident	External fixation	58/F	Nil	Healed
	Our study 2011	1	Direct blow to shoulders	Intramedullary K wire	23/F	Nil	Healed (8weeks)

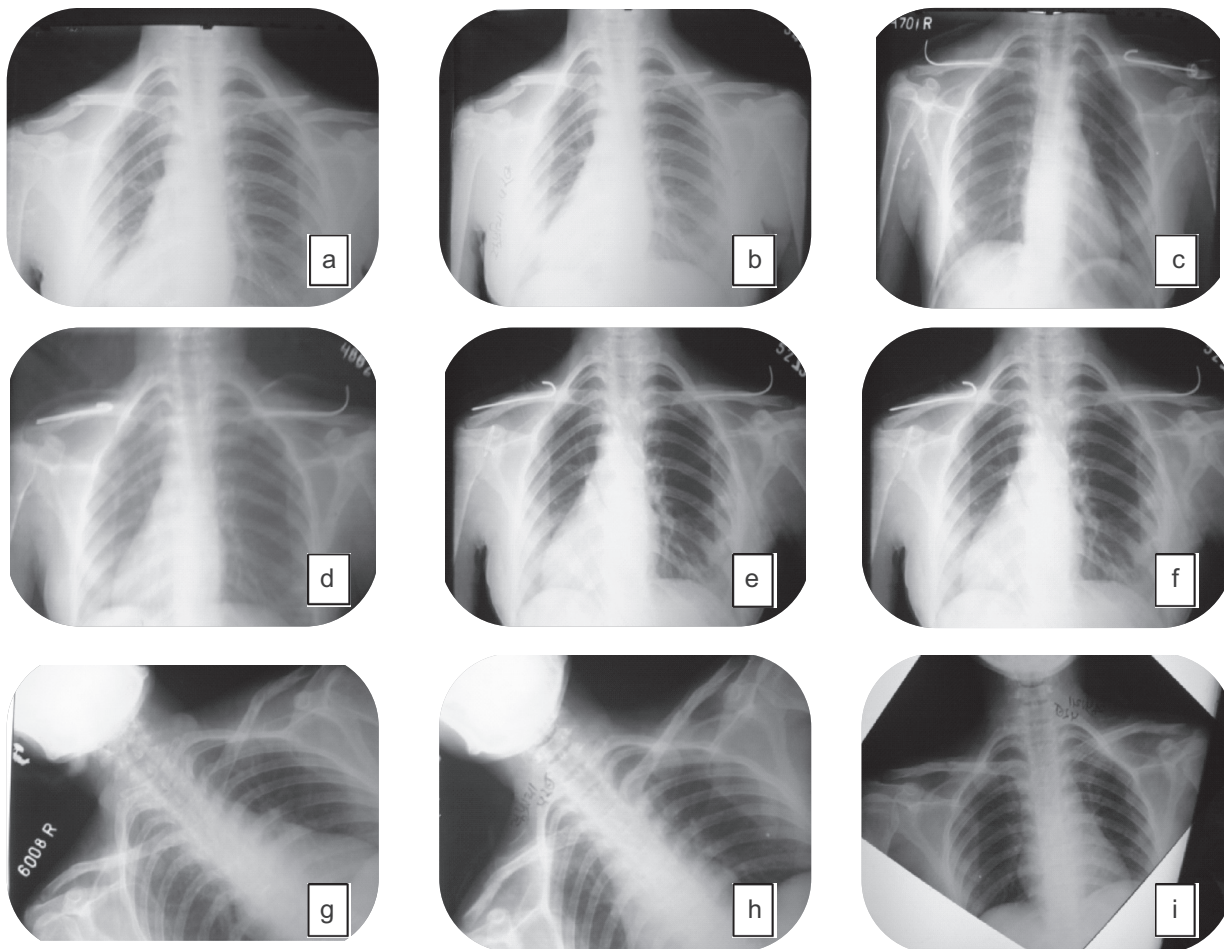
where NA =not available , F = female

Six weeks following surgery follow up radiographs showed good bone healing in an anatomic position and she achieved full range of motion in both shoulders, totally free from pain. At eight weeks, follow up radiograph showed a complete fracture healing of both clavicles. Subsequently patient was mobilized under full load.

## DISCUSSION

Bilateral clavicular fractures have been treated well with plates and screws [16], external fixation methods [10] and combination of conservative on one side and intramedullary fixation on other side [20] but we did not come across any literature support for concurrent bilateral traumatic fracture of clavicle treated with

intramedullary K wire though one case report suggested idiopathic concurrent nontraumatic bilateral fracture of clavicle should be considered for differential diagnosis of fracture clavicle [21]. Our aim was to check out the feasibility and functional outcome in terms of pain ,range of motion and union of fracture after surgical management of concurrent bilateral traumatic fracture of clavicle with intramedullary fixation in single sitting. Strauss et al [22] had shown similar results in a series of 16 patients of unilateral fracture clavicle treated with intramedullary fixation. The advantages of using intramedullary fixation are minimally invasive, safe alternative to plate and screw fixation, intramedullary compression, minimal stripping of periosteum,

**Figure 1:** Preoperative and post operative radiographs

- a and b = AP and PA views showing bilateral clavicle fractures  
 c = Immediate post operative radiograph showing intramedullary K wires  
 d = Post operative radiographs after 1 week  
 e = Post operative radiographs after 2 weeks.  
 f = Post operative radiographs after 1 month with no signs of non union  
 g = Immediately after removal of K-wire  
 h = Two weeks post removal K-wire  
 i = One month post removal K-wire showing good union

cosmesis and rapid recovery as outlined by Khalil [23] and Mueller et al [24]. The reasons for primary surgical stabilization in our case are completely displaced bilateral fractures and marked risk of non union or poor result in female patients as suggested by Smekal et al [25], Duijff et al [26] and Pieske et al [27]. Braunstein et al [20] revealed that quick analgesia and high mobility can be easily achieved in bilateral clavicular fractures if treated with intramedullary fixation which is in accordance with our report. A handful of case series or case reports

showing age, sex, mode of injury with modality of treatment with complications encountered are tabulated below [Table 1] which concludes that majority of bilateral involvement occurred in females because of high velocity trauma and in all except two studies [14,15] (fracture treated non operatively in both) there was no complication which is similar to our study. We were not able to find out any published recommendation concerning conservative or operative treatment for displaced bilateral traumatic clavicular fractures. The patient presented here,

showed good clinical outcome concerning pain, function and union of fracture [Fig. 1] although the intramedullary K wire used was not strong enough, hence the arms could not be mobilised under complete load reduction.

## CONCLUSION

For simultaneously occurred bilateral fractures clavicle, intramedullary K wire is a safe and effective modality for good pain relief and rapid recovery of range of motion .

### CLINICAL MESSAGE:

*Bilateral Clavicle fractures require internal fixation and intramedullary fixation using K wires is minimally invasive and gives good results*

## REFERENCES

- Nordqvist A, Petersson C. The incidence of fractures of the clavicle. Clin Orthop Relat Res. 1994 Mar;(300):127-32.
- Golish SR, Oliviero JA, Francke EI, Miller MD. A biomechanical study of plate versus intramedullary devices for midshaft clavicle fixation. J Orthop Surg Res. 2008 Jul 16;3:28.
- Robinson CM. Fractures of the clavicle in the adult. Epidemiology and classification. J Bone Joint Surg Br. 1998 May;80(3):476-84.
- Stanley D, Trowbridge EA, Norris SH. The mechanism of clavicular fracture. A clinical and biomechanical analysis. J Bone Joint Surg Br. 1988 May;70(3):461-4.
- Hill JM, McGuire MH, Crosby LA. Closed treatment of displaced middle-third fractures of the clavicle gives poor results. J Bone Joint Surg Br. 1997 Jul;79(4):537-9.
- Stegeman SA, de Jong M, Sier CF, Krijnen P, Duijff JW, van Thiel TP, de Rijcke PA, Soesman NM, Hagenaars T, Boekhoudt FD, de Vries MR, Roukema GR, Tanka AF, van den Bremer J, van der Meulen HG, Bronkhorst MW, van Dijkman BA, van Zutphen SW, Vos DI, Schep NW, Eversdijk MG, van Olden GDj, van den Brand JG, Hillen RJ, Frölke JP, Schipper IB. Displaced midshaft fractures of the clavicle: non-operative treatment versus plate fixation (Sleutel-TRIAL). A multicentre randomised controlled trial. BMC Musculoskelet Disord. 2011 Aug 24;12:196.
- Denard PJ, Koval KJ, Cantu RV, Weinstein JN. Management of midshaft clavicle fractures in adults. Am J Orthop (Belle Mead NJ). 2005 Nov;34(11):527-36.
- Wijdsicks FJ, Houwert RM, Dijkgraaf MG, De Lange DH, Meylaerts SA, Verhofstad MH, Verleisdonk EJ. Rationale and design of the plate or pin (POP) study for dislocated midshaft clavicular fractures: study protocol for a randomized controlled trial. Trials. 2011 Jul 15;12:177.
- Schwarz N, Hocker K. Osteosynthesis of irreducible fractures of the clavicle with 2.7 mm ASIF plates. J Trauma 1992;33:179-83.
- Bonnevalle N, Delannis Y, Mansat P, Peter O, Chemama B, Bonnevalle P. Bilateral clavicle fracture external fixation. Orthop Traumatol Surg Res. 2010 Nov;96(7):821-4.
- Qi ZL, Li JL, Li WY, Jia L. [Bilateral distal clavicle fractures: a case report]. Zhongguo Gu Shang. 2011 Apr;24(4):303-4.
- Marya KM, Yadav V, Kochar H . Bilateral clavicle fractures. Hong Kong Journal of Orthopaedic Surgery 2002;6(1):39-41
- Sutherland AG, Knight DJ. Bilateral fractured clavicles--a pair of cases. Acta Orthop Belg. 2000 Jun;66(3):306-7.
- Mullett H, Laing A, Curtin W. Successful operative treatment of bilateral clavicle non-union. Injury. 2001 Jan;32(1):69-70.
- Hargan B, Macafee AL. Bilateral pseudarthrosis of the clavicles. Injury 1981;12:316-8
- Puranik G, Gillham N. Bilateral fractured clavicles with multiple rib fractures. Emerg Med J. 2007 Sep;24(9):675. Erratum in: Emerg Med J. 2007 Dec;24(12):867.
- Hart R., Janeček M., Buček P., Chaker A. Bilateral clavicular and scapular neck fractures. Case report Scripta Medica (Brno) – February 2004;77 (1): 3-10
- Allman FL Jr. Fractures and ligamentous injuries of the clavicle and its articulation. J Bone Joint Surg Am. 1967 Jun;49(4):774-84.
- Singh R, Rambani R, Kanakaris N, Giannoudis PV. A 2-year experience, management and outcome of 200 clavicle fractures. Injury. 2011 May 20.
- Braunstein V, Kirchhoff C, Buhmann S, Mutschler W, Biberthaler P. [Bilateral clavicular fractures occurring at different times. Conservative vs operative therapy using intramedullary nailing--a case report]. Orthopade. 2007 Aug;36(8):757-60.
- Quinn RH, Drenga J. Case reports: concurrent bilateral nontraumatic fractures of the clavicle. Clin Orthop Relat Res. 2006 Jun;447:252-5.
- Strauss EJ, Egol KA, France MA, Koval KJ, Zuckerman JD. Complications of intramedullary Hagie pin fixation for acute midshaft clavicle fractures. J Shoulder Elbow Surg. 2007 May-Jun;16(3):280-4.
- Khalil A. Intramedullary screw fixation for midshaft fractures of the clavicle. Int Orthop. 2009 Oct;33(5):1421-4.
- Mueller M, Rangger C, Striepens N, Burger C. Minimally invasive intramedullary nailing of midshaft clavicular fractures using titanium elastic nails. J Trauma. 2008 Jun;64(6):1528-34.
- Smekal V, Oberladstaetter J, Struve P, Krappinger D. Shaft fractures of the clavicle: current concepts. Arch Orthop Trauma Surg. 2009 Jun;129(6):807-15.
- Duijff JW, Sier CF, Schipper IB. [The midshaft clavicular fracture]. Ned Tijdschr Geneesk. 2010;154:A2367.
- Pieske O, Dang M, Zaspel J, Beyer B, Löffler T, Piltz S. [Midshaft clavicle fractures--classification and therapy. Results of a survey at German trauma departments]. Unfallchirurg. 2008 Jun;111(6):387-94.

**Conflict of Interest : NONE**  
**Source of Funding : NONE**

