

# Management of injuries near the innominate artery bifurcation using an accurate kissing Viabahn stent technique

Shuang-Long Hu<sup>1</sup>, Chun-Xin Wang<sup>2</sup>,  
Hui-Jun Lu<sup>1</sup> and Ye Yuan<sup>1</sup> 

## Abstract

**Objective:** To evaluate the feasibility, safety, and efficacy of an accurate kissing Viabahn stent technique to manage injuries near the innominate artery bifurcation.

**Methods:** This retrospective study included patients with injuries near the innominate artery bifurcation who were treated with an accurate kissing Viabahn stent technique. Perioperative and follow-up data were extracted and analysed.

**Results:** A total of 10 patients were included (mean age, 52.8 years; six male and four female patients) with injuries at the following sites: the distal end of the innominate artery ( $n = 2$ ), the innominate artery bifurcation ( $n = 5$ ), the root of the right common carotid artery ( $n = 2$ ) and the origin of the right subclavian artery ( $n = 1$ ). All were successfully treated with the accurate kissing Viabahn stent technique. During follow-up (mean duration, 16.8 months), there were no complications, such as right upper limb ischaemia, neurological dysfunction, stent occlusion or migration.

**Conclusions:** The accurate kissing Viabahn stent technique to manage injuries near the bifurcation of the innominate artery was safe and effective, with good perioperative and long-term follow-up results.

## Keywords

Innominate artery, brachiocephalic artery, right subclavian artery, right common carotid artery, accurate kissing Viabahn stent technique, endovascular repair

Date received: 13 August 2019; accepted: 17 February 2020

<sup>1</sup>Department of Vascular Surgery, The Affiliated Wuxi People's Hospital of Nanjing Medical University, Wuxi, Jiangsu, China

<sup>2</sup>Department of Radiology, The Affiliated Wuxi People's Hospital of Nanjing Medical University, Wuxi, Jiangsu, China

## Corresponding author:

Ye Yuan, Department of Vascular Surgery, The Affiliated Wuxi People's Hospital of Nanjing Medical University, 299 Qingyang Road, Wuxi, Jiangsu 214023, China.  
Email: yeyuan777@163.com



## Introduction

The innominate artery is the first branch of the aortic arch, which then divides into the right common carotid artery and right subclavian artery. This innominate artery bifurcation is located in the thoracic cavity, close to the aorta and body surface. External forces have a small probability of injuring the distal end of the innominate artery, the innominate artery bifurcation, and the root of the right common carotid artery or right subclavian artery, resulting in corresponding pseudoaneurysms, dissection, and arteriovenous fistulae.<sup>1</sup> If the pseudoaneurysm is left untreated, it may increase in size and compress the surrounding tissues, including vessels, nerves, and the trachea, and it may eventually rupture, causing thrombosis or embolization.<sup>2</sup>

According to a detailed civilian single-centre trauma registry spanning 30 years, civilian innominate artery injuries accounted for 0–3% of recognized cases of arterial trauma.<sup>3</sup> However, only a few such cases have been reported in the literature.<sup>2,4–11</sup> The aim of the present study was to retrospectively evaluate the feasibility, safety, and efficacy of endovascular repair using an accurate kissing Viabahn stent technique that was performed in a series of patients with injuries near the innominate artery bifurcation.

## Patients and methods

### Study population

This retrospective case series included patients who were diagnosed with pseudoaneurysms associated with injuries near the bifurcation of the innominate artery, at the Department of Vascular Surgery, The Affiliated Wuxi People's Hospital of Nanjing Medical University, Wuxi, China between May 2013 and August 2018. For study inclusion, the distance between the

break and the bifurcation of the innominate artery must have been  $\leq 1$  cm.

Patients were first diagnosed based on computed tomography angiography (CTA) that was performed following injury using a dual slice spiral CT system (Siemens, Berlin, Germany); this method allows a detailed assessment of the injury site. During intraoperative imaging, the diameters of the right common carotid artery, right subclavian artery and innominate artery were measured, then stents were implanted that were oversized by approximately 20% to ensure secure device placement.

Ethical permission for this retrospective study was not deemed necessary as the techniques were routinely applied in the clinic, and the report aimed to describe how the stents can be released accurately in the innominate artery. Verbal informed consent was obtained from the patient or their legal proxy in cases where non-routine procedures were used.

### Procedure

All treatments were performed in the digital subtraction angiography (DSA) room at Wuxi People's Hospital, by the same surgeon (YY), who had many years of experience. After successful induction of local anaesthesia by subcutaneous injection of 1% lidocaine (5 ml), the patients underwent aortic arch angiography via incision or Seldinger puncture of one femoral artery. Then, focus was aimed toward innominate artery, selective right subclavian artery and right common carotid artery angiography if necessary. The purpose was to determine the location and extent of bleeding and to measure the diameter of associated vessels to formulate a surgical treatment plan and select appropriate stents.

Following successful induction of local anaesthesia, the right brachial artery was incised and blunt-dissociated, and a

Hi-Torque Supra Core<sup>®</sup> 35 guide wire (Abbott Laboratories, Chicago, IL, USA) was inserted proximal to the innominate artery. An additional Supra Core<sup>®</sup> 35 guide wire was inserted through the femoral artery, by incision or Seldinger puncture, into the right external carotid artery. A Viabahn stent (Gore<sup>®</sup> Viabahn<sup>®</sup> endoprosthesis; W.L. Gore and Associates, Flagstaff, AZ, USA) delivery system was transported through the femoral artery to the right common carotid artery until the end of the stent was parallel to the proximal innominate artery (stent 1). Then, another Viabahn stent delivery system was transported to the innominate artery via the right brachial artery until its head was parallel to the distal end of stent 1 (stent 2). Stent 1 was then released and stopped with approximately 1.5 cm remaining to be released. Next, the head of stent 2 was aligned with the end of stent 1, stent 2 was completely released, and then stent 1 was completely released, in that order. Following surgery, blood flow, endoleaks and bleeding were observed by DSA (Figure 1).

### Adjunctive pharmacotherapy

Patients were not administered pretreatment with aspirin or clopidogrel prior to endovascular repair. During endovascular repair,

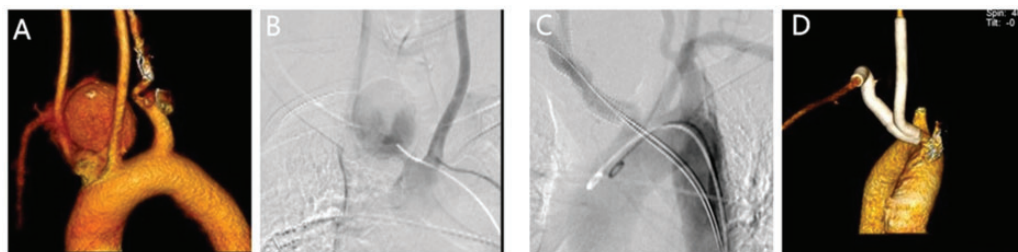
patients who had undergone elective surgery were administered unfractionated heparin (80 U/kg), but patients who had undergone emergency surgery due to massive haemorrhage and unstable vital signs did not receive unfractionated heparin. Following the procedures, all patients were administered aspirin (100 mg, orally, four times daily) and clopidogrel (75 mg, orally, four times daily) for 3 months and aspirin alone indefinitely thereafter, as previously described.<sup>12-14</sup>

### Follow-up

Follow-up observation was performed with Doppler ultrasound during the first 3 months, to confirm the patency of the stents. Then, contrast-enhanced CT was performed at 6 months postoperatively, and annually thereafter to assess size changes and to detect endoleaks or stent occlusions, migrations, or kinking. Procedural complications occurring within 30 days after the procedure were defined as early complications, and the rest were defined as late complications.

### Statistical analysis

Data are presented as *n* or mean, and were analysed using IBM SPSS software, version 19.0 (IBM Corp., Armonk, NY, USA).



**Figure 1.** Representative images showing: (A) Three-dimensional reconstruction of the aortic arch by computed tomography angiography (CTA) revealing a pseudoaneurysm at the innominate artery bifurcation; (B) Intraoperative aortic arch angiography confirming that the bleeding point was at the innominate artery bifurcation; (C) The accurate kissing Viabahn stent technique used to cover the bleeding points, revealing no subsequent bleeding or endoleak; and (D) Postoperative follow-up CTA three-dimensional reconstruction of the aortic arch showing that the stent was patent without endoleak or displacement.

## Results

### Baseline clinical characteristics

A total of 10 patients were included in this study, comprising six male and four female patients (mean age, 52.8 years; range, 25–71 years). Patients were found to have injuries at the following sites: the distal end of the innominate artery (two patients), the innominate artery bifurcation (five patients), the root of the right common carotid artery (two patients) and the origin of the right subclavian artery (one patient). The patient information is summarized in Table 1. Pseudoaneurysms were observed in all 10 of these cases, and to avoid life-threatening pseudoaneurysm rupture, all patients required surgical treatment. Three patients were injured due to trauma and were transported to hospital by ambulance. On hospital arrival, they had low blood pressure and rapid heart rate, indicating

that the patient was close to shock. These patients were immediately given an intravenous drip for fluid replacement and blood transfusion, and then underwent endovascular repair to isolate the bleeding via the accurate kissing Viabahn stent technique following CTA. The rest of the patients had iatrogenic injuries, but only one of them was critically ill and needed immediate surgery.

### Outcomes and follow-up

The accurate kissing Viabahn stent technique was successfully applied in all 10 patients, and no serious procedural or postprocedural complications occurred (Table 2). Small Type I endoleaks were noted at the time of stenting in two patients, and these endoleaks occluded spontaneously by the time CT angiography was performed at the 1- and 2-year follow-up. The mean duration of postoperative

**Table 1.** Summary of demographic and clinical data for the 10 included patients who underwent an accurate kissing Viabahn stent technique.

Parameter									
Case No.	Sex	Age, years	Injured vessels	Distance between injury site and BIA, cm	Medical history	Graft dimensions (CCA, RSA), mm	Cause of IA injury	Diameter of IA, mm	
1	M	51	IA	0.5	RF, ↑BP, DM	8 × 100, 10 × 100	iatrogenic injury	10	
2	M	77	IA	0.5	RF, ↑BP, CAHD	8 × 100, 10 × 100	iatrogenic injury	9	
3	F	50	BIA	0	RF, ↑BP	8 × 100, 10 × 100	iatrogenic injury	10	
4	F	67	BIA	0	RF, ↑BP, CAHD	8 × 100, 10 × 100	iatrogenic injury	10	
5	M	25	BIA	0	–	8 × 100, 10 × 100	trauma	10	
6	M	50	BIA	0	RF	8 × 100, 10 × 100	iatrogenic injury	9	
7	M	50	BIA	0	RF, ↑BP, DM	8 × 100, 10 × 100	iatrogenic injury	9	
8	F	55	RCCA	1.0	RF	8 × 100, 10 × 100	iatrogenic injury	9	
9	M	56	RCCA	0.5	↑BP	8 × 100, 10 × 100	trauma	10	
10	F	47	RSA	0.8	↑BP	8 × 100, 10 × 100	trauma	10	

M, male; F, female; IA, innominate artery; BIA, bifurcation of the IA; RCCA, right common carotid artery; RSA, right subclavian artery; RF, renal failure; ↑BP, hypertension; CAHD, coronary atherosclerotic heart disease; CCA, common carotid artery; DM, diabetes mellitus.

**Table 2.** Summary of outcomes in 10 patients who underwent an accurate kissing Viabahn stent technique.

Case no.	Immediate outcome	Early postoperative outcome	Duration of postoperative hospitalization (days)	3-month Doppler ultrasound	6-month CT follow-up	1-year CT follow-up	2-year CT follow-up	Follow-up duration (months)
1	Complete exclusion	Uneventful	7	Patency	Stents in good position	Stents in good position	Stents in good position	24
2	Complete exclusion	Uneventful	5	Patency	Stents in good position	Stents in good position	–	12
3	Small Type I endoleak	Uneventful	8	Patency	Stents in good position, small residual	Stents in good position, endoleak disappeared, Type I endoleak	Stents in good position	24
4	Complete exclusion	Uneventful	6	Patency	Stents in good position	Stents in good position	Declined further follow-up	12
5	Small Type I endoleak	Uneventful	9	Patency	Stents in good position, small residual	Stents in good position, small residual	Stents in good position, endoleak	24
6	Complete exclusion	Uneventful	7	Patency	Stents in good position	Stents in good position	–	12
7	Complete exclusion	Uneventful	6	Patency	Stents in good position	Stents in good position	–	12
8	Complete exclusion	Uneventful	5	Patency	Stents in good position	Stents in good position	–	12
9	Complete exclusion	Uneventful	4	Patency	Stents in good position	Stents in good position	–	12
10	Complete exclusion	Uneventful	6	Patency	Stents in good position	Stents in good position	Stents in good position	24

CT, computed tomography.

hospitalization was 6.3 days. The mean follow-up duration was 16.8 months, and there were no complications, such as right upper limb ischaemia, neurological dysfunction, stent occlusion and stent migration, all of which were defined as complications that would affect quality of life during the follow-up.

No cases of rupture or reintervention occurred following the use of this endovascular technique.

## **Discussion**

The innominate artery is the second most commonly affected large vessel after the isthmus of the aorta, and injury to this structure can present with a range of symptoms. Innominate artery injuries have high morbidity and mortality rates ranging between 5% and 43%.<sup>15</sup> The anatomical location of the innominate artery is behind the sternum, and this region also contains many nerves and blood vessels of different sizes; it is therefore difficult to perform dissections to achieve the corresponding vascular reconstruction, and such difficulties increase the morbidity and mortality rates of these procedures.<sup>2,5</sup> With the development of endovascular techniques, iatrogenic morbidity rates, hospital length of stay, surgical procedure times, haemorrhage and blood transfusion-related risks have decreased, and endovascular procedures also ensure long-term favourable outcomes.<sup>9</sup> In all ten cases in the current study, the site of injury was very deep and close to the innominate artery bifurcation, making it undoubtedly difficult and dangerous to perform open surgery. Endovascular repair was therefore the best choice at the time in these patients.

For simple injuries of the innominate artery, right common carotid artery or right subclavian artery that provide sufficient anchorage area, only a covered stent needs to be implanted in the target

artery.<sup>7,16</sup> In the present study, the injured sites were located near the innominate artery bifurcation. Because of the insufficient anchoring area, placing a covered stent only in the innominate artery, right common carotid artery or right subclavian artery would not have isolated the bleeding points. The accurate kissing Viabahn stent technique introduced in the present study had a 100% success rate, and it not only covered the bleeding point but retained the right subclavian artery and right common carotid artery.

One issue to address in cases of injury near the bifurcation of the innominate artery is how the Viabahn stent can be released to ensure that one stent is level with another stent in the innominate artery. The experience of the present study revealed key points to consider when using the accurate kissing Viabahn stent technique to treat injuries near the innominate artery bifurcation, as follows. Because the right common carotid artery and particularly the right subclavian artery are often distorted, the choice of approach and the release sequence of the Viabahn stent will seriously affect the isolation effect after stent release. The selected stents should therefore be of the same brand and type. Viabahn stents provide better flexibility and more traction capacity and very rarely collapse and rupture;<sup>12</sup> and were therefore viewed as the best choice in the present cases. It was considered that the right common carotid artery stent and right subclavian artery stent could be best implanted through one femoral artery and the right brachial artery, respectively. The release procedure described in the present study was mainly chosen due to the poor fluoroscopy effect of the stent when the Viabahn covered stent was completely released.<sup>17</sup> However, the marks at both ends of the stent were clearly visible on X-ray before release. If the stents are implanted through the bilateral femoral artery, even if the two



covered stents are flat in the innominate artery before release, distortion of the right subclavian artery and right common carotid artery will lead to different degrees of shortening of the two Viabahn stents when they are released. Hence, one stent will squeeze the other stent, causing stent endoleak, occlusion and potential failure of the surgery. The present technique may be used to not only treat the injury near the innominate artery bifurcation, but also to achieve anatomical reduction and restore the blood supply.

None of the patients needed to take aspirin or clopidogrel prior to surgery, but they all received both of these drugs for 3 months postoperatively and aspirin alone indefinitely thereafter. Following the operation, all patients were monitored by ambulatory electrocardiographic monitoring, and changes in blood pressure, heart rate and state of consciousness were closely observed. At the same time, the pseudoaneurysms were observed for whether they disappeared or continued to increase in size. During the initial 3-month follow-up period, patients were assessed using Doppler ultrasound as it is economical and simple to use and reduced potential damage to patients caused by contrast medium. If blood flow outside the stents was observed, further contrast-enhanced CT was performed. Contrast-enhanced CT was used during the subsequent follow-up because it helped to locate and deal with any problems that arose, in a timely and accurate manner.

The results of the present study may be limited by the fact that this was a small, retrospective, observational study conducted at a single centre. Multicentre studies with a large sample population and long-term follow-up are needed to further confirm the safety and effectiveness of this technique.

In conclusion, the present study showed that management of injuries near the

bifurcation of the innominate artery with an accurate kissing Viabahn stent technique was safe and effective and achieved a good effect during perioperative and long-term follow-up.


### Declaration of conflicting interest

The authors declare that there is no conflict of interest.

### Funding

This research received no specific grant from any funding agency in the public, commercial, or not-for-profit sectors.

### ORCID iD

Ye Yuan  <https://orcid.org/0000-0002-7928-2228>

### References

1. Choufani C, Aoun O, Mlynski A, et al. Endovascular treatment of brachiocephalic artery war-related injury. *Acta Chir Belg* 2017; 117: 256–259.
2. Axisa BM, Loftus IM, Fishwick G, et al. Endovascular repair of an innominate artery false aneurysm following blunt trauma. *J Endovasc Ther* 2000; 7: 245–250.
3. Mattox KL, Feliciano DV, Burch J, et al. Five thousand seven hundred sixty cardiovascular injuries in 4459 patients. Epidemiologic evolution 1958 to 1987. *Ann Surg* 1989; 209: 698–705; discussion 706–707.
4. Howe KL, Guirgis M, Woodman G, et al. Blunt innominate artery trauma requiring repair and carotid ligation. *Trauma Case Rep* 2017; 12: 24–27.
5. du Toit DF, Odendaal W, Lambrechts A, et al. Surgical and endovascular management of penetrating innominate artery injuries. *Eur J Vasc Endovasc Surg* 2008; 36: 56–62.
6. Sugisawa R, Sano M, Yamamoto N, et al. Axillo-axillary artery bypass with coil embolization of the innominate artery for a traumatic innominate artery aneurysm: a case report. *Vasc Endovascular Surg* 2018; 52: 573–578.

7. Kooraki S, Grohmann J, Elshikh S, et al. Covered stents for exclusion of iatrogenic common carotid artery-internal jugular vein fistula and brachiocephalic artery pseudoaneurysm. *J Neurointerv Surg* 2016; 8: e31.
8. Lee SK, Son JH, Kim YS, et al. Tracheo-innominate artery fistula caused by isolated innominate artery pseudo-aneurysm rupture. *J Thorac Dis* 2018; 10: E577–E580.
9. Mousa AY, Batsides GP and Vogel TR. Delayed presentation of traumatic innominate artery injury. *J Vasc Surg* 2010; 51: 1014.
10. Tsuda K, Ohkura K, Shintani T, et al. Endovascular treatment of a ruptured innominate artery aneurysm in Behcet disease. *Ann Vasc Surg* 2016; 33: 230. e1–4.
11. Li X, Shu C, Li QM, et al. Innominate artery bifurcation pseudoaneurysm repair by “kissing stent-grafts technique”: a case report. *J Med Case Rep* 2018; 12: 352.
12. Schönholz CJ, Uflacker R, De Gregorio MA, et al. Stent-graft treatment of trauma to the supra-aortic arteries. A review. *J Cardiovasc Surg (Torino)* 2007; 48: 537–549.
13. Tiewei Q, Ali A, Shaolei G, et al. Carotid cavernous fistulas treated by endovascular covered stent grafts with follow-up results. *Br J Neurosurg* 2010; 24: 435–440.
14. Ellens DJ, Hurlley MC, Surdel D, et al. Radiotherapy-induced common carotid pseudoaneurysm presenting with initially occult upper airway hemorrhage and successfully treated by endovascular stent graft. *Am J Otolaryngol* 2010; 31: 195–198.
15. Johnston RH Jr, Wall MJ Jr and Mattox KL. Innominate artery trauma: a thirty-year experience. *J Vasc Surg* 1993; 17: 134–139; discussion 139–140.
16. Cenizo NM, Gonzalez-Fajardo JA, Ibanez MA, et al. Endovascular management of radiotherapy-induced injury to brachiocephalic artery using covered stents. *Ann Vasc Surg* 2014; 28: 741. e15–18.
17. Gifford SM, Deel JT, Dent DL, et al. Endovascular repair of innominate artery injury secondary to air rifle pellet: a case report and review of the literature. *Vasc Endovascular Surg* 2009; 43: 301–305.