

# Evaluation of Resistive Index of Orbital Vessels Using Color Doppler Imaging in Patients with Type 2 Diabetes Mellitus

Vikrant Kanagaraju<sup>1</sup>, K. Divya<sup>2\*</sup>, M. Raajaganesh<sup>2</sup>, B. Devanand<sup>1</sup>

<sup>1</sup>Department of Radiology, PSG Institute of Medical Sciences and Research, Coimbatore, Tamil Nadu, India, <sup>2</sup>Department of Ophthalmology, PSG Institute of Medical Sciences and Research, Coimbatore, Tamil Nadu, India

## Abstract

**Background:** Resistive index (RI), derived from color Doppler imaging (CDI), is a marker of vascular resistance used widely in varied clinical settings. The aim of this study was to analyze the association between RIs of the orbital vessels in a pure cohort of type 2 diabetic patients with or without retinopathy using CDI. **Methods:** Fifty patients having type 2 diabetes and 50 age-matched controls were evaluated in this prospective study. Diabetic retinopathy (DR) was diagnosed based on seven-field stereo fundus photography and diabetic patients were divided into two. Patients with no DR ( $n = 26$ ) were taken as Group 1, while patients with DR ( $n = 24$ ) were taken as Group 2. CDI was performed and the RIs of the ophthalmic artery (OA), posterior ciliary artery (PCA), central retinal artery (CRA), and central retinal vein (CRV) were measured. **Results:** Significant differences were observed in the mean RI values of all orbital arteries between controls and patients with DR ( $P < 0.05$ ). Comparison of RI values between controls and Group 1 showed no significant differences. Mean RI values of the PCA and CRA were found to be significantly higher in the patients in Group 2 than in Group 1 ( $P = 0.03$  and  $P < 0.001$ , respectively). The duration of diabetes correlated with the mean RI of all the orbital vessels. RI of the CRA was a reliable predictive indicator for DR ( $P = 0.001$ ). **Conclusion:** RIs of the orbital arteries are significantly higher in patients with DR. RI of the orbital vessels can be a potentially useful biomarker in the early diagnosis and follow-up of patients with DR.

**Keywords:** Color Doppler ultrasonography, diabetic retinopathy, vascular resistance

## INTRODUCTION

Color Doppler imaging (CDI) is a convenient noninvasive method that gives information about the velocity of blood and vascular resistance at various sites of complex vasculature using simultaneous B mode ultrasound and Doppler images. The resistive index (RI), calculated from CDI, is a universally used measure of resistance to the arterial blood flow. In the recent past, RIs of the orbital arteries have been studied extensively to gain diagnostic and prognostic insight into a variety of clinical conditions, such as chronic obstructive pulmonary disease, hypertension, chronic kidney disease, and diabetes-related micro and macrovasculopathies.<sup>[1-5]</sup>

Usefulness of RI of the retrobulbar vessels in risk stratification and management of ophthalmic diseases such as diabetic retinopathy (DR), age-related macular degeneration, glaucoma,

retinal vein occlusion, and thyroid-associated orbitopathy has been documented in the literature.<sup>[6,7]</sup>

Several studies have evaluated the RI of the retrobulbar vessels in diabetic patients with or without retinopathy and have shown inconsistent results. While few studies have shown significant correlation between RI of the orbital vessels and severity of DR,<sup>[8,9]</sup> few others suggest that the hemodynamic alterations observed in the orbital arteries reflect macrovascular changes and are not related to DR.<sup>[5,10]</sup> The observed inconsistencies can be attributed partly to the differences in sample sizes, patient characteristics, duration of diabetes, methods of assessment of DR, and probe positions used for color Doppler

**Address for correspondence:** Dr. K. Divya,

Department of Ophthalmology, PSG Institute of Medical Sciences and Research, Coimbatore - 641 004, Tamil Nadu, India.  
E-mail: divyakcbe80@gmail.com

Received: 15-06-2020 Revised: 21-07-2020 Accepted: 24-08-2020 Available Online: 12-11-2020

### Access this article online

Quick Response Code:



Website:  
www.jmuonline.org

DOI:  
10.4103/JMU.JMU\_88\_20

This is an open access journal, and articles are distributed under the terms of the Creative Commons Attribution-NonCommercial-ShareAlike 4.0 License, which allows others to remix, tweak, and build upon the work non-commercially, as long as appropriate credit is given and the new creations are licensed under the identical terms.

**For reprints contact:** WKHLRPMedknow\_reprints@wolterskluwer.com

**How to cite this article:** Kanagaraju V, Divya K, Raajaganesh M, Devanand B. Evaluation of resistive index of orbital vessels using color Doppler imaging in patients with type 2 diabetes mellitus. J Med Ultrasound 2021;29:111-5.

measurement. Further, most of these studies included patients with comorbidities such as hypertension and coronary artery disease as well as those patients on cardiac or antihypertensive drugs, which might alter the vascular resistance.

The aim of this study was to analyze the association between RIs of the orbital vessels in a pure cohort of type 2 diabetic patients with or without retinopathy using CDI.

## MATERIALS AND METHODS

This prospective study was conducted between March 2017 and May 2019 from a tertiary care institution in South India. The institutional human ethical committee approval was obtained before the initiation of the study (IRB approval number: 16/325), and the principles of Declaration of Helsinki were adhered to. Informed, written consent was obtained from all the study participants. Fifty consecutive patients of type 2 diabetes (as per definition of the American Diabetes Association) were recruited for the study. Exclusion criteria were the presence of associated systemic hypertension, nephropathy, dyslipidemia, and cardiovascular diseases. Patients on medications known to affect systemic hemodynamics such as angiotensin-converting enzyme inhibitors, calcium channel blockers, and antimigraine drugs were excluded. Patients with a history of any ocular disease that might affect ocular blood flow such as retinal diseases, high myopia, glaucoma, previous ocular surgery, or panretinal photocoagulation were also excluded from the study. A control group of 50 age-matched subjects were included. None of the controls had any ocular or systemic disease.

Data regarding age, gender, body mass index (BMI), duration of diabetes and antidiabetic medications were obtained from all the study participants. Blood pressure and serum glycosylated hemoglobin (HbA1c) levels were determined.

All participants underwent a comprehensive eye examination and the presence/absence of retinopathy was diagnosed through dilated fundus examination and 30° stereoscopic fundus photograph of seven standard early treatment DR study fields using a digital fundus camera (TRC-50 DX Mydriatic Retinal Camera; Topcon Medical Systems, Oakland, NJ, USA). Diabetic patients were divided based on retinopathy into two groups. Group 1 contained patients with no DR; Group 2 included patients with DR. One eye (right eye, unless another ocular pathology was identified) was included from each study participant.

A masked expert radiologist performed CDI of the eye for all study participants using a color Doppler unit and a 12–5 MHz linear-array transducer (Philips iU22 xMATRIX ultrasound system). The CDI was performed with patients lying in the supine position with a 30° head tilt and any undue pressure on the eye was avoided. Examiner's hand was rested on the orbital margin, and sterile coupling gel was applied over closed eyelids. Angle of the transducer was taken as 30°–60° during the examination. CDI was performed after exclusion of any

other ocular or orbital pathologies by B mode, and optic nerve was considered as a reference for all further measurements. The velocity of blood flow in the ophthalmic artery (OA) was measured 20–30 mm behind the globe after crossing of the optic nerve in the nasal aspect. Blood flow velocity in the central retinal vein (CRV) and central retinal artery (CRA) was measured within the optic nerve around 5 mm behind the posterior margin of the eyeball. Blood flow velocity from the temporal branch of the short posterior ciliary artery (PCA) was determined approximately 5–10 mm posterior to the globe. The peak systolic velocity (PSV) and end diastolic velocity (EDV) measurements were taken for OA, CRA, PCA, and CRV. With the help of PSV and EDV, we calculated the vascular resistance based on the RI using Pourcelot's formula:

$$RI = (PSV - EDV)/PSV.$$

## Statistical analysis

Statistical analysis was carried out using Statistical Package for the Social Sciences (SPSS, SPSS Inc., Chicago, IL, USA) Version 24. Data were reported as mean ± standard deviation. The normality of data distribution was assessed by Kolmogorov–Smirnov test. One-way analysis of variance with a *post hoc* Bonferroni was used for analysis of normally distributed continuous data. Kruskal–Wallis analysis was used for analyzing nonnormally distributed data. Bivariate analysis using Pearson's correlation coefficient was used to study the relationship of RIs with biochemical and demographic variables of patients with diabetes. Receiver operating characteristic (ROC) curve analysis was used to explore the predictive indicators of DR. A  $P < 0.05$  (two-tailed) was considered statistically significant.

## RESULTS

The study consisted of 51 males and 49 females. The age of the participants ranged from 41 to 76 years. Duration of diabetes ranged between 6 months and 20 years. Among the diabetic patients studied, 26 had no DR and constituted Group 1. Group 2 consisted of 24 patients with DR. In Group 2, three patients had mild nonproliferative DR (NPDR) characterized by only few microaneurysms, seven had moderate NPDR (presence of more than just microaneurysms but less than severe NPDR), six had severe NPDR (presence of more than 20 intraretinal hemorrhages in each of four quadrants or definite venous beading in 2+ quadrants or prominent intraretinal microvascular abnormalities in 1+ quadrant), and eight had proliferative DR (presence of neovascularization of disc or elsewhere in the retina).

There were no statistically significant differences in the age, BMI, and blood pressure between controls and diabetic groups. Duration of diabetes and HbA1c levels were found to be significantly increased in Group 2 patients with DR ( $P < 0.001$ ). Significant differences were observed in the RI values of all orbital arteries between controls and diabetic groups. Table 1 shows the demographic data and clinical attributes of controls and diabetic subjects.

Subgroup analysis with *post hoc* comparison revealed significantly higher RI values in OA, PCA, and CRA in Group 2 compared to controls ( $P < 0.001$ ,  $P < 0.001$ , and  $P = 0.03$ , respectively). Comparison of RI values between Group 1 and controls showed no significant differences. When diabetic Groups 1 and 2 were compared, statistically significant differences were observed in the mean RI values of CRA and PCA ( $P < 0.001$  and  $P = 0.03$ , respectively).

In bivariate analysis, the mean RI values of all orbital vessels, namely OA, CRA, PCA, and CRV, had a significant correlation with the duration of diabetes ( $R = 0.396$ ,  $P < 0.001$ ;  $R = 0.282$ ,  $P = 0.005$ ;  $R = 0.334$ ,  $P = 0.001$ ; and  $R = 0.290$ ,  $P = 0.003$ , respectively) [Figure 1]. In addition, the mean RI of the OA correlated significantly with HbA1c levels ( $R = 0.321$ ,  $P = 0.001$ ) [Figure 2].

ROC analysis showed that the RI of CRA was a definitive predictive indicator for DR. RI of the CRA  $\geq 0.79$  indicated the

existence of DR with a sensitivity of 75% and a specificity of 73% (area under the curve = 0.780 [95% confidence interval: 0.650–0.909]) [Figure 3].

### DISCUSSION

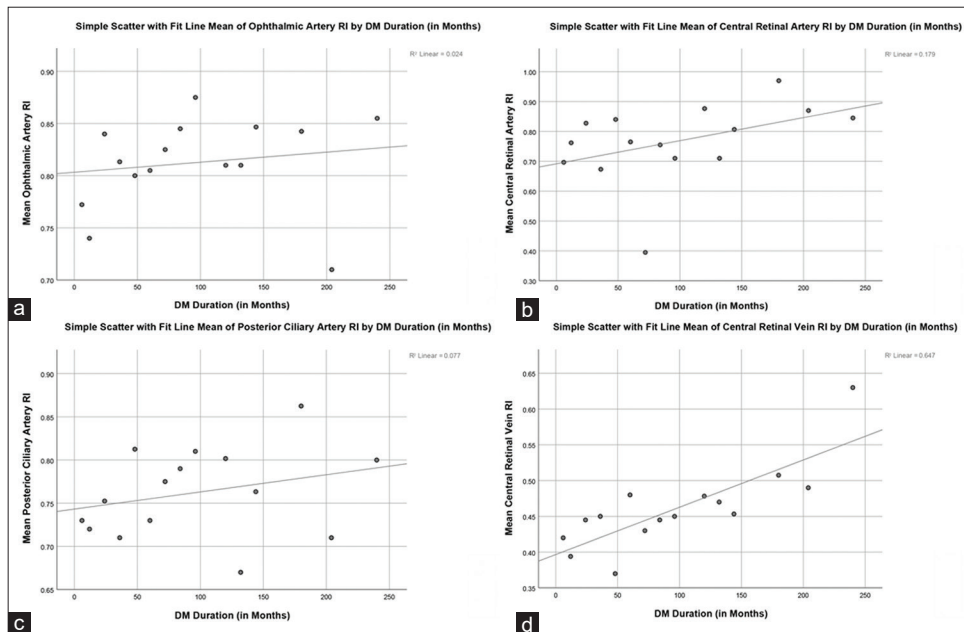
DR, a common microvascular complication of diabetes, is one of the leading causes for preventable blindness in people of the working age.<sup>[11]</sup> There has been conflicting evidence on the ocular hemodynamics as to whether blood flow is increased or decreased in diabetics. Curtis *et al.* have proposed a hemodynamic framework which states that there is an initial reduction in the perfusion of retina before the onset of DR which later increases as DR progresses.<sup>[12]</sup>

The various hematological changes observed in diabetes such as increased aggregation of erythrocytes and platelets, increased blood viscosity, and reduced deformability of

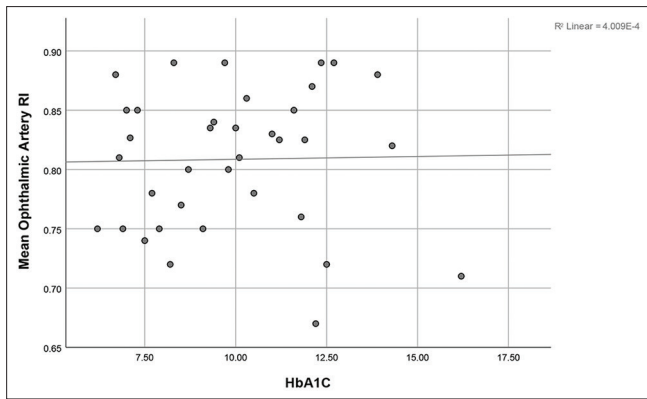
**Table 1: Demographic and clinical characteristics of controls and diabetic subjects**

Characteristic	Controls (n=50)	Group 1 (n=26)	Group 2 (n=24)	P
Mean age (years)	56.58±8.81	54.85±8.52	54.42±7.84	0.52
Mean body mass index (kg/m <sup>2</sup> )	23.35±3.62	25.33±2.69	24.09±3.88	0.07
Median systolic BP (mmHg)	110 (110-130)	120 (110-126.25)	120 (110-130)	0.16
Median diastolic BP (mmHg)	70 (70-80)	76.5 (70-80)	70 (70-80)	0.27
Median duration of diabetes (months)	-	24 (6-72)	120 (48-144)	<0.001
Mean glycosylated hemoglobin (%)	5.81±0.30	8.62±1.91	10.64±2.29	<0.001
Mean RI of OA	0.76±0.06	0.79±0.06	0.82±0.06	<0.001
Mean RI of CRA	0.77±0.07	0.72±0.17	0.84±0.11	0.001*
Mean RI of PCA	0.73±0.06	0.74±0.08	0.79±0.08	0.004*
Mean RI of CRV	0.42±0.12	0.44±0.12	0.46±0.11	0.29

\* $P < 0.05$ . BP: Blood pressure, OA: Ophthalmic artery, CRA: Central retinal artery, PCA: Posterior ciliary artery, CRV: Central retinal vein, RI: Resistivity index



**Figure 1:** Scatter diagram showing correlation between duration of diabetes and resistive index of (a) ophthalmic artery, (b) central retinal artery, (c) posterior ciliary artery, and (d) central retinal vein



**Figure 2:** Scatter diagram showing correlation between mean resistive index of ophthalmic artery and glycosylated hemoglobin

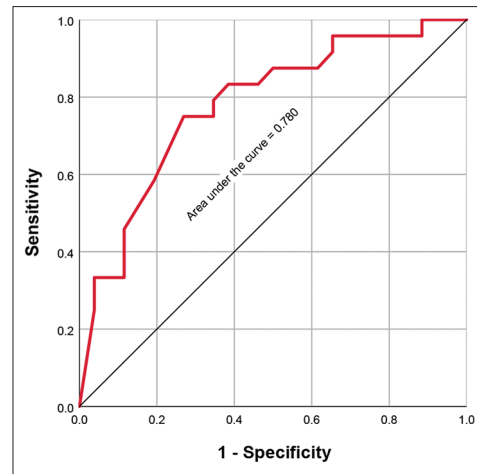
erythrocytes contribute to increased peripheral vascular resistance.<sup>[13]</sup> RI, an indirect measure of vascular resistance, can be useful to identify individuals at higher risk for developing DR. Further, RI, being independent of Doppler angle, has been shown to be reliable and reproducible with least coefficient of variation.<sup>[14]</sup>

Our study results demonstrate that significant changes occur in the RIs of the orbital vessels in patients with diabetes. The orbital vascular resistance (as reflected by RI) was found to be significantly increased in patients with DR as compared to controls and those in Group 1. Our observations are in agreement with certain other published studies.<sup>[15,16]</sup>

We observed no significant differences in the mean RI values between controls and those without DR. Our findings are similar to that of Basturk *et al.*, who evaluated the RI of the orbital arteries in type 2 diabetics with microalbuminuria. No significant differences were observed in the mean RIs of OA, CRA, and PCA between controls and no DR group.<sup>[9]</sup>

In contrast, Dimitrova *et al.* have noted higher RI in the PCA in patients with no DR than controls.<sup>[17]</sup> However, their study included patients with hypertension and longer duration of diabetes than ours. In patients with hypertension, the RI of the PCA is reported to be high and correlates with duration of hypertension.<sup>[18]</sup> Moreover, CDI was performed in erect posture, which might have influenced the results. Few other investigators have noted increased RI values in the OA and CRA in patients with diabetes but without DR compared to that of controls, suggesting that even before the appearance of overt DR, there is increased resistance to blood flow in the peripheral vascular bed.<sup>[19,20]</sup>

We found significantly greater RI in the PCA and CRA ( $P=0.03$  and  $P < 0.001$ , respectively) in patients with DR compared to those without DR. While the inner layers of the retina are perfused by the CRA, the choroidal vasculature (derived from PCA) is responsible for the nourishment of outer retina. The various pathological changes observed in DR, such as loss of pericytes, thickening of the capillary basement membrane, and vascular smooth muscle cells, lead to compromised arteriolar



**Figure 3:** Receiver operating characteristic curve analysis of resistive index of central retinal artery and diabetic retinopathy (area under the curve was 0.780)

integrity and autoregulation of blood flow. Loss of capillaries is critical to the pathogenesis of progressive retinal ischemia in DR and is a ubiquitous retinal finding from histopathological specimens.<sup>[21]</sup> Dropout of capillaries could be responsible for the increased vascular resistance observed in the RI of CRA and PCA in patients with DR. Further, the RI of the CRA was found to be a reliable predictive indicator of DR in our study. In this context, our findings are partly in agreement with that of Krasnicki *et al.*, who have noted significant differences in the RI of CRA in subjects with DR and concomitant coronary artery disease.<sup>[5]</sup> The CRA, one of the major feeding vessels of the retina, reflects the identified vascular changes that have been associated with DR more sensitively. It has been suggested that hemodynamics in OA, a medium-sized muscular artery with many branches, is unlikely to be influenced by isolated alterations in blood flow in one of the branches.<sup>[22]</sup>

However, with progression of DR, the RI of the OA can eventually increase due to ensuing vascular changes related to diabetes in both retinal and choroidal vasculature.

Our finding of positive correlation between RI of all orbital vessels and the duration of diabetes is in concordance with that of Karami *et al.*<sup>[23]</sup> With prolonged duration of diabetes, alterations in blood vessel diameter and perfusion pressure occur due to disturbed autoregulatory mechanisms, subsequently leading to changes in the resistance of all retrobulbar vessels. We identified a statistically significant correlation between RI of the OA and the levels of HbA1c ( $P = 0.001$ ). Clermont *et al.* have demonstrated reduction in the blood flow to retina with increasing HbA1c in subjects with type 1 diabetes without DR.<sup>[24]</sup>

Nagaoka *et al.* evaluated subjects with type 2 diabetes for changes in the retinal circulatory parameters using laser Doppler velocimetry and found significantly higher HbA1c in patients with the least retinal blood flow quartile, suggesting that poor glycemic control is associated with lowering of the retinal blood flow.<sup>[25]</sup>



Our study has several strengths. None of the patients had any associated vascular diseases such as hypertension. The presence of DR was assessed through seven-field stereo fundus photography for accuracy. A single experienced radiologist performed the CDI studies of the entire study participants, thereby eliminating interobserver variability. All examinations were performed with least pressure on the globe.

Limitations of our study include cross-sectional design and a small sample size. However, we intentionally excluded patients with other comorbid conditions to focus the effects of diabetes on retrobulbar circulation. Subgroup analysis of patients with different stages of retinopathy could not be performed because of limited sample size.

## CONCLUSION

RI of the orbital arteries are significantly higher in subjects with DR. RI of the orbital vessels can be a potentially useful biomarker in the early diagnosis and follow-up of patients with DR. This may be particularly helpful in patients with opacities in the ocular media.

## Financial support and sponsorship

Nil.

## Conflicts of interest

There are no conflicts of interest.

## REFERENCES

- Ozer T, Altin R, Ugurbas SH, Ozer Y, Mahmutyazicioglu K, Kart L. Color Doppler evaluation of the ocular arterial flow changes in chronic obstructive pulmonary disease. *Eur J Radiol* 2006;57:63-8.
- Reddy R. Usefulness of color Doppler imaging of orbital arteries in young hypertensive patients. *Proc (Bayl Univ Med Cent)* 2019;32:514-9.
- Rokni Yazdi H, Faraji S, Ahmadi F, Shahmirzae R. Color Doppler indices of orbital arterial flow in end-stage renal disease patients; are the changes related to chronic hemodialysis or chronic renal failure? *Iran J Radiol* 2012;9:12-6.
- Basturk T, Akcay M, Albayrak R, Unsal A, Ulas T, Koc Y. Correlation between the resistive index values of renal and orbital arteries. *Kidney Blood Press Res* 2012;35:332-9.
- Krasnicki P, Dmuchowska DA, Proniewska-Skrettek E, Dobrzycki S, Mariak Z. Ocular haemodynamics in patients with type 2 diabetes and coronary artery disease. *Br J Ophthalmol* 2014;98:675-8.
- Dimitrova G, Kato S. Color Doppler imaging of retinal diseases. *Surv Ophthalmol* 2010;55:193-214.
- Walasik-Szemplińska D, Pauk-Domańska M, Sanocka U, Sudoł-Szopińska I. Doppler imaging of orbital vessels in the assessment of the activity and severity of thyroid-associated orbitopathy. *J Ultrason* 2015;15:388-97.
- Khatri M, Saxena S, Kaur A, Bhasker SK, Kumar M, Meyer CH. Resistive index of ophthalmic artery correlates with retinal pigment epithelial alterations on spectral domain optical coherence tomography in diabetic retinopathy. *Int J Retina Vitreous* 2018;4:12.
- Basturk T, Albayrak R, Ulas T, Akcay M, Unsal A, Toksoy M, *et al.* Evaluation of resistive index by color Doppler imaging of orbital arteries in type II diabetes mellitus patients with microalbuminuria. *Ren Fail* 2012;34:708-12.
- Ino-ue M, Azumi A, Yamamoto M. Ophthalmic artery blood flow velocity changes in diabetic patients as a manifestation of macroangiopathy. *Acta Ophthalmol Scand* 2000;78:173-6.
- Cheung N, Mitchell P, Wong TY. Diabetic retinopathy. *Lancet* 2010;376:124-36.
- Curtis TM, Gardiner TA, Stitt AW. Microvascular lesions of diabetic retinopathy: Clues towards understanding pathogenesis? *Eye (Lond)* 2009;23:1496-508.
- Cho YI, Mooney MP, Cho DJ. Hemorheological disorders in diabetes mellitus. *J Diabetes Sci Technol* 2008;2:1130-8.
- Neudorfer M, Kessner R, Goldenberg D, Lavie A, Kessler A. Retrobulbar blood flow changes in eyes with diabetic retinopathy: A 10-year follow-up study. *Clin Ophthalmol* 2014;8:2325-32.
- MacKinnon JR, McKillop G, O'Brien C, Swa K, Butt Z, Nelson P. Colour Doppler imaging of the ocular circulation in diabetic retinopathy. *Acta Ophthalmol Scand* 2000;78:386-9.
- Gracner T. Ocular blood flow velocity determined by color Doppler imaging in diabetic retinopathy. *Ophthalmologica* 2004;218:237-42.
- Dimitrova G, Kato S, Tamaki Y, Yamashita H, Nagahara M, Sakurai M, *et al.* Choroidal circulation in diabetic patients. *Eye (Lond)* 2001;15:602-7.
- Akal A, Ulas T, Goncu T, Karakas E, Karakas O, Kurnaz F, *et al.* Evaluation of resistive index using color Doppler imaging of orbital arteries in geriatric patients with hypertension. *Indian J Ophthalmol* 2014;62:671-4.
- Arai T, Numata K, Tanaka K, Kiba T, Kawasaki S, Saito T, *et al.* Ocular arterial flow hemodynamics in patients with diabetes mellitus. *J Ultrasound Med* 1998;17:675-81.
- Tamaki Y, Nagahara M, Yamashita H, Kikuchi M. Blood velocity in the ophthalmic artery determined by color Doppler imaging in normal subjects and diabetics. *Jpn J Ophthalmol* 1993;37:385-92.
- Gardiner TA, Archer DB, Curtis TM, Stitt AW. Arteriolar involvement in the microvascular lesions of diabetic retinopathy: Implications for pathogenesis. *Microcirculation* 2007;14:25-38.
- Harris A, Joos K, Kay M, Evans D, Shetty R, Sponsel WE, *et al.* Acute IOP elevation with scleral suction: Effects on retrobulbar haemodynamics. *Br J Ophthalmol* 1996;80:1055-9.
- Karami M, Janghorbani M, Dehghani A, Khaksar K, Kaviani A. Orbital Doppler evaluation of blood flow velocities in patients with diabetic retinopathy. *Rev Diabet Stud* 2012;9:104-11.
- Clermont AC, Aiello LP, Mori F, Aiello LM, Bursell SE. Vascular endothelial growth factor and severity of nonproliferative diabetic retinopathy mediate retinal hemodynamics *in vivo*: A potential role for vascular endothelial growth factor in the progression of nonproliferative diabetic retinopathy. *Am J Ophthalmol* 1997;124:433-46.
- Nagaoka T, Sato E, Takahashi A, Yokota H, Sogawa K, Yoshida A. Impaired retinal circulation in patients with type 2 diabetes mellitus: Retinal laser Doppler velocimetry study. *Invest Ophthalmol Vis Sci* 2010;51:6729-34.