

Received: 2012.06.12
Accepted: 2012.07.03
Published: 2012.07.09

Major liver resection by a hanging maneuver for an infant with hepatoblastoma

Megumi Kobayashi, Masaru Mizuno, Yasushi Hasegawa, Hiroyuki Nitta, Go Wakabayashi

Department of Surgery Iwate Medical University School of Medicine, Morioka, Japan

Summary

Background:

The liver hanging maneuver (LHM) was reported to be a safe and accurate method for hepatectomy, and its use in adults has been increasing in recent years. Because fragility of a blood vessel and the tissue is concerned about in the children as compared with adults, the adaptation to children is subobsolete.

Case Report:

We describe a case involving an extended right hepatic lobectomy using the LHM in a 5-month-old infant. We received LHM using forceps of the size identical to adults. There were no postoperative complications.

Conclusions:

Anterior approach is suitable for the hepatoblastomas to form a bulky tumor. LHM is a useful and safe technique for hepatectomy in pediatric surgery.

key words:

liver hanging maneuver • hepatectomy • hepatoblastoma

Full-text PDF:

<http://www.amjcaserep.com/fulltxt.php?ICID=883241>

Word count:

1022

Tables:

–

Figures:

4

References:

15

Author's address:

Megumi Kobayashi, Department of Surgery Iwate Medical University School of Medicine, Morioka, Japan

BACKGROUND

Many pediatric surgeons encounter few cases that require a hepatectomy. Therefore, a wide technical gap exists between pediatric and adult hepatic surgery. However, the number of major adult liver resection cases has been recently increasing [1–3]. There have been at least 100 adult cases in which the liver hanging maneuver (LHM) was used at our institution. We report that LHM is a useful and safe technique for hepatectomy in pediatric surgery.

CASE REPORT

A 7-kg 3-month-old female infant was born by cesarean section at the 38th gestational week weighing 2738 g. Based on her family medical history, her 9-year-old sister was being treated for a brain tumor. Two months after the patient was born, a hard palpable tumor was noticed on her right flank, and she was referred to our hospital for a detailed work-up.

An abdominal CT scan revealed a hepatic tumor occupying segments V to VIII of the right lobe, shifting the middle hepatic vein to the left (Figure 1). The α -fetoprotein (AFP) level was elevated to 130610 ng/ml. The patient was diagnosed with hepatoblastoma following a biopsy. The patient underwent 2 cycles of Japanese Study Group for Pediatric Liver Tumor (JPLT) protocol-2 preoperative chemotherapy using cisplatin-pirarubicin (CITA) for a PRETEXT-II hepatoblastoma. The tumor was reduced from 10 cm to 6 cm in maximum diameter and was localized to the right hepatic lobe. However, because the left tumor margin was still in contact with the middle hepatic vein, we decided to perform an extended right hepatic lobectomy, which included the middle hepatic vein.

The operation was performed when the patient was 5 months old. A 6-cm skin incision was made below the right costal margin. A small amount of pale yellow ascitic fluid was observed. The tumor was observed to be partially protruding and there was no obvious dissemination. After taping the hepatic portal region using Pringle's method [4,5], we transected the right hepatic artery and right portal vein and confirmed the demarcation lines. We also confirmed the occupying sphere of the tumor with ultrasound.

We subsequently began the LHM with separation of the right and left hepatic veins from the suprahepatic portion of the inferior vena cava (IVC). Under non-direct vision in the dorsal surface of the liver, separation was continued with dissecting forceps (made by Nitta; Iwate medical University) (Figure 2), from the caudate lobe toward the loose space between the right hepatic vein and the trunk of the common hepatic vein (Figure 3). This forceps is useful for tunneling between the liver and the IVC through a small incision. Next, 4 mm teflon tape was passed through the area between the liver and the anterior surface of the IVC. If resistance occurs, the forceps should be wiggled left and right to search for an area with no resistance. Forced blunt dissection or forcibly probing with the forceps is dangerous when resistance is encountered. It is important to minimize detachment from the caudal direction as the short hepatic vein is located in the caudal 1/3 of the IVC. It is safest to perform as much of the detachment under as much direct visualization as possible.

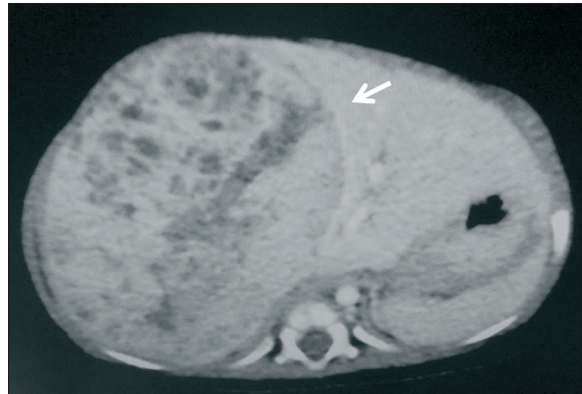


Figure 1. Prechemotherapeutic CT. A middle hepatic vein is performed exclusion of along mass margins (arrow).



Figure 2. This forceps with a highly-curved and long tip is useful for tunneling through a small incision.

We finally conducted the hepatic transection. Elevating the tape secured the IVC and revealed the hepatic parenchyma incision lines. We transected the peripheral region of the middle hepatic vein that was in contact with the tumor but preserved the proximal region. The transection was performed using the Cavatron Ultrasonic Surgical Aspirator (CUSA; Integra lifesciences Corporation, Newjersey, United States) and EnSeal (Ethicon Endo-Surgery, Ohio United States) (Figure 4).

The right triangular ligament and coronary ligaments were transected, and a 70×77×68 mm tumor was removed. The operative time was 242 minutes with a hemorrhage volume of 86 ml. There were no postoperative complications.

DISCUSSION

The LHM which was first reported in 2001 by Belghiti et al. [6], has increased the safety of anterior approach hepatectomy. At the same hospital, Nitta reported on the utility of the LHM method in laparoscopy-assisted operations in 2010 [7]. The most important advantages include hemorrhage, reduced risk of tumor rupture and reduced hemodynamic changes that accompany mobilization of the liver. Taping the anterior surface of the IVC secured the IVC and minimized mobilization of the liver. Elevating the entire liver ventrally with tape enables the liver to be divided at the optimal line. Simultaneously, this technique allows the deviations in detachment direction that are caused by unnecessary traction or operating table inclination. Retracting the detached edge also compresses the wall of the hepatic vein, which can reduce hemorrhage. This method allows for easier confirmation of hemorrhages and makes hemostasis

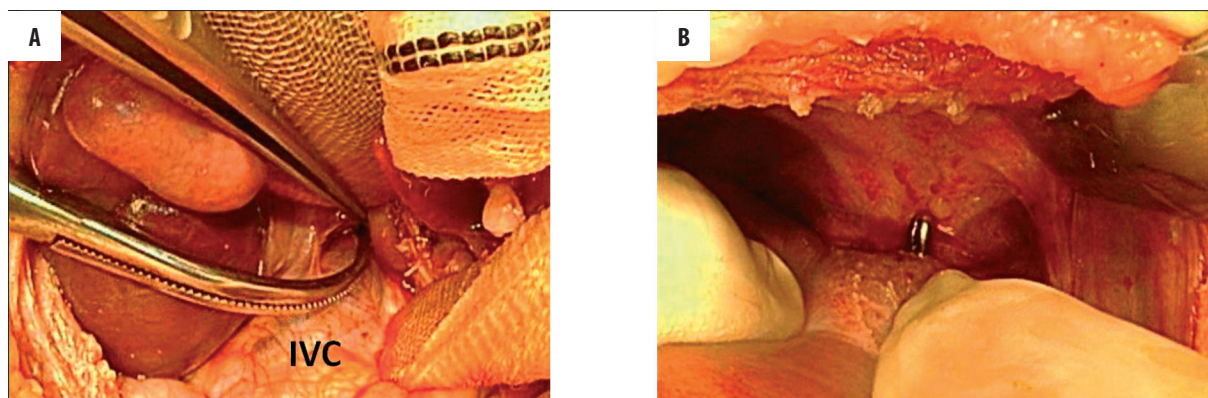


Figure 3. The forceps passes between the liver and the IVC. (A) This forceps is useful for tunneling through a small incision. (B) The tip of the forceps is appeared from the anterior surface of the IVC in the suprahepatic portion.



Figure 4. Lifting the liver with a tape, the liver transection was performed primarily using CUSA.

easier to achieve. In addition, retrograde IVC flow may be reduced because the detached surface is raised slightly by venous pressure.

The techniques for the detachment of the anterior surface of the IVC are based on the anatomical fact that the IVC has an avascular area in the 10 to 11 o'clock position [8,9]. However, it is important to determine whether the IVC is invaded by the tumor prior to surgery. Hepatoblastoma forms a large tumor in the hepatic parenchyma, often distorting the anatomical position of the liver [10]. This distortion increases the chances of erroneously identifying the hepatic incision lines. LHM is an extremely useful technique for the correct assessment of the anatomy of the patient's liver during hepatectomies. In the hepatic resection for large hepatocellular carcinoma (HCC), the anterior approach results in better operative compared with the conventional approach. It will be the same for hepatoblastoma [11,12]. Although we have performed hepatectomies using LHM on many adult patients at our facility, this was the first time that we performed a hepatectomy using LHM on a child. There is not the report operated on using LHM for the infants who are lower than 5-month-old or it. We successfully performed the procedure without any difficulty using the same instruments as those used for adult patients. Advances have been made in hepatic surgery in recent years, and strategies for the surgical treatment of hepatoblastoma are continually being developed [13–15].

CONCLUSIONS

It is absolutely vital that hepatectomies in pediatric patients be performed safely and precisely, making the LH method extremely useful.

REFERENCES:

- Ogata S, Belghiti J, Varma D et al: Two hundred liver hanging maneuvers for major hepatectomy. A single-center experience. *Ann Surg*, 2001; 31–35: 245
- Sasaki A, Nitta H, Otsuka K et al: Laparoscopic liver resections in a single institution. *Br J Surg*, 2000; 232: 753–62
- Peng SY, Qian HR, Li JT et al: The significance of liver hanging maneuver in liver-splitting anterior approach for hepatectomy. *Zhonghua Wai Ke Za Zhi*, 2005; 43(19): 1239–42
- Chouker A, Schachtner T, Schauer R et al: Effects of Pringle manoeuvre and ischaemic preconditioning on haemodynamic stability in patients undergoing elective hepatectomy; a randomized trial. *Br J Anaesth*, 2004; 93: 204–11
- Pringle JH: Notes on the arrest of hepatic hemorrhage due to trauma. *Ann Surg*, 1908; 48(4): 541–49
- Belghiti J, Guevera OA, Noun R et al: Liver hanging maneuver: a safe approach to right hepatectomy without liver mobilization. *J Am Coll Surg*, 2001; 193: 109–11
- Nitta H, Sasaki A, Fujita T et al: Laparoscopy-Assisted Major Liver Resections Employing a Hanging Technique. *Ann Surg*, 2010; 251(3): 450–53
- Sato TJ, Hirai I, Murakami G et al: An anatomical study of short hepatic veins, with special reference to delineation of the caudate lobe for hanging maneuver of the liver without the usual mobilization. *J Hepatobiliary Pancreat Surg*, 2002; 9: 55–60
- Zhang Y, Li Z, Liu A et al: The study on sectional anatomy and imaging of accessory hepatic veins. *Surg Radiol Anet*, 2009 [Epub ahead of print]
- Otte JB, Prichard J, Aronson DC et al: Liver transplantation for hepatoblastoma: Results from the International Society of Pediatric Oncology (SIOP) Study SIOPEL-1 and review of the world experience. *Pediatr Blood Cancer*, 2004; 42: 74–83
- Oldhafer KJ, Donati M, Lipp M et al: Anterior approach liver resection with the liver hanging maneuver: Technique and indications. *Chirurg*, 2012; 83: 65–70
- Liu CL, Fan ST, Cheung ST et al: Anterior approach versus conventional approach right hepatic resection for large hepatocellular carcinoma. *Ann Surg*, 2006; 244(2): 194–203
- Ikeda T, Yonemura Y, Ueda N et al: Pure laparoscopic right hepatectomy in the semi-prone position using the intrahepatic Glissonian approach and a modified hanging maneuver to minimize intraoperative bleeding. *Surg Today*, 2011; 41(12): 1592–98
- Kasahara M, Ueda M, Haga H et al: Living-donor liver transplantation for hepatoblastoma. *Am J Transplant*, 2005; 5: 2229–35
- Kim SH, Kim YK: Living donor right hepatectomy using the hanging maneuver by Glisson's approach under the upper midline incision. *World J Surg*, 2012; 36(2): 401–6