




Case Report

Thirty-two nails injected into the head: An operative report and review of the literature

Laura A. Zima¹, Subhiksha Srinivasan², Brad Budde¹, Ryan Kitagawa¹

¹Department of Neurosurgery, UT Houston, ²UT Health Houston, McGovern Medical School, UT Houston, Houston, Texas, United States.

E-mail: *Laura A. Zima - laura.a.zima@gmail.com; Subhiksha Srinivasan - subhiksha.srinivasan@uth.tmc.edu; Brad Budde - bradley.j.budde@uth.tmc.edu; Ryan Kitagawa - ryan.s.kitagawa@uth.tmc.edu



*Corresponding author:

Laura A. Zima,
Department of Neurosurgery,
UT Houston, Houston, Texas,
United States.

laura.a.zima@gmail.com

Received : 02 June 2022

Accepted : 28 July 2022

Published : 26 August 2022

DOI

10.25259/SNI_512_2022

Quick Response Code:



ABSTRACT

Background: Self-inflicted nail gun injuries are a rare phenomenon that can result in traumatic damage. The velocity of the nail is generally fast enough to penetrate the skull. However, the extent of damage depends on the exact angle and structures of the brain encountered by the nails.

Case Description: A 55-year-old male presented with 32 nails in the head and was found down. Initially, the patient presented with localization but had to be intubated soon after due to declining condition. This report describes the operative technique for safe removal of all nails, separated into six categories based on location and structures of the brain encountered. A review of literature revealed potential complications such as hemorrhage and infections and how to protect against these undesired effects.

Conclusion: Self-inflicted nail gun head injuries are an uncommon form of traumatic head injury. Some important tools that helped prevent our patient from developing major complications included stereotactic navigation, antibiotic prophylaxis, and angiography to carefully monitor for vascular injuries.

Keywords: Neurotrauma, Penetrating trauma, Sinus injury

INTRODUCTION

We describe a unique case of 32 independent nails to the head. The surgical technique to remove the nail depends on the penetration depth, trajectory, and surrounding structures. We review the operative set up and technique in detail for six different types of nail injuries encountered and review the relevant literature. All nails, including two through the superior sagittal sinus, were safely removed.

Nail gun injuries are associated with several important potential complications. One is the formation of a traumatic pseudoaneurysm. A 50% mortality rate in the event of a rupture has been reported, therefore, performing arteriograms a week or two after injury are helpful, especially in patients with a subarachnoid hemorrhage or hematoma.^[11] Another potential complication is the development of postinjury epilepsy, as mentioned by Sim *et al.*^[10] This can be managed with antiepileptic prophylaxis.^[10] Antibiotic prophylaxis is recommended to protect against infections and meningitis, another potentially life-threatening consequence of this injury.^[10]

This is an open-access article distributed under the terms of the Creative Commons Attribution-Non Commercial-Share Alike 4.0 License, which allows others to remix, transform, and build upon the work non-commercially, as long as the author is credited and the new creations are licensed under the identical terms.

©2022 Published by Scientific Scholar on behalf of Surgical Neurology International

CASE REPORT

The patient is a 55-year-old male who presented after being found down with nail injuries including multiple shots to the head. The patient was reportedly localizing on the scene but subsequently deteriorated and was intubated. Representative images on arrival are shown in Figure 1. He was taken to the operative room emergently. We describe the operative technique for removal of six broad categories of nails; under skin but not involving other structures, into bone but does not violate dura, into brain but uncomplicated, into brain with underlying hematoma, through air sinus (frontal sinus), and through blood sinus.

Operative technique

The patient was placed in the supine position in a Mayfield head holder with care to avoid placement of the pins into any of the fractures. Stereotactic image guidance was used to locate each nail and evaluate the trajectory and ultrasound was used to evaluate for intracerebral hemorrhage (ICH). A microscope was present for removal of the nails through the superior sagittal sinus. A bicoronal incision that was bisected posteriorly was used to access to all of the nails from a single operative approach.

Representative images of each nail type are shown in Figure 2.

Type 1: Nail under the skin but not penetrating the skull

This group is the most simple for removal, but this type is also the most likely to be left behind at the conclusion of the surgery. In our case, the skin was opened in its entirety first and any nails were removed directly. The overlying skin defect was closed with suture, and at the case conclusion, we obtain fluoroscopic imaging to ensure that none of these nails were left behind. This type of nail removal may also be performed at the bedside under local anesthesia if open surgical intervention is not otherwise needed.

Type 2: Nail penetrating the skull but not violating the dura

The next group of nails was those that went into the bone but did not violate the dura. This type of nail was confirmed with both preoperative imaging and image guidance before extraction. They were then removed and the holes were sealed using bone wax and the entrance wound sutured in case there were microperforations of the dura that could lead to cerebrospinal fluid (CSF) leakage. This type of nail could be removed at the bedside as well.

Type 3: Dural penetration without underlying hematoma

Multiple nails penetrated the dura and pia without underlying hematoma on preoperative imaging. A single burr hole

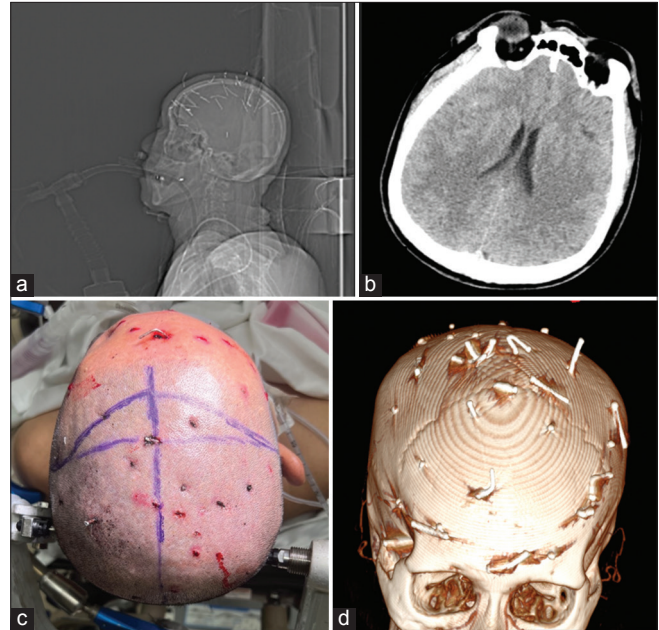


Figure 1: Representative images at patient presentation. (a) Scout skull X-ray showing all 32 nails, (b) CT axial showing no midline shift at time of presentation, (c) head with patient positioned and incision marked, and (d) stealth scan model used intraoperative.

followed by a 2–3 cm circular craniectomy was performed around the nail. Excessive nail movement was avoided and the bone flap was elevated in the nail trajectory as determined by image guidance. Any surface vascular hemorrhage was controlled followed by ultrasonography to ensure no ICH. The dura is opened followed by pial hemostasis. In this case, all of the nails were sequentially removed and a final ultrasound was performed at all sites to ensure no delayed hematoma before craniectomy reconstruction.

Type 4: Dural penetrating with underlying hematoma

The same procedure was performed for the nail removal as was done when there was no underlying hematoma initially. One nail was associated with an underlying subdural hematoma which was able to be evacuated through the small craniectomy. Another nail was associated with a <3 cm ICH visualized with ultrasound. The craniectomy was expanded and the hemorrhage was evacuated with ultrasound guidance through the original cortical violation of the nail.

Type 5: Penetration through an air sinus

The next type of nail that was encountered was through both the inner and outer tables of the frontal sinus. The craniectomy was performed superior to the frontal sinus and the dura was dissected away from the posterior table. The nail was removed and hemostasis was obtained. The ultrasound confirmed no underlying hematoma. The anterior table was

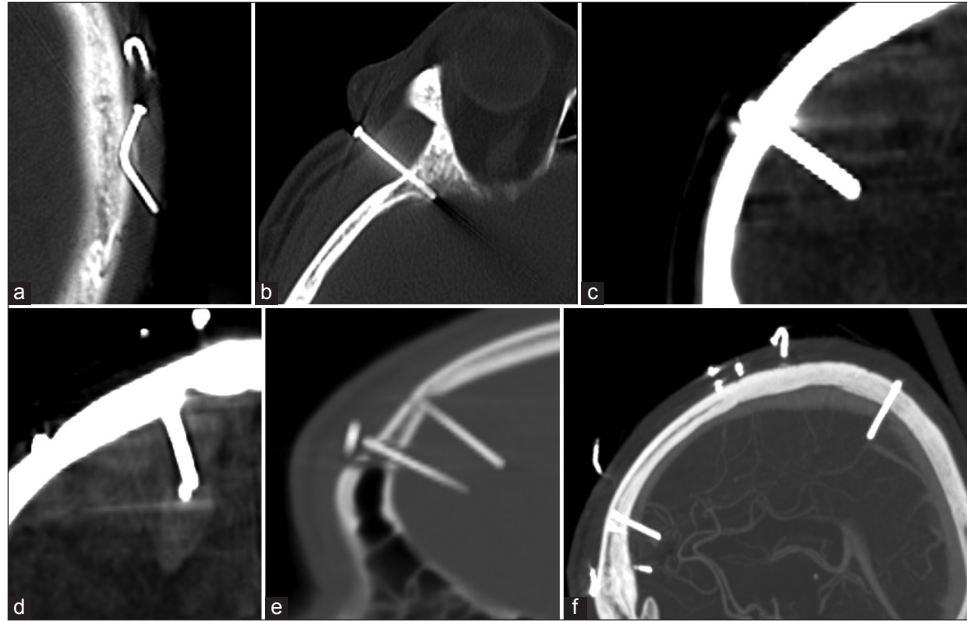


Figure 2: Seven types of nails described, under skin but not involving other structures not pictured. (a) Into bone but does not violate dura, (b) into brain but uncomplicated, (c) into surface vessel, (d) into brain with underlying hematoma, (e) through air sinus (frontal sinus), and (f) through blood sinus.

sealed using bone wax and the posterior table was isolated from the dural violation with vascularized pericranial graft. A complete cranialization of the frontal sinus was not needed given the small defect.

Type 6: Penetration through the superior sagittal sinus

These lesions have the most risk for hemorrhage and complications. Although the anterior sinus injuries are less dangerous given the ability to ligate the sinus if needed, the treatment is the same. A craniectomy with exposure of the sinus anterior and posterior to the nail is performed. The dura ipsilateral to the nail exit site is opened and the exit of the nail from the sinus is visualized with the operative microscope. The nail and bone flap are removed and the internal and external sinus defects are packed with foam-based hemostatic products and Cottonoid patties. This technique was effective in our case, but ligation or reconstruction of the sinus may be necessary in unique cases.

Ultrasound and fluoroscopy were performed before cranial reconstruction with titanium mesh to ensure no retained nails or operative hematomas. The patient had a postoperative venogram which demonstrated patent superior sagittal sinus. The patient was discharged home with the right hemiparesis.

DISCUSSION

Treatment of self-inflicted nail gun injuries to the head varies based on the penetration level and structures

affected. In most cases, the speed of a nail dislodged from a nail gun allows penetration of the skull.^[13] Important risk factors for poor clinical outcomes include major vascular injury in the brain, pseudoaneurysms, and injury to the brainstem.^[7,9,15] Therefore, it is important to use preoperative and postoperative CT or conventional angiography to assess extent of vascular involvement.^[9] In addition, stereotactic navigation, intraoperative ultrasound, and intraoperative fluoroscopy ensure complete removal of the foreign bodies to prevent future brain abscess formation.^[5]

Our case represents a unique situation in which 32 separate nails were encountered which fit into six different categories: under skin but not involving other structures, into bone but does not violate dura, into brain but uncomplicated, into brain with underlying hematoma, through air sinus (frontal sinus), and through blood sinus. While the previous case reports have described management of self-inflicted nail gun head injuries, this report separates the nails encountered into categories based on location of the nail penetration.

In general, subcutaneous nail gun injuries not involving other structures can easily be removed at bedside in a sterile manner using local anesthesia.^[3] The next type of nail reviewed includes penetration of the cranium but not into brain, which can be removed at the bedside or in the operating room. In our patient, a craniectomy was performed for each nail that penetrated into the brain followed by reconstruction. Arıcı *et al.* described a patient presenting with four nails that penetrated the cranium.^[11] The case

was done under general anesthesia.^[1] Two of the nails were removed directly after making a small incision on the scalp.^[1] The other two nails were extracted with a mini craniotomy.^[1] Although there is no difference in the reported morbidity between craniotomy versus craniectomy, both should be monitored closely for development of infection.^[1,14]

Occasionally, the nail may penetrate an air sinus. A previous case by Patchana *et al.* describes a nail extending through the maxillary sinus into the skull base and right frontal lobe.^[8] A craniotomy was performed with anterior extradural dissection until the entry point of the nail was found.^[8] There was no parenchymal hematoma in this patient's case.^[8] To cover the dural defect, a pericranial flap was set below and DuraGen and DuraSeal were also used to seal the defect.^[8] In our patient, a similar approach was used including a pericranial graft and foam-based hemostatic agents to seal the defect.

Although this case did not involve large vessel arterial injury, the previous literature has described a case of penetration of the basilar artery. Englot *et al.* presented a 51-year-old male with a nail gun head injury who presented with a subarachnoid hemorrhage and occlusion of the basilar artery.^[4] In this rare complication, a crani-orbital zygomatic osteotomy was performed with clipping of the penetrated wall.^[4] This clipping ensured protection from any retrograde blood flow affecting the circulation.^[4]

Another possible area of injury involves the venous sinuses. Nail gun injury to the superior sagittal sinus requires careful management required to prevent life-threatening bleeding.^[12] In the previous cases, anterior superior sagittal sinus injury has been treated using ligation with a gelatin sponge or similar hemostatic material.^[12] On the other hand, posterior superior sagittal sinus injury has required a more aggressive approach to reduce the risk for cerebral edema.^[12] Wang *et al.* described that posterior superior sagittal sinus injury could require reconstruction of a collateral blood vessel pathway due to the anatomic significance of the posterior superior sagittal sinus.^[12] However, the case reported here was uncomplicated, allowing packing with hemostatic products without sinus ligation.

Common complications of nail gun head injuries include meningitis, CSF leak, and cerebral abscesses.^[10] The recommended prophylaxis by the "Infection in Neurosurgery" Working Party of British Society includes intravenous co-amoxiclav 1.2 g q 8h, or intravenous cefuroxime 1.5 g, then 750 mg q 8 h with intravenous metronidazole 500 mg q 8 h (or 1 g q 12 h per rectum or 400 mg q 8 h by mouth).^[2] Another important complication is posttraumatic aneurysm, normally detected 2–3 weeks after injury.^[10] Therefore, vascular imaging should also be performed preoperatively, postoperatively, and a few weeks after injury.^[6]

CONCLUSION

We describe a unique case of 32 independent nails to the head. We describe the operative technique for the removal of six broad categories of nails; under skin but not involving other structures, into bone but does not violate dura, into brain but uncomplicated, into brain with underlying hematoma, through air sinus (frontal sinus), and through blood sinus. Key points include use of stereotactic navigation to evaluate each nail, ultrasound to evaluate for intraparenchymal hemorrhage intraoperatively, and fluoroscopy to assure all nails are removed.

Declaration of patient consent

Patient's consent not required as patient's identity is not disclosed or compromised.

Financial support and sponsorship

Nil.

Conflicts of interest

There are no conflicts of interest.

REFERENCES

1. Arici L, Akgün B, Kaplan M, Yılmaz I. Penetrating head trauma with four nails: An extremely rare case. *Ulus Travma Acil Cerrahi Derg* 2012;18:265-7.
2. Bayston R, de Louvois J, Brown EM, Johnston RA, Lees P, Pople IK. Use of antibiotics in penetrating craniocerebral injuries. "Infection in neurosurgery" working party of British society for antimicrobial chemotherapy. *Lancet* 2000;355:1813-7.
3. Carnevale JA, Morrison JF, Choi DB, Klinge PM, Cosgrove GR, Oyelese AA. Self-inflicted nail-gun injury with cranial penetration and use of intraoperative computed tomography. *Surg Neurol Int* 2016;7:S259-62.
4. Englot DJ, Laurans MS, Abbed K, Bulsara KR. Removal of nail penetrating the basilar artery. *Neurosurg Rev* 2010;33:501-4.
5. Ferraz VR, Aguiar GB, Vitorino-Araujo JL, Badke GL, Veiga JC. Management of a low-energy penetrating brain injury caused by a nail. *Case Rep Neurol Med* 2016;2016:4371367.
6. Isaacs AM, Yuh SJ, Hurlbert RJ, Mitha AP. Penetrating intracranial nail-gun injury to the middle cerebral artery: A successful primary repair. *Surg Neurol Int* 2015;6:152.
7. Min SH, Kweon C-young, Shin W. Penetrating brain injury caused by a nail gun. *Nerve* 2017;3:81-4.
8. Patchana T, Taka TM, Ghanchi H, Wiginton J 4th, Wacker M. Case report: Projectile into right frontal lobe from a nail gun. *Cureus* 2020;12:e9460.
9. Selvanathan S, Goldschlager T, McMillen J, Campbell S. Penetrating craniocerebral injuries from nail-gun use. *J Clin Neurosci* 2007;14:678-83.

10. Sim SK, Theophilus SC, Noor Azman AR. Multiple nail gun penetrating head injury: A case report. *IIUM Med J Malaysia* 2013;12:514.
11. Testerman GM, Dacks LM. Multiple self-inflicted nail gun head injury. *South Med J* 2007;100:608-10.
12. Wang AS, Zeng MH, Wang F. Successful treatment of a nail gun injury in right parietal region and superior sagittal sinus. *J Craniofac Surg* 2021;32:1297-301.
13. Ye CN, Lin MC, Huang CL. Double penetration wound: A nail gun injury involving the head and heart. *Radiol Case Rep* 2020;15:334-8.
14. Yuh SJ, Alaqeel A. Ten self-inflicted intracranial penetrating nail gun injuries. *Neurosciences (Riyadh)* 2015;20:267-70.
15. Zhu RC, Yoshida MC, Kopp M, Lin N. Treatment of a self-inflicted intracranial nail gun injury. *BMJ Case Rep* 2021;14:e237122.

How to cite this article: Zima LA, Srinivasan S, Budde B, Kitagawa R. Thirty-two nails injected into the head: An operative report and review of the literature. *Surg Neurol Int* 2022;13:377.