

**Received:** 2012.02.29  
**Accepted:** 2012.03.29  
**Published:** 2012.05.25

## Gemcitabine induced hemolytic uremic syndrome

Seyed-Ali Sadjadi<sup>1,2</sup>, Pavan Annamaraju<sup>2</sup>

<sup>1</sup> Nephrology Section, Jerry L. Pettis Memorial Veterans Medical Center, Loma Linda, CA, U.S.A

<sup>2</sup> Loma Linda University School of Medicine, Loma Linda, CA, U.S.A

### Summary

**Background:**

Gemcitabine is frequently used for the treatment of many cancers. Not infrequently it leads to development of hemolytic uremic syndrome, presenting with hemolytic anemia, acute kidney injury and occasionally peripheral edema, livedo reticularis and digital necrosis.

**Case Report:**

A 78 year old man with non-small cell lung cancer developed uremic syndrome following treatment with multiple chemotherapy agents including gemcitabine. He was treated aggressively with hemodialysis and plasmapheresis. Initially he responded but upon attempts at decreasing the frequency of plasmapheresis, lactate dehydrogenase increased and platelet count decreased, indicating continuing hemolysis. Hemolysis responded to splenectomy but he continued to require hemodialysis treatment.

**Conclusions:**

Although many cases of gemcitabine induced HUS have been reported, its cause and pathogenesis remain unclear and it should be used with caution. Frequent monitoring of renal function and close observation of the patient are essential.

**key words:**

**HUS • plasmapheresis • gemcitabine**

**Full-text PDF:**

<http://www.amjcaserep.com/fulltxt.php?ICID=882858>

**Word count:**

1164

**Tables:**

–

**Figures:**

1

**References:**

20

**Author's address:**

Seyed-Ali Sadjadi, Nephrology Section, Jerry L Pettis Memorial Veterans Medical Center, Loma Linda, CA 92357, U.S.A., e-mail: sadjadia@yahoo.com

## BACKGROUND

Gemcitabine, a fluorine substituted citarabine (2-2 difluorodeoxycytidine) is an anti-metabolite used for the treatment of a variety of malignancies including non-small cell lung cancer, pancreatic cancer, breast cancer, ovarian cancer, metastatic renal cell carcinoma [1] and mesothelioma. Side effects of the drug are multiple but the most important ones include myelotoxicity, hepatorenal toxicity, increased vascular permeability and peripheral edema. In recent years, many cases of acute renal failure, due to hemolytic uremic syndrome and attributed to gemcitabine have been described [2–4], but the cause and the treatment of the disease remain unclear. Herein we report a case of HUS following the use of gemcitabine and review the pertinent literature on the subject.

## CASE REPORT

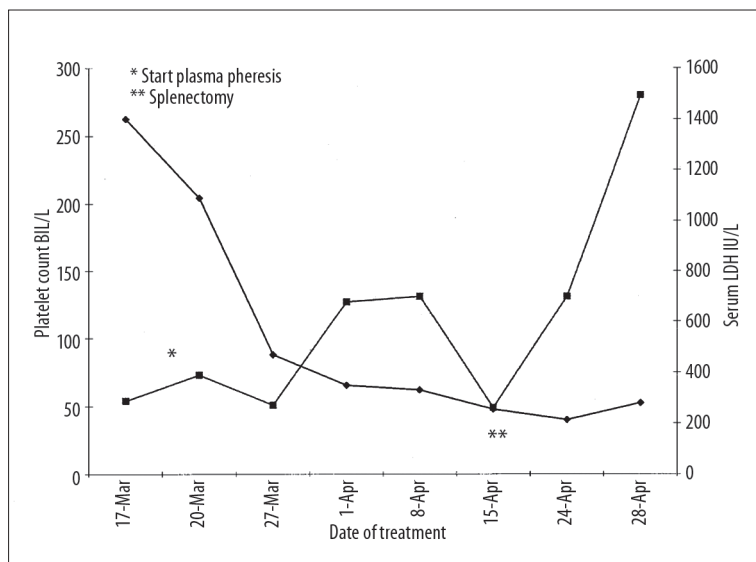
The patient was a 78 year old African American man with history of pulmonary asbestosis who was diagnosed to have non-small cell lung cancer with metastases to his spine. Due to spread of the disease to the bones, he was deemed not to be a candidate for surgery. He was initially treated with radiation therapy to his spine and later he was placed on chemotherapy, consisting of paclitaxel, 90 mg per dose  $\times$  15 doses. Due to lack of response, paclitaxel was switched to docetaxel and he received six doses, 80 mg each. Having no response, he was switched to gemcitabine and he received 17 doses, 1000 mg each over the next 8 months. Six months later, a rise in his serum creatinine and blood urea nitrogen (BUN) levels were observed. At this time, he looked cachectic, afebrile and hypertensive. Laboratory evaluation showed: White blood cell count (WBC) 32200/L, hematocrit 32.2%, platelet 91000, BUN 64 mg/dL, creatinine 4.4 mg/dL (Baseline 1.3), proteinuria >1000 mg/dL (random urine) and hematuria. Renal ultrasound showed normal size kidneys and no hydronephrosis. Suspecting acute glomerulonephritis or vasculitis, he underwent a percutaneous kidney biopsy that showed obsolescent glomeruli, thrombosis of glomerular capillaries and arterioles, consistent with the diagnosis of hemolytic uremic syndrome. Due to fluid overload and presence of uremic symptoms, hemodialysis was

initiated and simultaneously he was placed on plasmapheresis (PLEX), one volume exchange, with fresh frozen plasma replacement. Lactate dehydrogenase and platelet count were used as indicators of response to treatment. He responded to PLEX after 10 treatments, but on decreasing the frequency of PLEX, LDH rose and platelet count decreased. PLEX exchange volume was increased to 1.5 and in spite of daily treatments, on attempt to decrease the frequency of PLEX, platelet count decreased and LDH increased again (Figure 1). This was in spite of the fact that he was simultaneously on vincristine. Failing 28 PLEX treatments, he was referred for splenectomy. After splenectomy, his platelet count increased, LDH decreased and both remained stable until his death four months later. Post-splenectomy, kidney function did not improve and he remained hemodialysis dependent.

## DISCUSSION

This case illustrates an uncommon but a serious complication of gemcitabine therapy for malignancy, thrombotic microangiopathy or hemolytic uremic syndrome (HUS). HUS is the most common renal complication of gemcitabine therapy presenting with acute kidney injury, proteinuria, hematuria, thrombocytopenia, hemolytic anemia and elevated lactate dehydrogenase levels. Early recognition of this condition is often delayed as anemia and thrombocytopenia of HUS may mimic the myelotoxicity of the drug itself. Occasionally, rising reticulocyte count, livedo reticularis appearing in lower extremities or digital necrosis may be initial manifestations of HUS [5,6]. Rarely, anemia resistant to erythropoietin therapy, new onset hypertension or exacerbation of prior hypertension are clues to the presence of HUS [7]. Mean duration of time between the initiation of therapy and the onset of HUS is 7.4 months, with a median cumulative dose of 20,000 mg/m<sup>2</sup> or 21.9 doses of gemcitabine [8]. Renal failure and hemolysis frequently lead to hemodialysis and plasma exchange.

The true incidence of gemcitabine induced HUS is difficult to estimate as many cases may go unrecognized. Its incidence has been variously reported to be between 0.015 to 4% [8] and its true cause is unknown. Some authors speculate that



**Figure 1.** Platelets are depicted ( $\times$ 1000) on the left and LDH on the right side of Y axis. Days of treatment are displayed on the X axis.

a partial decrease in ADAMTS-13, caused by cancer itself or cancer drugs [9] and some suggest prolonged and repeated therapy as causative factors. Gemcitabine induced HUS has traditionally been treated with plasma exchange but there are questions about its efficacy. Our patient was treated intensely with plasmapheresis, hemodialysis and finally splenectomy. His HUS was stabilized with normal platelet counts and LDH levels, but he continued to be dialysis dependent.

Gemcitabine can also cause nausea, vomiting and sometime peripheral edema due to increased vascular permeability and capillary leak [10,11]. As such, it can cause pre-renal azotemia and in some cases hyponatremia. The latter situation should respond to expansion of intravascular volume with crystalloids. In a human study of 11 untreated patients with non-small cell lung cancer, initial gemcitabine infusion had no effect on GFR and renal plasma flow as measured by iothalamate and 131- Hippuran clearances. However with repeated infusions, 3 patients had a 10% decrease in GFR and one patient developed albuminuria and erythrocyturia [12]. Of interest, one case of MPGN type I in association with gemcitabine therapy has been reported [13].

Gemcitabine is an off-white powder with a molecular weight of 299.6 Daltons, excreted primarily by the kidneys as inactive metabolites. It has minimal protein binding and therefore it is dialyzable and therefore it should be given post-dialysis. There are no established guidelines for use of the gemcitabine in patients with chronic kidney or liver disease but it should be used with caution in these patients. Close monitoring of BUN, creatinine, platelet count and LDH is advisable when treating patient with gemcitabine.

Why gemcitabine causes HUS is unclear, but endothelial damage to glomerular capillaries and formation of thrombi may be contributing factors. HUS induced by gemcitabine is an atypical one and traditionally plasma exchange has been used to remove the possible offending agent or antibody. However, reports indicate that PLEX is not effective in all cases [14,15] and the most important therapeutic decision is to stop gemcitabine. In many cases, HUS stabilizes or subsides once gemcitabine is discontinued. Gore and et al in a review of the reported cases of gemcitabine induced HUS pointed out that 56% of 26 untreated *vs.* 30% of 18 PLEX treated patients recovered. They speculated that the difference in the rate of recovery may have been due to use of intense dialysis therapy in the PLEX untreated group. There are also reports in the literature of the use of splenectomy [16] and rituximab for the treatment of gemcitabine induced HUS that is resistant to plasmapheresis and withdrawal of gemcitabine [17,18]. Eculizumab a C5 inhibitor has been recently approved by FDA for atypical HUS, however its role in malignancy or chemotherapy induced HUS has not been defined [19,20].

## CONCLUSIONS

We have reported a case of gemcitabine induced HUS and reviewed the literature on therapeutic options and renal pharmacology of gemcitabine. A high degree of suspicion

is essential to the early diagnosis of HUS. Plasma exchange can be tried but the most important action by the treating physician is to discontinue the offending drug.

## REFERENCES:

1. Richey SL, Ng C, Lim ZD et al: Durable remission of metastatic renal cell carcinoma with gemcitabine and capecitabine after failure of targeted therapy. *J Clin Oncol*, 2011, e203-5
2. Fung MC, Storniolo AM, Nguyen B et al: A review of hemolytic uremic syndrome in patients treated with gemcitabine. *Cancer*, 1999, 85: 2023-32
3. Walter RB, Joerger MJ, Pestalozzi BC: Gemcitabine associated hemolytic uremic syndrome. *Am J Kidney Dis*, 2002; 40(4): E16
4. Flombaum CD, Mouradian JA, Gasper E et al: Thrombotic microangiopathy as a complication of long term therapy with gemcitabine. *Am J Kidney Dis*, 2002; 33: 555-62
5. Serke S, Riess H, Oettle H, Huhn D: Elevated reticulocyte count- A clue to the diagnosis of hemolytic uremic syndrome associated with gemcitabine therapy for metastatic duodenal papillary carcinoma: A case report. *Br J Cancer*, 1999; 79(9-10): 1519-21
6. Zemstov A, Omueti-Ayoade K, Zemstov R, Yang M: Livedo reticularis as initial manifestation of gemcitabine induced hemolytic uremic syndrome. *Japanese Derm Asso*, 2011; 38: 1-2
7. Assi C, Lepage C, Jouve JL, Sgro C, Bedenne L: Chronic anemia resistant to erythropoietin in a patient treated with gemcitabine showing a hemolytic uremic syndrome. *Gastroenterol Clin Biol*, 2010; 34(11): 640-42
8. Izzedine H, Bagnis CI, Launay-Vacher V et al: Gemcitabine induced thrombotic microangiopathy: A systematic review. *Nephrol Dial Transplantation*, 2008, 21: 3038-45
9. Gore EM, Jones BS, Marques BM: Is therapeutic plasma exchange indicated for patients with gemcitabine induced hemolytic uremic syndrome. *J Clin Apheresis*, 2009; 24(5): 209-14
10. Azzoli CG, Miller VA, NG KK et al: Gemcitabine induced peripheral edema: Report on 15 cases and review of the literature. *Am J Clin Oncol*, 2003; 26(3): 247-51
11. Biswas S, Nki S, Corrie PG: Severe gemcitabine induced capillary leak syndrome mimicking cardiac failure in a patient with advanced pancreatic cancer and high risk cardiovascular disease. *Clin Oncol*, 2004; 16(8): 577-79
12. Gietama JA, Groen HJ, Meijer S, Smit EF: Effects of gemcitabine on renal function in patients with non-small cell lung cancer. *Eur J Cancer*, 1998; 34(1): 199-202
13. Fracasso PM, Tan BR, Grief M et al: Membranoproliferative glomerulonephritis following gemcitabine and vinorelbine chemotherapy for peritoneal mesothelioma. *J Nat Cancer Inst*, 1999; 91(20): 1779-80
14. Barz D, Budde U, Hellstern P: Therapeutic plasma exchange and plasma infusion in thrombotic microvascular syndromes. *Thromb Res*, 2002; 31: 107
15. McGaleb Gore E, Jones BS, Marques MB: Is therapeutic plasma exchange indicated for patients with gemcitabine induced hemolytic uremic syndrome. *J Clin Apheresis*, 2009; 24(5): 209-14
16. Zomas A, Gigantes S, Vasiloglou G et al: Early therapeutic splenectomy may reduce morbidity and management costs in selected resistant or relapsing cases of TTP/HUS. *J Thrombosis and Hemostasis*, 2003; 1(Suppl.1): abstract PO 326
17. Bharthuar A, Egloof L, Becker J et al: Rituximab based therapy for gemcitabine induced hemolytic uremic syndrome in a patient with metastatic pancreatic adenocarcinoma: A case report. *Cancer Chemother Pharmacol*, 2009; 64(1): 177-81
18. Gourley BL, Mesa H, Gupta P: Rapid and complete resolution of chemotherapy induced thrombotic thrombocytopenic purpura/hemolytic uremic syndrome with rituximab. *Cancer Chemother Pharmacol*, 2010; 65(5): 1001-4
19. Schrezenmeier H, Hochsmann B: Drugs that inhibit complement. *Transfus Apher Sci*, 2012; 46(1): 87-92
20. Weitz M, Amon O, Brassler D, Koenigsrainer A, Nadalin S: Prophylactic eculizumab prior to kidney transplantation for atypical hemolytic uremic syndrome. *Pediatr Nephrol*, 2011; 26(8): 1325-29