


CLINICAL ARTICLE

Comparing the Bridge-Type Zero-Profile Anchored Spacer (ROI-C) Interbody Fusion Cage System and Anterior Cervical Discectomy and Fusion (ACDF) with Plating and Cage System in Cervical Spondylotic Myelopathy

Shuangjun He, MD¹, Zhangzhe Zhou, MD², Xiaofeng Shao, MM², Lijian Zhou, MM¹, Changhao Zhang, MM², Xinfeng Zhou, MD², Shuhua Wu, MM¹, Kangwu Chen, MD², Yaowei Wang, MM¹, Zhonglai Qian, MD² 

¹Department of Orthopedic Surgery, The People's Hospital of Danyang, Affiliated Danyang Hospital of Nantong University, Danyang and

²Department of Orthopedic Surgery, The First Affiliated Hospital of Soochow University, Suzhou, China

Objective: To compare the clinical efficacy and radioactivity of the bridge-type zero-profile anchored spacer (ROI-C) interbody fusion cage and anterior cervical discectomy and fusion with plating and cage system (ACDF) for cervical spondylotic myelopathy (CSM).

Methods: This is a retrospective contrastive study. We recruited 35 patients who received ROI-C (ROI-C group) and 34 patients who received ACDF (ACDF group), between January 2014 to January 2019, at our treatment center. The ROI-C group comprised of 11 males and 24 females with a mean age of 61.59 ± 8.21 years (range, 51–71 years). The ACDF group comprised of 12 males and 22 females with a mean age of 60.15 ± 7.52 years (range, 52–74 years). Neck Disability Index (NDI), Japanese Orthopaedic Association score (JOA), Odom's score, cervical Cobb angle, fusion rate, adjoining ossification, and dysphagia.

Results: A total of 69 patients met the inclusion criteria, and these patients received more than two years of follow-up. There were significant differences in surgical duration (101 ± 22 min vs. 118 ± 29 min) and blood loss (102 ± 46 ml vs. 145 ± 58 ml) between two groups ($P < 0.05$). The JOA and NDI of these two groups of patients significantly improved, when compared with those before the operation ($P < 0.05$). Twenty-nine of 35 patients in the ROI-C group and 27 of 34 patients in ACDF group achieved good or excellent outcomes according to Odom's criteria. The cervical lordosis of both two groups significantly increased, when compared with those before the operation ($P < 0.05$). In the ROI-C group, the postoperative fusion rate was 85.7% at the 3-month follow-up and 100% at the final follow-up. In the ACDF group, the postoperative fusion rate was 82.4% at the 3-month follow-up and 100% at the final follow-up. The dysphagia incidence of the ACDF group was higher than that of the ROI-C group postoperatively and at the one month after surgery ($P < 0.05$), but no significant difference was found in the incidence of dysphagia at final follow-up ($P > 0.05$).

Conclusion: Both ROI-C and ACDF achieved good therapeutic effects. However, ROI-C can reduce the operation time and postoperative complications.

Key words: Cervical myelopathy; Cervical vertebra; Complications; Decompression; Degenerative disc disease

Address for correspondence Kangwu Chen and Zhonglai Qian, Department of Orthopedic Surgery, The First Affiliated Hospital of Soochow University, 188 Shizi Street, Suzhou, Jiangsu 215006, China. Email: chenkangwu@suda.edu.cn and qzldoctor@163.com

Yaowei Wang, Department of Orthopedics, The People's Hospital of Danyang, Affiliated Danyang Hospital of Nantong University, Xinmin Road 2, Danyang, 212300, China. Email: jsdywyw@163.com

Shuangjun He, Zhou Zhangzhe, Xiaofeng Shao and Lijian Zhou contributed equally to the article.

Received 16 March 2021; accepted 21 March 2022

Introduction

Cervical spondylotic myelopathy (CSM) is the most common progressive degenerative disease of the spine among the geriatric population.^{1,2} Cervical spondylosis generally begins with degenerative alterations in the disk space causing secondary changes in the surrounding soft tissue and bony structures, which leads to progressive narrowing of the spinal canal, followed by subsequent compression of the dural sac, resulting in neurologic symptoms like hypaesthesia and muscle weakness.³ Common conservative treatment methods include drug therapy, neck brace protection and traction therapy. However, these treatments are not effective for severe CSM, which can lead to spinal cord dysfunction and significantly reduce patients' quality of life.⁴ A previous study prospectively evaluated 62 patients with cervical myelopathy over one year.⁵ It revealed that patients who received surgery showed improvement in pain and functional status, whereas conservatively managed patients performed fewer daily activities and had progressive worsening of the neurological symptoms. Therefore, surgery remains the mainstay of treatment in patients with severe CSM.

Fortunately, massive advancements in medical technology and expertise have produced diverse surgical interventions for CSM. Preservation or improvement of neurologic function, correction of sagittal or coronal deformity, and maintaining cervical spine stability are the main aims of surgical intervention. Anterior cervical surgery is increasingly used due to its high efficacy, minimal trauma, and rapid recovery, especially in only 1 or 2 vertebral body levels.^{6,7} The bridge-type zero-profile anchored spacer (ROI-C) interbody fusion cage cervical cage is a novel interbody fusion cage that involves a polyether rather ketone box and two self-locking clips, which has gained success in numerous clinical applications. The design of this cage offers a firm biomechanical medium while avoiding contact between the implant and the anterior vertebral soft tissue. In most cases, an anterior plate (AP) is introduced with ACDF to increase stability. AP fixation was shown to stimulate bone fusion, lower risk of implant dislodges, preserve the physiological curvature of cervical spine, and maintain intervertebral space (IVS) height. Despite its many advantages, however, there are a few drawbacks to AP usage, namely, increased risks of soft tissue injury, dysphagia (DPh), fracture, internal fixation failure, etc. Fortunately, several studies reported that AP fixation can be replaced with interbody fusion cage (IFC) to reduce post-surgical complications, while enabling fixation stability and excellent bone graft fusion.^{8,9}

In the past, scholars have evaluated the efficacy and safety of the ROI-C and ACDF operation methods.¹⁰ Under the premise that these two surgical methods achieve the same curative effect, it remains controversial to determine which surgical method can more effectively reduce the occurrence of related complications. In this study, we retrospectively analyzed 69 CSM patients who received surgery with either ROI-C or ACDF. Our goal in this study was to compare the advantages and disadvantages of using these

systems in the treatment of CSM. The present study aims: (i) to assess the intraoperative indexes of both operations; and (ii) to evaluate the postoperative scores and complications of both operations.

Materials and Methods

Inclusion and Exclusion Criteria

Inclusion Criteria

Patients include in the study: (i) patients had cervical spondylotic myelopathy; and (ii) underwent ROI-C or ACDF.

Exclusion Criteria

The exclusion criteria were: (i) prior cervical surgery, tumor, or any serious disease; (ii) developmental stenosis and ossification of the posterior longitudinal ligament; and (iii) severe cervical instability or cervical fracture dislocation.

Patients

The study was approved by the Ethics Committee of the First Affiliated Hospital of Soochow University (No. 206). Between January 1, 2014 and January 1, 2019. Thirty-five patients were recruited as the ROI-C cohort (ROI-C group). Among them, 11 were males and 24 were females, with a mean age of 61.59 ± 8.21 years old (range, 51–71 years). Simultaneously, we selected 34 patients for the ACDF group (ACDF group). Among them, 12 were males and 22 were females, with a mean age of 60.15 ± 7.52 years old (range, 52–74 years).

Surgical Procedures

Anesthesia and Position

All surgeries were conducted by a highly experienced surgeon. In brief, the patients were provided with general anesthesia. All the patients were placed in the supine position with their shoulders raised to realize the hyperextension of the cervical vertebra.

The Zero-Profile Anchored Spacer (ROI-C) Group

After general anesthesia, with the patient placed in the supine position, extensive decompression was performed, including the removal of osteophytes, herniated discs and posterior longitudinal ligament as indicated to achieve sufficient decompression of the spinal cords and nerve roots. The cartilage endplates were abraded carefully, and the bony endplates were preserved to prevent possible subsidence. Following complete decompression, two intervertebral fusion cages (ROI-C, LDR, Troyes, France) of appropriate sizes were selected. The whole fusion cages were filled with subtracted osteophyte and bone induction, and then the ROI-C cages were placed into the whole intervertebral space to 2 mm from the front edge of the vertebral body. Once the fluoroscopy position was satisfactory, Caspar intervertebral

braces were slowly loosened and the impactors were used to drive the fixed insert into the upper and lower vertebral bodies along the lying groove for fixation.

The Anterior Cervical Discectomy and Fusion (ACDF) Group

Following complete decompression, the appropriate intervertebral fusion cages were selected according to the size of the patient's intervertebral space. The intervertebral fusion cages were filled with decompressed osteophyte and bone induction material, prior to placement into the whole intervertebral space. The dynamic compression titanium plate, with appropriate size and length (Medtronic, Minneapolis, MN, USA), was, then, fixed in the adjacent upper and lower vertebrae.

Outcome Measures

Japan Orthopaedic Association Scores

The Japan Orthopaedic Association (JOA) scores¹¹ were used to assess the severity of clinical symptoms, JOA scores consist of six categories: motor dysfunction of the upper extremities, motor dysfunction in the lower extremities, sensory function in the upper extremities,

sensory function in the trunk, sensory function in the lower extremities, and bladder function.

Neck Disability Index

Neck disability index (NDI)¹² is a self-rated disability questionnaire developed for patients with neck pain. It consists of 10 items: personal care, pain intensity, lifting, headaches, reading, concentration, sleeping, driving, work, and leisure activities. Each item is scored from 0–5, no disability to total disability, with the maximum score being 50.

Odom's Score

The effect of operation was determined by Odom's score,¹³ and the grades were as follows: (i) excellent, symptoms and signs disappeared after operation; (ii) good, most symptoms and signs were relieved, and normal function was restored; (iii) general, symptoms and signs were partially improved, but the person could not move normally; and (iv) poor, symptoms and signs were basically the same as before the operation.

Bazaz Score

According to the Bazaz score,¹⁴ the degree of dysphagia was divided into four grades, as follows: (i) none, no dysphagia;

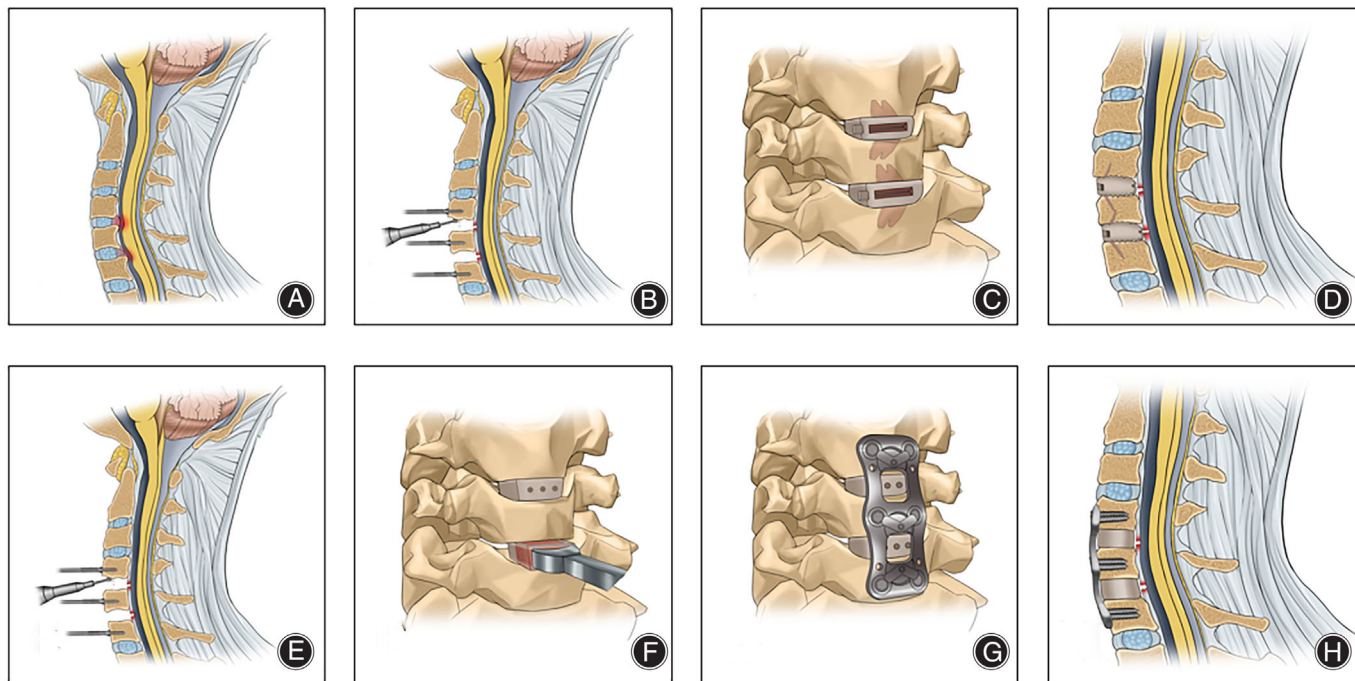


Fig. 1 Schematic diagrams of the surgical procedure for the two operations: The ROI-C operation process (A–D) and the ACDF operation process (E–H). (A) The cervical disc herniation compressing the spinal cord. (B) The removal of the herniated intervertebral discs and posterior longitudinal ligament. (C) The installation of the ROI-C interbody fusion cages. (D) A schematic diagram of the ROI-C after operation. (E) The removal of the herniated intervertebral discs and posterior longitudinal ligament. (F) The installation of interbody fusion cages. (G) The installation of cervical spine front titanium plate. (H) A schematic diagram of ACDF after operation

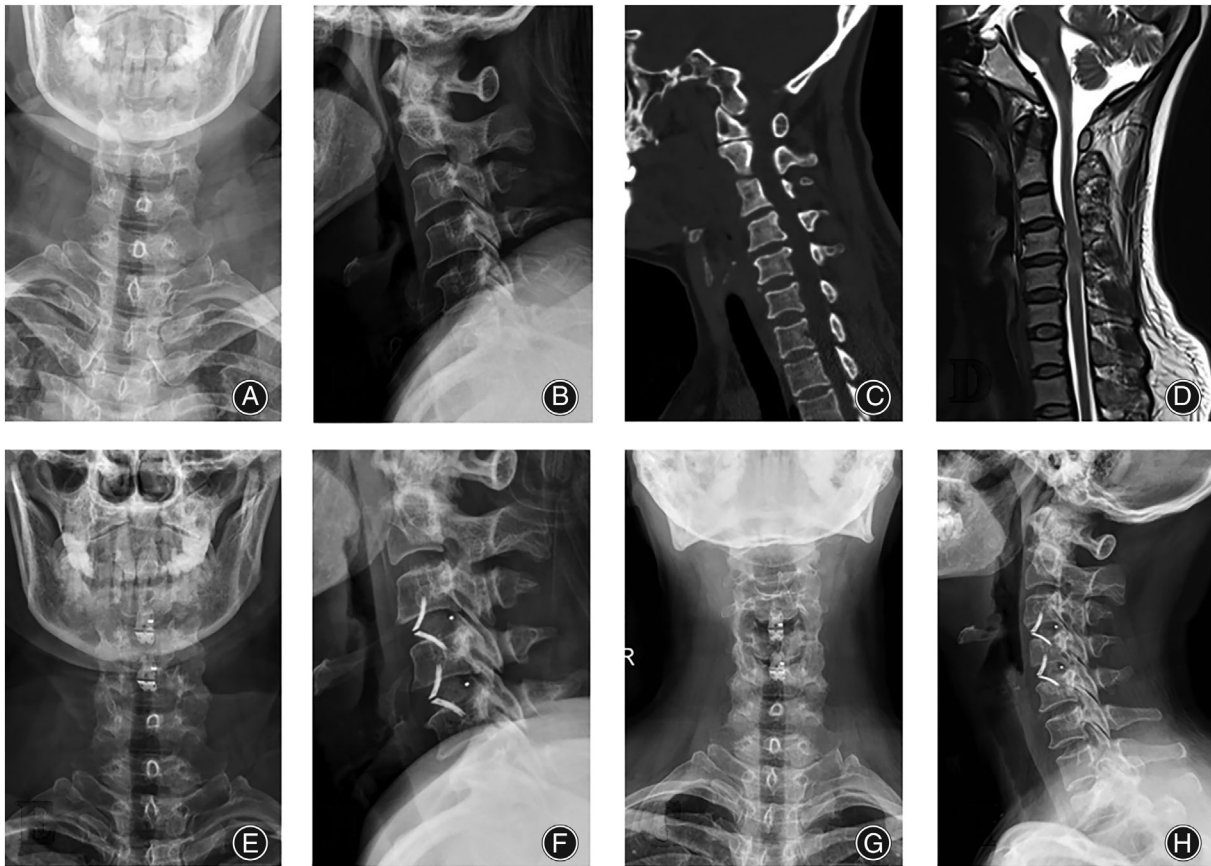


Fig. 2 A case involving a 65-year-old woman. She was enrolled in the ROI-C group: (A, B) Preoperative X-ray illustrating the disappearance of the cervical vertebrae radian; (C) Preoperative CT depicting cervical degeneration, loss of physiological radian, and hyperosteoegeny; (D) Preoperative MRI indicating C₃-C₄ and C₄-C₅ cervical disc herniation. (E, F) Day 3 postoperation X-ray revealing C₃-C₄ and C₄-C₅ cervical discectomy, and the good placement of the bridge-type ROI-C interbody fusion cages; (G, H) Year 2 postoperation X-ray illustrating the C₃-C₄ and C₄-C₅ cervical fusion, and the good position of the bridge-type ROI-C interbody fusion cages

(ii) mild, almost no dysphagia; (iii) moderate, occasional dysphagia; and (iv) severe, severe dysphagia.

Cervical Lordosis

The Cobb angle was measured in the sagittal position of the cervical spine, which formed between the perpendicular line of the inferior end plate of the C₂ and C₇ vertebral bodies.

Fusion Rate and Adjacent Level Ossification

Post operation, the following conditions were used to determine whether radiologic fusion has taken place: (i) adjacent vertebral displacement <2° in extension and flexion of neck; (ii) unaltered intervertebral space (IVS) height; and (iii) absence of a transparent line between the grafted bone and the top and bottom vertebral endplates. The adjacent level ossification development was evaluated.

Statistical Analyses

All data were collected and analyzed using IBM SPSS Statistics v.19.0 (IBM, Chicago, IL, USA). All results are presented as mean ± standard deviation. The Student's *t*-test was used for numerical data, including age, operation time, blood loss, JOA score, NDI score, and cervical lordosis angle. The Pearson's chi-square test and the Fisher's exact test were used for categorical data, including Odom criteria, adjacent level ossification, fusion rate, and incidence of dysphagia. *P* < 0.05 was considered statistically significantly.

Results

General Results

Among the 69 participants selected for the study, 35 were placed in the ROI-C group who received ROI-C (Figs 1-3) and 34 were in the ACDF group who received ACDF (Figs 1 and 4). The ROI-C group (*n*=35) consisted of 24 women and 11 men with a mean age of 61.59 ± 8.21 years.

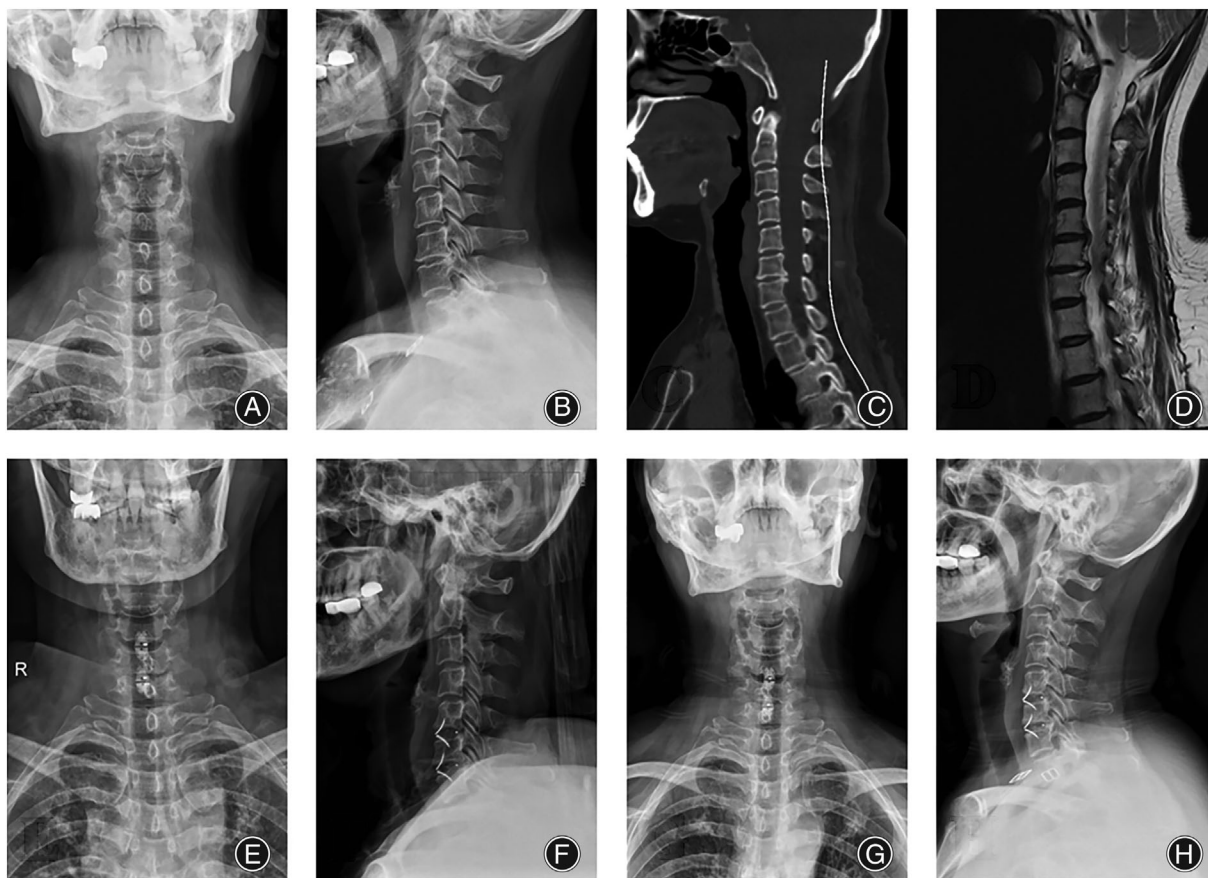


Fig. 3 A case involving a 62-year-old woman. She was enrolled in the ROI-C group: (A, B) Preoperative X-ray illustrating the disappearance of the cervical vertebrae radian; (C) Preoperative CT depicting cervical degeneration, loss of physiological radian, and hyperosteoegeny; (D) Preoperative MRI indicating C₅-C₆ and C₆-C₇ cervical disc herniation. (E, F) Day 3 post operation X-ray revealing the C₅-C₆ and C₆-C₇ cervical discectomy, and the good placement of the bridge-type ROI-C interbody fusion cages; (G, H) Year 2 post operation X-ray depicting the C₅-C₆ and C₆-C₇ cervical fusion, and good positioning of the bridge-type ROI-C interbody fusion cages

The mean follow-up in the ROI-C group was 26.6 ± 3.4 months. The operative segments were C₃-C₅ ($n = 5$), C₄-C₆ ($n = 21$) and C₅-C₇ ($n = 9$). The ACDF group ($n = 34$) consisted of 22 women and 12 men with a mean age of 60.15 ± 7.52 years. The mean follow-up in the ACDF group was 27.1 ± 3.8 months. The operative segments were C₃-C₅ ($n = 4$), C₄-C₆ ($n = 19$) and C₅-C₇ ($n = 11$). The basic demographic data are presented in Table 1.

The operation time of ROI-C group and ACDF group was 101 ± 22 min and 118 ± 29 min, and the blood loss of both groups was 102 ± 46 ml and 145 ± 58 ml, respectively. There were significant differences in surgical duration and blood loss between two groups ($P < 0.05$). The results are presented in Table 1.

Surgical Outcomes

Japan Orthopaedic Association Scores

In the ROI-C group, the JOA score increased from 9.4 ± 1.7 prior to operation to 13.6 ± 2.2 after the

operation ($P < 0.05$), and was 14.8 ± 1.6 at the final follow-up. In the ACDF group, the JOA score improved from 9.8 ± 1.5 prior to operation to 14.2 ± 1.6 after the operation ($P < 0.05$), and remained at 14.9 ± 1.7 in the subsequent follow-ups. However, there were no significant differences in JOA score between both groups preoperatively and at the two postoperative follow-ups ($P > 0.05$) (Table 2).

Neck Disability Index

In the ROI-C group, the NDI score reduced from 31.1 ± 7.9 prior to operation to 15.9 ± 4.7 ($P < 0.05$) after the operation and remained at 13.4 ± 4.6 . In the ACDF group, the NDI score reduced from 30.5 ± 7.6 prior to operation to 15.1 ± 4.9 ($P < 0.05$) after the operation and remained at 13.1 ± 4.3 . There were no significant differences in NDI score between two groups preoperatively and at the two postoperative follow-ups ($P > 0.05$) (Table 2).

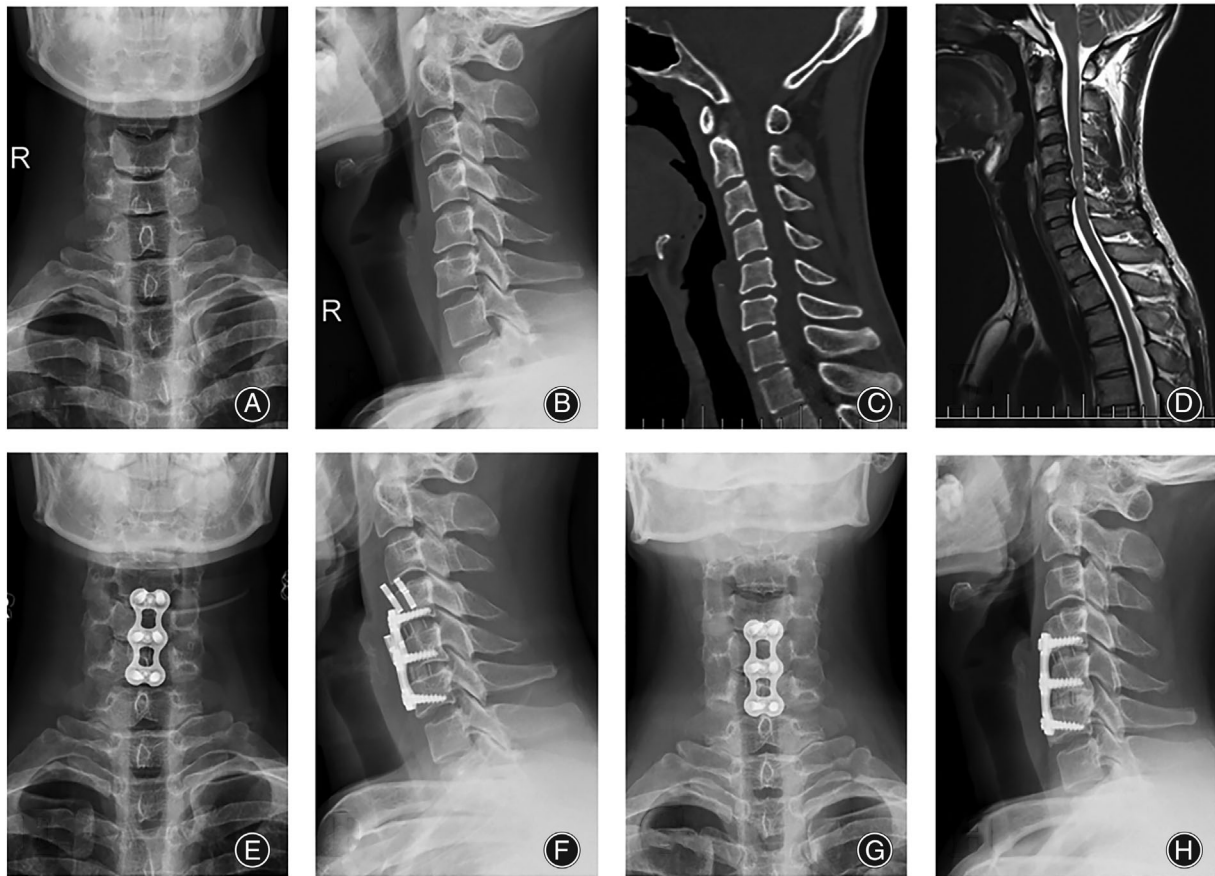


Fig. 4 A case involving a 67-year-old man. He was enrolled in the ACDF group. (A, B) Preoperative X-ray illustrating the disappearance of the cervical vertebrae radian; (C) Preoperative CT scan depicting the disappearance of cervical vertebrae radian, and alteration in the intervertebral space; (D) Preoperative MRI depicting the C₄-C₅ and C₅-C₆ cervical disc herniation. (E, F) Day 3 post operation X-ray revealing the C₄-C₅ and C₅-C₆ cervical discectomy, and good positioning of the cages and plate; (G, H) Year 2 post operation X-ray demonstrating the C₄-C₅ and C₅-C₆ cervical fusion, and good placement of the cages and plate

TABLE 1 General information

| | ROI-C | ACDF | P value |
|--------------------------------|--------------|--------------|---------|
| Number | 35 | 34 | |
| Gender | | | |
| Male | 11 | 12 | |
| Female | 24 | 22 | |
| Age (year) | 61.59 ± 8.21 | 60.15 ± 7.52 | 0.451 |
| Level | | | |
| C ₃ -C ₅ | 5 | 4 | |
| C ₄ -C ₆ | 21 | 19 | |
| C ₅ -C ₇ | 9 | 11 | |
| Follow-up (months) | 26.6 ± 3.4 | 27.1 ± 3.8 | 0.566 |
| Operation time (minute) | 101 ± 22 | 118 ± 29 | 0.008 |
| Blood loss (ml) | 102 ± 46 | 145 ± 58 | 0.001 |

Abbreviation: ACDF, Anterior Cervical Discectomy and Fusion.; P value is given for comparison between ROI-C and ACDF groups.; $P < 0.05$, statistically significant.

TABLE 2 Clinical outcomes of two groups

| | ROI-C | ACDF | P value |
|-----------------------|-------------------------|-------------------------|---------|
| JOA scores | | | |
| Preoperative | 9.4 ± 1.7 ^a | 9.8 ± 1.5 ^a | 0.304 |
| Postoperative 1 month | 13.6 ± 2.2 ^b | 14.2 ± 1.6 ^b | 0.191 |
| Last follow-up | 14.8 ± 1.6 ^b | 14.9 ± 1.7 ^b | 0.802 |
| NDI scores | | | |
| Preoperative | 31.1 ± 7.9 ^a | 30.5 ± 7.6 ^a | 0.749 |
| Postoperative 1 month | 15.9 ± 4.7 ^b | 15.1 ± 4.9 ^b | 0.491 |
| Last follow-up | 13.4 ± 4.6 ^b | 13.1 ± 4.3 ^b | 0.781 |
| Odom criteria | | | |
| Excellent | 10 (28.6%) | 9 (26.4%) | 0.714 |
| Good | 19 (54.3%) | 18 (53.0%) | |
| Fair | 6 (17.1%) | 7 (20.6%) | |
| Poor | 0 | 0 | |

Abbreviations: JOA Japanese Orthopaedic Association, NDI Neck Disability Index; ^aP < 0.05 comparing with preoperative value.; ^bP value is given for comparison between ROI-C and ACDF group.

TABLE 3 The mean outcomes of radiological parameters measured before operation and during follow-up(mean ± SD)

| | ROI-C | ACDF | P value |
|-----------------------------|-------------------------|-------------------------|---------|
| Cervical lordosis | | | |
| Preoperative | 13.6 ± 9.3 ^a | 12.2 ± 9.4 ^a | 0.536 |
| Postoperative 1 month | 18.2 ± 9.4 ^b | 17.3 ± 8.4 ^b | 0.677 |
| Last follow-up | 17.9 ± 8.8 ^b | 17.1 ± 9.6 ^b | 0.719 |
| Fusion rate | | | |
| Postoperative 3 month | 85.7% (30/35) | 82.4% (28/34) | 0.703 |
| Final fusion | 100% | 100% | |
| Adjacent level ossification | 25.7% (9/35) | 29.4% (10/34) | 0.731 |

^aP value is given for comparison between ROI-C and ACDF group.; ^bP < 0.05 comparing with preoperative value.

TABLE 4 Incidence of dysphagia

| | ROI-C | ACDF | P value |
|---------------------------|--------------|---------------|---------|
| Dysphagia | 17.1% (6/35) | 44.1% (15/34) | 0.015 |
| One month postoperatively | 2.9% (1/35) | 20.6% (7/34) | 0.021 |
| Final follow-up | 0% (0/35) | 2.9% (1/34) | 0.307 |

P value is given for comparison between ROI-C and ACDF groups; P < 0.05, statistically significant

Odom's Criteria

There were 82.9% of patients in the ROI-C group and 79.4% of the patients in the ACDF group that achieved a good or excellent outcome, and no significant difference was observed between the two groups (Table 2).

Cervical Lordosis

The ROI-C group exhibited a cobb angle increase from 13.6 ± 9.3 prior to operation to 18.2 ± 9.4 after surgery and it was at 17.9 ± 8.8 at the subsequent ACDF group

(P < 0.05). The ACDF group exhibited a cobb angle increase from 12.2 ± 9.4 prior to operation to 17.3 ± 8.4 after surgery and it was at 17.1 ± 9.6 at the subsequent ACDF group (P < 0.05). There were no significant differences in cervical lordosis angle between the two groups preoperatively and at the two postoperative ACDF group (P > 0.05) (Table 3).

Fusion Rate and Adjacent Level Ossification

In the ROI-C group, the postoperative fusion rate was 85.7% at the 3-month follow-up and 100% at the last follow-up.

Finally, the adjacent level ossification was at 25.7%. In the ACDF group, the postoperative fusion rate was 82.4% at the 3-month follow-up and 100% at the last follow-up. Finally, the adjacent level ossification was at 29.4%. No significant differences were observed in cervical lordosis angle between the two groups at the two postoperative follow-ups ($P > 0.05$) (Table 3).

Complications

In the ROI-C group, 17.1% (6/35) patients experienced the postoperative dysphagia. Five patients of them alleviated at one month after surgery. No one experienced the postoperative dysphagia at the final follow-up. The rate of adjacent level ossification was 25.7% (9/35) at last follow-up. In the ACDF group, 44.1% (15/34) patients experienced the postoperative dysphagia. Eight patients alleviated at one month after surgery. However, there still one patient experienced the postoperative dysphagia at the final follow-up. The rate of adjacent level ossification was 29.4% (10/34) at final follow-up. In addition, there was significant difference in the incidence of dysphagia between two groups postoperatively and at one month after surgery ($P < 0.05$). However, no significant difference was found in the incidence of dysphagia and the rate of adjacent level ossification at final follow-up ($P > 0.05$) (Table 4).

Discussion

The advantage of surgical treatment lies in optimal preservation of the physiological radius of the cervical vertebra, enhanced intervertebral fusion rate, and maintenance of spinal stability.^{15,16} In this study, both types of surgeries achieved a marked increase in the postoperative cervical Cobb angle, compared to before the operation. This suggests that both surgical types can effectively correct CSM. Hence, the fusion and biomechanical stability of ROI-C are comparable to that of ACDF.¹⁷ Moreover, the JOA and NDI scores were greatly enhanced after both operations, and the improved state remained throughout the length of this study, thus confirming the efficacy of both procedures. Furthermore, ACDF outcome is highly dependent on the level of decompression, Cobb angle restoration, and fusion stability. AP fixation is commonly employed with ACDF to accelerate interbody fusion and enhance cage stability. Bone fusion is essential for the effective prevention of kyphosis and spinal canal stenosis, which ultimately reduce spinal cord.¹⁸ Multiple studies have evidenced the success of ROI-C usage in surgeries. Wang *et al.*¹⁹ and Grasso *et al.*²⁰ demonstrated a fusion rate of 100% in patients receiving ROI-C, who were monitored for the next 2 years. Similarly, Hofstetter *et al.*¹⁶ revealed a fusion rate of 95.2% with ROI-C after a mean follow-up of 13.9 months. Moreover, based on the results from this study, both patients receiving ROI-C and ACDF achieved satisfactory bone fusion, with no discernible difference between them.

Compared to the ACDF, however, the ROI-C had certain advantages. First, the operative wound was relatively

small and induced reduced bleeding. Moreover, despite requiring comparable skin incision, the ROI-C procedure did not require plate fixation and exposure of the adjoining vertebrae. Instead, only the target IVS was exposed. Second, the surgical duration was short due to the simplicity of the procedure. Moreover, the direct fixation of the cage *via* self-locking clips saved critical operative time and was as effective as the relatively longer ACDF procedure. Third, patients undergoing ROI-C experienced less postoperative DPh, compared to patient receiving ACDF. DPh is commonly observed post ACDF, however, the related mechanisms are not fully understood.^{21,22} Among the multiple factors regulating DPh after surgery are the following: first, the pharyngeal and tracheal stimulation during anesthesia may cause DPh. Based on multiple reports, postoperative atomization can partially alleviate dysphagic symptoms and the recovery period can last about 1 month. Second, soft tissue adhesion after surgery may induce DPh. It is imperative to strip the soft tissue covering the vertebral body in order to expose the target location during surgery. In the ROI-C group, only the IVS was exposed to carry out the procedure. However, in the ACDF group, the plate was fixed in front of the vertebral body, which resulted in greater exposure and increased bleeding, thereby elevating risk of postoperative adhesion. Third, studies show that anterior cervical plate usage increases dysphagic risk.²³ Unfortunately, following plate fixation, the plate can protrude from the surface of cervical body and lightly compress the esophagus.^{24,25} Several studies suggest that employing a thinner plate fixation can lower dysphagic risk.²⁶ Moreover, using zero-profile anchored spacer can also markedly lower dysphagic cases.²⁷ Here, we observed that the unique design of ROI-C enabled it to be completely implanted within the IVS, hence avoiding esophageal compression. As a result, we showed that the ROI-C group experienced remarkably lower incidences of DPh, compared to the ACDF group. In fact, the difference was significant both at the 1- and 3-month ACDF group. Taken together, these data suggest that ROI-C can lower incidences of early DPh.

Adjacent level ossification is one of the manifestations of degenerative tissue surrounding the affected vertebrae. Clinical pathology of adjacent segments, which represents radiculopathological or myelopathological development arising from the movements of segments next to the fused location, is a more serious problem compared to the radiographically apparent pathology of adjoining segments. This is due to the natural degeneration of the adjoining joints and the increased activities of the top and bottom joints induced by the aberrant fusion.²⁸ Lee *et al.*²⁹ proposed the use of short plates with oblique screw tracks to dramatically decrease the risk and severity of adjacent level ossification, likely due to the maintenance of soft tissue separation in front of the vertebrae.^{30,31} In our study, ROI-C group had nine cases of adjacent level ossification, whereas ACDF group had ten cases. However, by the last follow-up none of the patients required surgery. We plan to further examine

and assess the relationship between ROI-C, adjacent level ossification, and the need for additional surgery in future studies.

Limitations

Our work had certain limitations. First, our study was retrospective in nature, with restricted evidence level. Second, there could be unintentional measurement errors. To circumvent this, we employed three experienced orthopedic surgeons to individually measure the X-ray parameters. Finally, our sample size was small, with relatively short follow-up duration. This may have introduced unintentional selection bias. To curb these limitations, we propose the need of extensive randomized prospective investigations, involving large patient population and long-term ACDF group, to validate our conclusions.

Conclusion

Both ROI-C and ACDF can effectively correct CSM. However, ROI-C can reduce operation time, intraoperative bleeding, and the risk of short-term dysphagia.

Funding information

This work was supported by the National Nature Science Foundation of China (grant no. 81802682) and the Natural Science Foundation of Jiangsu Province (grant no. BK20180199). This work was supported by the Zhenjiang City Social Development Fund (grant no. 2019049) and the Danyang City Social Development Fund (grant no. SSF202110 and SSF202116).

Acknowledgements

Thanks to the support from the First Affiliated Hospital of Soochow University.

References

- Boogaarts HD, Bartels RH. Prevalence of cervical spondylotic myelopathy. *Eur Spine J*. 2015;24(Suppl 2):139–41.
- Fountas KN, Kapsalaki EZ, Nikolakakos LG, et al. Anterior cervical discectomy and fusion associated complications. *Spine*. 2007;32(21):2310–7.
- Rong Y, Luo Y, Liu W, Gong F, Tang P, Cai W. Clinical effects of the bridge-type ROI-C interbody fusion cage system in the treatment of cervical spondylosis with osteoporosis. *Clin Interv Aging*. 2018;13:2543–51.
- Matsunaga S, Komiya S, Toyama Y. Risk factors for development of myelopathy in patients with cervical spondylotic cord compression. *Eur Spine J*. 2015;24(Suppl 2):142–9.
- Sampath P, Bendebba M, Davis JD, Ducker TB. Outcome of patients treated for cervical myelopathy. A prospective, multicenter study with independent clinical review. *Spine*. 2000;25(6):670–6.
- De la Garza-Ramos R, Xu R, Ramhmdani S, et al. Long-term clinical outcomes following 3- and 4-level anterior cervical discectomy and fusion. *J Neurosurg Spine*. 2016;24(6):885–91.
- Epstein NE, Hollingsworth R. Diagnosis and management of traumatic cervical central spinal cord injury: a review. *Surg Neurol Int*. 2015;6(Suppl 4):S140–53.
- Arnold PM, Anderson KK, Selim A, Dryer RF, Kenneth BJ. Heterotopic ossification following single-level anterior cervical discectomy and fusion: results from the prospective, multicenter, historically controlled trial comparing allograft to an optimized dose of rhBMP-2. *J Neurosurg Spine*. 2016;25(3):292–302.
- Pandey PK, Pawar I, Gupta J, Verma RR. Comparison of outcomes of single-level anterior cervical discectomy with fusion and single-level artificial cervical disc replacement for single-level cervical degenerative disc disease. *Spine*. 2017;42(1):E41–9.
- Zhang J, Liu H, Bou EH, et al. Comparative study between anterior cervical discectomy and fusion with ROI-C cage and Laminoplasty for multilevel cervical Spondylotic myelopathy without spinal stenosis. *World Neurosurg*. 2019;121:e917–24.
- Yonenobu K, Abumi K, Nagata K, Taketomi E, Ueyama K. Interobserver and intraobserver reliability of the Japanese orthopaedic association scoring system for evaluation of cervical compression myelopathy. *Spine*. 2001;26(17):1890–4. discussion 5.
- Vernon H, Mior S. The neck disability index: a study of reliability and validity. *J Manipulative Physiol Ther*. 1991;14(7):409–15.
- Odom GL, Finney W, Woodhall B. Cervical disk lesions. *JAMA*. 1958;166(1):23–8.
- Bazaz R, Lee MJ, Yoo JU. Incidence of dysphagia after anterior cervical spine surgery: a prospective study. *Spine*. 2002;27(22):2453–8.
- Li J, Zheng Q, Guo X, et al. Anterior surgical options for the treatment of cervical spondylotic myelopathy in a long-term follow-up study. *Arch Orthop Trauma Surg*. 2013;133(6):745–51.
- Hofstetter CP, Kesavabhotla K, Boockvar JA. Zero-profile anchored spacer reduces rate of dysphagia compared with ACDF with anterior plating. *J Spinal Disord Tech*. 2015;28(5):E284–90.
- Bucci MN, Oh D, Cowan RS, et al. The ROI-C zero-profile anchored spacer for anterior cervical discectomy and fusion: biomechanical profile and clinical outcomes. *Med Devices (Auckl)*. 2017;10:61–9.
- Kaiser MG, Haid RW Jr, Subach BR, Barnes B, Rodts GE Jr. Anterior cervical plating enhances arthrodesis after discectomy and fusion with cortical allograft. *Neurosurgery*. 2002;50(2):229–36. discussion 36–38, 238.
- Wang Z, Jiang W, Li X, et al. The application of zero-profile anchored spacer in anterior cervical discectomy and fusion. *Eur Spine J*. 2015;24(1):148–54.
- Grasso G, Giambardino F, Tomasello G, Iacopino G. Anterior cervical discectomy and fusion with ROI-C peek cage: cervical alignment and patient outcomes. *Eur Spine J*. 2014;23(Suppl 6):650–7.
- Nguyen C, Sanchez K, Roren A, et al. Anatomical specificities of the degenerated cervical spine: a narrative review of clinical implications, with special focus on targeted spinal injections. *Ann Phys Rehabil Med*. 2016;59(4):276–81.
- Nakagawa H, Okazaki T, Saito K. Surgical strategies in management of cervical spondylotic myelopathy. *World Neurosurg*. 2015;84(2):220–1.
- Shin JS, Oh SH, Cho PG. Surgical outcome of a zero-profile device comparing with stand-alone cage and anterior cervical plate with iliac bone graft in the anterior cervical discectomy and fusion. *Korean J Spine*. 2014;11(3):169–77.
- Guo H, Sheng J, Sheng WB, Liang WD, Wang J, Xun CH. An eight-year follow-up study on the treatment of single-level cervical Spondylosis through intervertebral disc replacement and anterior cervical decompression and fusion. *Orthopaedic Surgery*. 2020;12(3):717–26.
- Chung JY, Kim SK, Jung ST, Lee KB. Clinical adjacent-segment pathology after anterior cervical discectomy and fusion: results after a minimum of 10-year follow-up. *Spine J*. 2014;14(10):2290–8.
- Chen Y, Chen H, Cao P, Yuan W. Anterior cervical interbody fusion with the zero-P spacer: mid-term results of two-level fusion. *Eur Spine J*. 2015;24(8):1666–72.
- Alimi M, Njoku I, Hofstetter CP, et al. Anterior cervical discectomy and fusion (ACDF): comparison between zero profile implants and anterior cervical plate and spacer. *Cureus*. 2016;8(4):e573.
- Goodwin CR, Desai A, Khattab MH, Elder BD, Bydon A, Wolinsky JP. Cervical fusion for absent pedicle syndrome manifesting with myelopathy. *World Neurosurg*. 2016;86(515):e17–22.
- Lee DH, Lee JS, Yi JS, Cho W, Zebala LP, Riew KD. Anterior cervical plating technique to prevent adjacent-level ossification development. *Spine J*. 2013;13(7):823–9.
- Park JB, Cho YS, Riew KD. Development of adjacent-level ossification in patients with an anterior cervical plate. *J Bone Joint Surg Am*. 2005;87(3):558–63.
- Ishihara H, Kanamori M, Kawaguchi Y, Nakamura H, Kimura T. Adjacent segment disease after anterior cervical interbody fusion. *Spine J*. 2004;4(6):624–8.