



ELSEVIER

Contents lists available at [ScienceDirect](https://www.sciencedirect.com)

## Respiratory Medicine Case Reports

journal homepage: [www.elsevier.com/locate/rmcr](http://www.elsevier.com/locate/rmcr)

## Case report

## Endobronchial blood-patch: A novel technique for a persistent pleural air leak

Richard J. Durrance<sup>a,\*</sup>, Kenneth G. D'Souza<sup>a</sup>, Reiichiro Obata<sup>a</sup>, Ellen C. Bradley<sup>a</sup>, Muhammad K. Perwaiz<sup>b</sup><sup>a</sup> Pulmonary-Critical Care Fellow, Icahn School of Medicine at Mount Sinai, Elmhurst Hospital, United States<sup>b</sup> Interventional Pulmonology and Pulmonary Critical Care Attending, Icahn School of Medicine at Mount Sinai: Elmhurst Hospital, United States

## ARTICLE INFO

## Keywords:

Alveolar-pleural fistula  
Persistent air leak  
Covid-19  
Bronchoscopic air-leak repair

## ABSTRACT

**Introduction:** Patients with severe COVID-19 Pneumonia requiring prolonged mechanical ventilation have an increased incidence of pneumothorax. Mechanically ventilated patients who are critically ill and develop a persistent air leak from pneumothorax are poor candidates for surgical repair. As the persistent air leak can be a significant barrier to vent-weaning and clinical stability, these patients present a unique clinical challenge.

**Clinical case:** A 65-year-old male intubated and on prolonged mechanical ventilation for severe COVID-19 Pneumonia developed a pneumothorax complicated by a persistent alveolar-pleural fistula with a persistent air-leak. Given his critical state with ongoing pressor requirements and elevated vent requirements, surgical repair was not an option. A bedside bronchoscopy occlusion study with isolation of the air leak, and subsequent autologous endobronchial blood-patch repair with thrombin was performed with rapid and definitive resolution of the air leak. The patient progressed favorably, ultimately being weaned from the ventilator, decannulated, and walking out of the hospital.

**Conclusion:** In critically ill ventilated patients with pneumothorax complicated by a persistent air-leak, bedside endobronchial evaluation and blood-patch repair is a feasible approach to management.

## 1. Introduction

Mechanically ventilated patients with persistent alveolar-pleural fistulas (APF) present a unique clinical challenge. These patients are often critically ill with a dynamic clinical course that generally precludes repair by surgical intervention. In addition, the persistent air leak can pose a significant hurdle to the ventilator-weaning process.

Patients with severe COVID-19 infection requiring mechanical ventilation have been observed to have a relatively increased incidence of barotrauma [1]. As the subset of these patients who require prolonged mechanical ventilation are poor surgical candidates, pose a potential infection risk to Operating Room staff, and are often critically ill, the presence of a persistent APF can stagnate their clinical progression significantly.

Treatment options for patients with persistent APF and non-resolving pneumothorax who are poor surgical candidates are limited. While endobronchial valve placement can be considered [2], post-procedure pneumonia occurs in 4–9% of patients when optimized

Abbreviations: IRB, Institutional Review Board; APF, Alveolar-Pleural Fistula; VATS, Video-Assisted Thorascopic Surgery.

\* Corresponding author.

E-mail address: [jessedurrance@gmail.com](mailto:jessedurrance@gmail.com) (R.J. Durrance).

<https://doi.org/10.1016/j.rmcr.2022.101670>

Received 4 August 2021; Received in revised form 13 February 2022; Accepted 17 May 2022

Available online 28 May 2022

2213-0071/© 2022 Published by Elsevier Ltd.

This is an open access article under the CC BY-NC-ND license

(<http://creativecommons.org/licenses/by-nc-nd/4.0/>).

for lung-volume reduction [3]. It can therefore be easily extrapolated that infection risk would be significantly higher in the critically ill, especially those with an existing ventilator-associated pneumonia.

We report an alternative approach of a recently described novel technique of autologous endobronchial blood-patch with thrombin injection [4] in a patient with severe COVID-19 pneumonia and subsequent resolution of his persistent APF.

## 2. Case report and technique

A 65-year-old male without significant past medical history was admitted with severe COVID-19 pneumonia, and intubated on hospital day 2. His COVID-19 ARDS was treated with low-tidal-volume ventilation, prone-positioning, steroids, and IL-6 inhibitor therapy. Despite improvement in oxygenation, he could not be weaned off from the ventilator and underwent bedside percutaneous tracheostomy on day 14.

Five days later he developed a tension pneumothorax on the right side, which was successfully treated first with needle-decompression, and subsequent placement of a small-bore chest tube. He demonstrated a persistent continuous air-leak on suction and water seal. His clinical course was complicated by an ipsilateral hemothorax, for which a surgical chest tube was placed, and underwent arterial embolization of the right internal mammary artery for hemostatic control (Fig. 1A).

Given the fact that the patient remained on vasopressor support with persistent rapid atrial fibrillation, interdisciplinary evaluation with the thoracic surgery service concluded that the risk of surgical intervention was determined to be unacceptable. Therefore, after 14 days of unsuccessful resolution via chest tube drain, endobronchial treatment was pursued. Endobronchial valves required either IRB approval or humanitarian exemption, a process which could take up to 3–5 days. Therefore, autologous endobronchial blood patch repair was considered, and appropriate humanitarian exemption paperwork was completed in accordance with the scope of the procedure.

### 2.1. Occlusion study

One key aspect of endobronchial treatment of a persistent APF is air leak localization and the determination that collateral ventilation is not present via high-resolution CT chest imaging. However, given the significant parenchymal compromise evident on imaging (Fig. 1 A and B), an adequate evaluation of fissure integrity was not reliable. Furthermore, the location of the air leak was not obvious on the CT imaging done (Fig. 1 A and B). For this reason, an occlusion-study approach was determined to be most feasible and practical option to leak localization determination of potential resolution.

The patient was first subjected to a bedside bronchoscopic occlusion study. In order to keep the patient still, fentanyl and midazolam were administered to assure passive compliance with the ventilator. The pleural drain was maintained to continuous suction at 20cm H2O, with a constant 1-column air leak appreciated. An 80cm 5Fr Fogarty catheter was utilized under bronchoscopic guidance, with sequential apical-to-caudal segmental occlusion. Occlusion of the lateral segment of the right middle-lobe (B4) resulted in rapid

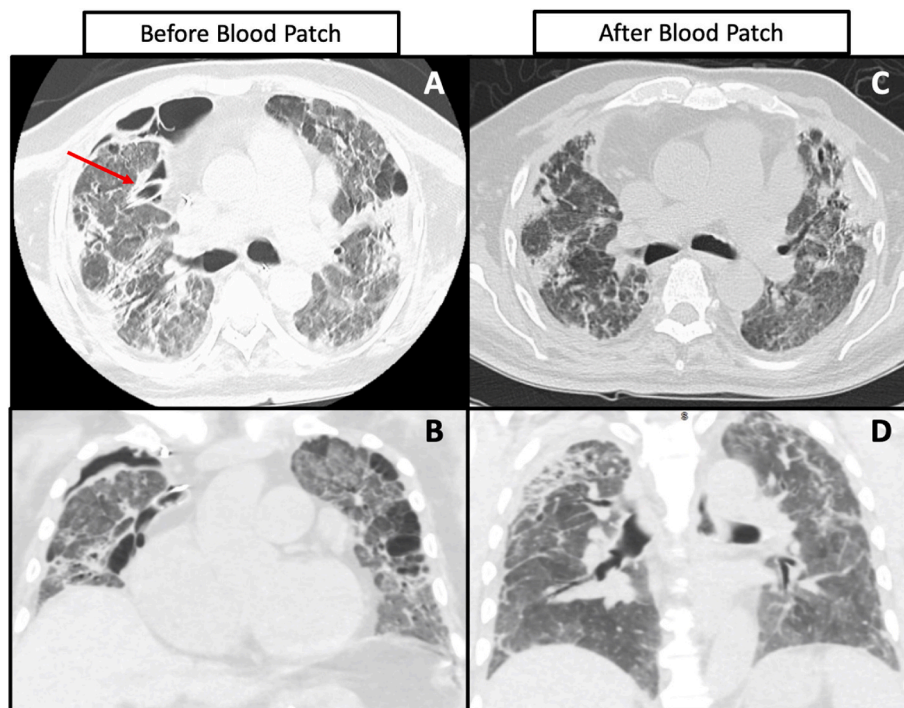


Fig. 1. CT Chest Axial and Coronal views pre- (A and B) and post- (C and D) blood-patch repair. The red arrow in Image A indicates the distal end of the surgical chest tube in the pre-repair image. (For interpretation of the references to colour in this figure legend, the reader is referred to the Web version of this article.)

air leak cessation on the pleural drain (Fig. 2). The air leak quickly re-appeared after removing occlusion from the segment. No change in air leak was observed with occlusion of any other segment, and therefore the persistent Broncho-pleural fistula was isolated to the B4 segment.

## 2.2. Blood-patch

The blood-patch was performed as a separate procedure. As before, the patient was sedated to passive compliance with the ventilator. Rocuronium was used as a paralytic in this instance to assure no inadvertent movement (i.e., cough) during the blood-patch procedure itself. After bronchoscopic inspection, we performed occlusion of the B4 segment of the Right Middle Lobe, reconfirming the location of the air leak location (again with the pleural drain to 20cm H2O negative pressure). The Swan-Ganz catheter was used in this instance in order to assure satisfactory occlusion prior to performing the blood-patch portion of the procedure.

Under sterile conditions, 30 cc of autologous blood was removed from the patient. With the Swan-Ganz catheter through the therapeutic scope the previously identified B4 segment with the balloon inflated, the 30 cc of autologous blood was then injected into the B4 segment, followed by two injections of 5000 U of reconstituted Thrombin (10 cc solution total), for a total of 40 cc fluid. Occlusion was maintained for 3 minutes under direct visualization, during which time no fluid was appreciated escaping the occluded segment on the bronchial side. On balloon deflation and removal of the catheter, no blood was observed coming from the B4 segment, and the air-leak remained resolved on the pleural drain.

Serial chest x-rays over the remaining course of his hospitalization demonstrated expansion of the now-loculated pneumothorax, and the chest tube was removed post-procedure day 16 (Fig. 1C).

The patient continued to progress favorably, eventually being successfully weaned from the vent, decannulated, and discharged walking out of the hospital on 2L nasal cannula 5 months after initial admission.

## 3. Discussion

Persistent air leaks are known to prolong ICU stay and are associated with worse clinical outcomes [5,6]. Endobronchial treatment for persistent air leaks has been described by a number of techniques, using valves, spigots, and a combination of autologous blood with hemostatic synthetic material [7–11]. Autologous blood-patch repair with thrombin has been described only recently [4,8,12], and only once at bedside [12].

### 3.1. Mechanism

Autologous blood patches have been used frequently in the epidural space for many years [13]. The premise for which this is done is based on the fact that whole blood contains both platelets and clotting factors that are not foreign to the body. This allows the body's intrinsic clotting system to act to "seal off" the area over which it is applied. In difference to the epidural space in which a low-pressure and low-flow leak occurs, an alveolar-pleural fistula is a much more dynamic leak. In every breath, the transpulmonary pressure will stress the leak towards the pleural space on inspiration and away from the pleural space on exhalation. In order to facilitate rapid closure of the APF, the following steps were taken:

1. The airway was occluded just after injection of the autologous blood and Thrombin. This eliminated pulmonary-to-pleural flow of air during inspiration (or a positive-pressure breath in the case of mechanical ventilation), thereby permitting the blood patch to sit in a more static environment, and favoring clot formation.
2. Thrombin was added to the injection of autologous blood in order to facilitate rapid clot stabilization (activation of fibrinogen to fibrin) in the time during which the segmental bronchus was occluded. As the airway is not in communication with an open portion

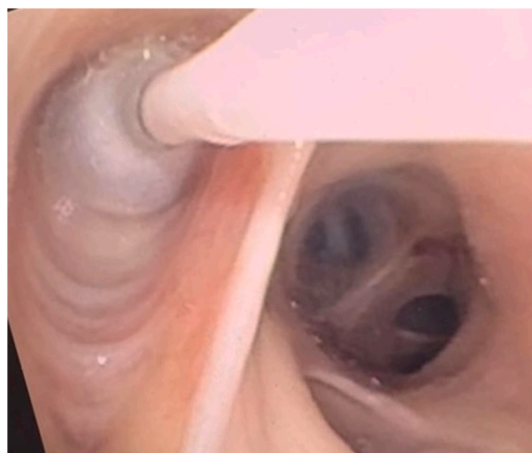


Fig. 2. Occlusion of the right middle lobe.

of the circulatory system, the risk of thrombo-embolic events [14], the principal adverse event associated with the use of thrombin, was negligible.

- By holding occlusion for 3 minutes, we allowed for roughly 10x the physiologic time necessary for clot formation to occur [15]. This appeared to be effective in observing no fluid return once the balloon was deflated.

### 3.2. Clinical caveats and limitations

Our case presents a couple of unique caveats that are worth mentioning. First of all, the treatment of a persistent alveolar-pleural fistula is ideally achieved in a much more controlled environment, with a more stable patient. The patient is usually evaluated with high-resolution CT Chest imaging in which anatomy can be appreciated, and patency of the fissures can be confirmed. Furthermore, in a lung that fully expands, pleurodesis by chemical means or mechanical means (VATS) can be attempted. Finally, placement of valves can be attempted, especially as these could potentially be removed after resolution of the air-leak. However, the dynamic and often tenuous nature of the critically ill and mechanically ventilated patient elevates the risk of any surgical intervention.

In critically ill patients with persistent alveolar-pleural fistulas, the absence of resolution poses a significant barrier to recovery. This is especially true in the COVID-19 era, in which there has been an increase in the number of patients with chronic respiratory failure. Therefore, we do not pretend to propose an alternative to standard of care therapy for those who are surgical candidates. In recognizing the limitations that critically ill patients possess, we seek to share our experience as a feasible and safe alternative approach to a complex clinical problem.

Secondly, one could argue that by virtue of the presence of a hemothorax, the patient effectively failed pleural blood-patch therapy. This would suggest that the endobronchial approach to autologous blood-patch repair could potentially have better efficacy than the pleural blood-patch procedure, quoted as 85% in one review [8].

## 4. Conclusion

Endobronchial blood-patch -thrombin repair of a persistent alveolar-pleural fistula in critically ill patients can be done at bedside effectively in select situations. These innovative bronchoscopic approaches are good options in these complex clinical problems, and have the potential to significantly improve patient outcomes.

### Declaration of competing interest

Informed Written Consent was obtained for the patient for the publication of this case.

The authors have no financial disclosures or conflicts of interest to declare.

### References

- Rajdev K, Spanel AJ, McMillan S, Lahan S, Boer B, Birge J, et al. Pulmonary barotrauma in COVID-19 patients with ARDS on invasive and non-invasive positive pressure ventilation. doi:10.1177/08850666211019719.
- H. Kalatoudis, M. Nikhil, F. Zeid, Y. Shweihat, Bronchopleural fistula resolution with endobronchial valve placement and liberation from mechanical ventilation in acute respiratory distress syndrome: a case series, *Case Rep. Crit. Care* (2017) 1–4, <https://doi.org/10.1155/2017/3092457>, 2017.
- D. Franzen, G. Straub, L. Freitag, Complications after bronchoscopic lung volume reduction, *J. Thorac. Dis.* (2018) S2811–S2815, <https://doi.org/10.21037/jtd.2018.06.66>. AME Publishing Company.
- M.K. Perwaiz, R. Pasrich, G. Grewal, R.J. Durrance, Endobronchial blood patch with thrombin injection, *Med. Case Rep. Stud. Protoc.* 2 (2021), e0090, <https://doi.org/10.1097/MD9.0000000000000090>.
- M.M. DeCamp, E.H. Blackstone, K.S. Naunheim, M.J. Krasna, D.E. Wood, Y.M. Meli, et al., Patient and surgical factors influencing air leak after lung volume reduction surgery: lessons learned from the national emphysema treatment trial, *Ann. Thorac. Surg.* 82 (2006) 197–207, <https://doi.org/10.1016/j.athoracsur.2006.02.050>.
- M. Liberman, A. Muzikansky, C.D. Wright, J.C. Wain, D.M. Donahue, J.S. Allan, et al., Incidence and risk factors of persistent air leak after major pulmonary resection and use of chemical pleurodesis, *Ann. Thorac. Surg.* 89 (2010) 891–898, <https://doi.org/10.1016/j.athoracsur.2009.12.012>.
- H.T. Zhang, Y.H. Xie, X. Gu, W.P. Li, Y.M. Zeng, S.Y. Li, et al., Management of persistent air leaks using endobronchial autologous blood patch and spigot occlusion: a multicentre randomized controlled trial in China, *Respiration* 97 (2019) 436–443, <https://doi.org/10.1159/000495298>.
- K. Manley, A. Coonar, F. Wells, M. Scarci, Blood patch for persistent air leak: a review of the current literature, *Curr. Opin. Pulm. Med.* (2012) 333–338, <https://doi.org/10.1097/MCP.0b013e32835358ca>.
- S. Keshishyan, A.E. Revelo, O. Epelbaum, Bronchoscopic management of prolonged air leak, *J. Thorac. Dis.* 9 (2017) S1034–S1046, <https://doi.org/10.21037/jtd.2017.05.47>.
- G. Wiaterek, H. Lee, R. Malhotra, W. Shepherd, Bronchoscopic blood patch for treatment of persistent alveolar-pleural fistula, *J. Bronchology Interv. Pulmonol.* 20 (2013) 171–174, <https://doi.org/10.1097/LBR.0b013e31828f4de0>.
- RM Mehta, A Singla, RS Bhat, R Godara, C Lokanath, M Cutaia, An innovative solution for prolonged air leaks, *J. Bronchol. Interv. Pulmonol.* 25 (2018) 111–117, <https://doi.org/10.1097/LBR.0000000000000459>.
- E. Schmitz, A new interventional bronchoscopy technique for the treatment of bronchopleural fistula, *Southwest J. Pulm Crit. Care* 15 (2017) 174–178, <https://doi.org/10.13175/swjpc120-17>.
- J.L. Booth, P.H. Pan, J.A. Thomas, L.C. Harris, R. D'Angelo, A retrospective review of an epidural blood patch database: the incidence of epidural blood patch associated with obstetric neuraxial anesthetic techniques and the effect of blood volume on efficacy, *Int. J. Obstet. Anesth.* 29 (2017) 10–17, <https://doi.org/10.1016/j.ijoa.2016.05.007>.
- F. Weaver, Clinical use of topical thrombin as a surgical hemostat, *Biol. Targets & Ther.* 23 (2008) 593, <https://doi.org/10.2147/BTT.S2435>.
- K.G. Mann, S. Butenas, K. Brummel, The dynamics of thrombin formation, *Arterioscler. Thromb. Vasc. Biol.* 23 (2003) 17–25, <https://doi.org/10.1161/01.ATV.0000046238.23903>.