



Migrated Peripherally Inserted Central Catheter in the Right Ventricle and Bilateral Pulmonary Arteries: A Case Report

Reena Anand¹ Vineeta Dagar¹ Rajeev Aggarwal² Sandeep Batra³

¹ Department of Radiology, Max Superspeciality Hospital, New Delhi, India

² Department of Cardiology, Max Superspeciality Hospital, New Delhi, India

³ Department of Oncology, Max Superspeciality Hospital, New Delhi, India

Address for correspondence Vineeta Dagar, MBBS, DNB

(Radiodiagnosis), 604 A Wing Aqua Blue Apartments, Rajkot 360005, Gujarat, India (e-mail: vnt.dagar92@gmail.com).

Indian J Radiol Imaging 2024;34:754–756.

Abstract

Keywords

- ▶ peripherally inserted central catheter
- ▶ localization
- ▶ computed tomography
- ▶ complications
- ▶ intervention

Introduction Central venous catheterization is a common tool widely used in medical treatment for long-term intravenous administration of medication (e.g. chemotherapy or antibiotics) or parenteral nutrition. Here, we present a case of a missing peripherally inserted central catheter (PICC) which was detected on computed tomography (CT) scan thorax.

Case Report A 50-year-old female admitted for follow-up for adenocarcinoma rectum was found to have a missing PICC line and advised CT thorax for evaluation. The imaging findings revealed coiled PICC line in the right atrium extending to inferior vena cava and into right ventricle and further extending and coiled PICC is seen in the main, right, and left pulmonary arteries. Through emergency interventional procedure, the PICC line was successfully retrieved percutaneously via the right femoral vein.

Conclusion PICC fracture is less common and always seen without significant discomfort if not found timely, and it may lead to serious complications, such as pulmonary embolism, and even death. Early detection and removal may help to prevent significant mortality.

Introduction

Nowadays peripherally inserted central catheter (PICC) is widely used in medical treatment for long-term intravenous (IV) administration of medication (e.g. chemotherapy) or parenteral nutrition. It is placed in a peripheral vein (usually basilic vein, cephalic vein, or median cubital vein) and travels along the brachial vein, axillary vein, and subclavian vein until it reaches the superior vena cava (SVC).¹ PICC is a good choice for prolonged venous access. The accurate incidence rate of PICC fracture is unknown due to a lack of long-term, large-scale, and prospective studies. However, PICC fracture

is potentially life-threatening and may result in serious outcomes. Retrieval of the fractured PICC fragment can now be accomplished with radiographical assistance using percutaneous techniques which have a high success rate of more than 90%, with few complications.²

Case Report

In a 50-year-old female diagnosed with adenocarcinoma rectum with a PICC seen traversing through left axillary, left brachiocephalic into the SVC visualized in a 3-month-old neonate's X-ray (▶ **Fig. 1**).

article published online
April 21, 2024

DOI <https://doi.org/10.1055/s-0042-1744234>
ISSN 0971-3026.

© 2024. Indian Radiological Association. All rights reserved.

This is an open access article published by Thieme under the terms of the Creative Commons Attribution-NonDerivative-NonCommercial-License, permitting copying and reproduction so long as the original work is given appropriate credit. Contents may not be used for commercial purposes, or adapted, remixed, transformed or built upon. (<https://creativecommons.org/licenses/by-nc-nd/4.0/>)

Thieme Medical and Scientific Publishers Pvt. Ltd., A-12, 2nd Floor, Sector 2, Noida-201301 UP, India

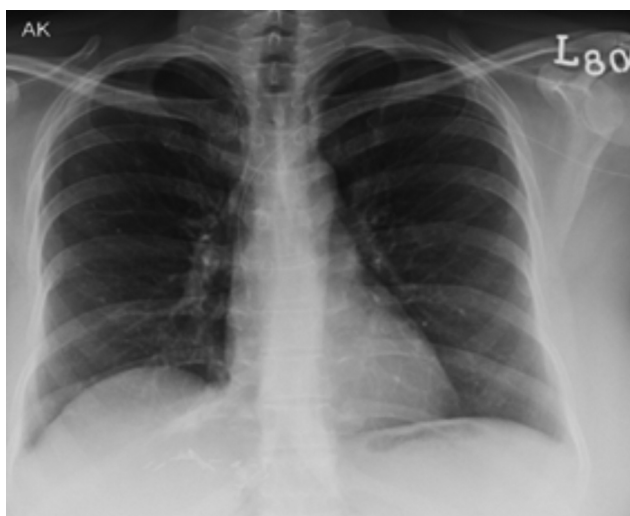


Fig. 1 Three months old chest X-ray showing the PICC line in position (yellow arrows showing PICC location). PICC, peripherally inserted central catheter.

Follow-up admission of patient revealed a missing PICC line which the patient was unaware of and the nursing staff confirmed that removal of PICC line has not been done by them. Evaluation for missing PICC line was advised by imaging and computed tomography (CT) thorax was advised.

The CT findings showed linear hyperdensity forming coils in the right atrium, inferior vena cava (IVC), and extending to right ventricle and further into the pulmonary arteries consistent with PICC line. The proximal end was lying in the right atrium and distal end coiled up in the main and right pulmonary artery (–**Fig. 3**) and into the left pulmonary artery (–**Fig. 4**) confirmed that PICC line was located within the heart.

The retrieval of the migrated PICC was performed immediately after detection on imaging. Under local anesthesia,

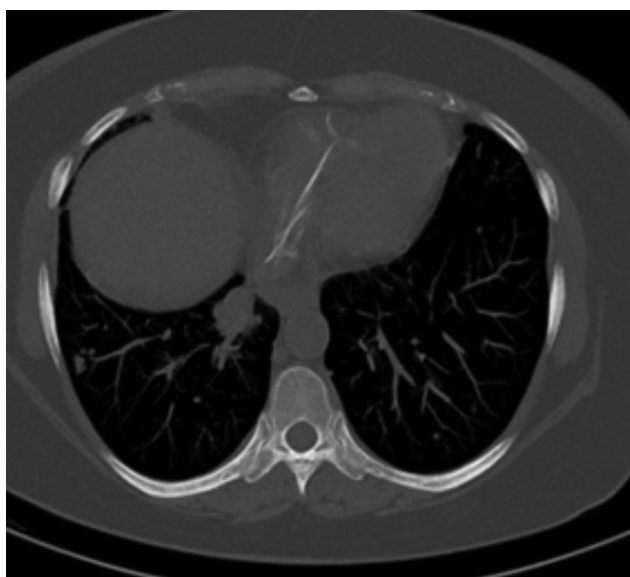


Fig. 2 HRCT axial view showed the broken PICC line into the right atrium and right ventricle (yellow arrow). HRCT, high-resolution computed tomography; PICC, peripherally inserted central catheter.

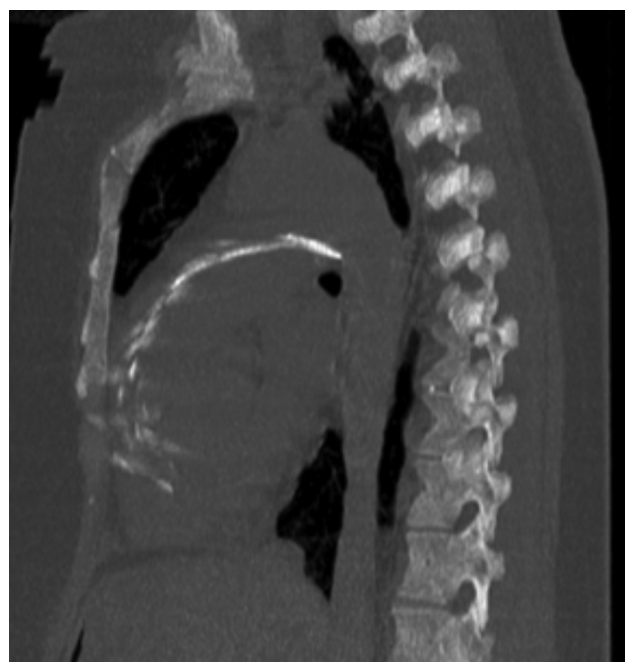

Fig. 3 HRCT reformatted sagittal section showing broken PICC line into the right ventricle and extending into the main pulmonary trunk (yellow arrow). HRCT, high-resolution computed tomography; PICC, peripherally inserted central catheter.

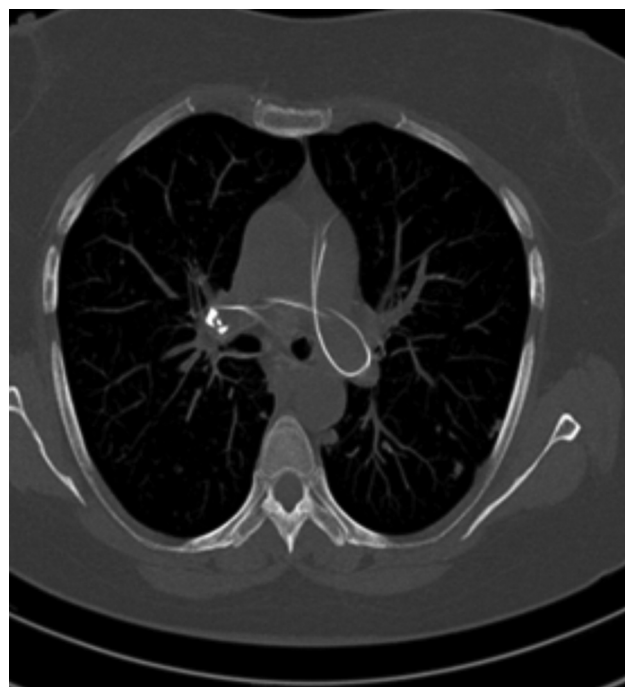


Fig. 4 HRCT axial cuts demonstrating presence of the coiled PICC line in the left pulmonary artery (yellow arrow). HRCT, high-resolution computed tomography; PICC, peripherally inserted central catheter.

using an ultrasound-guided percutaneous right femoral venous approach, a 9-F catheter sheath and snare taken, positioned in right atrium (RA), and the free end in RA is grasped in snare and pulled out through the sheath (–**Fig. 5**). Whole of the broken segment of PICC retrieved.

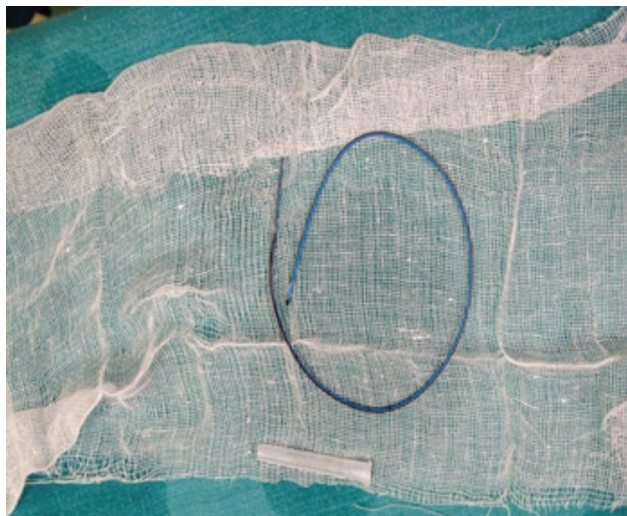


Fig. 5 Retrieved PICC line. PICC, peripherally inserted central catheter.

Discussion

Use of central and peripheral access devices is an integral part of modern oncology care for long-term infusion chemotherapy. In addition, PICC may be used for total parenteral nutrition, administration of antibiotics, and rehydration therapy. With proper maintenance, they can remain in situ up to 1 year. Optimal usage of PICC requires periodic (weekly) dressings and flushing. Majority of the complications can be avoided by proper maintenance. Common complications include phlebitis, vein thrombosis with embolization, and catheter occlusion. Catheter damage can occur with any PICC, sometimes due to defective products but more often from improper care.³ Migrated PICC may cause an increased incidence of thrombosis. Migration of a catheter has been reported as a delayed complication of PICC insertion.⁴ Catheters can migrate at an estimated rate of 0 to 3.1% within 1.5 years.⁵

The migrated PICC of our patient was located in the right atrium, ventricle, and extending up to the pulmonary arteries; it was a consequence of migration that shifted the segment of the catheter into the heart. Regular chest radiography is the common choice to ensure the safety of the

inserted PICC. If it was found broken or missing on chest X-ray, a CT scan should be performed to find out the exact position of the migrated PICC. The retrieval of the migrated PICC was performed immediately after detection on imaging in our case study.

Conclusion

Regular check X-ray should be taken for patients with PICC line to ensure the correct positioning of the catheter into the SVC. Any displacement/malpositioning can cause lethal complications, for example, vein thrombosis or embolization.

Authors' Contributions

R.A. and V.D. reviewed the CT thorax and reported the missing PICC into the right ventricle and extending into the pulmonary arteries. R.A. retrieved the PICC line through the right femoral route.

Conflict of Interest

None declared.

Acknowledgments

Authors would like to thanks Dr. Bharat Aggarwal for his contribution in our case.

References

- 1 Huhhes ME. PICC-related thrombosis: pathophysiology, incidence, morbidity and the effect of ultrasound-guided placement technique on occurrence in cancer patients. *J Assoc Vasc Access* 2011;16:8–18
- 2 Motta Leal Filho JM, Carnevale FC, Nasser F, et al. Endovascular techniques and procedures, methods for removal of intravascular foreign bodies. *Rev Bras Cir Cardiovasc* 2010;25(02):202–208
- 3 Zhang W, Yang Z, Shi H. Retrieval of a broken peripherally inserted central catheter migrated in the right pulmonary artery in a young girl: a case report. *J Cardiol & Cardiovasc Ther* 2015; 1:555555
- 4 Kadir S, Athanasoulis CA. Percutaneous retrieval of intravascular foreign bodies. In: Athanasoulis CA, Pfister RC, eds. *Interventional Radiology*. Philadelphia, PA: WB Saunders; 1982:379–397
- 5 Teragawa H, Sueda T, Fujii Y, et al. Endovascular technique using a snare and suture for retrieving a migrated peripherally inserted central catheter in the left pulmonary artery. *World J Cardiol* 2013;5(09):369–372