

Postoperative rescue closure of patent foramen ovale in the clinical setting of acute hypoxemic respiratory failure and stroke following coronary artery bypass surgery

José L. Díaz-Gómez^{1,2}, Eduardo Rodrigues², Monica Mordecai², John Moss¹, Richard C. Agnew³, Keith R. Oken⁴

Departments of ¹Critical Care Medicine, ²Anesthesiology, ³Cardiothoracic Surgery and ⁴Cardiology, Mayo Clinic, Jacksonville, Florida, United States

ABSTRACT

We describe a case of intraoperative diagnosis and successful deferred percutaneous closure of a patent foramen ovale (PFO) in the clinical setting of acute refractory hypoxemic respiratory failure and new-onset ischemic stroke in an elderly patient after coronary artery bypass graft. Perioperative morbidity (i.e. severe hypoxemia, worsening right ventricular dysfunction, and embolic stroke) that is potentially related to intraoperatively diagnosed PFO during cardiac surgery can complicate management in the Intensive Care Unit and perhaps affect the patient's outcome. Although the PFO closure can be challenging in the clinical setting of hypoxemic respiratory failure and stroke following cardiac surgery, it can be a reasonable perioperative option.

Received: 19-03-14
Accepted: 12-11-14

Key words: Coronary artery bypass graft; hypoxemia; patent foramen ovale; stroke

INTRODUCTION

There is a lack of data that can help guide decisions regarding incidental findings of PFO during CABG surgery in this patient population. Certainly, the benefit versus risk equation seems to be a reasonable approach on an individualized basis. We present a case where perioperative PFO closure provided an effective approach in the postoperative period when associated complications arose and warranted consideration of postoperative closure.

CASE REPORT

An 83-year-old man was admitted to our institution with the chief concern of worsening dyspnea on exertion for 3 days. The clinical

diagnosis was non-ST-segment elevation myocardial infarction. His past medical history included essential hypertension, aortic stenosis, heart failure with preserved ejection fraction, and chronic kidney disease.

The transthoracic echocardiogram revealed normal left ventricular function and a moderate decrease in right ventricular (RV) function. There was moderate aortic stenosis with peak velocity of 2.9 m/s and estimated area by velocity of 1.43 cm². The dimensionless velocity index was 0.34. The exam was inadequate for the atrial level shunt by color flow imaging. The patient subsequently underwent left heart catheterization, which showed multivessel coronary artery disease (CAD) and moderate aortic stenosis.

Access this article online

Website: www.annals.in

DOI:
10.4103/0971-9784.148328

Quick Response Code:



Address for correspondence: Dr. José L. Díaz-Gómez, Department of Critical Care, Mayo Clinic, 4500 San Pablo Road, Jacksonville, Florida 32224, United States. E-mail: diazgomez.jose@mayo.edu

The patient underwent urgent sternotomy and 4-vessel coronary artery bypass graft (CABG) surgery with no intervention to the aortic valve because the history of the present illness was directly related to the CAD. The patient had a myocardial infarction, the aortic stenosis was graded as moderate, the patient denied aortic stenosis related symptoms prior to his admission to the hospital, and his wishes on valve replacement were not discussed with him prior to the procedure. General anesthesia was maintained without major intraoperative events. Moderate tricuspid regurgitation and a patent foramen ovale (PFO) were identified with color flow Doppler during routine transesophageal echocardiogram (TEE) prior to cardiopulmonary bypass (CPB). The decision was made to defer closure of the PFO since there was no major evidence of cardiac right-to-left shunt in the setting of general anesthesia and CPB. Pre-CPB was reported as follows: pH = 7.36; PaO₂ = 292; PaCO₂ = 41.5; HCO₃ = 23.9; base excess (BE) = -1 while administering oxygen to a fraction of inspired oxygen (FIO₂) of 0.9. The aortic cross-clamp time and pump time were 72 min and 90 min, respectively. Repeat TEE following CPB, however, revealed a 4.7-mm PFO and right-to-left shunting [Figure 1] with normal left ventricular function and moderate RV dysfunction. Post-CPB was reported as follows, pH = 7.31; PaO₂ = 82; PaCO₂ = 42; HCO₃ = 21; BE = -5 (while administering oxygen to a FIO₂ of 1.0). There was no evidence of common causes of hypoxemia such as increased pulmonary secretions and mucus plug, bronchospasm – V/Q mismatch or insufficient FIO₂. Further, the pulse oximetry readings were between 88% and 96% after CPB. However, there was a continuous improvement in these oximetry readings, so it remained over 95% before the patient was transferred to the Intensive Care Unit (ICU).

After 2 h of admission to the ICU, the patient became hypoxemic. A chest X-ray-film revealed low lung volumes with atelectasis, consolidation, pulmonary edema or pneumothorax. An urgent TEE was performed at the bedside since the patient had persistent hypoxemia. The TEE confirmed the presence of the PFO with significant right-to-left shunting by color Doppler mapping and unchanged moderate RV systolic dysfunction (in comparison to post-CPB TEE exam). No new wall motion abnormalities were found.

During his first 72 h of ICU stay, the patient continued to require an FIO₂ of 1.0 to maintain a PaO₂ between 50 mmHg and 65 mmHg. On postoperative day 6, the patient presented acute motor deficit in the right upper

extremity. A computed tomography scan of the brain showed an ischemic stroke of the artery of Heubner territory [Figure 2].

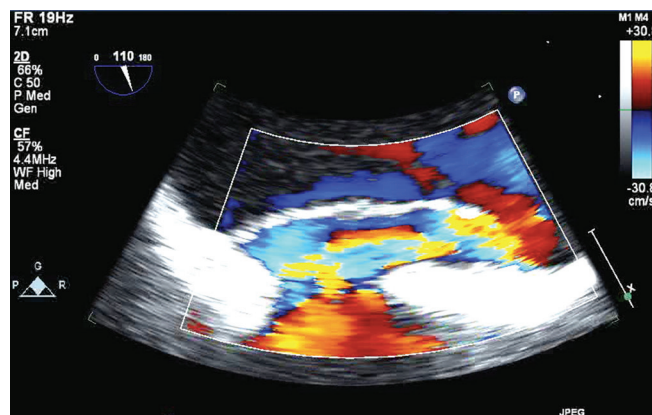


Figure 1: Echocardiographic evaluation of patent foramen ovale after cardiopulmonary bypass. Indicated in bicaval view of color flow Doppler transesophageal echocardiography

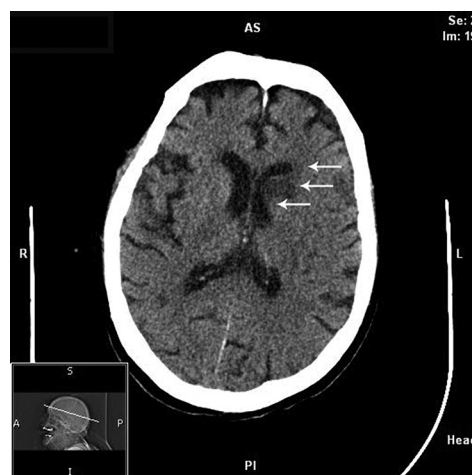


Figure 2: Noncontrast brain computed tomographic scan. Hypodensities apparent within right centrum semiovale, left anterior lentiform nucleus, left anterior capsule, and left caudate head. A indicates anterior; AS: anterosuperior; I: inferior; P: posterior; PI: posteroinferior; S: superior

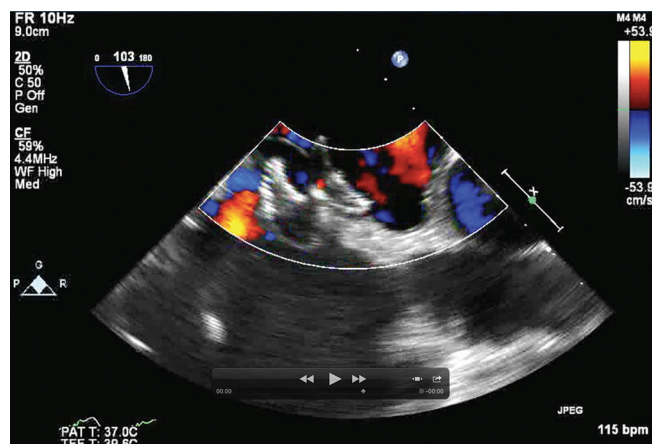


Figure 3: Postoperative closure of patent foramen ovale with amplatzer cribiform device. Bicaval view of transesophageal echocardiography

On postoperative day 7, our interventional cardiology team successfully closed the PFO with a 25-mm platzer Cribiform device AMPLATZERTM Multifenestrated Septal Occluder- “Cribiform” (Cribiform Occluder), AGA Medical corporation, Plymouth, MN, USA. [Figure 3]. Immediately after the device deployment, the oxygenation increased dramatically. Indeed, he tolerated the weaning process from mechanical ventilation and was extubated 48 h after the PFO closure. Two days later, he was transferred from the ICU to the step-down unit (total length of stay in the ICU, 10 days). After being in the hospital ward for an additional week for rehabilitation, the patient developed nosocomial pneumonia, and his family decided to adopt a palliative approach to his care. The patient was, therefore, not re-admitted to the ICU at this time, and he died 4 days later.

DISCUSSION

The present case raises the question of whether deferred postoperative percutaneous closure of an incidental PFO during CABG surgery should be an option for perioperative management of PFO related morbidity. Most cardiac surgeons make decisions regarding intraoperative PFO closure on the basis of PFO size and the patient’s history of embolism. The decision to defer the closure of a PFO exposes the patient to unclear immediate and long-term consequences, including postoperative refractory hypoxemia and potential ischemic stroke,^[1,2] as noted in this case.

A recent publication reported no association of PFO with increased perioperative morbidity.^[3] Rather, the investigators suggested that surgical closure may increase postoperative stroke risk. In a national survey of 734 cardiac surgeons, 303 (69.2%) of 438 respondents had never observed PFO-related hypoxemia that mandated medical intervention in the immediate postoperative period and only a third of the surgeons answered that they always close a PFO during on-pump surgery.^[4]

Intrapulmonary shunting and ventilation-perfusion mismatch are the most common causes of hypoxemic acute respiratory failure. However, the presence of a PFO may complicate ventilatory support and perpetuate the degree of hypoxemia among patients with severe respiratory failure.^[5] We thought that refractory postoperative hypoxemia was the main clinical decision-making factor for performing a rescue

percutaneous PFO closure with the additional goal of reducing the risk of further cerebral embolic events.

Timing and oxygenation threshold prior to PFO closure in the perioperative setting are factors to be considered. In our case, given the stability of the hypoxemia and the tenuous RV dysfunction, we initially strived to improve his oxygenation with very aggressive medical and ventilator management until hemodynamic stability could be achieved. The occurrence of a possible cardio-embolic stroke was an additional factor to take into account for the final decision to close the PFO.

Complicating decisions, intraoperative closure of a PFO could be utilized postoperatively via a percutaneous closure if compelling indications evolve. This raises the valid question of whether the two techniques for PFO closure yield similar results. There is no compelling evidence that either approach is effective at reducing the rate of recurrent thromboembolic events when used on a routine basis. Furthermore, there are no well-designed studies that support this procedure as a secondary prevention of stroke.^[6] Two recent publications showed no significant improvement in outcome associated with the closure of PFO in adults who previously had a cryptogenic ischemic stroke.^[7,8]

Despite the lack of evidence to support routine closure of intraoperatively diagnosed PFO, circumstances occasionally arise in which such an intervention may be merited. Sukernik *et al.*^[9] have published a case that shows a potential postoperative paradoxical embolism in a patient who did not undergo repair of an intraoperatively diagnosed asymptomatic PFO. The recent development of percutaneous methods of PFO closure provides an effective approach to such cases in which PFO is not closed during surgery and when postoperative hypoxemia due to right-to-left shunting or other complications, such as cardio-embolic stroke, may warrant consideration of postoperative closure.^[10]

REFERENCES

1. Krasuski RA, Hart SA, Allen D, Qureshi A, Petterson G, Houghtaling PL, *et al.* Prevalence and repair of intraoperatively diagnosed patent foramen ovale and association with perioperative outcomes and long-term survival. *JAMA* 2009;302:290-7.
2. Argenziano M. PRO: The incidental finding of a patent foramen ovale during cardiac surgery: Should it always be repaired? *Anesth Analg* 2007;105:611-2.
3. Flachskampf FA. CON: The incidental finding of a patent foramen ovale during cardiac surgery: Should it always be repaired? *Anesth Analg* 2007;105:613-4.

4. Sukernik MR, Goswami S, Frumento RJ, Oz MC, Bennett-Guerrero E. National survey regarding the management of an intraoperatively diagnosed patent foramen ovale during coronary artery bypass graft surgery. *J Cardiothorac Vasc Anesth* 2005;19:150-4.
5. Mekontso Dessap A, Boissier F, Leon R, Carreira S, Campo FR, Lemaire F, *et al.* Prevalence and prognosis of shunting across patent foramen ovale during acute respiratory distress syndrome. *Crit Care Med* 2010;38:1786-92.
6. O'Gara PT, Messe SR, Tuzcu EM, Catha G, Ring JC, American Heart Association, *et al.* Percutaneous device closure of patent foramen ovale for secondary stroke prevention: A call for completion of randomized clinical trials: A science advisory from the American Heart Association/American Stroke Association and the American College of Cardiology Foundation. *Circulation* 2009;119:2743-7.
7. Carroll JD, Saver JL, Thaler DE, Smalling RW, Berry S, MacDonald LA, *et al.* Closure of patent foramen ovale versus medical therapy after cryptogenic stroke. *N Engl J Med* 2013;368:1092-100.
8. Meier B, Kalesan B, Mattle HP, Khattab AA, Hildick-Smith D, Dudek D, *et al.* Percutaneous closure of patent foramen ovale in cryptogenic embolism. *N Engl J Med* 2013;368:1083-91.
9. Sukernik MR, Frumento R, Mets B, Jordan D, Bennett-Guerrero E, Cheung AT, *et al.* CASE 1–2004. Intraoperative diagnosis of a patent foramen ovale in a patient undergoing coronary artery bypass graft surgery. *J Cardiothorac Vasc Anesth* 2004;18:101-6.
10. Wang A, Bashore TM, Kisslo KB, Das GS, O'Laughlin MP, Harrison JK. Hypoxemia after prior cardiac surgery due to interatrial shunting and its treatment with a novel transcatheter occlusion device. *Catheter Cardiovasc Interv* 1999;46:452-6.

Cite this article as: Díaz-Gómez JL, Rodrigues E, Mordecai M, Moss J, Agnew RC, Oken KR. Postoperative rescue closure of patent foramen ovale in the clinical setting of acute hypoxemic respiratory failure and stroke following coronary artery bypass surgery. *Ann Card Anaesth* 2015;18:91-4.

Source of Support: Nil, **Conflict of Interest:** None declared.