

Contents lists available at [ScienceDirect](#)

## International Journal of Surgery Case Reports

journal homepage: [www.casereports.com](http://www.casereports.com)

## Acute cholecystitis secondary to dog bite

James Elliott\*, Eric Donaldson

Department of General Surgery, Toowoomba Hospital, 154 Pechey Street, South Toowoomba, Queensland, Australia

## ARTICLE INFO

## Article history:

Received 17 October 2018

Received in revised form 30 January 2019

Accepted 6 February 2019

Available online 12 February 2019

## ABSTRACT

**INTRODUCTION:** The gram-negative bacteria known as *Capnocytophaga canimorsus* (*C. canimorsus*) is found in dog saliva and rarely can cause severe infection in humans following a bite or scratch. There has previously been just a single case described in the literature of Acute Acalculous Cholecystitis (AAC) secondary to *C. canimorsus*.

**PRESENTATION OF CASE:** Here we describe the second ever published case of *C. canimorsus* bacteremia presenting with acute cholecystitis. The patient presented with epigastric pain and sepsis three weeks post domestic dog bite. On further examination, he was Murphy's sign positive. Investigations included blood cultures, Ultrasound Scan and Computed Tomography of the Abdomen. He was treated with intravenous fluid resuscitation, and intravenous ceftriaxone and metronidazole. He required an extended course of antibiotics for complete symptom resolution. His blood cultures were positive for *C. Canimorsus*.

**DISCUSSION:** This case highlights the ever-present need for thorough history and examination, and consideration of prolonged antibiotics for cases of cholecystitis that could be secondary to *C. canimorsus* bacteremia.

**CONCLUSION:** We strongly advocate blood cultures in patients who present with abdominal pain and sepsis, particularly when they have a recent history of animal bite. In cases of cholecystitis secondary to *C. canimorsus* it may be necessary to monitor the patient's progress more closely and treat with prolonged targeted antibiotic therapy.

© 2019 The Author(s). Published by Elsevier Ltd on behalf of IJS Publishing Group Ltd. This is an open access article under the CC BY license (<http://creativecommons.org/licenses/by/4.0/>).

## 1. Introduction

The gram-negative bacteria known as *Capnocytophaga canimorsus* (*C. canimorsus*) is found in dog saliva and rarely can cause severe infection in humans following a bite or scratch [1]. Infection typically only affects immunocompromised hosts [1]. Main risk factors for infection with *C. canimorsus* include asplenia, functional asplenia, cirrhosis, and a history of alcohol dependence [2]. A range of patient cases with other immunocompromised states have been described [3–6]. The small percentage of patients who become unwell usually present at an average of five to six days post bite [7] with one or a combination of the following: septic shock (41%), fever of unknown origin (13%), meningitis (13%), cellulitis (11%), and respiratory tract infection (7%) [2]. There are also case reports of endocarditis, septic arthritis, and purpura fulminans [2,8]. There has been just a single case described in the literature of acute acalculous cholecystitis secondary to *C. canimorsus* [9]. This was in an octogenarian female with a history of hypertension and diabetes mellitus.

Acalculous cholecystitis is an inflammatory disease process of the gallbladder and is thought to result from factors that promote gallbladder stasis and ischaemia. Such risk factors are wide-ranging, but there are recognised primary infections that are associated with acalculous cholecystitis. These include but are not limited to: *Ascaris lumbricoides*, *Brucella* species, *Campylobacter jejuni*, *Candida* species, *Coxiella burnetii*, *Cryptosporidium*, *Cytomegalovirus*, *Echinococcus granulosus*, Epstein-Barr virus, *Flavivirus*, *Hepatitis A and B*, *Isospora*, *Leptospira* species, *Mycobacterium tuberculosis*, *Plasmodium* species, *Salmonella* species and *Vibrio cholerae* [10,11]. Acalculous cholecystitis is more characteristically secondary to critical illness in already-hospitalised patients, though it is probably under-recognised in the outpatient setting [12].

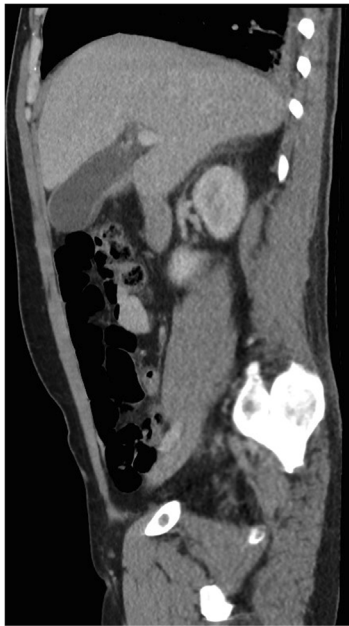
This case has been reported in line with the SCARE criteria [13].

## 2. Presentation of case

Here we describe the second ever published case of *C. canimorsus* bacteremia presenting with acute cholecystitis, albeit in a very different host: a forty year old Caucasian male tradesperson, with normal BMI, no medical conditions but previous heavy alcohol use and current cigarette smoking. The patient presented by ambulance to our institution with epigastric pain and sepsis three weeks post domestic dog bite to his right lower leg. A healing

\* Corresponding author.

E-mail addresses: [James.elliott@health.qld.gov.au](mailto:James.elliott@health.qld.gov.au) (J. Elliott), [ericdonaldson@bigpond.com](mailto:ericdonaldson@bigpond.com) (E. Donaldson).



**Fig. 1.** Oedematous gallbladder suggestive of cholecystitis with no evidence of calculi.

superficial bite wound was still present and healing well and with no signs of local infection. On examination, his Murphy's sign was positive. Investigations included blood cultures and CT-Abdomen (Fig. 1). CT revealed a distended and oedematous gallbladder suggestive of cholecystitis and he was treated with intravenous fluid resuscitation, and intravenous ceftriaxone and metronidazole. His blood cultures were positive for *C. Canimorsus*. Subsequent abdominal ultrasound imaging confirmed acalculous cholecystitis without evidence of perforation or gangrene: both recognised complications [14–16]. He improved rapidly with aggressive conservative treatment, and after seventy two hours of intravenous antibiotic therapy his treatment was converted to oral amoxicillin with clavulanic acid. He required a prolonged course of this (four weeks) for complete symptom resolution. The patient thus avoided emergency drainage or cholecystectomy. He has had no recurrent symptoms.

### 3. Discussion

This case highlights the ever-present need for thorough history and examination of a patient presenting with septic shock, as his dog bite was not obviously related at first. Blood cultures and abdominal imaging are essential in patients with a febrile illness, right upper quadrant pain, and distributive shock. Based on this case, we would encourage consideration of prolonged antibiotics in cases of acalculous cholecystitis that could be secondary to *c. canimorsus* bacteremia. Given the risk of recurrence of this illness is very low, interval cholecystectomy is considered unnecessary in patients who recovery from acute acalculous cholecystitis [17].

### 4. Conclusion

Acute Cholecystitis secondary to *C. Canimorsus* bacteremia is rare but still likely under-recognised. The bacteria may have enough pathogenicity to cause cholecystitis in hosts who are not immunodeficient such as this patient. We strongly advocate blood cultures in patients who present with abdominal pain and sepsis, particularly when they have a recent history of bite. In cases of cholecystitis secondary to *C. Canimorsus* it may be necessary

to monitor the patient closely and treat with prolonged targeted antibiotic therapy.

### Conflict of interest

Nothing to declare.

### Sources of funding

Nothing to declare.

### Ethical approval

This study has been granted status of “Not Requiring Ethical Review” (NRER) by the local HREC (Darling Downs Hospital and Health Service). Reference: LNR/2019/QTDD/51019 (Jan ver 1).

### Consent

Written informed consent was obtained from the patient for publication of this case report and any accompanying de-identified images. A copy of the written consent is available for review by the Editor-in-Chief of this journal on request.

### Author contribution

Dr James Elliott is the primary author of this case report, and authored the entire paper and associated documentation.

Dr Eric Donaldson was the patient's treating consultant during their hospital admission, and his role in this paper was to supervise the drafting and writing of this case report paper.

### Registration of research studies

Since this is a case report, not a research study, registration is not indicated.

### Guarantor

Dr James Elliott (the primary author) is the guarantor of this work.

### Provenance and peer review

Commissioned, externally peer-reviewed.

### References

- [1] A.P. Van Dam, A. Jansz, *Capnocytophaga canimorsus* infections in The Netherlands: a nationwide survey, *Clin. Microbiol. Infect.* 17 (February (2)) (2011) 312–315.
- [2] C. Pers, B. Gahrn-Hansen, W. Frederiksen, *Capnocytophaga canimorsus* septicemia in Denmark, 1982–1995: a review of 29 cases, *Clin. Infect. Dis.* 23 (1) (1996) 71.
- [3] S. Maury, T. Leblanc, P. Rousselot, P. Legrand, G. Arlet, C. Cordonnier, Bacteremia due to *Capnocytophaga* species in patients with neutropenia: high frequency of beta-lactamase-producing strains, *Clin. Infect. Dis.* 28 (May (5)) (1999) 1172–1174.
- [4] R. Martino, E. Ramila, J.A. Capdevila, A. Planes, M. Rovira, M. Ortega, G. Plume, L. Gomez, J. Sierra, Bacteremia caused by *Capnocytophaga* species in patients with neutropenia and cancer: results of a multicentre study, *Clin. Infect. Dis.* 33 (Aug (4)) (2001), E20–2. Epub 2001 Jul 20.
- [5] J.A. Kim, S.K. Hong, E.C. Kim, *Capnocytophaga sputigena* bacteremia in a patient with chronic lymphocytic leukemia, *Ann. Lab. Med.* 34 (July (4)) (2014) 325–327, Epub 2014 Jun 19.
- [6] T. Ugai, H. Sugihara, Y. Nishida, M. Yamakura, M. Takeuchi, K. Matsue, *Capnocytophaga canimorsus* sepsis following BMT in a patient with AML: possible association with functional asplenia, *Bone Marrow Transplant.* 49 (Jan (1)) (2014) 153–154, Epub 2013 Aug 26.
- [7] B.J. Kullberg, R.G. Westendorp, J.W. van 't Wout, A.E. Meinders, *Purpura fulminans and symmetrical peripheral gangrene caused by Capnocytophaga*

- canimorsus (formerly DF-2) septicemia—a complication of dog bite, *Medicine (Baltimore)* 70 (Sep (5)) (1991) 287–292.
- [8] J.M. Janda, M.H. Graves, D. Lindquist, W.S. Probert, Diagnosing *Capnocytophaga canimorsus* infections, *Emerg. Infect. Dis.* 12 (Feb (2)) (2006) 340–342.
- [9] H. Nishioka, T. Kozuki, H. Kamei, *Capnocytophaga canimorsus* bacteremia presenting with acute cholecystitis after a dog bite, *J. Infect. Chemother.* 21 (2015) 215–217.
- [10] P. Wind, J.M. Chevallier, D. Jones, P. Frileux, P.H. Cugnenc, Cholecystectomy for cholecystitis in patients with acquired immune deficiency syndrome, *Am. J. Surg.* 168 (3) (1994) 244.
- [11] J.A. Nash, S.A. Cohen, Gallbladder and biliary tract disease in AIDS, *Gastroenterol. Clin. North Am.* 26 (2) (1997) 323.
- [12] P.E. Savoca, W.E. Longo, K.A. Zucker, M.M. McMillen, I.M. Modlin, The increasing prevalence of acalculous cholecystitis in outpatients. Results of a 7-year study, *Ann. Surg.* 211 (4) (1990) 433.
- [13] R.A. Agha, A.J. Fowler, A. Saetta, I. Barai, S. Rajmohan, D.P. Orgill, for the SCARE Group, The SCARE statement: consensus-based surgical case report guidelines, *Int. J. Surg.* 34 (2016) 180–186.
- [14] M.J. Shapiro, W.B. Luchtefeld, S. Kurzweil, D.L. Kaminski, R.M. Durham, J.E. Mazuski, Acute acalculous cholecystitis in the critically ill, *Am. Surg.* 60 (5) (1994) 335.
- [15] S. Kalliafas, D.W. Ziegler, L. Flancbaum, P.S. Choban, Acute acalculous cholecystitis: incidence, risk factors, diagnosis, and outcome, *Am. Surg.* 64 (5) (1998) 471.
- [16] P.S. Barie, S.R. Eachempati, Acute acalculous cholecystitis, *Gastroenterol. Clin. North Am.* 39 (June (2)) (2010) 343–357.
- [17] S.H. Abbas, M.A. Ghazanfar, A.N. Gordon-Weeks, S.R. Reddy, Z. Soonawalla, M.A. Silva, Acalculous cholecystitis: is an elective interval cholecystectomy necessary, *Dig. Surg.* 35 (2) (2018), 171. Epub 2017 Jul 14.

#### Open Access

This article is published Open Access at [sciencedirect.com](https://www.sciencedirect.com). It is distributed under the [IJSCR Supplemental terms and conditions](#), which permits unrestricted non commercial use, distribution, and reproduction in any medium, provided the original authors and source are credited.