

Case Report

Disseminated tuberculosis with immune thrombocytopenic purpura

Rucha S. Dagaonkar, Zarir F. Udwadia

Department of Pulmonary Medicine, P. D. Hinduja National Hospital and MRC Veer Sawarkar Marg, Mahim, Mumbai, India

ABSTRACT

Tuberculosis has a variety of hematological manifestations. Immune thrombocytopenic purpura is an uncommon manifestation of tuberculosis. We present a case of disseminated tuberculosis with isolated thrombocytopenia. While TB granulomas in the bone marrow can themselves cause hematological abnormalities, persistent thrombocytopenia refractory to anti-TB therapy may be ITP associated with TB.

KEY WORDS: Disseminated tuberculosis, immune thrombocytopenic purpura, intravenous immunoglobulin

Address for correspondence: Dr. Rucha S. Dagaonkar, Department of Pulmonary Medicine, PFT lab, 3rd Floor, Hinduja Clinic Building, P. D. Hinduja National Hospital and MRC, Veer Sawarkar Marg, Mahim, Mumbai- 400 016, India. E-mail: rucha.dagaonkar@gmail.com

INTRODUCTION

We present an interesting case of disseminated tuberculosis, complicated by isolated thrombocytopenia which was diagnosed as immune thrombocytopenic purpura. This is a rare haematological manifestation of tuberculosis.

CASE REPORT

A 44-year-old female presented to our center in October 2009 with a history of continuous low grade fever, and lower backache, of 3 months duration. There was no history of cough with expectoration, loss of appetite, or weight-loss. The patient was a known case of diabetes mellitus on insulin. The patient had been managed symptomatically with antipyretics and analgesics prior to presentation to our center. The complete blood count (CBC) at the time of presentation was normal. She was advised admission for further evaluation of her fever of unknown origin.

A few hours after admission, the patient developed

altered sensorium and aggressive behavior, associated with spontaneous bleeding from the buccal mucosa. The patient was transferred to the intensive care unit, where she was sedated and restrained. The CBC showed thrombocytopenia (platelet count: 36000/mm³) with normal erythrocyte and leukocyte counts. An urgent computed tomography (CT) scan of the brain did not reveal any evidence of intracranial bleeding. However, a chest radiograph showed diffuse nodular lesions consistent with miliary tuberculosis, which was confirmed with high resolution computed tomography (HRCT) scan of the chest.

The working diagnosis was disseminated miliary tuberculosis. Central nervous system (CNS) involvement was confirmed by a magnetic resonance (MR) scan of the brain, which showed multiple granulomatous lesions in the cerebral cortex, consistent with tuberculosis.

First-line antituberculosis treatment (isoniazid, pyrazinamide, ethambutol, and levofloxacin) with steroids (for the CNS involvement) was started. In view of thrombocytopenia, rifampicin was held. Levofloxacin was given as a first-line drug in place of rifampicin. Platelet transfusions were also given, despite which platelet counts continued to decline. Therefore a bone marrow biopsy was done, which revealed occasional granulomas, suggestive of tuberculosis, but no acid fast bacilli (AFB) were seen. The bone marrow aspiration was normocellular, with normal megakaryocytes [Figure 1]. (The bone marrow AFB culture at the end of 6 weeks' incubation was also negative.)

Access this article online	
Quick Response Code: 	Website: www.lungindia.com
	DOI: 10.4103/0970-2113.92367

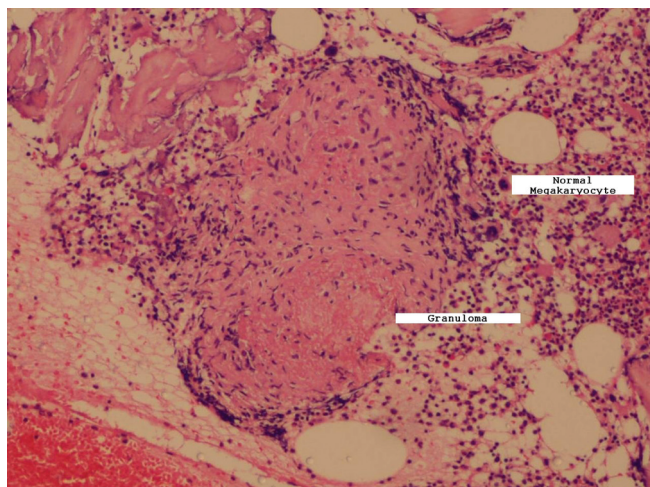


Figure 1: Low power (10×) photomicrograph of the bone marrow biopsy showing a caseating granuloma with normal megakaryocytes. Image courtesy: Department of Haematology

Thus the final diagnosis was disseminated tuberculosis with miliary, bone marrow and CNS involvement, based on clinical, radiological, and histopathological evidence.

There was improvement in the sensorium, and the patient became afebrile, with ATT and steroids. But the isolated thrombocytopenia persisted despite the ATT and also remained refractory to platelet transfusions. In view of this, a cause of thrombocytopenia other than tuberculosis of the bone marrow was considered. A detailed work-up for thrombocytopenia was done. Serological tests for HIV, dengue, and antinuclear antibodies were negative. The peripheral blood smear examination was negative for the malarial parasite. The direct Coomb's test was weakly positive.

In view of (1) persistent, isolated thrombocytopenia refractory to platelet transfusion and (2) the presence of normal megakaryocytes in the bone marrow aspirate, immune thrombocytopenic purpura (ITP), with disseminated tuberculosis was suspected. ITP was treated with intravenous immunoglobulin (IVIG), 400/mg/kg per day for 5 days. Just prior to infusion, the platelet count was 11,000/mm³. One week after completion of IVIG therapy, the platelet count rose up to 22,000/mm³. This response further supported the diagnosis of ITP. Steroid dosage was stepped up to 60 mg of prednisolone daily which was then gradually tapered. Rifampicin was now added to the ATT regimen and levofloxacin was stopped. The patient then developed ATT-induced hepatitis, and was treated briefly with a nonhepatotoxic regimen of amikacin, ethambutol, levofloxacin. However, rifampicin and isoniazid were reintroduced in full doses within 4 weeks.

On last follow-up in April 2010, the patient had completed 7 months of first line ATT, with significant symptomatic improvement. The platelet count was 99,000/mm³ at last follow-up.

DISCUSSION

Our patient had disseminated tuberculosis with miliary, CNS, and bone marrow involvement, with associated isolated thrombocytopenia. There was no evidence of pulmonary tuberculosis. There was no hepatosplenomegaly, and no lymph node enlargement. The isolated thrombocytopenia, at the outset, was attributed to the disseminated tuberculosis, which can cause a number of hematological abnormalities.^[1] Isolated thrombocytopenia has been reported in 23-43% patients with disseminated tuberculosis.^[2] Other hematological manifestations of disseminated tuberculosis include leucopenia, anemia, pancytopenia, myelofibrosis, and the hemophagocytic syndrome, which can occur due to direct bone marrow involvement in tuberculosis.^[1] In one study, bone marrow granulomas were found in 50-100% of the patients with disseminated tuberculosis.^[3] Some of the other mechanisms implicated in the causation of hematological abnormalities in disseminated tuberculosis include splenomegaly leading to hemolytic anemia and/or neutropenia, increased IL-6 production causing thrombocytosis and cell-mediated autoimmune mechanisms causing neutropenia.^[4]

The mechanism of isolated thrombocytopenia in tuberculosis is believed to be immune mediated, through antiplatelet antibodies or platelet-associated immunoglobulin G, which are generated by proliferating lymphocytes as a part of the immune response to infection.^[2,4-6] Most of the hematological abnormalities, including pancytopenia, have been noted to respond to ATT.^[7]

Rifampicin is also known to cause hematological abnormalities, which can be via autoimmune mechanisms, for example, rifampicin-induced autoimmune hemolytic anemia and thrombocytopenia. The latter is thought to be mediated via antibodies directed against glycoprotein Ib/IX and is more frequently observed with an intermittent schedule of rifampicin.^[4]

Our patient had not received any ATT prior to presentation to our institution. Hence ATT-induced thrombocytopenia was ruled out. In our patient, the altered sensorium and fever both responded favorably to ATT and steroids, whereas the thrombocytopenia did not. It responded eventually to IVIG infusions, which were given for suspected immune thrombocytopenic purpura (ITP).

ITP is a disorder in which antiplatelet antibodies cause accelerated destruction of platelets, resulting in thrombocytopenia and a varying propensity for bleeding.^[8] In addition, it is now recognized that these antibodies may also impair platelet production, creating a dual cause of thrombocytopenia. The diagnostic criteria^[9] for ITP are (1) isolated thrombocytopenia with otherwise normal peripheral complete blood count and smear, (2) an absence of hepatosplenomegaly and lymphadenopathy on

physical examination, and (3) platelet response to classic ITP therapy (usually intravenous immunoglobulin, IV anti-D, and possibly steroids). Our patient met the first two of the above-mentioned criteria for ITP. Also, her thrombocytopenia improved only after infusions of IVIG. This further supports the diagnosis of ITP in our patient.

ITP in conjunction with tuberculosis has not been reported frequently. A study from Saudi Arabia of 846 patients reported that only 1% of these had ITP as the presenting feature; all these patients had increased megakaryocytes in the bone marrow.^[9]

Ursavas *et al.* from Turkey reported a case of a middle-aged man with sputum-positive pulmonary tuberculosis who presented with bleeding tendency, and responded to ATT with steroids.^[10] A case of pulmonary tuberculosis presenting solely as purpura has also been reported.^[6,11] Ghobrial *et al.* have reported a case of a 41-year-old male with bleeding manifestations of ITP, with disseminated tuberculosis. In this case the bleeding manifestations resolved only after ATT was added to the ongoing immunotherapy for ITP.^[12] Cockcroft reported a case of miliary tuberculosis presenting with hyponatremia and thrombocytopenia and postulated that the latter could have been caused by activation of latent ITP by tuberculosis infection.^[13]

Patients known to have underlying ITP have also been reported to develop tuberculosis.

A case report from Turkey describes a child diagnosed with ITP, not responding to standard therapy with IVIG and pulsed steroids. Radiological investigations were suggestive of pulmonary infiltrates and the patient responded to the combination of ATT and steroids.^[14] Thrombocytopenia associated with tuberculous gumma has been reported from Japan.^[15] Tuberculous splenic abscess has been reported in a known case of ITP. The patient was a 14-year-old male, on steroids for his ITP, who developed a tuberculous splenic abscess.^[16] Thrombocytopenia has also been found with tuberculous lymphadenitis.^[17]

Effective ATT and appropriate immunomodulatory therapy (steroids/IVIG) are both important in the management of ITP associated with TB.^[6]

Tuberculosis is a great public health problem with a variety of manifestations. Some, like anemia and leucopenia, are well known. Rare manifestations like myelofibrosis,^[1] ITP, hemophagocytic syndrome have also been documented. Tuberculosis infection can thus act as a trigger for ITP in susceptible individuals. However, the mechanism of ITP in TB is not clearly defined.^[4] In our patient, timely recognition of the associated phenomenon of ITP enabled prompt management of the isolated thrombocytopenia with IVIG. Optimization of ATT was essential in view of the disseminated disease. However, it was challenging in view of the thrombocytopenia and then because of the ATT-induced hepatitis.

To summarize, a variety of hematological abnormalities occur in the context of tuberculosis. These may respond to ATT, or require adjuvant (and expensive) immunomodulatory therapy, or else mandate a change in the treatment regimen. This has obvious implications on potential complications of disseminated tuberculosis, cost of treatment, and also on optimization of chemotherapy with respect to the choice of drugs and duration of use. ITP is a rare but potentially treatable hematological manifestation of tuberculosis, and should be considered among possible causes of thrombocytopenia in tuberculosis.

REFERENCES

1. Avasthi R, Mohanty D, Chaudhary SC, Mishra K. Disseminated tuberculosis: interesting hematological observations. *J Assoc Physicians India* 2010;58:243-4.
2. Boots RJ, Roberts AW, McEvoy D. Immune thrombocytopenia complicating pulmonary tuberculosis: Case report and investigation of mechanisms. *Thorax* 1992;47:396-7.
3. Morris CD, Bird AR, Nell H. The haematological and biochemical changes in severe pulmonary tuberculosis. *Q J Med* 1989;73:1151-9.
4. Kashyap R, Chaudhary VP. Haematological manifestations of tuberculosis. In, Sharma SK, Mohan A (eds). *Tuberculosis*. New Delhi, Jaypee Brothers Medical Publishers (P) Ltd.; 2006;370-79.
5. Jurak SS, Aster R, Sawaf H. Immune thrombocytopenia associated with tuberculosis. *Clin Pediatr (Phila)* 1983;22:318-9.
6. Kalra A, Kalra A, Palaniswamy C, Vikram N, Khilnani GC, Sood R. Immune thrombocytopenia in a challenging case of disseminated tuberculosis: A case report and review of the literature. *Case Report Med* 2010;2010:946278.
7. Yadav TP, Mishra S, Sachdeva KJ, Gupta VK, Siddhu KK, Bakshi G, *et al.* Pancytopenia in disseminated tuberculosis. *Indian Pediatr* 1996;33:597-9.
8. Psaila B, Bussel JB. Immune thrombocytopenic purpura. *Hematol Oncol Clin North Am* 2007;21:743-59, vii. Review.
9. al-Majed SA, al-Momen AK, al-Kassimi FA, al-Zeer A, Kambal AM, Baaqil H. Tuberculosis presenting as immune thrombocytopenic purpura. *Acta Haematol* 1995;94:135-8.
10. Ursavas A, Ediger D, Ali R, Köprücüoğlu D, Baççetepe D, Kocamaz G, *et al.* Immune thrombocytopenia associated with pulmonary tuberculosis. *J Infect Chemother* 2010;16:42-4.
11. Verma SK. Thrombocytopenic Purpura with Pulmonary Tuberculosis: A Case Report. *Internet J Pulm Med* 2008. Available from: <http://www.ispub.com/journal/the-internet-journal-of-pulmonary-medicine/volume-9-number-2/thrombocytopenic-purpura-with-pulmonary-tuberculosis-a-case-report.html>.
12. Ghobrial MW, Albornoz MA. Immune thrombocytopenia: a rare presenting manifestation of tuberculosis. *Am J Hematol* 2001;67:139-43.
13. Cockcroft DW, Donevan RE, Copland GM, Ibbott JW. Miliary tuberculosis presenting with hyponatremia and thrombocytopenia. *Can Med Assoc J* 1976;115:871-3.
14. Akyildiz B, Uzel N, Yanni D, Citak A, Karaböcüoğlu M, Uçsel R. Immune thrombocytopenic purpura associated with pulmonary tuberculosis. *Turkish J Pediatr* 2009;51:271-4.
15. Maejima H, Arai S, Ebata T, Takeda H, Kusunoki M, Katsuoka K. Tuberculous gumma associated with idiopathic thrombocytopenic purpura: report of a Japanese female patient. *J Dermatol* 2007;34:86-91.
16. Sinha N, Gupta N, Jhamb R. Idiopathic thrombocytopenic purpura with isolated tuberculous splenic abscess. *Singapore Med J* 2009;50:e41-3.
17. Bakhshi S, Kabra M, Iyer VK, Arya LS. Thrombocytopenic purpura as a presenting manifestation of tubercular lymphadenitis. *Indian J Pediatr* 2003;70:993-4.

How to cite this article: Dagaonkar RS, Udwadia ZF. Disseminated tuberculosis with immune thrombocytopenic purpura. *Lung India* 2012;29:63-5.

Source of Support: Nil, **Conflict of Interest:** None declared.