

# Multifocal Electroretinography after High Dose Chloroquine Therapy for Malaria

Aline Correa de Carvalho<sup>1</sup>, PhD; Martin Schwarz<sup>2</sup>, MS; Givago da Silva Souza<sup>1,3</sup>, PhD  
Bruno Duarte Gomes<sup>3</sup>, PhD; Alexandre Antônio Marques Rosa<sup>1</sup>, MD, PhD  
Ana Maria Revoredo da Silva Ventura<sup>4</sup>, MD, PhD; José Maria de Souza<sup>4</sup>, MD, PhD  
Luiz Carlos de Lima Silveira<sup>1,3</sup>, MD, PhD; Jan Kremers<sup>2,5,6</sup>, PhD

<sup>1</sup>Núcleo de Medicina Tropical, Universidade Federal do Pará, Belém, Pará, Brazil

<sup>2</sup>Department of Ophthalmology, University Hospital Erlangen, Erlangen, Germany

<sup>3</sup>Instituto de Ciências Biológicas, Universidade Federal do Pará, Belém, Pará, Brazil

<sup>4</sup>Instituto Evandro Chagas, Belém, Pará, Brazil

<sup>5</sup>Rhenovia Pharma SAS, Mulhouse, France

<sup>6</sup>School of Life Sciences, University of Bradford, Bradford, UK

**Purpose:** To investigate changes in multifocal electroretinography (mfERG) parameters associated with high dose chloroquine therapy for treatment of malaria in the Amazonia region of Brazil.

**Methods:** Forty-eight subjects who had received chloroquine treatment for single or multiple malaria infections with a cumulative dose ranging from 1,050 to 27,000mg were included. The control group consisted of 37 healthy aged-matched subjects. Data was collected on amplitude and implicit time of the N1, P1 and N2 waves in the central macular hexagon (R1) and in five concentric rings at different retinal eccentricities (R2-R6).

**Results:** No significant difference was observed in any mfERG parameter between chloroquine treated patients and control subjects. A comparison with previous data obtained from patients with rheumatologic disorders in the same region of Brazil who had received larger cumulative doses of chloroquine and had displayed mfERG changes, indicated that retinal toxicity seems to be dependent on cumulative dose.

**Conclusion:** Lack of mfERG changes in the current study suggests that intensive high dose chloroquine therapy for treatment of malaria is not associated with retinal toxicity.

**Keywords:** Chloroquine; Malaria; Rheumatic Diseases; Retinal Degeneration; Multifocal Electroretinography

*J Ophthalmic Vis Res* 2013; 8 (3): 193-198.

**Correspondence to:** Prof. Givago da Silva Souza. Núcleo de Medicina Tropical, Av. Generalíssimo Deodoro 92 (Umarizal), 66055-240 Belém, Pará, Brazil.; Tel: +55 91 3201 6819, Fax: +55 91 3241 0032; email: givagosouza@ufpa.br

**Received:** July 12, 2012

**Accepted:** November 27, 2012

## INTRODUCTION

Chloroquine and its analogue, hydroxychloroquine, are widely prescribed for rheumatologic disorders,<sup>1</sup> but were originally used for prophylaxis and treatment of malaria.<sup>2</sup> These drugs may cause retinopathy with a predominant feature of progressive maculopathy.

Different methods have been used to explore retinal dysfunction associated with chloroquine use.<sup>3-12</sup> Over the past two decades, multifocal electroretinography (mfERG) has become an important tool in studying chloroquine retinopathy because it reveals functional retinal integrity with spatial orientation.<sup>13-28</sup>

Relatively high doses of chloroquine are prescribed over a few days for treatment of malaria. In Brazil, malaria caused by *Plasmodium vivax* is treated by a total chloroquine dose of 1,500 mg over three days.<sup>29</sup> Although the total dose per treatment may be low in malaria patients, several treatments after repeated infections may be necessary leading to a large cumulative dose. Thus, the regimen for chloroquine treatment is different in patients with malaria and those with rheumatologic disorders. It remains unknown whether treatment regimen, apart from cumulative dose, affects functional retinal integrity.

To our knowledge, the effects of high daily doses of chloroquine on mfERG have not been previously published. Malaria patients can be studied as a model to evaluate the acute effects of chloroquine on retinal function. Additionally, it is unknown if the disease process per se has an influence on chloroquine induced retinopathy.

In the present study, we evaluated mfERG in patients with malaria who had received high dose chloroquine therapy. We compared mfERG in these patients with tracings obtained from healthy subjects.

## METHODS

This study included 48 patients (39 male and 9 female subjects) with mean age of  $33.6 \pm 11.8$  years who had received chloroquine for treatment of malaria, and 37 healthy matched controls (22 male and 15 female subjects) with mean age of  $33.9 \pm 11.2$  years.

All patients had malaria infections caused by *Plasmodium vivax*. The standard therapy included chloroquine (600 mg) plus primaquine (30 mg) on the first day followed by 450 mg of chloroquine and 30 mg of primaquine on the second and third days. On the fourth to seventh day, only primaquine (30 mg) was administered.<sup>29</sup> Therefore, the total dose of chloroquine was 1,500 mg at the end of the one week treatment period. For the purpose of this study, we calculated total dose and total dose per kilogram (kg) of body weight.

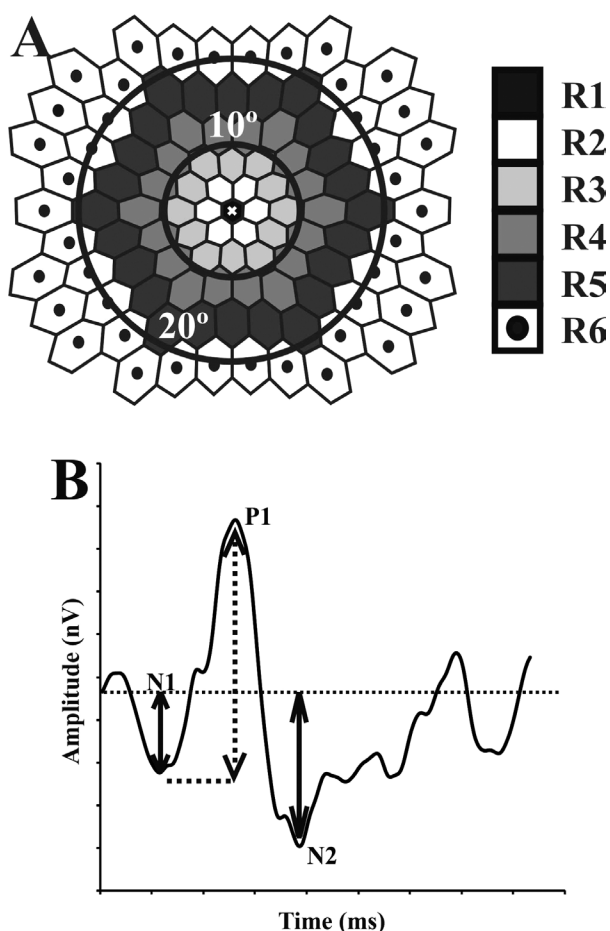
Control subjects had no history of degenerative disease and had never taken

chloroquine as an antimalarial agent or for treatment of rheumatologic disorders. They had best corrected visual acuity of at least 20/30, no ocular disorders and clear media as documented by an ophthalmologist. All controls agreed to participate in the study which adhered to the tenets of the Declaration of Helsinki and was approved by the Committee of Ethics in Research with Humans of the Tropical Medicine Nucleus, Federal University of Pará, Brazil.

Recordings were performed on one eye of each subject using a portable mfERG system controlled by RETIscan Science 4.0.0.4 (Roland Consult, Brandenburg, Germany). The protocol was in accordance with the guidelines of the International Society of Clinical Electrophysiology of Vision (ISCEV). All patients received a drop of 2.5% phenylephrine and 1% tropicamide to achieve maximal mydriasis. A drop of proxymetacaine chloride was instilled for topical anesthesia. Corneal DTL electrodes were used as active electrodes and were referenced by surface gold cup electrodes placed at the temporal canthus. Surface gold cup electrodes placed on the forehead were used as ground electrodes. The contralateral eye was occluded during recording. All measurements were performed at the Evandro Chagas Institute (Belém, State of Pará, Brazil).

A computer-controlled monitor was used to display the stimulus containing 103 hexagons (total visual angle of 25°). The distortion factor was 1:4. An m-sequence with exponent 15 was used to present a luminance modulation from less than 1 cd/m<sup>2</sup> (dark areas) to 200 cd/m<sup>2</sup> (bright areas). Recordings were performed under room lighting and took approximately 12 minutes. The test was paused on patient request. A cross (52' of visual angle) at the center of the display was used as the fixation point. If artifacts were observed (such as those caused by eye movements or blinks), the recording was interrupted and the test was restarted earlier in the m-sequence, after the potential returned to baseline levels.

The recordings were amplified (x 100,000), band-pass filtered between 5-100 Hz, and digitized at 1 KHz. First-order kernels were generated by the software. The recordings were



**Figure 1.** mfERG stimulus and analysis. (A) A 103 hexagonal array was used to elicit mfERG responses. The responses were averaged according to six concentric rings. The central hexagon was ring # 1 (R1). (B) An example of a response waveform is shown together with definitions of mfERG components. N1 and N2 amplitudes were measured from baseline to the respective troughs; P1 amplitude was defined as the voltage difference between N1-trough to P1-peak.

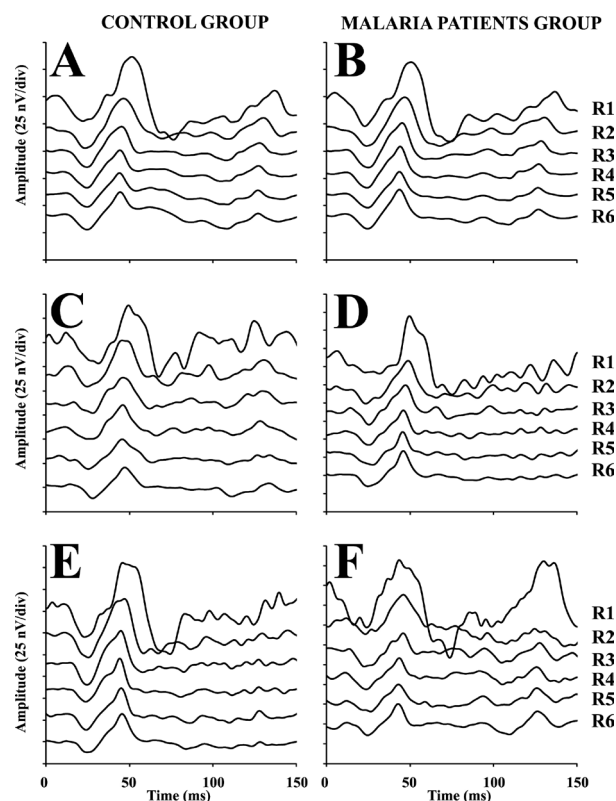
averaged in six concentric rings of hexagons (ring #1 being the central hexagon; Fig. 1). We analyzed the amplitude and implicit time of the mean waveform from each ring. N1 Amplitude was defined as the voltage difference between baseline and the negative peak in a time window between 15 to 45 milliseconds (ms). P1 amplitude was the difference between the N1 trough and P1 peak (occurring between 35 and 75 ms). N2 amplitude was the voltage difference between baseline and the negative peak in the time window between 50 to 125 ms (Fig. 1). We also measured the component amplitude ratio of each ring to ring #6 in order

to decrease interindividual variability.

Results are reported as mean values and standard errors. We used a two-way ANOVA ( $\alpha = 0.05$ , Bonferroni correction post-hoc test) to compare controls to malaria treated patients in the evaluation of mfERG parameters. The linear correlation coefficient ( $r$ ) was used to evaluate the correlation between mfERG parameters with total chloroquine dose and total dose per kg of body weight.

## RESULTS

The number of malaria infections ranged from 1 to 18 episodes in the patient group and mean cumulative chloroquine dose was  $5,429 \pm 782.3$  (range, 1,050 to 27,000) mg. The cumulative dose normalized to body mass varied from 14.58 to 545.45 mg/kg. Figure 2 shows mfERG responses in all six rings averaged from individuals in the control group (A) and in patients treated for



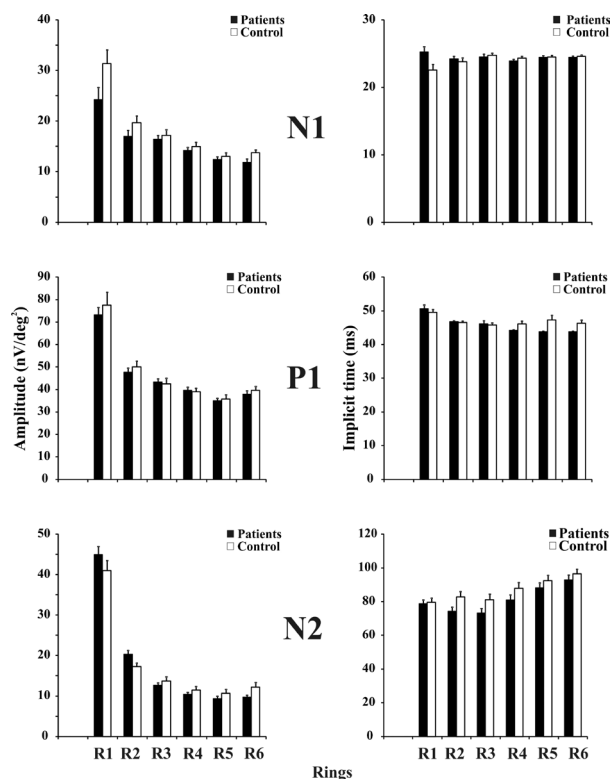
**Figure 2.** mfERG waveforms from controls and malaria patients. A-B: Mean waveforms for each of the six rings in the control group (A) and malaria patients (B). C-F: Recordings from single control subjects (C and E) and single malaria patients (D and F).

malaria (B). In addition, recordings from two individual control subjects (Figures 2C and E) and from two patients (Figures 2D and F) are displayed.

No significant difference was observed between chloroquine treated patients and controls in any mfERG parameter including N1, P1 and N2 amplitudes and implicit times at all eccentricities (Fig. 3). The ratio of amplitudes in each ring to the amplitude in ring #6 was also comparable between the groups.

No correlation was observed between cumulative dose or cumulative dose per kg of body weight, and amplitudes of the mfERG components ( $P>0.05$ ).

## DISCUSSION



**Figure 3.** Amplitudes (left column) and implicit times (right column) for different mfERG components at different rings, plotted separately for controls (open bars) and malaria patients (closed bars). Values for N1, P1 and N2 components are displayed in the upper, middle and lower plots respectively. None of the amplitudes and implicit times differed significantly between the two study groups.

Although the mechanism of chloroquine retinopathy remains unclear, there is ample evidence suggesting functional changes in the retina.<sup>30,31,32</sup> mfERG is a modality that can be used to monitor visual function following chloroquine therapy. This technique has revealed that the central and paracentral retina are mainly affected by long term administration of chloroquine and hydroxychloroquine.<sup>14,17,20-22,26-28</sup> However, diffuse retinal damage has also been reported.<sup>19,21,23</sup>

In Brazil, patients with malaria receive relatively high daily, but low cumulative, chloroquine doses and can therefore serve as a model to study the acute effects of chloroquine on the visual system. Moreover, the effect of repeated treatments after recurrent malarial infections could also be studied.

Previously, a histological study on the retina of macaques exposed to chloroquine showed alterations in retinal ultrastructure before changes could be observed by retinal examination and/or electroretinographic abnormalities could be recorded.<sup>30</sup> The earliest change was retinal ganglion cell degeneration after acute chloroquine intake for one week. Long-term exposure to chloroquine showed degeneration of photoreceptors and the retinal pigment epithelium (RPE). In the human retina, chronic exposure to chloroquine leads to histopathological changes especially in retinal ganglion cells and also in the inner plexiform layer, inner nuclear layer, photoreceptors and RPE.<sup>32</sup>

Optical coherence tomography (OCT) findings have also indicated that long-term chloroquine users with clinical symptoms have thinning of the outer nuclear layer in the parafoveal area.<sup>33,34</sup> Retinal changes have also been observed in OCT images of patients without clinical signs.<sup>35,36</sup> These changes were observed in the outer retina and retinal nerve fiber layer.

The malarial disease itself might cause retinopathy in subjects with severe manifestations of the disease as in cerebral malaria.<sup>37</sup> In the present study, none of the patients had severe or cerebral malaria.

To our knowledge, the present study is the first to investigate the effect of acute chloroquine



intake for treatment of malaria on mfERG parameters. We observed no changes in mfERG parameters in patients receiving high dose chloroquine for malaria. Our results contrast with that reported by Raster and colleagues<sup>28</sup> on the effects of chloroquine administered for rheumatologic indications on mfERG parameters in the same region of Brazil. The latter study reported decrements in amplitudes of the N1, P1, and N2 components in the macular region. As in other studies, the above-mentioned study<sup>28</sup> included cumulative doses that were on average 50 times larger than those employed in the current series. Therefore, mfERG changes seem to be dependent on the cumulative dose of chloroquine or hydroxychloroquine rather than acute high doses. This is consistent with previous reports on a correlation between mfERG changes and cumulative doses when high chloroquine doses are used.<sup>20,22,27,28</sup>

Based on our results, the acute regimen of chloroquine intake and the malarial disease itself are not associated with retinal toxicity. In the present study, follow-up was tenuous at best because the patients came to the Evandro Chagas Institute to receive medicine during the treatment period and subsequently returned to their remote villages.

### Acknowledgements

This work was supported by CAPES / DAAD PROBRAL #182/2007; CNPq / BMBF / IB-DLR #490857/2008-6; CNPq / FAPESPA PRONEX #2268 and #316799/2009; CNPq #620037/2008-3, #476744/2009-1, #475860/2010-1, and #479500/2011-8; and FINEP / UFPA / FADESP #1723 (IBN Net). JK is a Fellow in the Excellence Program of the Hertie Foundation. LCLS is a CNPq research fellow. ACC received a CNPq fellowship for graduate students.

### Conflicts of Interest

None.

### REFERENCES

1. Page F. Treatment of lupus erythematosus with mepacrine. *Lancet* 1951;2:755-758.
2. Most H, London IM, Kane CA, Lavietes PH, Schroeder EF, Hayman Jr JM. Chloroquine for treatment of acute attacks of vivax malaria. *J Am Med Assoc* 1946;131:963-967.
3. Henkind P, Carr RE, Siegel IM. Early chloroquine retinopathy: clinical and functional findings. *Am J Ophthalmol* 1964;71:157-165.
4. Carr RE, Henkind P, Rothfield N, Siegel IM. Ocular toxicity of antimalarial drugs. Long-term follow-up. *Am J Ophthalmol* 1968;66:738-744.
5. Easterbrook M. Ocular effects and safety of antimalarial agents. *Am J Med* 1988;85:23-29.
6. Ventura DF, Silveira LCL, Nishi M, Costa MF, Gualtieri M, Santos RMA, et al. Color vision loss in patients treated with chloroquine. *Arq Bras Oftalmol* 2003;66:9-15.
7. Fishman GA. Retinal toxicity with the use of chloroquine and hydroxychloroquine. In: Heckenlivley JR, Arden GB (eds). Principles and Practice of Clinical Electrophysiology of Vision. St. Louis: Mosby; 1991:594-599.
8. Arden GB, Fojas MR. Electrophysiological abnormalities in pigmentary degenerations of the retina. *Arch Ophthalmol* 1962;68:369-389.
9. Arden GB, Friedmann A, Kolb H. Anticipation of chloroquine retinopathy. *Lancet* 1962;1:1164-1165.
10. Kolb H. Electro-oculogram findings in patients treated with antimalarial drugs. *Br J Ophthalmol* 1965;49:573-590.
11. Weiner A, Sandberg MA, Gaudio AR, Kini MM, Berson EL. Hydroxychloroquine retinopathy. *Am J Ophthalmol* 1991;112:528-534.
12. Tzekov RT, Serrato A, Marmor MF. ERG findings in patients using hydroxychloroquine. *Doc Ophthalmol* 2004;108:87-97.
13. Maturi RK, Folk JC, Nichols B, Oetting TT, Kardon RH. Hydroxychloroquine retinopathy. *Arch Ophthalmol* 1999;117:1262-1263.
14. Kellner U, Kraus H, Foerster MH. Multifocal ERG in chloroquine retinopathy: regional variance of retinal dysfunction. *Graefes Arch Clin Exp Ophthalmol* 2000;238:94-97.
15. Penrose PJ, Tzekov RT, Sutter EE, Fu AD, Allen AW Jr, et al. Multifocal electroretinography evaluation for early detection of retinal dysfunction in patients taking hydroxychloroquine. *Retina* 2003;23:503-512.
16. So SC, Hedges TR, Schuman JS, Quireza MLA. Evaluation of hydroxychloroquine retinopathy with multifocal electroretinography. *Ophthalmic Surg Lasers Imaging* 2003;34:251-258.
17. Maturi RK, Yu M, Weleber RG. Multifocal

- electroretinographic evaluation of long-term hydroxychloroquine users. *Arch Ophthalmol* 2004;122:973-981.
18. Moschos MN, Moschos MM, Apostolopoulos M, Mallias JA, Bouros C, Theodossiadis GP. Assessing hydroxychloroquine toxicity by the multifocal ERG. *Doc Ophthalmol* 2004;108:47-53.
  19. Tzekov RT, Serrato A, Marmor MF. ERG findings in patients using hydroxychloroquine. *Doc Ophthalmol* 2004;108:87-97.
  20. Lai TY, Chan WM, Li H, Lai RY, Lam DS. Multifocal electroretinographic changes in patients receiving hydroxychloroquine therapy. *Am J Ophthalmol* 2005;140:794-807.
  21. Kellner U, Renner AB, Tillack H. Fundus autofluorescence and mfERG for early detection of retinal alterations in patients using chloroquine/hydroxychloroquine. *Invest Ophthalmol Visual Sci* 2006;47:3531-3538.
  22. Lai TY, Ngai JW, Chan WM, Lam DS. Visual field and multifocal electroretinography and their correlations in patients on hydroxychloroquine therapy. *Doc Ophthalmol* 2006;112:177-187.
  23. Lyons JS, Severns ML. Detection of early hydroxychloroquine retinal toxicity enhanced by ring ratio analysis of multifocal electroretinography. *Am J Ophthalmol* 2007;143:801-809.
  24. Halfeld Furtado de Mendonça R, Maia OO Jr, Yukihiko Takahashi W. Electrophysiologic findings in chloroquine maculopathy. *Doc Ophthalmol* 2007;115:117-119.
  25. Chang WH, Katz BJ, Warner JE, Vitale AT, Creel D, Digre KB. A novel method for screening the multifocal electroretinogram in patients using hydroxychloroquine. *Retina* 2008;28:1478-1486.
  26. Lyons JS, Severns ML. Using multifocal ERG ring ratios to detect and follow Plaquenil retinal toxicity: a review: Review of mfERG ring ratios in Plaquenil toxicity. *Doc Ophthalmol* 2009;118:29-36.
  27. Xiaoyun MA, Dongyi HE, Linping HE. Assessing chloroquine toxicity in RA patients using retinal nerve fiber layer thickness, multifocal electroretinography and visual field test. *Br J Ophthalmol* 2010;94:1632-1636.
  28. Raster M, Horn F, Jünemann A, Rosa AA, Souza GS, Gomes BD, et al. Retinal disorders in northern Brazilian patients treated with chloroquine assessed by multifocal ERG. *Doc Ophthalmol* 2011;122:77-86.
  29. Saude BMd, Saude FNd. Manual de terapeutica da malaria. 6th ed. Brasil: Ministerio da Saude; 2001.
  30. Rosenthal AR, Kolb H, Bergsma D, Huxsoll D, Hopkins JL. Chloroquine retinopathy in the rhesus monkey. *Invest Ophthalmol Vis Sci* 1978;17:1158-1175.
  31. Toler SM. Oxidative stress plays an important role in the pathogenesis of drug-induced retinopathy. *Exp Biol Med (Maywood)* 1978;229:607-615.
  32. Ramsey MS, Fine BS. Chloroquine toxicity in the human eye. Histopathologic observations by electron microscopy. *Am J Ophthalmol* 1972;73:229-235.
  33. Korah S, Kuriakose T. Optical coherence tomography in a patient with chloroquine-induced maculopathy. *Indian J Ophthalmol* 2008;56:511-513.
  34. Rodriguez-Padilla JA, Hedges TR 3rd, Monson B, Srinivasan V, Wojtkowski M, Reichel E, et al. High-speed ultra-high-resolution optical coherence tomography findings in hydroxychloroquine retinopathy. *Arch Ophthalmol* 2007;125:775-780.
  35. Kellner S, Weinitz S, Kellner U. Spectral domain optical coherence tomography detects early stages of chloroquine retinopathy similar to multifocal electroretinography, fundus autofluorescence and near-infrared autofluorescence. *Br J Ophthalmol* 2009;93:1444-1447.
  36. Xiaoyun MA, Dongyi HE, Linping HE. Assessing chloroquine toxicity in RA patients using retinal nerve fiber layer thickness, multifocal electroretinography and visual field test. *Br J Ophthalmol* 2010;94:1632-1636.
  37. Essuman VA, Ntim-Amponsah CT, Astrup BS, Adjei GO, Kurtzhals JA, Ndanu TA, et al. Retinopathy in severe malaria in Ghanaian children – overlap between fundus changes in cerebral and non-cerebral malaria. *Malar J* 2010;9:232.