




Taibah University

Journal of Taibah University Medical Sciences

www.sciencedirect.com



Case Report

Severe epistaxis in pregnancy due to nasal pyogenic granuloma: A case report



Johannas Mohd Yusof, MBBCh^{a,*}, Azwarizan Abd Halim, MD ORL-HNS^b and Aneesa Khairiyah Wan Hamizan, PhD^a

^a Department of Otorhinolaryngology-Head and Neck Surgery, Hospital Canselor Tuanku Muhriz UKM, Kuala Lumpur, Malaysia

^b Otorhinolaryngology Department, Hospital Tuanku Jaafar, Seremban, Malaysia

Received 17 January 2020; revised 21 June 2020; accepted 23 June 2020; Available online 20 July 2020

المخلص

يعتبر الرعاف الخفيف إلى الشديد شائعا خلال فترة الحمل. يحدث الرعاف في الحمل نتيجة زيادة الأوعية الدموية للغشاء المخاطي للأنف والتغيرات الهرمونية. ممكن أن تظهر الأعراض من غير وجود سبب موضعي واضح أو اضطراب جهازي. ولكن، التقييم الشامل للأنف والأذن والحنجرة مطلوب دائما. يعد الورم الحبيبي القيحي أو الورم الوعائي الشعري المفصلي من الأورام الليلية والعنائية التكاثرية الحميدة التي كثيرا ما تظهر على الوجه، والأصابع، والشفاة والغشاء المخاطي للأنف. الحمل المسبب للورم الحبيبي القيحي ليس نادرا ويمكن أن يؤدي إلى رعاف غزير، إذا لم يتم علاجه. يحتاج علاج حالة الرعاف الشديد أثناء الحمل عادة إلى فريق متعدد التخصصات. نقدم حالة رعاف شديد خلال الحمل، احتاجت إلى فحص التجويف الأنفي تحت التخدير العام. أظهرت النتائج أثناء العملية ورم أرجواني أزرق يحتل الجيب الفكي الأيمن للمريضة. تمكنا من إيقاف النزيف والوصول إلى التخثر الكامل. تبدد الورم الحبيبي القيحي الأنفي تماما في فترة ما بعد الولادة.

الكلمات المفتاحية: الحمل؛ الرعاف؛ الورم الحبيبي القيحي الأنفي؛ الورم الوعائي الشعري؛ العلاج متعدد التخصصات

Abstract

Mild to severe epistaxis is common in pregnancy and often results from increased vascularity of the nasal

mucosa and hormonal changes. Symptoms may occur in the absence of an obvious local cause or any systemic disorder; however, thorough otolaryngological (i.e., “ENT”) evaluation is always warranted. Pyogenic granuloma or lobular capillary haemangioma is a benign fibrovascular proliferative tumour that is commonly found on the face, fingers, lips, and nasal mucosa. Pregnancy-induced pyogenic granuloma is not an uncommon entity and may result in torrential epistaxis if untreated. Managing a case of severe epistaxis during pregnancy usually requires multidisciplinary management. The authors present a case of severe epistaxis in pregnancy that necessitated examination of the nasal cavity under general anaesthesia. Intraoperative findings showed a bluish-red mass occupying the patient’s right maxillary sinus. Bleeding was arrested and complete haemostasis was achieved. The nasal pyogenic granuloma completely resolved in the post-partum period.

Keywords: Capillary haemangioma; Epistaxis; Multidisciplinary management; Nasal pyogenic granuloma; Pregnancy

© 2020 The Authors.

Production and hosting by Elsevier Ltd on behalf of Taibah University. This is an open access article under the CC BY-NC-ND license (<http://creativecommons.org/licenses/by-nc-nd/4.0/>).

* Corresponding address: Department of Otorhinolaryngology-Head and Neck Surgery, Hospital Canselor Tuanku Muhriz UKM, Jalan Yaacob Latif, Bandar Tun Razak, 56000 WP Kuala Lumpur, Malaysia.

E-mail: drjohannas@gmail.com (J. Mohd Yusof)

Peer review under responsibility of Taibah University.



Production and hosting by Elsevier

Introduction

Lobular capillary haemangioma or pyogenic granuloma is a benign fibrovascular proliferative tumour occurring in both

children and adults. Occurrence during pregnancy is reported to be approximately 5%.¹ Based on a 10-year retrospective analysis of 155 cases by Koo et al., the predominant site for pyogenic granuloma is the face (30.3%), followed by the fingers (22.5%) and lip and oral cavity (10%). Nasal mucosa involvement is fairly common and has been reported to be as low as 1%² and as high as 33% of cases.³ Lopez et al. reported that the most common site for sinonasal pyogenic granuloma is the nasal septum, followed by the inferior turbinates.³ The occurrence of maxillary sinus pyogenic granuloma, however, has scarcely been reported.

Pregnancy is associated with up to 15% of nasal pyogenic granulomas,^{4,5} while a history of trauma was reported in 12% of these cases.⁴ Etiological factors for nasal pyogenic granuloma include increased or altered hormone activity (40%), previous injury to the nasal cavity (18%), and potential idiopathic disease in approximately 23% of cases.³ Some studies have also reported an increased frequency of pyogenic granuloma in patients with pre-existing skin conditions, including dermatitis, or vascular malformations such as hemangioma.^{4,5}

Case report

A 26-year-old primigravida at 35 weeks' gestation presented with persistent unilateral epistaxis, soaking more than one-half of her handkerchief. She claims to have experienced intermittent unprovoked epistaxis, which usually resolved spontaneously since entering her third trimester. She experienced rhinitis symptoms but denied any history of local trauma and no other bleeding tendencies. She reported a surgical history of right nasal polypectomy approximately 5 years previously.

Physical examination showed slow active oozing from the patient's right nostril; however, she was hemodynamically stable. First aid Trotter's manoeuvre with ice compression was attempted at the emergency department, and she was transferred to the authors' clinic for evaluation. Her epistaxis resolved after ice compression, thus enabling rigid nasal endoscopy to be performed, which showed clots over the lateral nasal wall. Initial complete blood count showed a haemoglobin level of 12.1 g/dl and platelet count of $206 \times 10^9/l$, with normal coagulation profile. She was admitted for observation; however, after 2 h in the ward, she experienced another active episode that was not resolved with compression. Accordingly, anterior nasal packing using Merocel (Medtronic Inc., Minneapolis, MN, USA) was performed and empirical intravenous (IV) amoxicillin clavulanate (Augmentin, GlaxoSmithKline, Brentford, United Kingdom) was started.

The packing was removed after 48 h; however, the patient experienced another episode of severe epistaxis that required both anterior and posterior nasal packing using a Foley's catheter. At this point, the patient experienced stage 1 hypovolemic shock and was resuscitated using 0.9% normal saline (IV, 10 ml/kg) over a 30 min period. After discussion between the obstetrician and patient, a decision was made for examination under anaesthesia to identify the source of epistaxis, and to secure haemostasis with the possibility of endoscopic sphenopalatine artery ligation. Differentials at this point included nasal pyogenic granuloma, bleeding nasal polyp, sinonasal tumour, and vascular malformation.

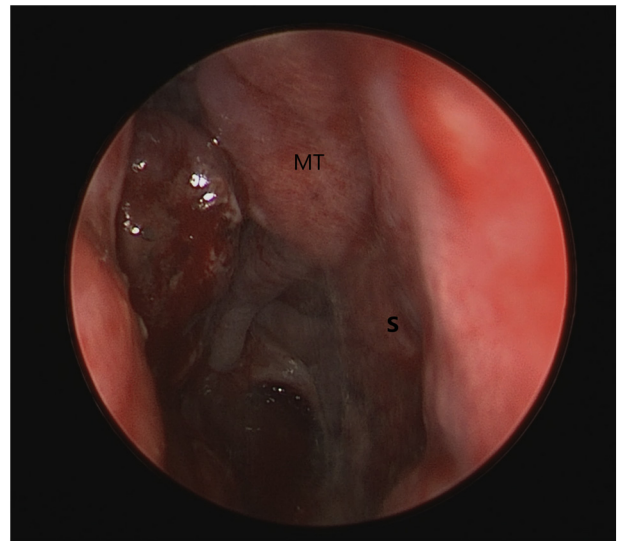


Figure 1: Endoscopic view of right nasal cavity with fleshy reddish mass arising from the lateral nasal wall. MT=middle turbinate, S=septum.

Intraoperatively, the nasal packing was removed, and rigid nasal endoscopy was performed. A fleshy reddish mass, measuring approximately 1 × 1 cm, was seen arising from the right lateral nasal wall adjacent to a widened maxillary antrum (Figure 1). On removal, the mass measured 1.0 × 1.5 cm and was sent for histopathological examination; however, it was reported to only be blood clots. A widened middle meatal antrostomy was evident, and a smooth bluish-red mass with active oozing arising from the anterior wall of the maxillary antrum was noted (Figure 2). The bleeding points were cauterized using suction diathermy, and an absorbable haemostat (Surgicel, Ethicon/Johnson & Johnson, Somerville, New Jersey, USA) was placed over the tissue to achieve haemostasis. Blood loss during the operation was estimated to be approximately 250 ml.

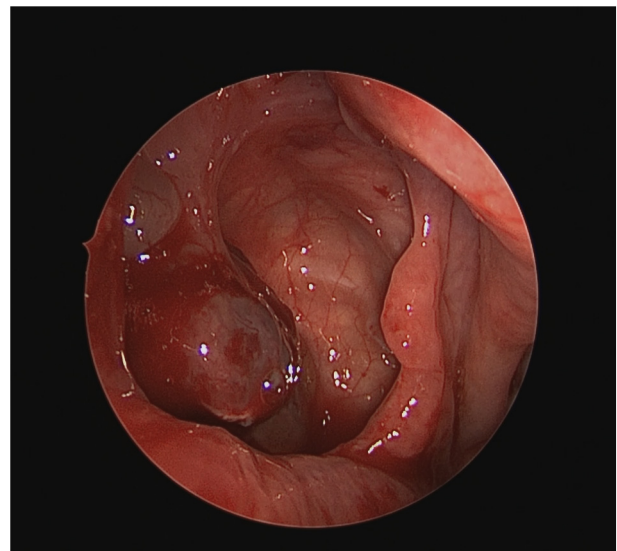


Figure 2: Evidence of previous widened middle meatal antrostomy with bluish-red mass at anterior wall of right maxillary sinus.

The patient recovered well during the immediate post-operative period. She experienced no recurrent epistaxis and was subsequently discharged at day 2 postoperatively. She was followed up 2 weeks later and subsequently at 1 month post parturition. During her last follow up, she denied any episodes of epistaxis or nasal obstruction. Rigid nasal endoscopy showed complete resolution of the previously observed lesion within the right maxillary sinus.

Discussion

Pregnancy granuloma or granuloma gravidarum are among other terms for lobular capillary haemangioma occurring in pregnancy. It is the most common vascular lesion of the nasal cavity.⁶ In one of the largest case series investigating lobular capillary haemangioma, the lesion occurs more in women, with a ratio of 2:1, and at a mean age of 45 years.³ The majority of patients present with epistaxis followed by nasal obstruction.

The aetiology of lobular capillary haemangioma is unclear; however, theories associated with hormonal components have been proposed because the lesion is commonly encountered in pregnant patients and those taking oral contraceptives.^{3,5} History of nasal injury is also a possible aetiology, ranging from 11 to 15% of nasal pyogenic granulomas.^{4,5} Some case reports have described the occurrence of nasal pyogenic granuloma after nasal surgery and nasal packing, which are believed to trigger an inflammatory reaction in response to the exposed mucosal surfaces.^{7,9} It is unusual for it to occur years after trauma, given that most reported cases occur within 1–2 months of injury; however, it is possible that our patient had been asymptomatic up until her first pregnancy due to hormonal changes, which have also been attributed to the pathophysiology of sinonasal pyogenic granuloma.³

Although the molecular mechanism of lobular capillary haemangioma regression post parturition is unclear, it has been proposed that it is due to a decrease in vascular endothelial growth factor levels post parturition.¹² Hence, it has been suggested that excision is indicated only in cases that fail to involute.⁸ Surgical excision is the preferred treatment for lobular capillary haemangioma of the nasal cavity. Other methods include electrocautery, laser therapy, and embolization. Recurrence can be as high as 40%, especially for lesions managed using cautery.⁴ Managing epistaxis in pregnancy can be difficult because some treatments may be contraindicated. Maternal safety needs to be prioritized with conservative measures being the first-line treatment(s).¹⁰ As described by Crunkhorn et al., chemical cautery with silver nitrate is safe in mild cases, as is anterior and posterior nasal packing(s); however, the use of bismuth iodoform paraffin paste-soaked ribbon gauze for nasal packing is contraindicated. If epistaxis is severe and conservative management fails, surgical intervention, such as vessel ligation, is feasible with consideration of the risks of general anaesthesia in pregnancy.¹⁰ Cocaine-based nasal preparations should be avoided due to well-known risks to the fetus.¹¹

In the present case, the patient underwent examination under anaesthesia due to severe epistaxis and no preoperative radiological investigation(s) could be performed. A clinical decision was made to manage the lesion conservatively to

achieve haemostasis with the possibility of second-look surgery post-partum. This was because there were no computed tomography imaging data to guide in terms of anatomical relations of the lesion to other important structures. There was also suspicion of it being a vascular lesion; hence, we did not want to risk profuse bleeding with subsequent harm to both patient and foetus. The diagnosis was made only in retrospect, after involution of the lesion post-partum.

In conclusion, epistaxis in pregnancy can be severe due to hormonal changes, with subsequent increase in nasal vascularity. Persistent severe epistaxis in pregnancy that is refractory to conservative treatment necessitates surgical treatment to achieve haemostasis. Although nasal pyogenic granuloma is a common benign cause of epistaxis in pregnancy and usually regresses post-partum, all pregnant patients with persistent epistaxis should be referred for otolaryngological (i.e., “ENT”) assessment to prevent significant morbidity.

Recommendation

The authors stress the importance of complete ENT assessment and evaluation in a pregnant patient presenting with recurrent or persistent epistaxis to the primary health care or obstetric physician.

Source of funding

This research did not receive any specific grant from funding agencies in the public, commercial, or not-for-profit sectors.

Conflict of interest

The authors have no conflict of interest to declare.

Ethical approval

No personal details or identifying information are included in this article. Consent was provided by the patient for the case report to be written and published. Ethics approval was not obtained from the authors' Clinical Research Center because it was not required for a case report.

Authors contributions

JMY collected necessary case information and wrote the original and final draft. AAH conceptualized the case report and its aims and reviewed the initial draft. AKWH provided critical review and editing of the case report. All authors have critically reviewed and approved the final draft and are responsible for the content and similarity index of the manuscript.

References

1. Kamal R, Dahiya P, Puri A. Oral pyogenic granuloma: various concepts of etiopathogenesis. *J Oral Maxillofac Pathol* 2012; 16(1): 79–82.

2. Koo MG, Lee SH, Han SE. Pyogenic granuloma: a retrospective analysis of cases treated over a 10-year. **Arch Craniofac Surg** 2017; 18(1): 16–20.
3. Lopez A, Tang S, Kacker A, Scognamiglio T. Demographics and etiologic factors of nasal pyogenic granuloma. **Int Forum Allergy Rhinol** 2016; 6.
4. Smith SC, Patel RM, Lucas DR, McHugh JB. Sinonasal lobular capillary hemangioma: a clinicopathologic study of 34 cases characterizing potential for local recurrence. **Head Neck Pathol** 2013; 7: 129–134.
5. Puxeddu R, Berlucchi M, Ledda GP, Parodo G, Farina D, Nicolai P. Lobular capillary hemangioma of the nasal cavity: a retrospective study on 40 patients. **Am J Rhinol** 2006; 20: 480–484.
6. Tamaki A, Babajanian E, D’Anza B, Rodriguez K. Lobular capillary hemangiomas: case report and review of literature of vascular lesions of the nasal cavity. **Am J Otolaryngol** 2017; 38(3): 363–366.
7. Lee HM, Lee SH, Hwang SJ. A giant pyogenic granuloma in the nasal cavity caused by nasal packing. **Eur Arch Oto-Rhino-Laryngol** 2002; 259: 231–233.
8. Ahmed F, Rouhani MJ, Navaratnam AV. Pyogenic granuloma gravidarum: a case in the nasal cavity and the use of MRI as a preoperative surgical aide. **BMJ Case Rep** 2019; 12:e225803.
9. Forte D, Irañeta AS, Nabais A, Figueiredo A, Mafra M, Gonçalves V. Nasal lobular capillary hemangioma as a complication after an endoscopic transsphenoidal gonadotrophin-producing pituitary adenoma resection. **J Neurol Surg Rep** 2017; 78(1): e59–e61.
10. Crunkhorn REM, Mitchell-Innes A, Muzaffar J. Torrential epistaxis in the third trimester: a management conundrum. **Case Rep** 2014; 2014. bcr2014203892.
11. Meyer KD, Zhang L. Short- and long-term adverse effects of cocaine abuse during pregnancy on the heart development. **Adv Cardiovasc Dis** 2009; 3(1): 7–16.

How to cite this article: Mohd Yusof J, Abd Halim A, Wan Hamizan AK. Severe epistaxis in pregnancy due to nasal pyogenic granuloma: A case report. *J Taibah Univ Med Sc* 2020;15(4):334–337.