

# The Anatomical Subunit Approach to Managing Tessier Numbers 3 and 4 Craniofacial Clefts

Aaron C. Van Slyke, MD, MSc,  
FRCSC\*  
Jonathan Burge, MBBS, FRACS\*  
Ria Bos, BSN†  
Gary Parker, DDS, FDSRCS†  
David K. Chong, MBBS,  
FRACS\*,†

**Background:** Patients with atypical facial clefts are rare, and there is a paucity of literature outlining the surgical approach to managing these patients. The anatomical subunit approach to the surgical correction of the cleft lip has revolutionized cleft care. Here, we outline our approach and operative technique to treating Tessier clefts 3 and 4 using a novel technique based on the anatomical subunit approach.

**Methods:** All cases of Tessier facial clefts 3 and 4 between 2019 and 2021 from the senior author's practice were reviewed retrospectively. Patient demographics, clinical presentation, procedure details, and complications are reported. The senior author's technique is described in detail.

**Results:** Five patients underwent treatment by the senior author during the study period. One patient had bilateral Tessier 4 clefts, one patient had bilateral Tessier 3 clefts, two patients had a unilateral Tessier 4 cleft, and one patient had a unilateral Tessier 3 cleft. Two of the patients had their clefts treated as secondary procedures. The surgical complication profile was a lost nasal stent in one patient. Treatment principles of the senior author's technique are presented.

**Conclusions:** The anatomical subunit approach to managing atypical facial clefts provides a structured approach to a complex problem for the cleft and craniofacial surgeon. The technique of repair presented here can assist surgeons attempting to treat patients with Tessier 3 and 4 clefts. (*Plast Reconstr Surg Glob Open* 2022;10:e4553; doi: 10.1097/GOX.0000000000004553; Published online 28 September 2022.)

## INTRODUCTION

Atypical facial clefts present with varying anatomical manifestations that have continued to intrigue craniofacial surgeons since Tessier's first detailed description.<sup>1</sup> The reconstructive task at hand is challenging, and the infrequency of presentation further compounds the issue. A predictable approach to repair based on knowledge of anatomy and sound plastic surgery principles is needed to address this complex problem.

Many approaches have been described for treating atypical facial clefts.<sup>2-9</sup> Surgical treatment with direct closure, local rotation flaps, use of tissue expansion, and Z-plasties have been proposed to manage these defects.<sup>2-9</sup> Although many craniofacial units have used these principles of treatment with reported success, a clear surgical

plan and concise description of their operative technique is lacking. This is in contrast to the literature on cleft lip repair, where the operative plan has been well documented. The anatomical subunit repair for cleft lip treatment has gained popularity since it was first introduced by Fisher.<sup>10,11</sup> Respecting aesthetic units, analyzing the geometry of an anatomical defect, placing opening incisions to elongate tissues, and planning triangles from areas of tissue excess to augment areas of tissue deficiency are also applicable to managing atypical facial clefts.<sup>12</sup>

Here, we describe a reconstructive method to treating atypical facial clefts using principles learned from the anatomical subunit cleft lip repair.<sup>10-12</sup> The incorporation of these concepts allows one to address tissue deficiencies along the cleft, while keeping scars hidden along aesthetic borders.

## METHODS

This is a retrospective chart review of all patients who received repair of their atypical facial cleft from the senior author (D.K.C.) between 2019 and 2021. Patients included in this series were operated on as part of a year-long surgical outreach on the Mercy Ship, with two patients repaired in Melbourne, Australia. The surgical set up to complex

From the \*Division of Plastic and Maxillofacial Surgery, Department of Surgery, Royal Children's Hospital, Melbourne, Victoria, Australia; and †Mercy Ships, Garden Valley, Tex.

Received for publication June 8, 2022; accepted August 3, 2022.

This work has not been previously presented at a public forum.

Copyright © 2022 The Authors. Published by Wolters Kluwer Health, Inc. on behalf of The American Society of Plastic Surgeons. This is an open-access article distributed under the terms of the [Creative Commons Attribution-Non Commercial-No Derivatives License 4.0 \(CCBY-NC-ND\)](https://creativecommons.org/licenses/by-nc-nd/4.0/), where it is permissible to download and share the work provided it is properly cited. The work cannot be changed in any way or used commercially without permission from the journal.

DOI:10.1097/GOX.0000000000004553

**Disclosure:** The authors have no financial interests to declare in relation to the content of this article. This research received no specific grant from any funding agency in the public, commercial, or not-for-profit sectors.

craniofacial procedures on the Mercy Ship is described elsewhere.<sup>13</sup> The senior author performed all aspects of the operation.

Patient records were retrospectively reviewed for age at time of surgery, gender, medical history, preoperative findings, date of surgery and postoperative follow-ups, intraoperative details, other facial procedures performed at the time, and complications.

This study was approved by the ethics committee at the Mercy Ships. Ethics was not required for the one case performed at the Royal Children’s Hospital, Melbourne, Australia. Patient consent for photography was obtained.

### TECHNIQUE

The procedure is performed under general anesthetic, with the patient in the supine position.

The commonalities of all procedures include:

1. Identify the side of the cleft that needs to be elongated and design incisions accordingly with the opening incision planned to camouflage within subunits.
2. Separation of posterior and anterior lamellae of the lower eyelid.
3. Reconstruction of the posterior lamella including medial canthoplasty where required.
4. Anterior lamella reconstruction with an extended cheek rotation flap.
5. Cheek rotation flap is bilaminar with wide subperiosteal undermining of the muscles of the face and skin, undermining from medial to lateral to allow redraping. Suspension of the muscle is in a supero-medial direction and is the foundation of the repair.
6. The limited skin undermining of the cheek rotation flap above the SMAS layer allows redraping of skin analogous to a reverse facelift.
7. Dissection is extensive to allow closure points to be along facial subunits with minimal tension.

Procedural details are as follows:

1. *Incision along the lateral and medial cleft margins.* When in doubt, incise along the cleft margins respecting that the lines of fusion between the skin and mucosa will

### Takeaways

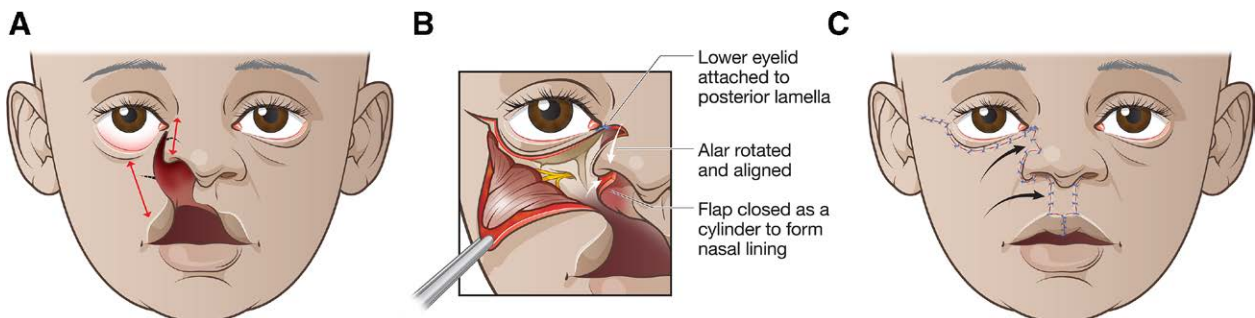
**Question:** Is it possible to create a consistent surgical approach to Tessier 3 and 4 craniofacial clefts?

**Findings:** We outline a surgical plan based on the following principles: (1) Incisions planned within anatomical subunits; (2) Skin discrepancies dealt with through the creation of triangular flaps on the side of skin excess; (3) Posterior lamella eyelid reconstruction as required; and (4) Large bilaminar cheek rotation flap to reposition the underlying musculature and allow tension-free skin closure.

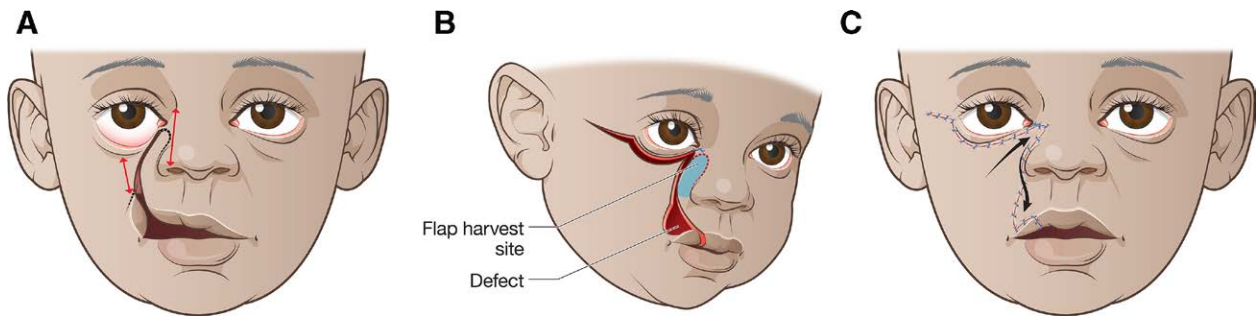
**Meaning:** A consistent surgical approach to Tessier 3 and 4 clefts is outlined using the principles of anatomic subunits.

always need to be separated and preserving as much tissue as possible by incising along this border.

2. *Lateral incision.* The incision is performed along the lateral margin of the cleft and is extended along the lower eyelid in a subciliary fashion. Variable extension into the temple skin is performed for the required tissue mobilization, with a Tessier 4 cleft needing the most lateral extension compared with a Tessier 3. The markings blend medially to reconstruct the cleft lip with the author’s preferred technique for cleft lip repair. Variations to the lateral cleft incision are further discussed below based on the Tessier 3 or 4 pattern. The incision designs for Tessier 3 and 4 patterns are shown in [Figures 1](#) and [2](#), respectively.
3. *Lateral muscle flap elevation.* The muscles of the face are elevated in a subperiosteal plane from medial to lateral, along the zygomatic bone up to the zygomaticofrontal (ZF) suture extending into the orbital floor and around the convexity of the body to achieve adequate mobilization while respecting the infraorbital nerve. The strength and vector of the repair relies on sufficient mobilization of this layer. In a Tessier cleft 3, this dissection commences supraperiosteally for the first 5 to 10 mm before transitioning subperiosteal. The aim here is to leave behind a periosteal sleeve along the lateral cleft margin that can be used to anchor the nasal base to later in the procedure.



**Fig. 1.** The anatomical subunit repair of the Tessier 3 cleft. Tissue discrepancies along the cleft margin are demonstrated, showing a deficiency of tissue along the medial margin and an excess of tissue along the lateral cleft margin (A). Extent of subperiosteal dissection demonstrated, posterior lamella reconstruction, ala derotation, nasal lining reconstruction using medial cleft tissue. Medial advancement of the deep tissues of the face hold the strength of the repair (B). Closure with the overlying skin flap laid down tension free (C).



**Fig. 2.** The anatomical subunit repair of the Tessier 4 cleft. Tissue discrepancies along the cleft margin are demonstrated, showing an excess of tissue along the medial cleft margin and a deficiency of tissue along the lateral cleft margin (A). Defect above suprawhite roll demonstrated after derotation of lip, and paranasal flap design using tissue excess along medial cleft margin (B). Paranasal flap rotation and closure (C).

4. *Lateral skin flap elevation.* Elevation is performed using facelift scissors in a plane above the superficial musculoaponeurotic system. This dissection is performed in a “reverse facelift” fashion to create separate skin and muscle flaps so that the skin flap can be redraped without tension, after the muscle has been suspended.
5. *Medial cleft dissection.* The medial margin of the cleft is incised and the skin and deep tissues are elevated up to the medial canthus attachment point. Dissection is varied based on the Tessier 3 and 4 pattern as described below.
6. *Posterior lamella reconstruction and medial canthus suspension.* The medial canthus is reconstructed as per the surgeon’s preferred technique. In the setting where the upper lid is in the correct position, the senior author has found that there is often enough lower lid medial canthal remnant medially to dissect free and repair directly to canthal remnant from the lateral lower lid. In this setting, the superior suture approximating the posterior lamella is performed with a 5-0 Monocryl suture. The rest is closed with interrupted 6-0 plain gut suture with the knots away from the conjunctivae. Otherwise medial canthal reconstruction is undertaken with the favored canthoplasty technique.
7. *Tessier 3 variation (Fig. 1).* When planning the incisions for repair of a Tessier 3 cleft, one must be cognizant that there is an excess of tissue along the lateral border of the cleft and a paucity of tissue along the medial border of the cleft. The medial cleft dissection is carried in the subperiosteal plane posterior to the piriform to free the mucosa of the nose completely and allow lining reconstruction. The restricted ala is released with an opening incision within the supra alar crease to rotate the ala caudally into its correct anatomical position. This is a full thickness incision through skin and nasal lining. An anchoring suture with PDS is used to suture the alar base caudally, with the correct vector, to the preserved periosteum of the maxilla to create symmetry to the alar orientation of the other side. The resulting defect in the skin within the supra alar crease is then filled with a triangle designed from the lateral cleft tissue, similar to that seen in the anatomical subunit cleft lip repair.<sup>10</sup> The lining will require a similar advancement triangle from the mucosa liberated from

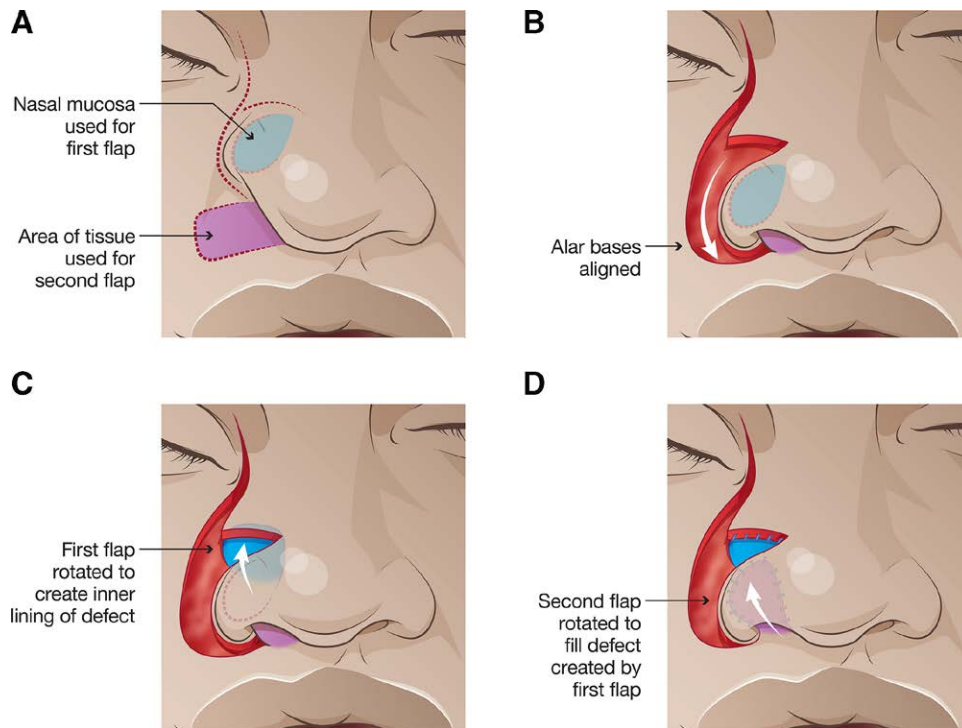
the floor of the nose. An alternative is also shown for secondary cases where a skin flap can be used to replace nasal lining (Fig. 3).

8. *Tessier 4 variation (Fig. 2).* In designing the incisions along the Tessier 4 cleft, the vertically shortened tissue is on the lateral side; so the opening incision to elongate the lateral tissue margin is above the suprawhite roll of the lateral lip element—rotating the lateral lip caudally. An inferiorly based triangle is designed using the excess medial tissues immediately lateral to the nose and rotated down to fill the defect above the white roll of the lateral lip element, up to the commissure. This triangle conveniently mimics the nasolabial fold subunit, as well as allowing the line of closure to approximate the nasal subunit.
9. *Closure.* Muscle is closed with a 5-0 prolene suture. Excess skin is marked and excised, and then the skin flap is laid down with minimal tension analogous to a facelift. Nasal lining and skin closure is performed based on the surgeon’s preference. A nasal stent constructed from a silicone sheet is placed in both nares and secured with a 4-0 nylon suture to support the nasal structure. This is removed on the fifth postoperative day at the same time as the suture removal.

## RESULTS

A total of five patients underwent repair of their atypical facial cleft by the senior author. Our study population consisted of two female and three male patients with an average age of 12.4 years at the time of surgery, with a range of 3 months to 46 years old. The age range is variable as the majority of these patients were treated on the Mercy Ships. One patient had bilateral Tessier 4 clefts (complete on the right and incomplete on the left), one patient had bilateral Tessier 3 clefts (complete on the right and incomplete on the left), two patients had unilateral Tessier 4 clefts, and one patient had a unilateral Tessier 3 cleft. Our population was generally healthy, with no patients having a systemic medical condition. Two patients had their clefts treated as secondary procedures—that is, they had previously undergone treatment of their cleft elsewhere. One patient had a complication in the form of a lost nasal stent.

Figure 4 shows representative preoperative (A, B) and postoperative (C, D) photographs of a 10-month-old boy.



**Fig. 3.** Modification for secondary reconstruction of the Tessier 3 cleft. Tissue origin of flaps used to create the nasal lining (A). Derotation of the ala after backcut along the alar groove (B). Reconstruction of nasal lining defect using nasal mucosa flap from nasal lining of ala (C). Reconstruction of secondary nasal lining defect using skin flap (D).

This patient presented with a complete Tessier 3 cleft on the right side, incomplete Tessier 3 cleft on the left, and bilateral upper eyelid colobomas. He underwent reconstruction as a primary procedure. His postoperative course was complicated by a lost nasal stent that had no negative sequelae. Figure 5 shows representative preoperative (A) and postoperative (B) photographs of an 8-month-old girl. This patient presented with a complete Tessier 4 cleft on the right side and incomplete Tessier 4 cleft on the left. She underwent reconstruction as a primary procedure. Her postoperative course was uneventful. Figure 6 shows representative preoperative (A, B) and postoperative (C, D) photographs of a 14-year-old boy with a right-sided Tessier 3 cleft. He presented years after having his cleft repaired at another institution. He underwent reconstruction as a secondary procedure using the modification for nasal skin lining shown in Figure 3. His postoperative course was uneventful.

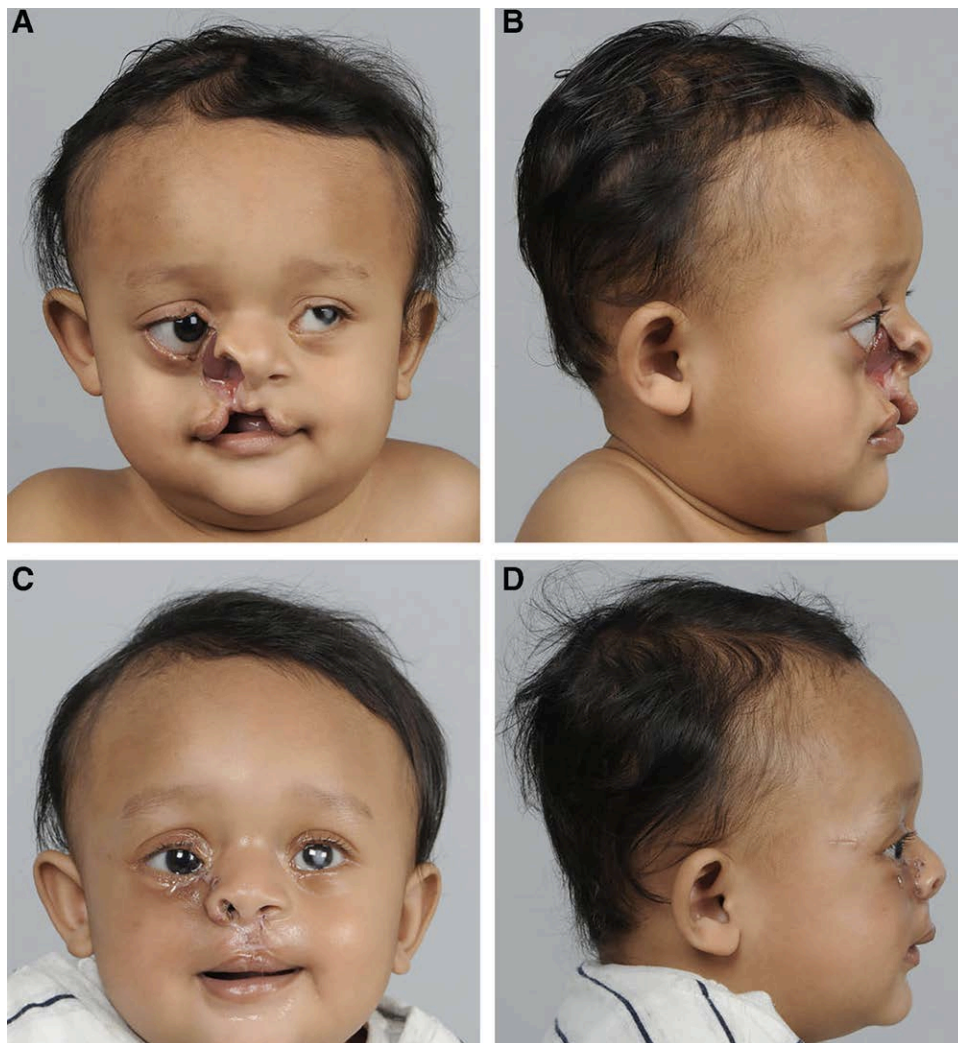## DISCUSSION

Atypical facial clefts remain a complex surgical challenge that besets the craniofacial surgeon. Tessier's first description of these clefts has stood the test of time.<sup>1</sup> The soft tissue description of the Tessier 3 cleft starts superiorly through the lacrimal portion of the lower eyelid and proceeds around the alar base within the naso-labial groove, terminating inferiorly as a cleft lip.<sup>1</sup> The soft tissue portion of a Tessier 4 cleft begins superiorly through the central portion of the lower eyelid, then extends inferiorly, lateral to the nasal ala and exits through the lip lateral to the Cupid's bow.<sup>1</sup>

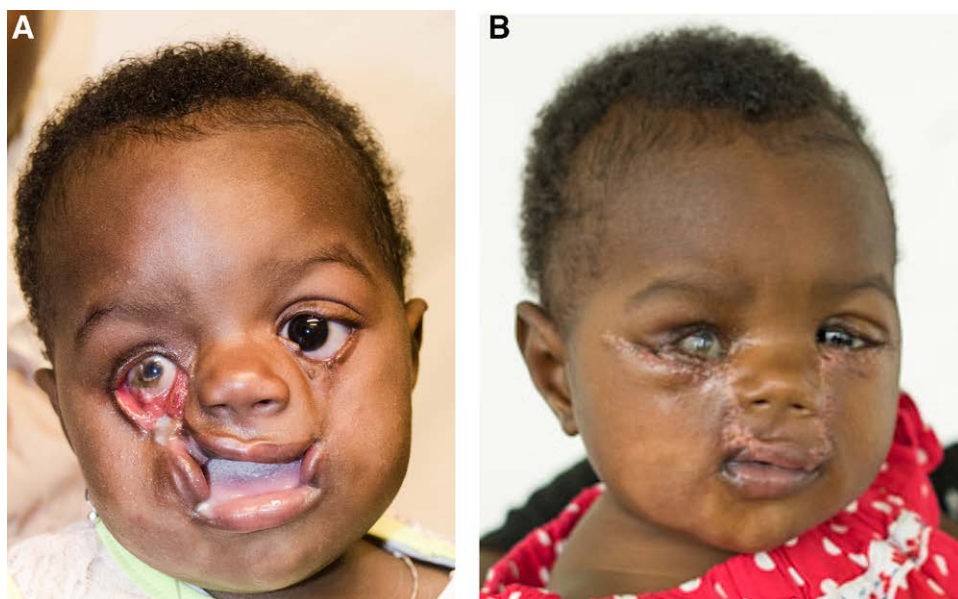Although these original anatomical descriptions have held true over the years, detailed knowledge of the anthropometrics of Tessier 3 and 4 clefts is lacking.<sup>14</sup> Despite this, there are clear differences in skin heights along the medial and lateral margins of the Tessier 3 and 4 clefts that are significant in how these clefts should be repaired. The tissue deficiency within the Tessier 3 cleft lies along the medial cleft margin; as such, the nasal soft tissues are constricted (Fig. 1A). Tissue excess in a Tessier 3 cleft is found along the cheek on the lateral cleft margin (Fig. 1A). With the Tessier 4 cleft, the tissue deficiency and excess is opposite to that seen with the Tessier 3 cleft (Fig. 2A). Tissue excess lies along the medial cleft margin, but the nose is in the correct position (Fig. 2A). Tissue deficiency within the Tessier 4 cleft is in the cheek skin on the lateral cleft margin, constricting the lower eyelid and causing ectropion (Fig. 2A). Tissue excess can be unfurled from the skin next to the nose on the medial cleft margin (Fig. 2A).

With these tissue discrepancies in mind, and applying principles learned from the anatomical subunit repair for cleft lips, one can address these discrepancies along the cleft margins using a triangle on the side of tissue excess, and an opening incision bordering anatomical subunits on the side of skin deficiency.<sup>10</sup> In the Tessier 3 cleft, the opening incision is placed within the supra alar crease and the triangle is designed using the skin excess along the lateral cleft margin. In designing the incisions along the Tessier 4 cleft, the opening incision is above the suprawhite roll of the lateral lip element to

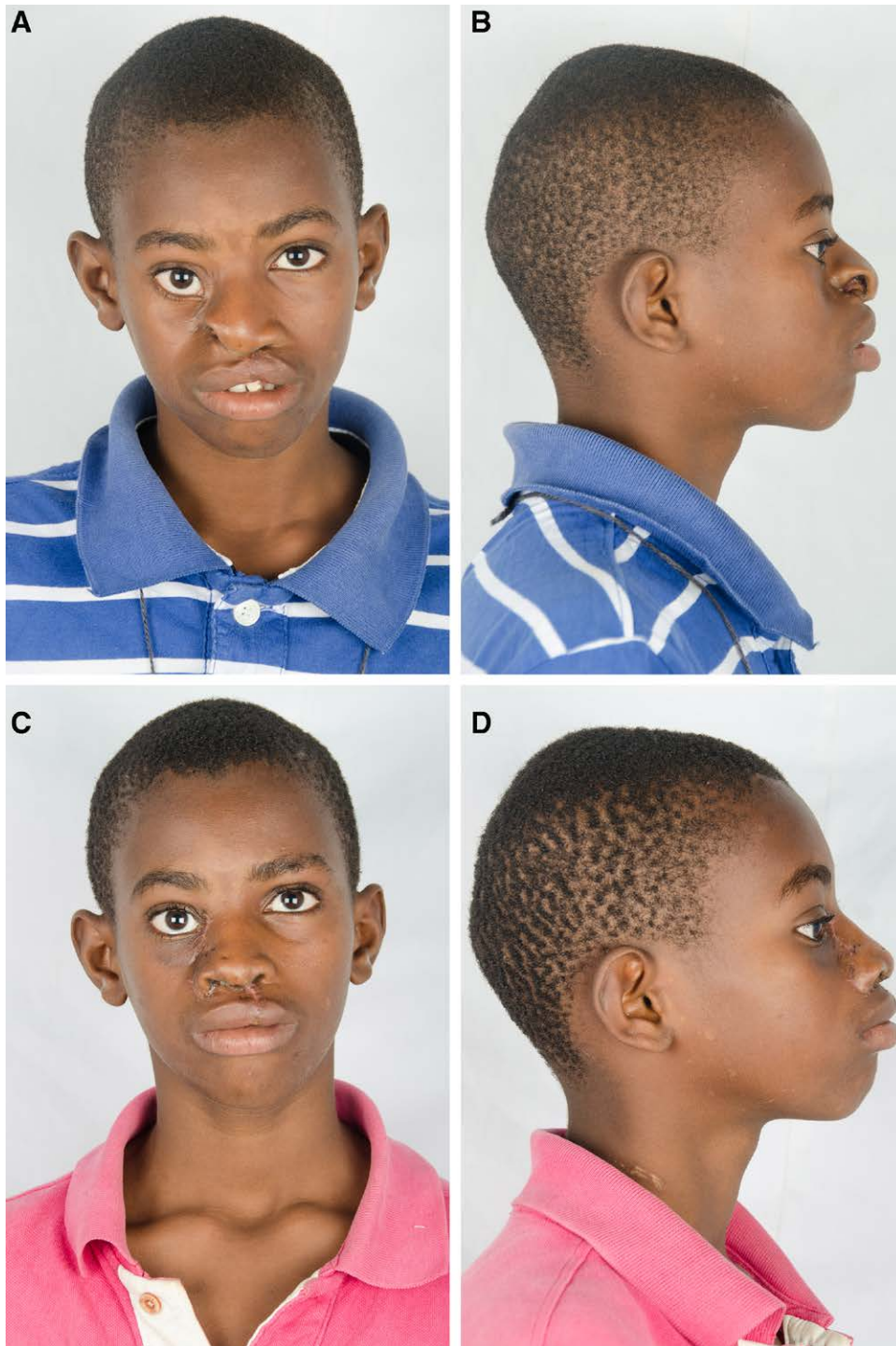




**Fig. 4.** Preoperative photographs of a 10-month-old boy with a bilateral Tessier 3 cleft, complete on the right and incomplete on the left (A, B). Postoperative photographs of the same patient 2 weeks after repair (C, D).



**Fig. 5.** Preoperative photograph of an 8-month-old girl with a bilateral Tessier 4 cleft, complete on the right and incomplete on the left (A). Postoperative photograph of the same patient 1 month after repair (B).



**Fig. 6.** Preoperative photographs of a 14-year-old boy with a right Tessier 3 cleft that was previously repaired at another institution (A, B). Postoperative photographs of the same patient 2 months after repair (C, D).

rotate the lateral lip caudally. The inferiorly based triangle is then taken from the skin excess along the medial margin of the cleft and used to fill the defect above the white roll of the lateral lip element, similar to that seen in the anatomical subunit cleft lip repair.<sup>10</sup> This excess skin rotated downward also helps control the shape of the nose, and allows the seam of closure to lie closer to the nasal subunit.

Various groups have published their treatment philosophy and approach to atypical facial clefts.<sup>2-9</sup> Monasterio and Taylor presented a large series of 495 major craniofacial clefts, in which they applied their revised treatment philosophy to 280 of these patients.<sup>2</sup> By the generous use of tissue expanders, placement of scars within anatomic boundaries, and symmetrically reconstructing facial landmarks with tissue of like color and texture, the authors have been able to reduce



their incidence of facial asymmetry and visible scars post repair.<sup>2</sup> Chen and colleagues reported a series of 14 patients who underwent repair of Tessier clefts 3 and 4 over a 35 year period; they compared patients who received Z-plasty closure over the cleft to those who received rotation advancement flap closure.<sup>3</sup> By repositioning the abnormal facial muscular insertions, and creating large skin rotation advancement flaps, Chen and colleagues have been able to improve the aesthetics of their results.<sup>3</sup> In a series of 21 patients treated by Alonso et al, the authors describe their treatment approach to Tessier 4 clefts.<sup>4</sup> Similarly, they have found improved success by the use of local flaps and the placement of scars within anatomical boundaries.<sup>4</sup> Recently, Morgan and colleagues have suggested that a repair based on anthropometrics of the deformity is needed to mask the stigma of the Tessier 3 cleft; they present a case report to demonstrate this.<sup>5</sup> Still, despite the literature, little is found to help technically guide the surgeon. Hence, we present a step-by-step description to managing these complex patients using principles learned from the anatomical subunit cleft lip repair.

Our series builds off of these previously published concepts.<sup>2-5</sup> In addition, we have incorporated the use of triangles and opening incisions seen in the anatomical subunit repair of cleft lips.<sup>10</sup> With wide subperiosteal undermining and bilaminar dissection, we postulate that incisions can be closed along anatomic subunits and the use of flaps outside the ones described are not necessary. We also encourage the procedure to be done between 3 months and 2 years of age to take advantage of the tissue elasticity of infancy. Taken together, we have developed the following principles and have applied these to the repair of Tessier 3 and 4 clefts with acceptable aesthetic results:

1. Anatomical points and incisions are planned so that the scars are within anatomical boundaries.
2. Skin discrepancies are dealt with through the creation of triangular flaps on the side of skin excess, and the placement of these flaps into opening incision within anatomical borders on the side of skin deficiency.
3. Posterior lamella reconstruction and medial canthus resuspension is achievable.
4. Large bilaminar cheek rotation flaps to reposition the underlying musculature into the appropriate superomedial vector of closure, and then redraping the skin without tension. The cheek rotation flap is larger in a Tessier 4 compared with a Tessier 3 cleft.
5. Where a patient has a bilateral asymmetrical cleft, the complete cleft side is closed first, and then the incomplete side is closed to match the complete side.

This study was limited by its retrospective nature and small sample size. The follow-up period for these patients is shorter than desired. It has been challenging to obtain longer follow-up given that the majority of these patients were treated in low resource settings. While we have been pleased with the short term results using this technique, longer follow-up is required to determine the evolution of postoperative morphology with growth. We are in the process of collecting further data.

Using the above principles, we have been able to treat patients with Tessier 3 and 4 clefts. The anatomical

subunit repair for atypical facial clefts has allowed us to achieve results with acceptable scar position and restoring facial balance, while preserving key facial landmarks. This approach can be applied in the academic and low resource setting, as four of the five patients presented here were treated on the Mercy Ships in low middle income countries.<sup>13</sup> We propose this approach to provide a clear surgical plan for the craniofacial surgeon to confidently close these challenging clefts.

**David K. Chong, MBBS, FRACS**

Division of Plastic Surgery, The Royal Children's Hospital  
Melbourne  
50 Flemington Rd  
Parkville, VIC 3052  
Australia  
E-mail: davidkchong@gmail.com

### ACKNOWLEDGEMENTS

*We gratefully acknowledge Mr. Bill Reid for his detailed illustrations.*

### PATIENT CONSENT

*Parents or guardians provided written consent for the use of the patients' image.*

### REFERENCES

1. Tessier P. Anatomical classification facial, cranio-facial and latero-facial clefts. *J Maxillofac Surg.* 1976;4:69-92.
2. Monasterio FO, Taylor JA. Major craniofacial clefts: case series and treatment philosophy. *Plast Reconstr Surg.* 2008;122:534-543.
3. Chen PK, Chang FC, Chan FC, et al. Repair of Tessier no. 3 and no. 4 craniofacial clefts with facial unit and muscle repositioning by midface rotation advancement without Z-plasties. *Plast Reconstr Surg.* 2012;129:1337-1344.
4. Alonso N, Freitas RDS, de Oliveira E Cruz GA, et al. Tessier no. 4 facial cleft: evolution of surgical treatment in a large series of patients. *Plast Reconstr Surg.* 2008;122:1505-1513.
5. Morgan AL, Cason R, El Amm CA. Anthropometrically-based surgical technique for Tessier 3 cleft reconstruction. *J Craniofac Surg.* 2016;27:e785-e787.
6. Aköz T, Erdoğan B, Görgü M, et al. Bilaterally involved Tessier No. 4 cleft: case report. *Cleft Palate Craniofac J.* 1996;33:252-254.
7. Allam KA, Lim AA, Elsherbiny A, et al. The Tessier number 3 cleft: a report of 10 cases and review of literature. *J Plast Reconstr Aesthet Surg.* 2014;67:1055-1062.
8. Longaker MT, Lipshutz GS, Kawamoto HK Jr. Reconstruction of Tessier no. 4 clefts revisited. *Plast Reconstr Surg.* 1997;99:1501-1507.
9. da Silva Freitas R, Alonso N, Busato L, et al. Oral-nasal-ocular cleft: the greatest challenge among the rare clefts. *J Craniofac Surg.* 2010;21:390-395.
10. Fisher DM. Unilateral cleft lip repair: an anatomical subunit approximation technique. *Plast Reconstr Surg.* 2005;116:61-71.
11. Tse R, Lien S. Unilateral cleft lip repair using the anatomical subunit approximation: modifications and analysis of early results in 100 consecutive cases. *Plast Reconstr Surg.* 2015;136:119-130.
12. Marcus JR, Allori AC, Santiago PE. Principles of cleft lip repair: conventions, commonalities, and controversies. *Plast Reconstr Surg.* 2017;139:764e-780e.
13. Munabi NC, Nagengast ES, Parker G, et al. A novel surgical technique for large frontocephalocele management: the mercy ships approach. *FACE.* 2021;2:82-88.
14. Omodan A, Pillay P, Lazarus L, et al. Scoping review of the morphology and anthropometry of Tessier craniofacial clefts numbers 3 and 4. *Syst Rev.* 2019;8:42.