

Received: 2017.11.08
Accepted: 2017.12.11
Published: 2018.01.09

Diffusion Tensor Imaging in Diagnosis of Post-Traumatic Syringomyelia in Spinal Cord Injury in Rats

Authors' Contribution:
Study Design A
Data Collection B
Statistical Analysis C
Data Interpretation D
Manuscript Preparation E
Literature Search F
Funds Collection G

ABEFG 1,2 **Chao Zhang***
CD 3,4 **Kai Chen***
DEFG 1 **Xiuxin Han***
CF 5 **Jiayuanyuan Fu**
EF 5 **Patricia Douglas**
AB 6 **Anna Y. Morozova**
ABC 2 **Maxim A. Abakumov**
BC 2 **Ilya L. Gubsky**
EG 7 **Dejin Li**
EG 7 **Jin Guo**
FG 4 **Xuening Zhang**
AG 1 **Guowen Wang**
AG 2,6 **Vladimir P. Chekhonin**

1 Department of Bone and Soft Tissue Tumors, Tianjin Medical University Cancer Institute and Hospital, National Clinical Research Center for Cancer, Key Laboratory of Cancer Prevention and Therapy, Tianjin, P.R. China
2 Department of Medicinal Nanobiotechnology, Pirogov Russian National Research Medical University, Moscow, Russian Federation
3 Department of Radiology, The Second Hospital of Tianjin Medical University, Tianjin, P.R. China
4 Department of Tumor Intervention, Tianjin 4th Centre Hospital, Tianjin, P.R. China
5 Tianjin Medical University, Tianjin, P.R. China
6 Department of Basic and Applied Neurobiology, Federal Medical Research Center for Psychiatry and Narcology, Moscow, Russian Federation
7 Tianjin Key Laboratory for Prevention and Control of Occupational and Environmental Hazards, Logistics University of The People's Armed Police Force, Tianjin, P.R. China

* These authors contributed equally to the study

Corresponding Authors:

Chao Zhang, e-mail: drzhangchao@tmu.edu.cn, Xuening Zhang, e-mail: luckyxn@126.com

Source of support:

The present study was sponsored by Natural Science Foundation of Tianjin Medical University (2016KYZQ10), the Natural Science Foundation of China (81702161), the Natural Science Foundation of Tianjin Science and Technology Committee China (17JCQNJC11000), and the Open Foundation of Tianjin Key Laboratory for Prevention and Control of Occupational and Environmental Hazards (WHKF201703)

Background: Post-traumatic syringomyelia (PTS) is a common disease after spinal cord injury (SCI). The present study was performed to evaluate the advantages of diffusion tensor imaging (DTI) in estimating SCI and prognosing PTS in SCI rats.





Material/Methods: Forty rats were divided into 3 groups based on the extent of the individual SCI and PTS: a control group (n=10), a PTS group (n=8), and an SCI group (n=22). BBB tests were performed preoperatively and postoperatively at (1 d, 3 d, 5 d, 1 w, 2 w, 1 w, 2 w, 3 w, 4 w, 5 w, and 6 w). MRI T2 scanning was conducted postoperatively at (1 w, 2 w, 3 w, 4 w, 5 w, 6 w). DTI and diffusion tensor tractography were used for analyzing neuro-fiber changes after SCI.

Results: BBB scoring showed no differences between the PTS group and SCI group (P<0.05). PTS was found in 8 rats after SCI. MRI showed PTS formation in 3 rats at 2 w after SCI, and 5 rats showed PTS formation at postoperative 3w after SCI. Compared with the control group, ADC showed significant increase in both the PTS group (P<0.05) and the SCI group (P<0.05), FA showed significant decreases in the PTS (P<0.05) and SCI (P<0.05) groups. Compared with the SCI group, the PTS group showed an increase in ADC, but no statistical difference was found in ADC (P>0.05). The PTS group showed a significant increase in FA (P<0.05).

Conclusions: The combination of diffusion tensor imaging and diffusion tensor tractography has characteristics of high-sensitivity and quantitation for PTS prognosis. FA is predictive in the prognosis of PTS formation after SCI.

MeSH Keywords: **Diffusion Tensor Imaging • Spinal Cord Injuries • Syringomyelia**

Full-text PDF: <https://www.medscimonit.com/abstract/index/idArt/907955>

 1835  6  3  21



Background

Spinal cord injury (SCI) can lead to the paralysis of sensory and motor function. SCI has been reported to cause global economic loss exceeding 4 billion dollars per year [1].

Post-traumatic syringomyelia (PTS) is the subsequent cystic degeneration of the spinal cord parenchyma post SCI. PTS is common at the primary injury site. Lesions occasionally invade adjacent segments [2]. A change in cerebrospinal fluid dynamics normally occurs as the fluid accumulates in the PTS. Increased spinal cord internal pressure may result in neurological deficits after SCI. The most common complaint in PTS is pain, and other symptoms include sensory deprivation, motor weakness, dysreflexia, hyperhidrosis, and sexual dysfunction [3]. Time of onset after SCI ranges from 2 months to 30 years [4].

Magnetic resonance imaging (MRI) is a standard method for PTS diagnosis. MRI images can accurately show the formation of PTS in the spinal cord after SCI [5]. Conventional MRI rarely detects pre-PTS lesion or early PTS formation. Diffusion tensor imaging (DTI) is a quantitative imaging strategy. DTI images are generated according to the diffusion of water molecules within the evaluated tissue [6]. DTI is more sensitive when evaluating and predicting the severity of the lesion site after SCI than is traditional MRI [7–9]. Diffusion tensor tractography (DTT) can be generated from DTI scans. When combined with quantitative DTI scans, DTT can effectively reveal the change in neuro-fibers at a lesion site after SCI.

Using a 7.0T MRI system, SCI rats were scanned pre- and post-operatively in the present study. The feasibility of PTS prognosis with DTI and DTT was evaluated by comparing images of rats with and without PTS after SCI.

Material and Methods

Animal grouping

Forty SD rats (all females, 200±25 g) were divided into 3 groups. The control group (n=10) had laminectomy without SCI. The other 30 SCI rats were divided into 2 groups after reviewing the MRI results. The PTS group (n=8) had PTS formation after SCI and the SCI group (n=22) did not have formation of PTS after SCI.

Experiments were carried out in compliance with the principles of International Laboratory Animal Care, and the European Communities Council Directive of 24 November 1986 (86/609/EEC), and were approved by the Ethics Committee of Pirogov Russian National Research Medical University. All efforts were made to minimize the number of animals used and to minimize their suffering.

Spinal cord injury model

Surgical laminectomies were conducted as previously reported [10–12]. Anesthetization was performed with an intraperitoneal injection of ketamine (50 mg/kg). The rats were placed prone on a warm pad. The dorsal fur was shorn by an electric razor. Iodophor and chlorhexidine were used to sterilize the surgical area. The dorsal surface of the rat was covered with a sterile drape. A thoracic 9–10 laminectomy was conducted. After exposing the spinal cord, an impact injury was induced with a force of 200 kilodynes using the PSI-IH Impactor (Precision Systems and Instrumentation LLC, Fairfax, VA). Ice-cold saline was used to flush the wound, and the surgical site was sutured. Injections of Baytril (2.5 mg/kg/d; Bayer, USA) were used on the animals to prevent potential infection. The animals were returned to cages after surgery. Twice-daily manual bladder expression was performed for animals until the recovery of spontaneous urinary function.

BBB score

Double-blind Basso, Beattie, and Bresnahan (BBB) locomotor tests were performed to evaluate the hind-limb motor changes (1 d, 3 d, 5 d, 1 w, 2 w, 3 w, 4 w, 5 w, 6 w).

MRI and DTI scan

All rats were anesthetized by isoflurane inhalation (5DG9621, BAXTER, USA) with the E-Z Anesthesia system (EZ-7000 330, PA, USA). MRI and DTI scans were performed weekly after SCI with a 7 Tesla animal MRI (ClinScan, Bruker BioSpin, USA). For coronal images, T2-weighted images in the coronal plane were acquired by Turbo Spin-Echo sequence with the following parameters: FOV 120×59.2mm, base resolution 320×158, TR=3850 ms, TE=39 ms, slice thickness 1 mm, number of acquisitions=1, and echo train length=9. For sagittal images, T2-weighted images in sagittal plane were acquired by Turbo Spin-Echo sequence with the following parameters: FOV 100×49.2 mm, base resolution 256×126, TR=3850 ms, TE=42 ms, slice thickness 1 mm, number of acquisition=3, and echo train length=9.

DTI images were taken with identical geometry as the MRI images using single shot spin-echo planar imaging (EPI) sequence with TR/TE of 4000 ms/88 ms, slice thickness of 3 mm, b factor of 1000 s/mm², bandwidth of 200 kHz, 25 gradient encoding directions, acquisition matrix of 64×64, and 10×10 mm field of view. To calculate the DTI indices, the collected images were analyzed on an offline workstation. DTT of the spinal cord was generated using the FACT algorithm, implemented in Volume-One software. Fractional anisotropy (FA) threshold <0.2 and stopping angle of >25° were used as parameters.

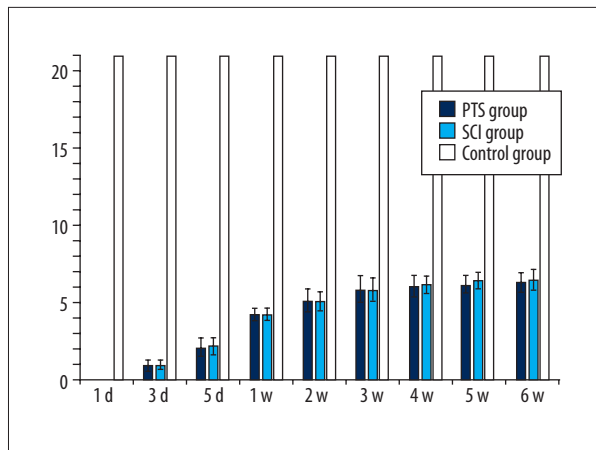


Figure 1. Postoperative BBB scores in all the groups.

Statistical analysis

All statistical analyses were performed using SPSS 17.0 software package (SPSS Inc., Chicago, USA). Results were considered to be statistically significant at $p < 0.05$. All data are presented as mean \pm standard error of the mean (SEM), and repeated-measures ANOVA (RANOVA) was used.

Results

Functional postoperative change

All rats showed normal BBB scores of 21 preoperatively. In both the PTS group and the SCI group, complete paraplegia was seen 24 h postoperatively with BBB scores of 0. In the control group, 1 individual scored a BBB of 19 at 24h postoperatively, but achieved a score of 21 at 3 days postoperatively. The phenomenon could have been mediated by soft-tissue edema and/or hematoma compression on the nerve root. The BBB score gradually increased in the PTS group and the SCI group postoperatively. As shown in Figure 1, at 5 weeks (w) after the operation, the recovery plateaued. BBB scores showed no statistical difference between the PTS group and SCI group. Postoperative BBB scores decreased significantly in PTS group ($p < 0.001$) and SCI group ($p < 0.001$) compared with the control group.

PTS formation after SCI

As shown in Figure 2, scar tissue can be seen at the surgical site at 2 w postoperatively in the control group, without positive symptoms of spinal cord injury. PTS was found in 8 SCI rats (26.7%). At 2 w after SCI, 3 rats showed signs of gradual PTS formation. The other 5 rats showed formation of PTS at 3 w after SCI. PTS formation was not found in the other 22 SCI rats at 6 w after the operation.

As shown in Figure 2, in the T2 weight MRI, high signal change is visible in the lesion site 1 w postoperatively. The fluid cavity started to form at 2 w postoperatively. The volume of the fluid cavity started to expand at 3 w postoperatively. Scar tissue was noted at the lesion site by 3 w postoperatively. The cavity volume continued expanded at 4 w to 5 w postoperatively. Further expansion was not noted at 6 w postoperatively.

Compared with the control group at 1 w, 2 w, 3 w, 4 w, 5 w, and 6 w postoperatively, ADC values significantly increased in the PTS group and SCI group, but FA values significantly decreased in the PTS and SCI groups. The ADC values from 1 w to 6 w postoperatively gradually decreased, while FA values gradually increased. The trend suggests a self-healing process in the rats after SCI.

Compared with the SCI group at different postoperative time points, ADC values in the PTS group were higher than those in the SCI group, but without statistical significance ($p > 0.05$). FA values in the PTS group were significantly higher than those in the SCI group ($p < 0.05$). (Tables 1–6).

As shown in Figure 3, spinal cord DTT is an effective strategy to track the neuro-fibers of the spinal cord. Well-organized spinal cord fiber tracking was observed in the control group, while the disruption of spinal cord neuro-fibers was seen in SCI rats. DTT clearly revealed the lack of continuity of neuro-fibers caused by the formed PTS.

Discussion

PTS is a chronic disease following SCI, which can be asymptomatic or associated with sensory disorders, autonomic dysreflexia, and/or neuropathic pain [2]. Several reported factors can lead to PTS formation. These include angiolysis, fluid dynamics change in cerebrospinal fluid, increasing penetration of perivascular space, and intensified inflammatory response [2,13]. A previous study suggested that astrocytes and/or ependymocyte compose the PTS cavity walls [14]. The cavities can be divided into 3 subtypes – central, split, and diffuse – based on the proliferative type of gliosis. The diffuse type of cavity was the most common after SCI in recent reports and in our previous study [10].

PTS is normally diagnosed with MRI. The incidence of PTS was reported to be 3.0–13.5% [2]. The differences in PTS formation were thought to be caused by the different origins of SCI onset. The present research suggests the incidence of PTS to be 26.7% after traumatic SCI. After reviewing previous studies and the current results, PTS formation is more likely to occur in severe SCI. However, there has been no conclusive evidence that PTS formation can affect behavioral ability. The present results concurred with those findings. Further research is warranted.

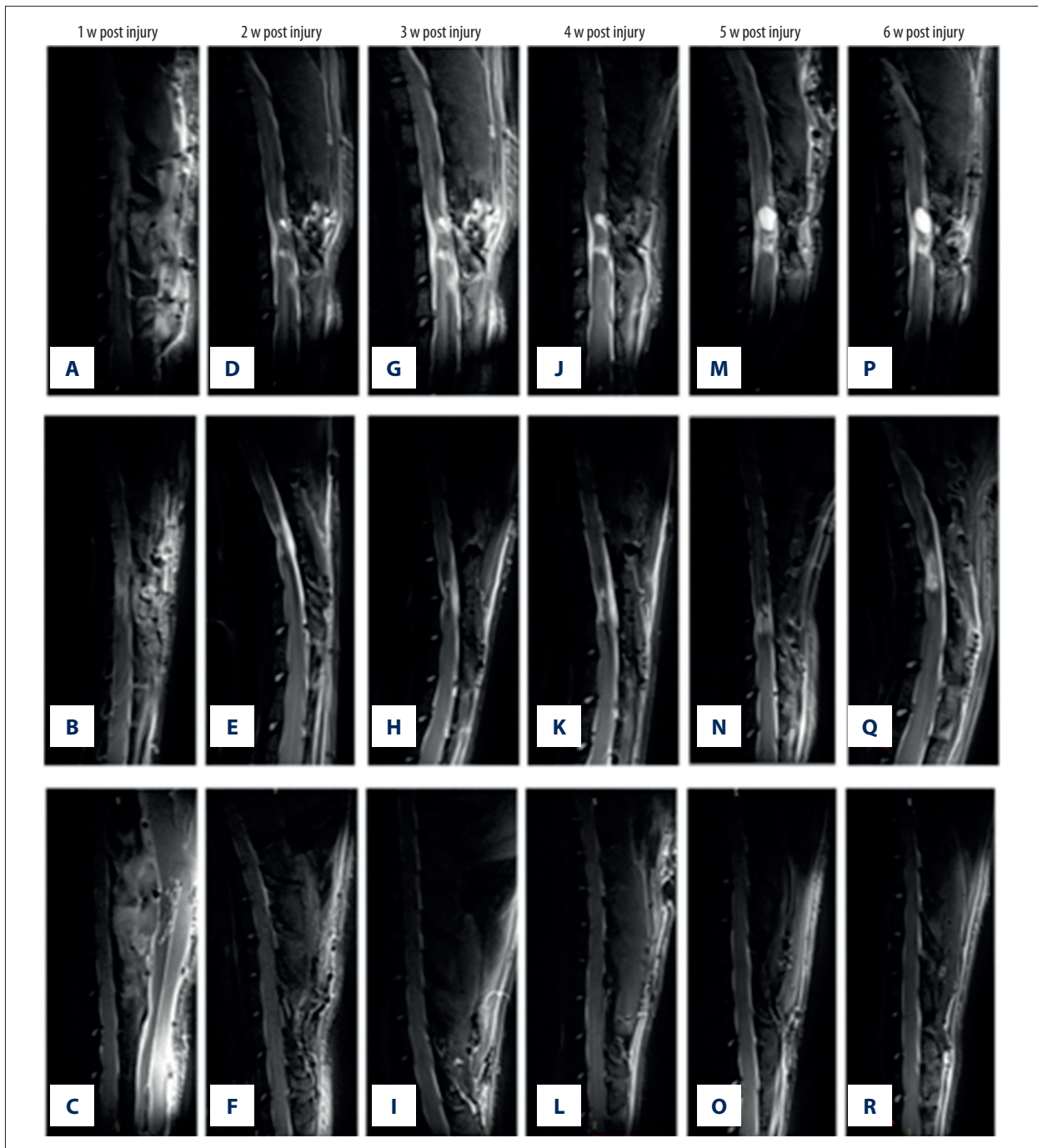


Figure 2. (A–R) Post-injury MRI T2 scanning in all groups (1 w, 2 w, 3 w, 4 w, 5 w, 6 w).

Conventional MRI is a widely accepted diagnostic technique for SCI. However, it can offer limited information on morphological and signal changes in the lesion site. Compared with conventional MRI, DTI can offer quantitative parameters for evaluating microstructural changes in the spinal cord after SCI. DTT can visualize the injury epicenter and the interrupted spinal cord tracts. DTI is a useful quantitative evaluation for nerve degeneration and axonal loss, as changes in axonal

structure can affect the diffusion of water molecules [15,16]. A series of studies have concluded that FA values decrease and ACD values increase at lesion sites after SCI [17,18]. The present results concurred with those findings. DTI and DTT, as the additional examination for conventional MRI, can offer clinicians more detailed information on tissue microstructural changes and depict the interrupted spinal cord tracts. Thus, we proposed the hypothesis that the combinative application

Table 1. ADC and FA value in groups at 1w postoperatively.

Group	ADC ($\times 10^{-6}$ mm ² /s)	FA
PTS group (n=8)	2239.44 \pm 750.97	0.49 \pm 0.09
SCI group (n=22)	2042.15 \pm 561.92	0.31 \pm 0.11
Control group (n=10)	1025.48 \pm 197.29	0.65 \pm 0.08

Table 2. ADC and FA value in groups at 2 w postoperatively.

Group	ADC ($\times 10^{-6}$ mm ² /s)	FA
PTS group (n=8)	2085.91 \pm 691.72	0.51 \pm 0.12
SCI group (n=22)	1924.74 \pm 817.39	0.32 \pm 0.07
Control group (n=10)	992.34 \pm 119.28	0.64 \pm 0.12

Table 3. ADC and FA value in groups at 3 w postoperatively.

Group	ADC ($\times 10^{-6}$ mm ² /s)	FA
PTS group (n=8)	1972.10 \pm 710.31	0.52 \pm 0.11
SCI group (n=22)	1788.72 \pm 539.47	0.32 \pm 0.11
Control group (n=10)	984.95 \pm 179.13	0.64 \pm 0.12

Table 4. ADC and FA value in groups at 4 w postoperatively.

Group	ADC ($\times 10^{-6}$ mm ² /s)	FA
PTS group (n=8)	1716.39 \pm 662.44	0.52 \pm 0.08
SCI group (n=22)	1601.26 \pm 703.81	0.33 \pm 0.09
Control group (n=10)	995.33 \pm 162.58	0.64 \pm 0.09

Table 5. ADC and FA value in groups at 5 w postoperatively.

Group	ADC ($\times 10^{-6}$ mm ² /s)	FA
PTS group (n=8)	1674.58 \pm 739.25	0.52 \pm 0.09
SCI group (n=22)	1588.49 \pm 610.88	0.34 \pm 0.08
Control group (n=10)	970.39 \pm 168.41	0.65 \pm 0.12

Table 6. ADC and FA value in groups at 6 w postoperatively.

Group	ADC ($\times 10^{-6}$ mm ² /s)	FA
PTS group (n=8)	1652.39 \pm 699.55	0.52 \pm 0.08
SCI group (n=22)	1582.39 \pm 651.29	0.34 \pm 0.07
Control group (n=10)	966.35 \pm 155.35	0.65 \pm 0.12

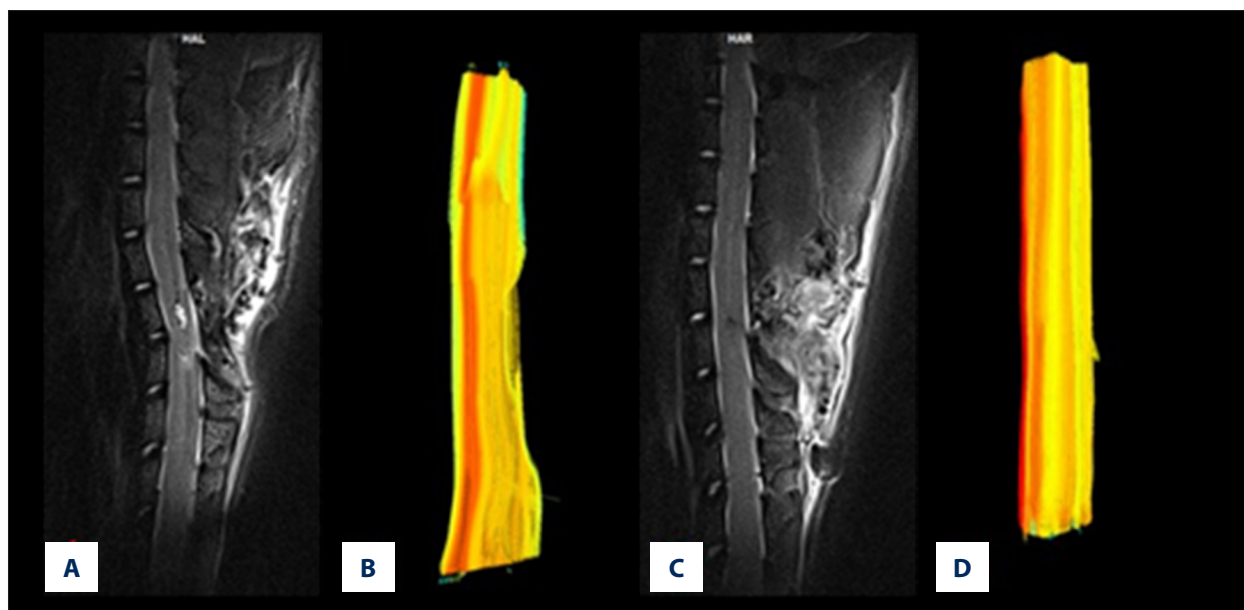


Figure 3. (A–D) Neuro-fibers tracking with spinal cord diffusion tensor tractography in the rats with/without SCI.

of conventional MRI, DTI, and DTT be effective in evaluation of SCI and PTS. This hypothesis concurs with the latest published clinical reports [19–21].

Utilizing the DTI and DTT technique, the present study confirmed FA and ADC values changes in PTS rats after SCI. ADC values showed no significant change in PTS rats after SCI. FA values showed significant decrease after SCI. FA values showed less decrease after SCI in rats with PTS formation than in individuals without post-SCI PTS.

The main limitation of the present study was the lack of sufficient sample size of PTS rats. The precise scope of FA values after SCI leading to PTS formation cannot be accurately calculated.

References:

1. Oliveri RS, Bello S, Biering-Sørensen F: Mesenchymal stem cells improve locomotor recovery in traumatic spinal cord injury: Systematic review with meta-analyses of rat models. *Neurobiol Dis*, 2014; 62: 338–53
2. Krebs J, Koch HG, Hartmann K et al: The characteristics of posttraumatic syringomyelia. *Spinal Cord*, 2016; 54(6): 463–66
3. Karam Y, Hitchon PW, Mhanna NE et al: Post-traumatic syringomyelia: Outcome predictors. *Clin Neurol Neurosurg*, 2014; 124: 44–50
4. Fehlings MG, Austin JW: Posttraumatic syringomyelia. *J Neurosurg Spine*, 2011; 14(5): 570–72
5. Lewis MJ, Cohen EB, Olby NJ: Magnetic resonance imaging features of dogs with incomplete recovery after acute, severe spinal cord injury. *Spinal Cord*, 2017 [Epub ahead of print]
6. Lewis M, Yap PT, McCullough S et al: The relationship between lesion severity characterized by diffusion tensor imaging and motor function in chronic canine spinal cord injury. *J Neurotrauma*, 2017 [Epub ahead of print]
7. D'souza MM, Choudhary A, Poonia M et al: Diffusion tensor MR imaging in spinal cord injury. *Injury*, 2017; 48(4): 880–84
8. Shah LM, Ross JS: Imaging of spine trauma. *Neurosurgery*, 2016; 79(5): 626–42
9. Cohen Y, Anaby D, Morozov D: Diffusion MRI of the spinal cord: From structural studies to pathology. *NMR Biomed*, 2017; 30(3)
10. Zhang C, Morozova AY, Abakumov MA et al: Precise delivery into chronic spinal cord injury syringomyelic cysts with magnetic nanoparticles MRI visualization. *Med Sci Monit*, 2015; 21: 3179–85
11. Zhang C, Kong X, Ning G et al: All-trans retinoic acid prevents epidural fibrosis through NF- κ B signaling pathway in post-laminectomy rats. *Neuropharmacology*, 2014; 79: 275–81
12. Zhang C, Kong X, Liu C et al: ERK2 small interfering RNAs prevent epidural fibrosis via the efficient inhibition of collagen expression and inflammation in laminectomy rats. *Biochem Biophys Res Commun*, 2014; 444(3): 395–400
13. Klekamp J: Treatment of posttraumatic syringomyelia. *J Neurosurg Spine*, 2012; 17(3): 199–211
14. Mueller CA, Conrad S, Schluesener HJ: Spinal cord injury-induced expression of the antiangiogenic endostatin/collagen XVIII in areas of vascular remodeling. *J Neurosurg Spine*, 2007; 7(2): 205–14
15. Alizadeh M, Fisher J, Saksena S et al: Reduced field of view diffusion tensor imaging and fiber tractography of the pediatric cervical and thoracic spinal cord injury. *J Neurotrauma*, [Epub ahead of print].
16. Koskinen EA, Hakulinen U, Brander AE et al: Clinical correlates of cerebral diffusion tensor imaging findings in chronic traumatic spinal cord injury. *Spinal Cord*, 2014; 52(3): 202–8
17. Li XH, Wu F, Zhao F et al: Fractional anisotropy is a marker in early-stage spinal cord injury. *Brain Res*, 2017; 1672: 44–49
18. D'souza MM, Choudhary A, Poonia M et al: Diffusion tensor MR imaging in spinal cord injury. *Injury*, 2017; 48(4): 880–84
19. Liu Y, Kong C, Cui L et al: Correlation between diffusion tensor imaging parameters and clinical assessments in patients with cervical spondylotic myelopathy with and without high signal intensity. *Spinal Cord*, 2017 [Epub ahead of print]
20. Shanmuganathan K, Zhuo J, Chen HH et al: Diffusion tensor imaging parameter obtained during acute blunt cervical spinal cord injury in predicting long-term outcome. *J Neurotrauma*, 2017; 34(21): 2964–71
21. Alizadeh M, Fisher J, Saksena S et al: Reduced field of view diffusion tensor imaging and fiber tractography of the pediatric cervical and thoracic spinal cord injury. *J Neurotrauma*, 2017 [Epub ahead of print].

A more extensive study should be carried out to further evaluate FA values as an indicator for PTS formation after SCI.

Conclusions

The combination of DTI and DTT can be an effective strategy for post-SCI PTS diagnosis. FA values can be a good indicator for evaluating PTS prognosis. PTS formation at a lesion site is more likely to arise in cases with a gradual decrease in FA values after SCI.

Conflicts of interest

None.