

Multiple-level Replantation in Elderly Patients: Risk Versus Benefit

Rafael G. Jakubietz, MD
 Michael G. Jakubietz, MD
 Rainer H. Meffert, MD
 Karsten Schmidt, MD

Summary: Multiple-level amputations of the upper extremity represent a surgical challenge generally only attempted in young patients. This case demonstrates a successful replantation in an elderly woman. The postoperative course was complicated by disseminated intravascular coagulopathy most likely due to inadequate resuscitation. Hand trauma is often underestimated in its general severity. Upper extremity amputations need to be handled similar to polytraumatized patients. (*Plast Reconstr Surg Glob Open* 2017;5:e1313; doi: 10.1097/GOX.0000000000001313; Published online 27 April 2017.)

Despite significant advances in microsurgery, multiple-level amputations remain a surgical challenge and are often considered a contraindication for replantation.¹⁻³ The sparsity of documented cases exemplifies the complexity of such procedures. Multiple-level replantation is relatively contraindicated in elderly patients because regeneration of peripheral nerves is limited. In the literature, only cases of young patients are documented, where a return of functional sensibility can be expected.¹⁻⁶

CASE REPORT

A 62-year-old, right-handed woman suffered a complete double-level amputation transversely across the left distal forearm and the wrist and a severe crush injury of the midhand in a tree-shredder (Fig. 1). Cold ischemia time was less than 2 hours. The proximal amputation occurred at the forearm 3 cm proximal to the radiocarpal joint, the distal obliquely through the wrist at the distal carpal row. The crush injury at the midhand level proved to be a third line of interruption of blood flow with severe vascular damage of the palmar arch. After bony fixation, revascularization was carried out starting proximally. At the midhand level, the crushed arterial parts were excised and repaired primarily. Primary repair of all flexor tendons was performed. To reduce reperfusion toxicity, the replanted parts were flushed out with approximately 500 cc of blood after completion of arterial anastomoses. After reestablishing venous outflow completely proximally and distally, repair of the median and ulnar nerve were carried out. The fractures at the metacar-

pal level were judged stable and not fixed. No primary repair of the extensor tendons was performed. Postoperatively the patient was transferred to the intensive care unit where she developed severe disseminated intravascular coagulopathy (DIC), requiring substitution of clotting factors. After 3 hours, continuous blood loss required revision surgery where profuse bleeding consistent with DIC was encountered. Meticulous hemostasis and use of Arista (C.R. Bard Davol, Warwick, R.I.) eventually controlled the bleeding. The patient received high doses of vasopressors, transfusion of 46 units of fresh frozen plasma, 22 units of packed red blood cells, 4 units of platelet concentrate, in addition to antithrombin III, fibrinogen, and prothrombin complex concentrate replacement. The further course was uneventful. A minor wound dehiscence at the intermediate segment was skin grafted after 10 days. The patient was discharged after 20 days. Kirschner wires were partially removed after 3 months. Bony union was delayed at the distal ulna and occurred after 14 months (Fig. 2). The patient returned to light work 6 months postoperatively. Further corrective surgeries were declined by the patient.

Two years after the accident, fair recovery of sensation was present with protective sensibility in the ulnar nerve distribution. Sensation to touch was present in the median nerve distribution. The patient did not regularly use pain medication. Range of motion at the wrist was 30 degrees of flexion and 5 degrees of extension. No active flexion at the metacarpal-phalangeal, proximal interphalangeal, distal interphalangeal joints was possible.

DISCUSSION

There are only few reports on successful replantation of multiple-level amputations of the upper extremity. All cases in the literature were reported in significantly younger patients.¹⁻⁶ The decision for replantation must be made on a case-by-case basis.

Disclosure: This publication was funded by the German Research Foundation (DFG) and the University of Wuerzburg in the funding programme Open Access Publishing. The Article Processing Charge was paid for by the authors.

From the Department of Trauma, Hand, Plastic and Reconstructive Surgery, University Hospital Wuerzburg, Wuerzburg, Germany.

Received for publication February 9, 2017; accepted March 3, 2017.

Copyright © 2017 The Authors. Published by Wolters Kluwer Health, Inc. on behalf of The American Society of Plastic Surgeons. This is an open-access article distributed under the terms of the Creative Commons Attribution-Non Commercial-No Derivatives License 4.0 (CCBY-NC-ND), where it is permissible to download and share the work provided it is properly cited. The work cannot be changed in any way or used commercially without permission from the journal.

DOI: 10.1097/GOX.0000000000001313

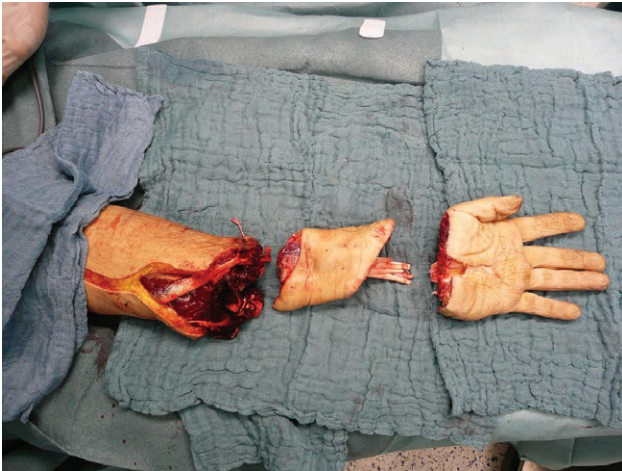


Fig. 1. Before replantation with intermediate segment.

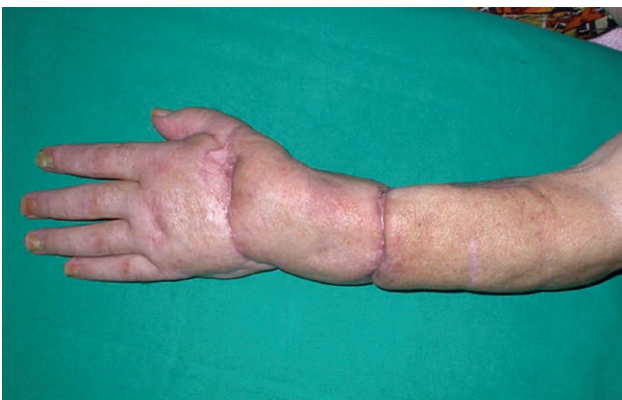

Fig. 2. Three months postoperatively.

The rationale behind this triple-level replantation/revascularization in a relatively old patient was the favorable mechanism of injury, overall health of the patient, and patient request. Retrospectively, this is a debatable decision. A completion-amputation may have expedited the postoperative course and return to daily activities. Besides the functional impairment of a below-elbow amputation, elderly patients are known to adapt less favorably to prosthetic fitting.

The final result is aesthetically acceptable with protective sensation but limited function. The patient remained pain-free without the need for regular pain medication.

Despite the uneventful surgery, the overall course was complicated by profuse bleeding secondary to DIC within a few hours postoperatively. The causes for this remain ultimately unclear but are likely related to resuscitation. The development of dilutional coagulopathy is arguably preventable.⁷ Volume resuscitation and substitution of coagulation factors may have been delayed. Only crystalloids were used during the initial phase of surgery, which dilutes plasma coagulation factors after major blood loss.⁷ After release of the tourniquet, additional blood loss occurred intentionally by flushing out the amputated parts. The 2:1 final ratio of fresh frozen plasma to packed red blood

cells hints that blood loss may have been underestimated. There are several explanations: compensated vital parameters and a normal hematocrit upon presentation may suggest a stable fluid state. The initial part of the surgery is performed under tourniquet control, which may mask the urgency to transfuse the patient. As the injury is confined to 1 extremity, operating room staff tends to misinterpret these cases as regular “hand cases.”

The development of DIC is commonly felt to be a late event in surgery, which has been proven wrong in trauma patients.⁷ Data regarding DIC in surgical patients were mainly acquired during elective cases where patients are normovolemic.⁷ This does not translate to patients suffering from major trauma, where more aggressive correction of hypovolemia is mandatory. The equivalent of whole blood needs to be transfused to prevent dilutional coagulopathy.⁷

As patency of blood vessels is mandatory in microsurgery, correction of coagulopathy is even more challenging in this situation. There are currently no data regarding treatment of DIC in patients undergoing microvascular reconstruction. Substitution of clotting factors in this case successfully corrected coagulopathy without inducing a hypercoagulable state leading to vascular thrombosis. If hemorrhage had continued, amputation of the replanted limb would have been required to follow the “life before limb”-rule.

In conclusion, hand amputations represent major trauma with the same implications to fluid resuscitation as in other multiinjured patients. All involved staff needs to keep a high level of suspicion regarding generalized sequelae such as DIC and acute respiratory distress syndrome despite “only” being a “hand case.”

Rafael G. Jakubietz, MD

Department of Trauma, Hand, Plastic
and Reconstructive Surgery
University Hospital Wuerzburg
Oberduerrbacher Str. 6
DE 97080 Wuerzburg, Germany
E-mail: Jakubietz_R@ukw.de

REFERENCES

1. Belsky MR, Ruby LK. Double level amputation: should it be replanted? *J Reconstr Microsurg.* 1986;2:159–162.
2. Yousif NJ, Muoneke V, Sanger JR, et al. Hand replantation following three-level amputation: a case report. *J Hand Surg Am.* 1992;17:220–225.
3. Yoshizu T, Katsumi M, Tajima T. Replantation of untidily amputated finger, hand, and arm: experience of 99 replantations in 66 cases. *J Trauma.* 1978;18:194–200.
4. Pei GX, Zhao DS, Xie CP, et al. Replantation of multi-level hand severances. *Injury.* 1998;29:357–361.
5. Papanastasiou S, Sood M. Double-level replantation of the upper extremity with microvascular pulp transfer onto an intermediate macroreplant segment. *Plast Reconstr Surg.* 2002;110:1294–1297.
6. Cai J, Cao X, Pan J, et al. Replantation of a multiple digit and circular palm amputation: a case report. *Microsurgery.* 1993;14:221–224.
7. Ho AM, Karmakar MK, Dion PW. Are we giving enough coagulation factors during major trauma resuscitation? *Am J Surg.* 2005;190:479–484.