

Descemet's Stripping Automated Endothelial Keratoplasty Using Donor Tissue from an 83-Day-Old Infant

Nikolaos Ziakas^{1,2}, Angeliki Chranioti², Argyrios Tzamalīs¹, Dimitrios Giannoulis², Dimitrios Kapantais², Michael Tsatsos², Konstantinos T. Tsaousis¹

¹2nd Department of Ophthalmology, Aristotle University of Thessaloniki, Papageorgiou Hospital, Thessaloniki, Greece, ²1st Department of Ophthalmology, Aristotle University of Thessaloniki, AHEPA Hospital, Thessaloniki, Greece

Abstract

Purpose: To report a case of Descemet stripping automated endothelial keratoplasty (DSAEK) combined with phacoemulsification in an adult recipient using endothelial graft from an 83-day-old infant donor.

Methods: A corneoscleral button was obtained from an infant donor and a DSAEK graft was prepared using a microkeratome. In comparison to the standard technique of DSAEK graft preparation some modifications were made in order to avoid inadvertent perforation, as the donor cornea had a very spherical shape, probably due to the very young age of the donor. The DSAEK graft was transplanted to the left eye of a 68-year-old woman suffering from Fuchs' endothelial dystrophy. Her preoperative best-corrected visual acuity (BCVA) in that eye was 20/100 and central corneal thickness 831 μm .

Results: An uneventful DSAEK combined with phacoemulsification was performed. The main complication noted was detachment of the peripheral part and contraction of the corneal graft, observed two months after the procedure. The implanted tissue remained centrally attached with a BCVA of 20/40, 3 years postoperatively.

Conclusion: This case report highlights the difficulties emerging from preparation and implantation using an endothelial graft tissue from the youngest ever reported donor.

Keywords: Corneal graft, Descemet stripping automated endothelial keratoplasty, Endothelial keratoplasty, Fuchs' endothelial dystrophy, Infant donor

Address for correspondence: Argyrios Tzamalīs, 2nd Department of Ophthalmology, Aristotle University of Thessaloniki, Papageorgiou General Hospital, Thessaloniki, Greece.

E-mail: argyriostzamalīs@yahoo.com

Submitted: 01-Aug-2021; **Revised:** 19-Dec-2021; **Accepted:** 26-Dec-2021; **Published:** 26-Jul-2022

INTRODUCTION

Descemet stripping automated endothelial keratoplasty (DSAEK) and Descemet membrane endothelial keratoplasty (DMEK) are among the preferred lamellar keratoplasty techniques for endothelial decompensation management, exhibiting numerous advantages over penetrating keratoplasties, such as maintenance of corneal integrity, fast visual recovery, and minimally induced refractive change.¹ In contrary to DMEK, where grafts from older donors are preferred due to ease of preparing and unrolling, there is theoretically no age

limit for grafts in DSAEK.² Herein, we report a case of DSAEK combined with phacoemulsification in an adult patient using endothelial graft from an 83-day-old infant donor. To the best of our knowledge, this highlights the youngest endothelial graft ever used in DSAEK surgery.

CASE REPORT

The donor cornea was obtained by an 83-day-old infant who passed away to heart failure. Cardiac death to enucleation

This is an open access journal, and articles are distributed under the terms of the Creative Commons Attribution-NonCommercial-ShareAlike 4.0 License, which allows others to remix, tweak, and build upon the work non-commercially, as long as appropriate credit is given and the new creations are licensed under the identical terms.

For reprints contact: WKHLRPMedknow_reprints@wolterskluwer.com

How to cite this article: Ziakas N, Chranioti A, Tzamalīs A, Giannoulis D, Kapantais D, Tsatsos M, *et al.* Descemet's stripping automated endothelial keratoplasty using donor tissue from an 83-day-old infant. *J Curr Ophthalmol* 2022;34:257-9.

Access this article online

Quick Response Code:



Website:
www.jcurrophthalmol.org

DOI:
10.4103/joco.joco_242_21

time was 2 h, and enucleation to graft preparation was 1 h. Endothelial cell count (ECC) of the infant donor cornea was 6061/mm², and central corneal thickness (CCT) 523 μm. The donor graft was stored for 5 days until transplantation in a viewing corneal chamber containing 20 mL Eusol-C (AL.CHI. M.I.A., Italy) at 4°C.

The corneoscleral button was mounted on an artificial anterior chamber, where it exhibited great elasticity with remarkable protrusion acquiring a more spherical shape, resembling the cornea of a patient with keratoglobus. To avoid inadvertent penetration, the pressure was adjusted from 90 cm H₂O that we typically use to a lower level (70 cm H₂O), demonstrating a better configuration of the graft. Thereafter, corneal epithelium was manually debrided, CCT was measured with an ultrasound device (478 μm), and dissection was carried out with the Evolution 3E Microkeratome (Moria, France), using a 300-μm head, resulting in a DSAEK graft of 196 μm central thickness. We decided not to perform any further dissection with a second pass to minimize the risk of perforation. The graft was subsequently transferred onto a cutting block and trephined with a 7.00-mm vacuum punch (Moria, France). Some difficulty was noticed in fully unfolding the graft on the cutting block, as it exhibited the tendency to acquire an oval configuration. However, this was eventually overcome by vacuum stabilizing the graft before punching.

A 68-year-old woman with bilateral Fuchs' endothelial dystrophy was selected as the recipient. Her best-corrected visual acuity (BCVA) was 20/40 in the right eye (RE) and 20/100 in the left eye (LE). CCT readings were 692 μm and 831 μm in her RE and LE, respectively, and ECC was 1574/mm² in the RE but could not be documented in the LE due to significant corneal edema. Signed informed consent by the patient was obtained before the surgery. The recipient underwent a LE uneventful phacoemulsification, intraocular

lens insertion (target -1.0 sph), and DSAEK through a 4.1-mm temporal limbal incision using Busin glide for graft insertion. The recipient corneal diameter was 11.8 in the horizontal meridian, and the descemetorhexis was performed in the central 7.5 mm. The graft was securely attached with air against the posterior stroma showing a slight superior decentration.

During the follow-up period, a peripheral and paracentral detachment and contraction of the graft were noted at the postoperative month 2 [Figure 1]. However, the central corneal part maintained its clarity allowing an acceptable for the patient visual acuity, who denied any further intervention. Although the graft was noticeably thick since the beginning, increased CCT has not affected central corneal clarity. Three years postoperatively, no further complications or immunological reactions were noted and BCVA was 20/40 with a stable refraction (+1 sph, -2.5 cyl/90°) and ECC of 3583 cells/mm². An informed consent form has been signed and obtained from the patient.

DISCUSSION

Donor age in endothelial corneal transplantations has been a topic of discussion in the past decade. Although more prone to rejection, neonatal corneas offer a healthy reservoir of endothelial cells, lowering the risk of postoperative endothelial failure.³ It is well documented that ECC and morphologic regularity are higher in newborns and children than in adults, although there is great ECC variation between studies, reaching up to 6000 cells/mm.^{2,4,5}

Several researchers have already reported successful outcomes in endothelial keratoplasty using grafts from children or infants aged 9 months to 3 years old.^{3,6-8} In 2012, Kim *et al.* reported that using infant donor tissue for DSAEK surgery is safe after applying three DSAEK grafts (from one 1-year-old

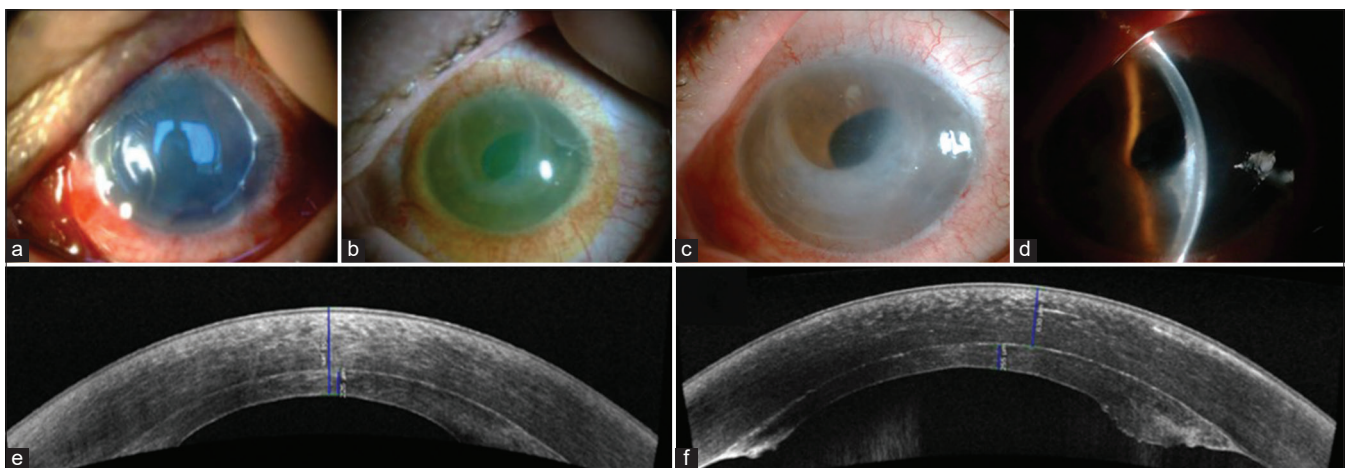


Figure 1: Slit-lamp photographs and anterior segment optical coherence tomography (OCT) at different time points during follow-up. (a) Slit-lamp photograph immediately after the operation (visible air bubble). (b) Slit-lamp photograph 3-month postoperative where the inferior/temporal part of the graft appears hazy and thickened. (c) Slit-lamp photograph 1-year postoperative. (d) Slit-lamp photograph 3-year postoperative showing peripheral detachment and thickening of the graft. (e) Anterior segment OCT 1-year postoperative. (f) Anterior segment OCT 3-year postoperative.

and two 2-year-old donors) in three adult patients undergoing DSAEK surgery.³ This was soon followed by Kobayashi *et al.* in 2014 (case report of an adult patient undergoing DSAEK with tissue from a 2-year-old donor), who concluded that infant donor tissue should preferably be used for DSAEK rather than penetrating Keratoplasty or DMEK.⁶ More recently, Agarwal *et al.* performed three successful pre-Descemet endothelial keratoplasties in three adults using corneas from infant donors aged 9–12 months.⁷ Interestingly, Peng *et al.* published lately an observational case series of DSEK outcomes using donor corneas from children younger than 3 years, concluding that the grafts from 1 to 3-year-old donors are appropriate for DSEK, but on the contrary, those from younger donors (<1 years old) are less suitable due to the likelihood of significant postoperative graft contraction.⁸

DSAEK graft preparation in such donors can be sometimes challenging. In our case, graft tenderness and elasticity caused the graft to acquire a more globular shape than its normal gradual curve when pressurizing the artificial chamber with a balanced salt solution. Elasticity also caused the DSAEK corneal button to assume an oval shape when delivering it onto the punch, which was overcome by vacuum stabilizing the button before punching. Furthermore, the peripheral edges of the graft, as depicted in the postoperative optical coherence tomography, showed increased thickness and asymmetry in comparison to DSAEK grafts acquired from adult donors. This fact may be attributed to the increased corneal elasticity and difficulty to have a regular pass using a microkeratome. In such cases, the use of femtosecond laser could possibly represent an advantageous alternative.

In our case, the main issue was a considerable peripheral detachment and contraction of the graft, noticed 2 months after the procedure, which affected the final visual outcome causing corneal thickening and a quite high astigmatism. It is unknown if infantile tissue is most prone to detachment than that from older donors, but according to Peng *et al.*, contraction of grafts is very common for grafts from donors <1 years old while is not normally noted with adult grafts.⁸ Moreover, it is impossible to predict the long-term viability of the graft, but our patient was clinically stable with a partially acceptable, although not optimal, outcome 3 years after the transplantation.

This case report highlights the difficulties emerging from preparation and implantation using endothelial graft tissue from the youngest ever reported donor. As contraction and peripheral detachment of the DSAEK graft was observed 2 months after the procedure, long-term follow-up is mandatory to determine the viability and elucidate the behavior of corneal grafts from such young donors.

Declaration of patient consent

The authors certify that they have obtained all appropriate patient consent forms. In the form, the patient has given his consent for his images and other clinical information to be reported in the journal. The patient understands that his name and initials will not be published and due efforts will be made to conceal his identity, but anonymity cannot be guaranteed.

Financial support and sponsorship

Nil.

Conflicts of interest

There are no conflicts of interest.

REFERENCES

1. Nanavaty MA, Wang X, Shortt AJ. Endothelial keratoplasty versus penetrating keratoplasty for Fuchs endothelial dystrophy. *Cochrane Database Syst Rev* 2014;2:CD008420.
2. Kruse FE, Schrehardt US, Tourtas T. Optimizing outcomes with Descemet's membrane endothelial keratoplasty. *Curr Opin Ophthalmol* 2014;25:325-34.
3. Kim P, Yeung SN, Lichtinger A, Amiran MD, Rootman DS. Descemet stripping automated endothelial keratoplasty using infant donor tissue. *Cornea* 2012;31:52-4.
4. Murphy C, Alvarado J, Juster R, Maglio M. Prenatal and postnatal cellularity of the human corneal endothelium. A quantitative histologic study. *Invest Ophthalmol Vis Sci* 1984;25:312-22.
5. Bahn CF, Glassman RM, MacCallum DK, Lillie JH, Meyer RF, Robinson BJ, *et al.* Postnatal development of corneal endothelium. *Invest Ophthalmol Vis Sci* 1986;27:44-51.
6. Kobayashi A, Yokogawa H, Yamazaki N, Masaki T, Sugiyama K. Endothelial keratoplasty with infant donor tissue. *Clin Ophthalmol* 2014;8:1827-30.
7. Agarwal A, Agarwal A, Narang P, Kumar DA, Jacob S. Pre-Descemet endothelial keratoplasty with infant donor corneas: A prospective analysis. *Cornea* 2015;34:859-65.
8. Peng RM, Guo YX, Qiu Y, Hong J, Xiao GG, Qu HQ. Clinical outcomes after Descemet's stripping endothelial keratoplasty using donor corneas from children younger than 3 years. *Clin Exp Ophthalmol* 2018;46:721-9.