

Alar cartilage—an alternative for spreader graft in primary rhinoplasty

Carlos Oscar Uebel¹ · Renato Matta¹

Received: 15 April 2017 / Accepted: 7 June 2017 / Published online: 12 July 2017
© The Author(s) 2017. This article is an open access publication

Abstract

Background Alar cartilage can be very useful for tip and dorsum grafts. Depending on its size and thickness, it can be an important alternative for spreader grafts to improve endonasal functional deficiencies, correct deviated noses, and prevent inverted “V” deformities. Caucasian patients with bulbous tips are the most common candidates to achieve such benefits. It is easy to obtain and to frame into a desired graft.

Methods The authors describe a surgical technique using the alar cartilages as spreader grafts. All Caucasian patients with bulbous tips who underwent primary rhinoplasty were included. All patients have been evaluated after 3 to 4 months and after 1 and 2 years by aesthetical and functional criteria.

Results Thirty-four patients (28 female and 6 male) underwent this procedure between 2001 and 2015: 94% reported a better airflow, 91% reported very good aesthetic results and were very satisfied 2 years postoperatively, and 12% had nasal deviations that were corrected with a one side double-layered spreader grafts. Two patients presented supra-tip deformities and one patient had a columella scar that was revised surgically. No cases of inverted “V” deformity were reported 2 years postoperatively.

Conclusions Patients with functional satisfaction and with a straight and smooth dorsum seem to be the most important benefits that were achieved with this technique using alar cartilage spreader grafts, an alternative that can be offered to

improve airflow and to prevent deviated and inverted “V” deformities.

Level of Evidence: IV, therapeutic study.

Keywords Primary rhinoplasty · Inverted “V” deformity · Internal valve deficiency · Deviated nose · Spreader graft · Alar cartilage

Introduction

Rhinoplasty techniques date back to the nineteenth century, as first described by Roe [1]. Thereafter, Joseph [2] devised an endonasal technique that is still performed by many surgeons today. Rethi described the open transcolumellar approach in 1929 [3], and more recently, Vogt [4] brought further advances to the open rhinoplasty approach.

One of the greatest challenges in rhinoplasty is maintaining endonasal integrity and functional nasal vault activity [5, 6]. The endonasal vaults are the narrowest part of the airway. These structures are defined by the junction between the septum and the caudal superior lateral cartilages, forming an angle of 10–15° in Caucasians (leptorrhine) and a larger angle in people of African and Asian heritage (platyrrhine) [5, 7, 8].

Some issues can affect the complex junction between the alar and superior lateral cartilages stretching between the lateral nasal wall and the terminal part of the inferior turbinate [1, 9]. Reasons for obstruction can be congenital, traumatic, or iatrogenic, particularly after a rhinoplasty [10]. Large resections of alar cartilage from the lateral crus, dorsal hump removal, and lateral osteotomies can reduce physiologic support for the superior lateral cartilage, resulting in deviated structures [9, 11]. A resection of only 2 mm of vault cartilage is sufficient to flatten it [12]. Because of this, when a dorsum

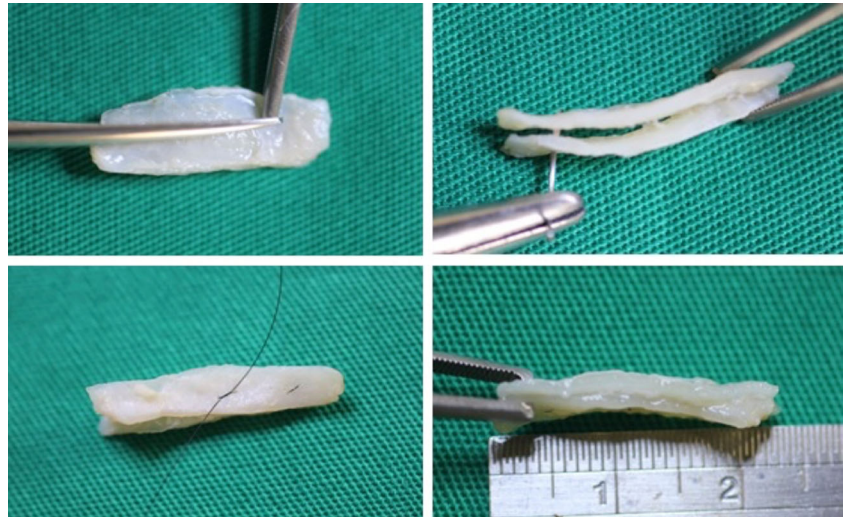
✉ Carlos Oscar Uebel
carlos@uebel.com.br

¹ Division of Plastic Surgery –PUCRS, Porto Alegre, Brazil

Fig. 1 Alar grafts from our Caucasian patient series

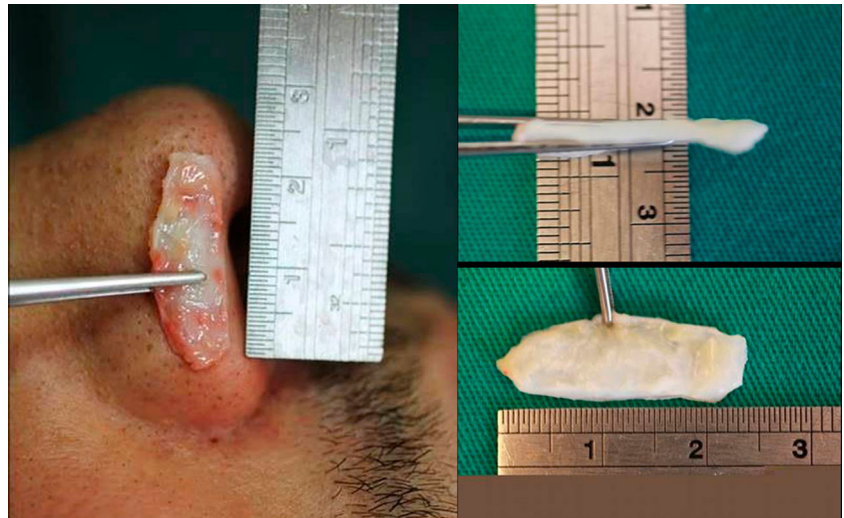

Fig. 2 A double-layered alar spreader graft being prepared



removal is performed, it is sometimes necessary to spread and reconstruct the medial vault to prevent a vault deficiency and an inverted “V” deformity.

Many authors have described different methods to improve nasal vault function, including spreader grafts [10], spreader

flaps [13, 14], also known as turnover flaps [15], alar batten flaps [16], splay grafts [17], flaring sutures [18], the auto-

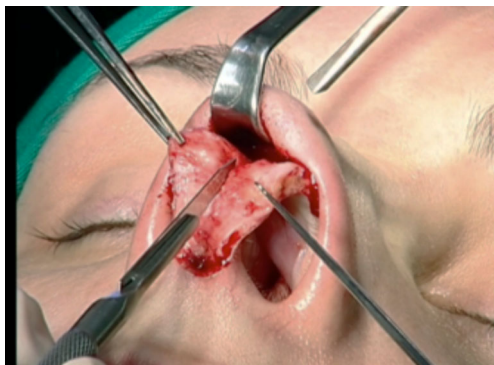


Fig. 3 Septum exposure via sub-mucoperichondrial plane

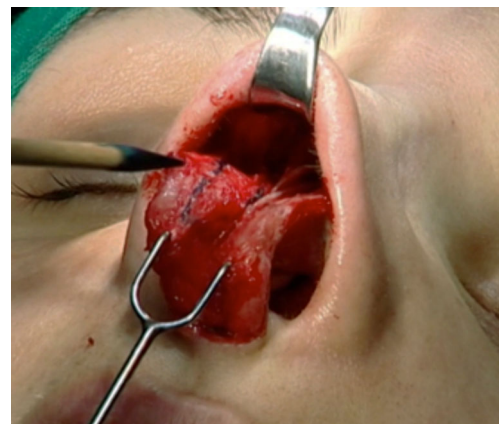


Fig. 4 Marking the cephalic alar ellipse to be excised, leaving 3 to 4 mm of alar rim

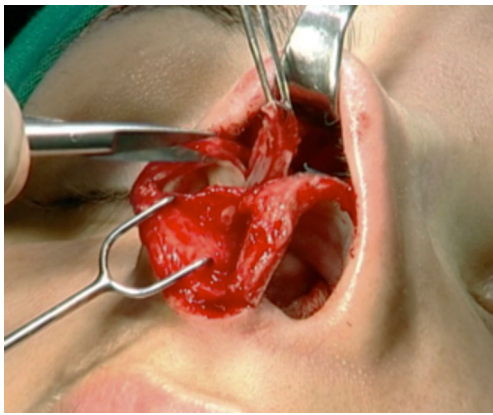


Fig. 5 Alar resection “en bloc” with small nasal mucosa excess

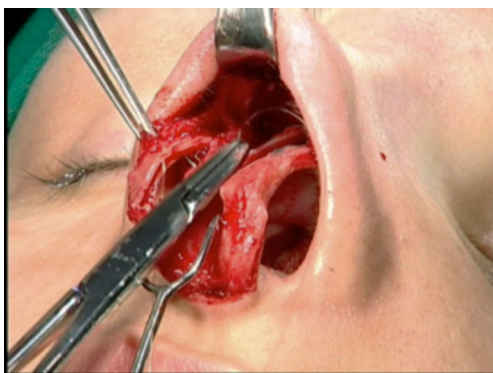


Fig. 6 Suture of the opening structures, including mucosal layer

spreading spring flap [6], or double-layered stepped spreader graft [19]. Overall, 81% of patients receiving spreader grafts experience significant nasal airflow improvement [20].

The authors present an alternative for spreader grafts obtained from the cephalic portion of the alar cartilage, especially for patients with alar cartilage hypertrophy, such as Caucasian and Middle Eastern patients. This technique can be useful to correct those deformities preserving intact

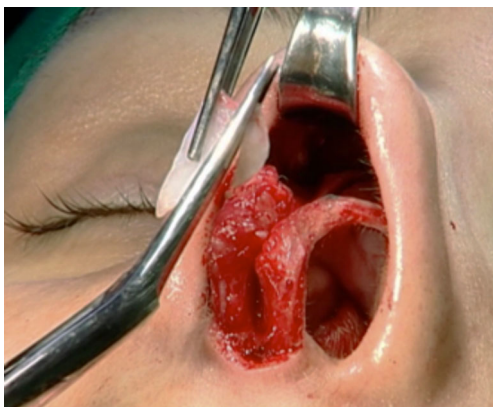


Fig. 7 Trimming “alar cartilage spreader graft”

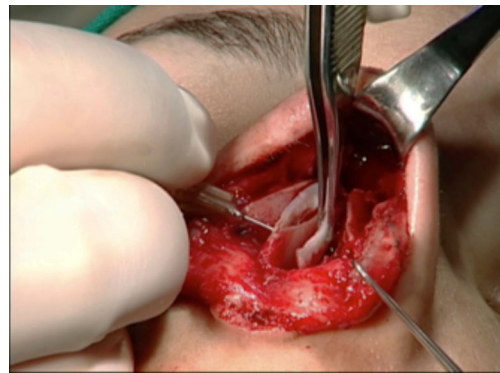

Fig. 8 Both graft attachment with the convex side oriented medially. Note the thickness of the alar grafts in relation to the septal plate

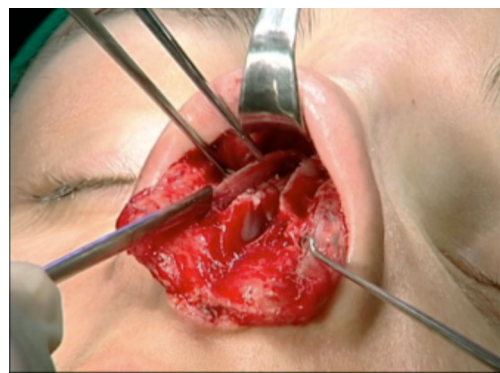


Fig. 9 Trimming upper lateral cartilages. They can also be sutured over the dorsum

material from the septum, chondrocostal, or auricular cartilage, diminishing the surgical time and morbidity.

Table 1 Patients’ characteristics

Characteristic	No. of patients	Percentage
Sex (total)	34	100%
Female	28	82%
Male	6	18%
Age range	22–58	–
Follow-up of 2 years	34	100%
Follow-up of 5 years	23	68%
Lost to follow-up in 5 years	11	32%
Functional evaluation (second year postoperative)		
Better airflow	32	94%
Same before surgery	0	–
Worst in one side	2	6%
Worst in both sides	0	–
Aesthetic result (second year postoperative)		
Very good and very satisfied	31	91%
Good but it could be better	3	9%
Other	0	–
Patients with nasal septal deviation	4	12%
Surgical re-interventions	3	9%

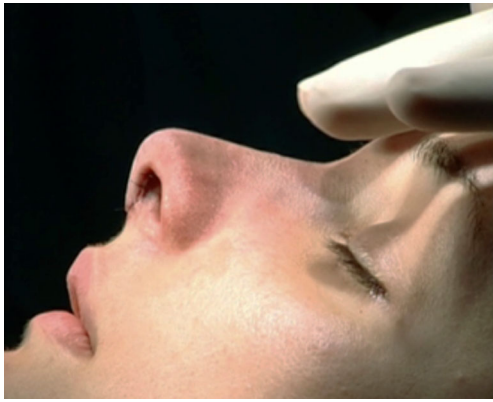

Fig. 10 Dorsum immediate postoperative result

Methods

Patients with pronounced and bulbous nasal tips were selected as good candidates to improve airflow and to prevent an inverted V deformity, from 2001 to 2015 in our Division of Plastic Surgery using alar cartilages as spreader grafts. In our study, we have considered patients with alar cartilages from 19 to 26 mm length, 9 to 12 mm width, and 2.5 to 3.5 mm thickness (Fig. 1). Four patients with nasal septal deviation were included, and in these cases, it was used a double-layered alar spreader graft (Fig. 2). There were excluded patients with previous rhinoplasty and with weak and smaller alar cartilages. They were evaluated monthly during fourth months and after 1 and 2 years postoperatively.

The main author performed the functional evaluation by direct inspection of the internal vault with speculum and asking the patient to perform the forced inspiration/expiration maneuver. The patients answered a questionnaire about the

nasal airflow at the second year postoperative in a following scale: 1, better; 2, same before surgery; 3, worst on one side; and 4, worst on both sides. The aesthetic result was evaluated from a questionnaire by the patients as follows: 1, very good and very satisfied; 2, good and satisfied; 3, regular; and 4, bad. Besides this, an accurate study was done with pre- and post-operative pictures.

Surgical technique

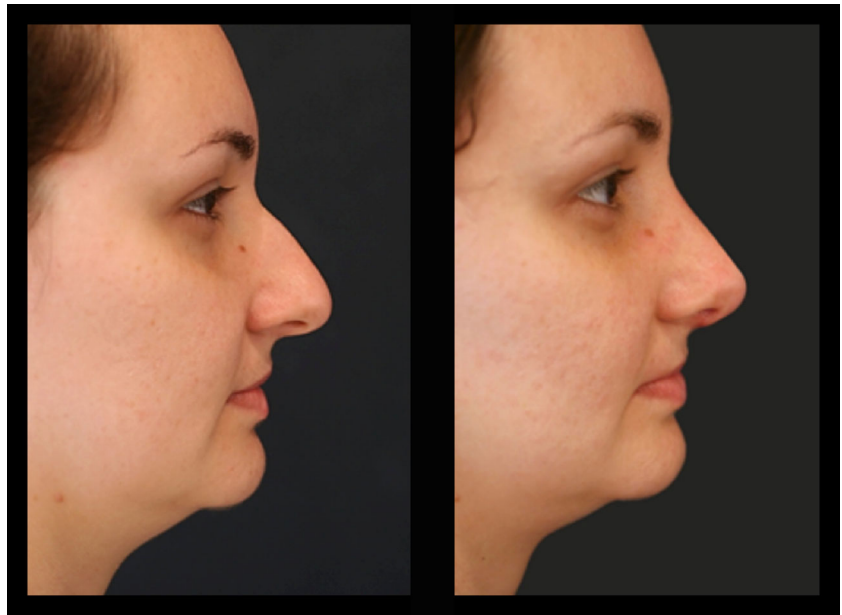
Patients were placed under general anesthesia with 2,6-diisopropylphenol (Profolen® 10 mg/ml, Blau Farmacêutica S.A., SP, Brazil) or local in stand-by with midazolam (Dormonid® 15 mg/3 ml, Roche, RJ, Brazil) divided into 3 mg/2 cm³ portions delivered intravenously at approximately 30-min intervals or then propofol (10 mg/ml). Local infiltration was performed 15 min before incision with bupivacaine without epinephrine (Marcain® 0.25%, AstraZeneca, SP, Brazil) with epinephrine 1:120,000. An open approach was performed with an inferior “V” columellar incision extending to the nostril rim and subcutaneously to the glabella, with exposure of the alar cartilages and osteocartilaginous dorsum. The membranous septum was opened with septal exposure via the sub-mucoperichondrial plane (Fig. 3). The upper lateral cartilages were released from the septum by a submucosal approach, and the portion of the osteocartilaginous dorsum was resected with angular scissors and finalized with a rasp or osteotome.

The next step was to identify and prepare the alar cartilage spreader grafts. A cephalic ellipse was removed with no less than 19 mm of length and 2 mm of thickness (Fig. 4). If the patient had a large bulbous tip, a resection “en bloc” including

Fig. 11 Thirty-two-year-old patient. Preoperative and 1-year postoperative result. Well-defined nasal dorsum, “eyebrow-nasal tip line,” and an optimal functional outcome



Fig. 12 Same patient in lateral view



cartilage and a small inner portion of mucosa was performed (Fig. 5). Besides this, mucosal excision is performed mostly in patients to prevent ripples inside the external valve. The defect is closed with poliglecaprone 5–0 suture (Monocryl®, Ethicon, Johnson & Johnson do Brasil, SP, Brazil) (Fig. 6).

Both cartilages are trimmed, inserted into the superior septum as spreader grafts, and fixed with nylon 5–0 (Ethilon®, Ethicon, Johnson & Johnson do Brasil, SP, Brazil) (Figs. 7 and 8). If some excess of upper lateral cartilage is available, it can be excised or sutured over the dorsum covering the spreader grafts to produce a smooth and straight dorsum (Fig. 9). After closing the columellar and rim incisions with Monocryl 4–0,

tape strips (Micropore®, 3M Health Care, St. Paul, MN, USA) are applied and an acrylic splint is fixed over the dorsum, where it will remain for 8 days. No endonasal packing was used.

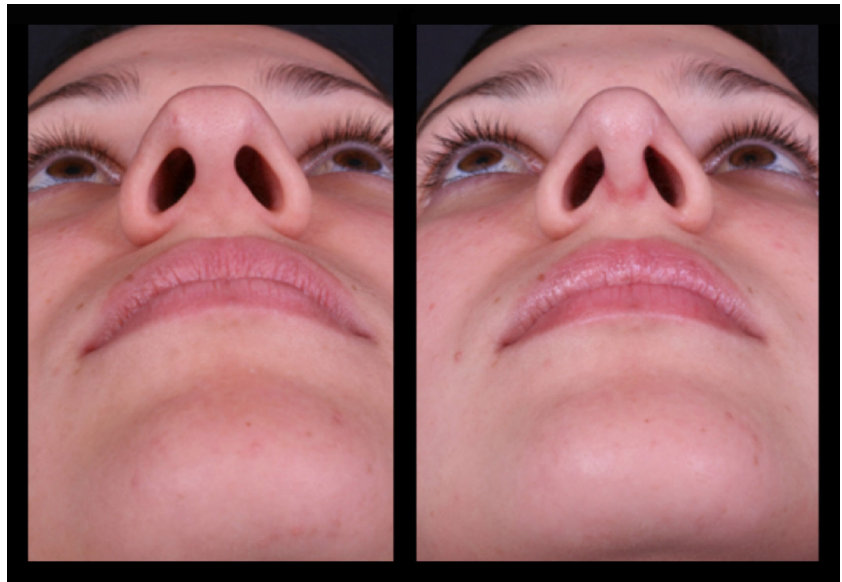Results

Thirty-four patients (28 female and 6 male) underwent this procedure between 2001 and 2015 by an open rhinoplasty approach under general and local anesthesia; three of them stayed for one night at the hospital and the others went home in the

Fig. 13 Twenty-six-year-old patient. Pre- and fourth month postoperative result. Straight dorsum lines and well-defined nasal tip



Fig. 14 The same patient in inferior view



same day of the surgery. The majority of them (94%) reported a better airflow, no patient reported worst functional result 1 year postoperatively, 6% reported worst airflow in one nasal side 2 years postoperatively, 91% reported a very good aesthetic results and were very satisfied 2 years postoperatively, and 12% had nasal deviations that were corrected with a one side double-layered spreader grafts. Two patients presented supra-tip deformities that were revised surgically and in one patient a columella scar revision. No cases of inverted “V” deformity were reported 2 years postoperatively. The patients’ features are summarized in Table 1. Representative cases are depicted in Figs. 10, 11, 12, 13, 14, 15, 16, 17, 18, 19, 20, and 21).

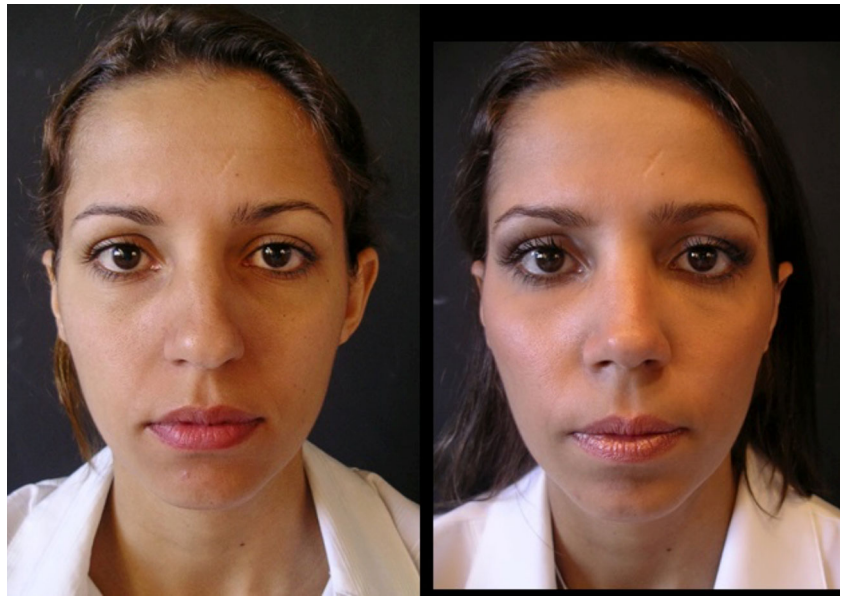
Discussion

The use of cartilage as spreader graft is inexpensive and practical should be the first choice when available [6]. The most common donor area is the septum because of its strong and straight cartilage. A chondrocostal graft offers the advantage of a large amount of donor material, allowing the surgeon to shape long, straight, and thick pieces. However, it has disadvantages of requiring sculpture to achieve an adequate form and the need to harvest from the sixth or seventh rib, with the possibility of postoperative morbidity. Auricular cartilage is easier to obtain, but the graft will not be straight and can curl

Fig. 15 The same patient 5 years postoperatively

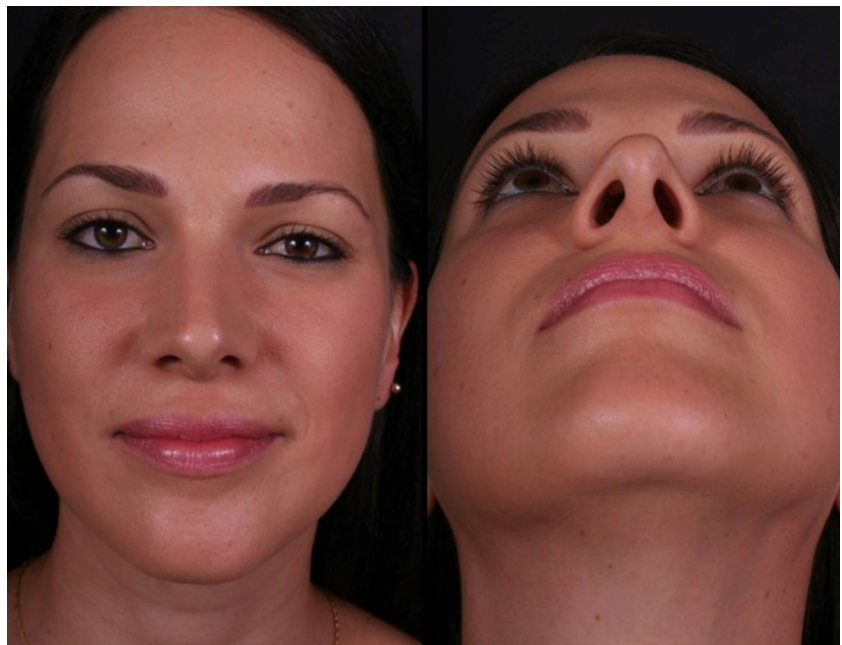

Fig. 16 Twenty-six-year-old patient. Pre- and fourth month postoperative result. Straight dorsum lines and well-defined nasal tip



over after implantation [21, 22]. Spreader flaps from the upper lateral cartilages can be another option for patients with a large humpectomy as described by Gruber et al. [13], Berkowitz [23], O Neal and Berkowitz [24], and Seyhan [25]. Alloplastic and cadaveric materials have been used in some patients [26], but at high cost, and with the possibility of infection and extrusion [6]. Calcium hydroxyapatite [27] and hyaluronic acid [28] have been described for use as spreader graft material. It has been used at the sub-mucoperichondrial level, as have high-density polyethylene (HDPP) plates [22].

Alar cartilages can be another option for spreader grafts depending on its structure and dimensions. In 1979, Zelnik and Gingrass [29] described average Caucasian alar cartilage

dimensions of 21.1-mm length by 1.2-mm width. An anatomical study of Asians found an average length of 17.9 (± 2.28) mm, width of 10.0 (± 1.31) mm, and thickness of 0.54 (± 0.09) mm in both genders [30]. In another study of Iranians, the reported average was 23.4 (± 2.7) mm length, 10.8 (± 1.29) mm width, and 1.0 (± 0.15) mm thickness [31]. More recently, Daniel et al. [32] described an average thickness of 0.5 mm at the lateral crura [32]. In our series of 34 Caucasian patients, we have observed alar cartilages from 19 to 26 mm of length, width of 9 to 12 mm, and from 2.5 to 3.5 mm of thickness.

Described by Sheen in 1984 [33], the spreader graft is considered a well-established technique to improve the

Fig. 17 The same patient 5 years postoperatively in an oblique view

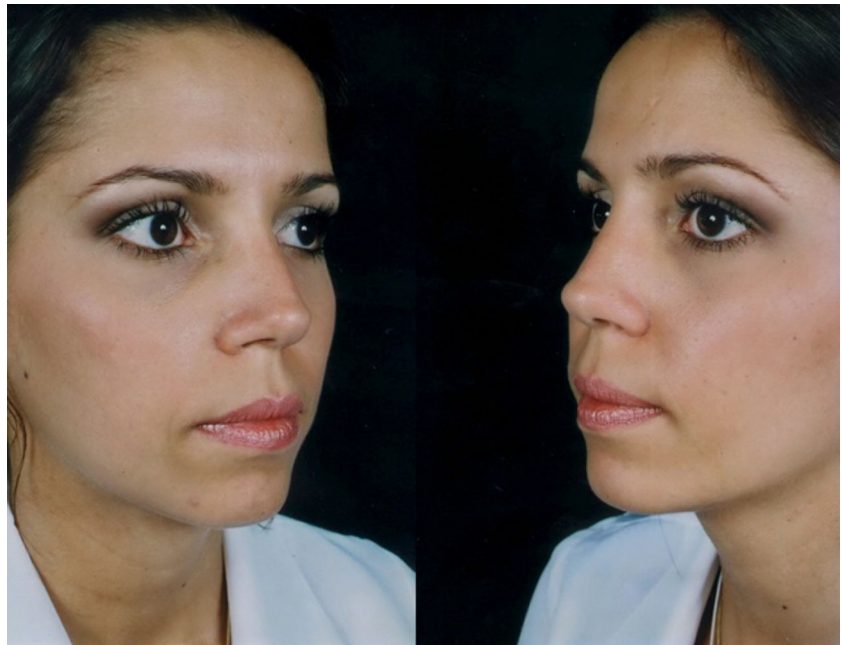

Fig. 18 Thirty-six-year-old patient. Pre- and 2 years postoperative result



internal vault. It not only improves the angle between septum and superior lateral cartilages but also improves the aesthetic appearance of the nasal dorsum “eyebrow-nasal tip lines” [5, 6, 34]. Initially, the spreader graft was described to correct the inverted “V” deformity caused by large osteocartilaginous dorsum removal [35]. It is also used for nasal roof reconstruction after dorsum removal and for reconstruction of asymmetric noses [34]. The most common challenge involves fixing the spreader grafts to maintain the symmetry of the nasal dorsum [36]. Some techniques have been described to help maintain these grafts, including the narrow dorsal tunnel, transcutaneous, and trans-septal sutures [34].

According to the Bernoulli principle [5], reduced pressure is transmitted to the lateral walls during inspiration, thereby

narrowing the internal nasal vault. Air passing through the nasal vaults at high speed lowers intraluminal pressure, producing an inspiratory collapse [35]. This effect can be estimated by acoustic rhinometry [37, 38], one of few available tests to identify nasal airflow and nasal vault deficiencies [39].

Some details of this technique should be considered, such as choosing an adequate patient to perform the procedure. A strong, thick, and long lateral crura is necessary, especially in those large and bulbous tips. The alar cartilage slice should have a thickness like the septum from 2 to 3 mm and a length sufficient to spread the middle internal valve from the anterior septal angle to the osteocartilaginous junction from a minimum of 19 to 26 mm in length. The cartilage graft should be placed and adapted with the natural convex side oriented

Fig. 19 Same patient in lateral view

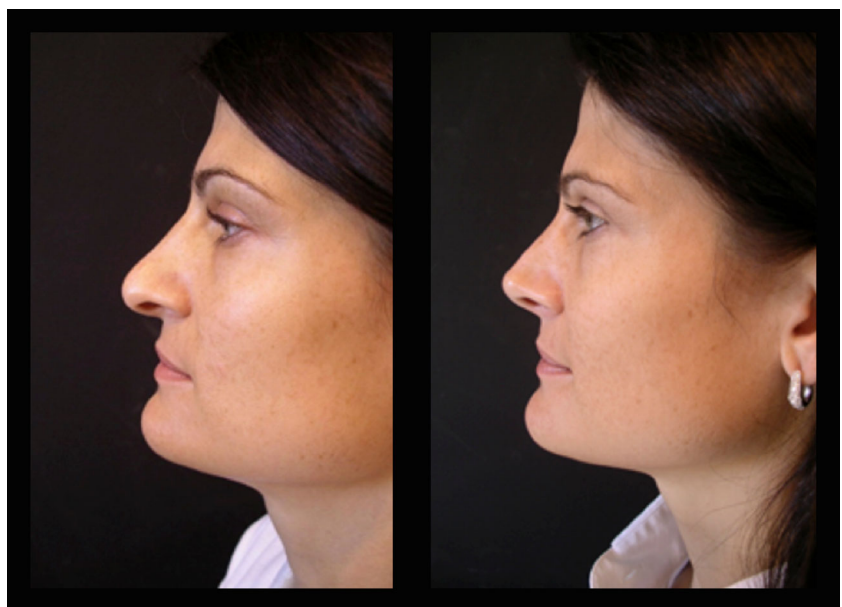
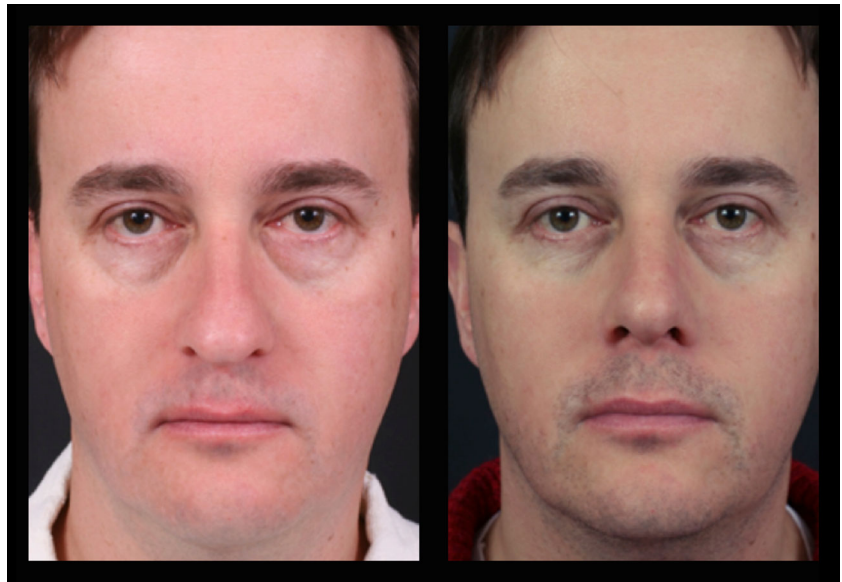
Fig. 20 Forty-two-year-old male patient with a bulbous tip pre- and postoperative of 3 years



medially for better opening of the nasal valve angle. After placement of the “alar cartilage spreader graft,” any excess ULC can be trimmed or sutured over the dorsum, covering the spreader grafts, to create a smooth and straight dorsum, as described by Cerkes [40] and others [28, 32]. Another issue, mostly found in large bulbous nose, is the redundant inner nasal mucosa that can be excised “en bloc” and removed from the alar cartilage. Although we have a mucosa retraction, this can improve and bring up the nasal tip and prevent ripples inside the nasal valve. In cases we need a stronger and more structured spreader graft, especially in nasal deviation, a double-layered alar graft can be used (Fig. 2).

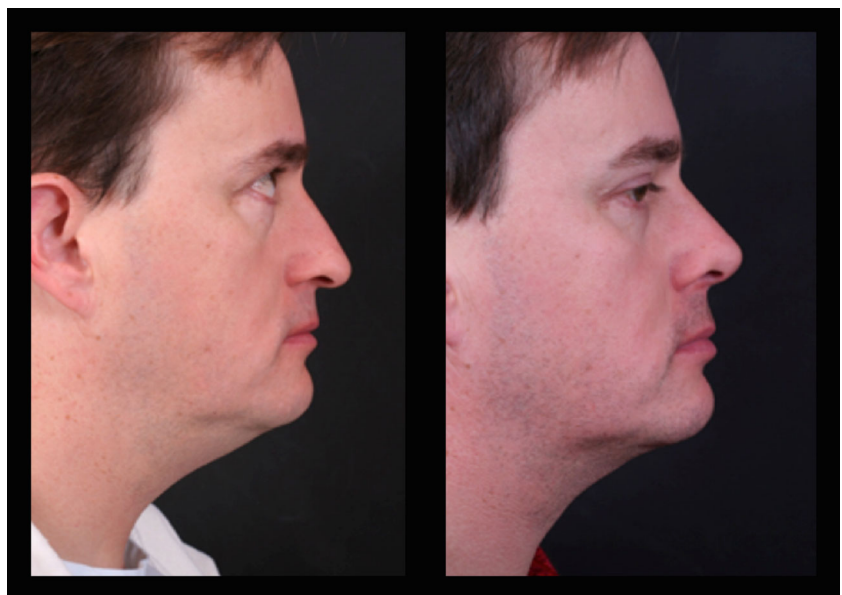This is a very simple, brief, and predictable procedure that has an excellent teaching curve. After 1 year, postoperative

patients have had acceptable functional result, and after 2 years, a good aesthetic results. Further studies and conclusions should be done in the future with a larger series of patients.

Conclusions

The alar cartilage spreader graft, in selected patients, is an alternative and effective procedure to improve dorsum deformities, to prevent inverted “V” deformities, and to improve airway flow in the internal nasal valve deformities. It is a predictable technique with a low complication rate with a simple and short surgical protocol.

Fig. 21 Lateral view of the same patient



Compliance with ethical standards

Conflict of interest Carlos Oscar Uebel and Renato Matta Ramos declare that they have no conflicts of interest.

Funding There was no funding from either public, private, or third sector sources.

Ethical approval Local ethics committee approval was not required for this manuscript as this is a retrospective study describing a surgical technique modification.

Patient consent The patients provide standard written informed consent as per our institution's policy for surgery and publication of photographs for this article.

Open Access This article is distributed under the terms of the Creative Commons Attribution 4.0 International License (<http://creativecommons.org/licenses/by/4.0/>), which permits unrestricted use, distribution, and reproduction in any medium, provided you give appropriate credit to the original author(s) and the source, provide a link to the Creative Commons license, and indicate if changes were made.

References

- Roe J (1899) Correction of nasal deformities by subcutaneous operation. *Am Med Q* 1:56
- Joseph J (1931) Nasenplastik um sonstige Gesichtplastik, Webst einem Anhang uber Mammoplastik und einige weitere Operationen aus dem Gebiete der ausseren Korperplastik; Ein Atlas und Lehrbuch. Curt Kabitzsch. Leipzig
- Rethi A (1929) Uber die korrekativen Operationen der Nasen deformitäten I Die Hockerabtragung. *Der Chirurgie* 1:1103
- Vogt T (1983) Tip rhinoplastic operations using a transverse columellar incision. *Aesthetic Plast Surg* 7:13–19
- Gwanmesia I, Couto R, Papay F (2015) A cadaveric study comparing the efficacy of the Sheen spreader graft and the fulcrum spreader graft: part 1. *Plast Reconstr Surg* 136:669–675
- Eren S, Tugrul S, Ozucer B et al (2004) Autospreading spring flap technique for reconstruction of the middle vault. *Aesthetic Plast Surg* 38:322–328
- Passos A, Alonso N, Utsonomia K, Ferreira M (2009) Acurácia da rinometria na avaliação da válvula nasal: estudo em 385 pacientes. *Rev Bras Cir Plast* 24:262–264
- Schlosser R, Park S (1999) Surgery for the dysfunctional nasal valve. Cadaveric analysis and clinical outcomes. *Arch Facial Plast Surg* 1:105–110
- Jalali M (2015) Comparison of effects of spreader grafts and flaring sutures on nasal airway resistance in rhinoplasty. *Eur Arch Otorhinolaringol* 272:2299–2303
- Marakami C (2004) Nasal valve collapse. *Ear Nose Throat J* 83:163–164
- Guyuron B, Uzzo C, Scull H (1999) A practical classification of septonasal deviation and an effective guide to septal surgery. *Plast Reconstr Surg* 104:2202–2209 Discussion 2210–2212
- Teller D (1997) Anatomy of a rhinoplasty: emphasis on the middle third of the nose. *Facial Plast Surg* 13:241–252
- Gruber R, Park E, Newman J et al (2007) The spreader flap in primary rhinoplasty. *Plast Reconstr Surg* 119:1903–1910
- Byrd H, Meade R, Gonyon D (2007) Using the autospreader flaps in primary rhinoplasty. *Plast Reconstr Surg* 119:1902–1987
- Rohrich R (1999) Treatment of the nasal hump with preservation of the cartilaginous framework. *Plast Reconstr Surg* 103:1729–1733 discussion 1734–1735
- Becker D, Becker S (2003) Treatment of nasal obstruction from nasal valve collapse with alar batten grafts. *J Long-Term Eff Med Implants* 13:259–269
- Tastan E, Demirci M, Aydin E et al (2011) A novel method for internal nasal valve reconstruction: H-graft technique. *Laryngoscope* 121:480–486
- Park S (1998) The flaring suture to augment the repair of the dysfunctional nasal valve. *Plast Reconstr Surg* 101:1120–1122
- Seyham A, Ozden S, Gungor M et al (2009) A double-layered stepped spreader graft for the deviated nose. *Ann Plast Surg* 62:604–608
- Zijlker T, Quaedvlieg P (1994) Lateral augmentation of the middle third of the nose with autologous cartilage in nasal valve insufficiency. *Rhinology* 32:34–41
- Pochat V, Alonso N, Meneses J (2010) Avaliação funcional e estética da rinoplastia enxertos cartilaginosos. *Rev Bras Cir Plast* 25:260–270
- Mehmet A, Fariz A, Ersoz-Ozturk A et al (2006) The use of high-density porous polyethylene as a custom-made nasal spreader graft. *Aesthetic Plast Surg* 30:34–41
- Berkowitz R (1995) Barrel vault technique for rhinoplasty. Presented at the poster session of the 28th Annual Meeting of the American Society for aesthetic plastic surgery, San Francisco, Ca
- Oneal R, Berkowitz R (1998) Upper lateral cartilage spreader flaps in rhinoplasty. *Aesthet Surg J* 18:370–371
- Seyhan A (1997) Method for middle vault reconstruction in primary rhinoplasty: upper lateral cartilage bending. *Plast Reconstr Surg* 100:1941–1943
- Reiffel A, Cross K, Spinelli H (2011) Nasal spreader grafts: a comparison of Medpor to autologous tissue reconstruction. *Ann Plast Surg* 66:24–28
- Nyte C (2006) Spreader graft injection with calcium hydroxyapatite: a nonsurgical technique for internal nasal valve collapse. *Laryngoscope* 116:1291–1292
- Nyte C (2007) Hyaluronic acid spreader graft injection for internal nasal valve collapse. *Ear Nose Throat J* 86:272–273
- Zilnik J, Gingrass R (1979) Anatomy of the alar cartilage. *Plast Reconstr Surg* 64:650–653
- Dhong E, Han S, Lee C et al (2002) Anthropometric study of alar cartilage in Asians. *Ann Plast Surg* 48:386–391
- Farahvash M, Ebrahimi A, Farahvash B et al (2012) Anatomic and anthropometric analysis of 72 lower lateral nasal cartilages from fresh Persians (Iranian) cadavers. *Aesthet Surg J* 34:447–453
- Daniel R, Palhazi P, Gerbault O et al (2014) Rhinoplasty: the lateral crura-alar ring. *Aesthet Surg J* 34:526–537
- Sheen J (1984) Spreader graft: a method of reconstructing the roof of the middle nasal vault following rhinoplasty. *Plast Reconstr Surg* 73:230–239
- Bracaglia R, Gentileschi S, D'ettore M et al (2012) A technique to make spreader graft fixation easier. *Plast Reconstr Surg* 129:857e–869e
- Pochat V, Alonso N (2010) Avaliação da permeabilidade das vias aéreas com a utilização dos enxertos expansores (spreader grafts) em rinoplastia: estudo preliminar. *Rev Bras Cir Plast* 25:59–63
- Johnson J (1989) Spreader-graft fixation. *Plast Reconstr Surg* 84:540–541
- Hilberg O, Jackson A, Swift D et al (1986) Acoustic rhinometry: evaluation of nasal cavity geometry by acoustic reflection. *J Appl Physiol* 66:295–303
- Corey J, Gungor A, Nelson R et al (1998) Normative standards for nasal cross-sectional areas by race as measured by acoustic rhinometry. *Otolaryngol Head Neck Surg* 119:389–393
- Hilberg O, Pedersen OF (2000) Acoustic rhinometry: recommendations for technical specifications and standard operating procedures. *Rhinol Suppl* 16:3–17
- Cerkes N (2013) Concurrent elevation of the upper lateral cartilage perichondrium and nasal bone periosteum for management of dorsum: the perichondrio-periosteal flap. *Aesthet Surg J* 33:899–914