



# Hip Arthroscopy: Where We Are, and Where We Are Going

Myung Sik Park, MD, Sun Jung Yoon, MD, Kwang Hun Lee, MD, Hong Man Cho, MD\*, Woo Churl Chung, MD†

*Research Institute of Clinical Medicine of Chonbuk National University-Biomedical Research Institute of Chonbuk National University Hospital, Jeonju, Korea, Department of Orthopedic Surgery, Veteran's Hospital, Gwangju, Korea\*, Department of Orthopedic Surgery, Carollo Hospital, Suncheon, Korea†*

## INTRODUCTION

In 2003, Ganz et al.<sup>1)</sup> described anterior femoroacetabular impingement (FAI) as an under recognized cause of early hip osteoarthritis. Impingement is a purely mechanical hip disorder defined as abnormal contact between skeletal prominence of the acetabula rim or femoral head-neck junction that leads to painful, periarticular joint. If untreated, FAI can lead to end-stage osteoarthritis of the hip joint and may be one of the main causes of so-called primary osteoarthritis of the hip. Depending on the pathomechanism, two types of FAI, pincer and cam can be distinguished. Isolated cam or pincer lesions are not very common; 86% of all affected patients showed combined deformity<sup>2)</sup>. But imaging studies according to Byrd and Jones<sup>3)</sup>, Bellaïche et al.<sup>4)</sup> showed a cam effect in 58% to 73% of cases and mixed cam and pincer effects in 9 to 19% of cases. Anterior FAI has been increasingly recognized over the last five to six years as a cause of hip pain in adults younger than 50

years of age. This FAI was newly identified and recognized as a risk factor for labral, cartilage damage, and early hip osteoarthritis is now understood as a major role of hip primary osteoarthritis<sup>5)</sup>. Clinical signs of FAI often present themselves in active, young adults as groin pain of slow onset, usually noticed after an episode of minor trauma. Most patients are 20 to 50 years old. In 70% of all patients were athletically active and 30% of patients were elite athletes<sup>5)</sup>. Patients complain of sharp pain or lasting aches in the groin which can last from a few minutes to a few hours. Some patients feel apprehension or discomfort in the seated position, particularly when sitting on low seats or while driving.

Usually patients report no pain during walking. Sports most implicated in this condition require repeated forceful flexion of the hip (combat sports, dancing, gymnastics, rowing, hurdle racing, golfing and taekwondo practice).

Imaging studies are very important to find a FAI. We usually use pelvis anteroposterior radiographs (AP), frog-leg lateral view, Dunn 45°, 90° views and false profile views. Pelvis AP view should be used as the standard method to check rotation or tilting deformities. AP view should be taken with the patient in a supine position and the leg internally rotated (15°). The distance between the symphysis pubis and sacro-coccygeal joint should be 1-4 cm<sup>6)</sup>. The physician should carefully evaluate: ① the cross-over sign (local retroversion) which indicates acetabular focal retroversion. In a normal hip, the acetabulum is anteverted; the anterior wall runs medial to the posterior rim without crossing it. In anterior acetabular over coverage, the anterior acetabular rim is projected more lateral than the posterior rim ② the posterior acetabular over coverage can be evaluated by determining the position of the posterior acetabular rim

**Submitted:** January 26, 2015 **1st revision:** February 15, 2015

**Final acceptance:** February 16, 2015

**Address reprint request to**

**Myung Sik Park, MD**

Research Institute of Clinical Medicine of Chonbuk National University-Biomedical Research Institute of Chonbuk National University Hospital, 20 Geumam-dong, Geonjiro, Deokjin-gu, Jeonju-si, Jeollabuk-do 561-712, Korea

**TEL:** +82-63-250-1768 **FAX:** +82-63-271-6538

**E-mail:** mspark@jbnu.ac.kr

This is an Open Access article distributed under the terms of the Creative Commons Attribution Non-Commercial License (<http://creativecommons.org/licenses/by-nc/3.0>) which permits unrestricted non-commercial use, distribution, and reproduction in any medium, provided the original work is properly cited.

relative to the femoral head center. In a normal hip, the posterior rim of the acetabulum runs approximately through the femoral head center. If the posterior wall is too prominent, the projected posterior wall line runs lateral to the femoral head center, indicating posterior FAI in extension and external rotation. The acetabular protrusion (③ coxa profunda), which refers to the degree of displacement of the medial acetabular wall relative to the ilioischial line, can be measured in order to quantify the abnormality. Generally, acetabular over coverage can be judged by the depth of the acetabular fossa. In healthy patients the acetabular fossa is lateral to the ilioischial line. In the case of coxa profunda the acetabular fossa touches or crosses the ilioischial line. In the case of ④ protrusion acetabuli, which represents the worst type of general over coverage, the femoral head crosses the ilioischial line. Coxometric measurement techniques are used to quantify acetabular depth, including the lateral center-edge angle, acetabular index, and femoral head extrusion index. Normally, the lateral center-edge angle varies between 25° and 39°. The acetabular index (also called acetabular roof angle) is formed by a horizontal line through the medial edge of the sclerotic zone and lateral edge of the acetabulum. In hips with coxa profunda or protrusion acetabuli, the acetabular index typically is 0° or even negative. The femoral head extrusion index is defined as the horizontal portion of the femoral head that is uncovered by the acetabulum even if there is maximal extrusion of 25% (indicating dysplasia). Usually a pincer impingement is caused by a focal or general acetabular over coverage with a relatively normal femur or a large deformation of the femoral head. Repeated micro trauma induces cystic deformation of the labrum and bone growth at its base that subsequently ossifies (⑤ os acetabuli). This rim ossification is responsible for additional deepening of the acetabulum and worsening impingement. Pincer impingement is more common in middle-aged women.

False profile view may show an excessively arched acetabular roof, creating ⑥ an exaggerated downward slope of the anterior portion of the roof and thereby exacerbating the pincer effect. This roof curve abnormality has been described elsewhere. It was found in 8% of patients, usually in combination with other morphological abnormalities<sup>7</sup>. It has been postulated that the focal pressure increase resulting from this deformity may precipitate the development of hip osteoarthritis. Most importantly, the surgeon must evaluate joint space

narrowing in order to assess initial hip osteoarthritis. He should then look for indications for arthroscopy. False profile view is not used widely for diagnosing FAI because it does not show the relationship between the anterior and posterior acetabular walls. Rather, it can be used for diagnosing early joint degeneration in the inferior part of the acetabulum, which is also an indication for hip joint preserving surgery<sup>5,7</sup>.

The cam-lesion (femoral neck bump) predominates at the anterosuperior part of the head-neck junction. The osseous irregularity involves superior lateral part loss of the concave of the neck (so-called pistol grip deformity). This abnormality is usually located anteriorly and is therefore not seen on AP view. The frog-leg lateral and lateral Dunn views are more useful in detecting the anterior femoral neck bump lesion<sup>6</sup>. A pistol-grip deformity occurs in approximately 6% of men and 2% of women<sup>6</sup>. It can be quantified by the alpha-angle ( $\alpha$ -angle). The  $\alpha$ -angle is formed by the femoral neck axis and a line connecting the femoral head center with the point of beginning at the asphericity of the superior femoral head contour<sup>8</sup>. A normal  $\alpha$ -angle in AP pelvic view is 65° in men and 50° in women. Most surgeons use 55° as a cut-off value for defining cam-impingement<sup>9</sup>. Magnetic resonance arthrography (MRA) which is also helpful in evaluating casual morphological abnormalities and head asphericity can be used to quantify the  $\alpha$ -angle for the appropriate section. We used an indirect MRA for this purpose (the iMRA method showed a sensitivity of 88% and an accuracy of 90% in detecting labral pathology)<sup>10</sup>.

## HIP ARTHROSCOPIC MANAGEMENT

The goal of FAI treatment is to restore the normal anatomy and to preserve as much as possible the labrum and femoral-head neck junction in case of cam impingement. Arthroscopic treatment of FAI is successful and clinical outcomes are similar to those of open surgical dislocation treatment and have a low complication rate<sup>11,12</sup>. Harris et al.<sup>13</sup> reviewed arthroscopic procedures of 6,000 patients. The three most common diagnoses were labral tear (38%), FAI (36%; cam 37%, pincer 16%, mixed 47%) and osteoarthritis (16%). Both genders were equally represented (52% female and 48% male participants). Most operations were performed in the supine position (62%). Labral treatment (50%) and femoral/acetabular osteochondroplasty (32%) were the

most commonly performed procedures. Only 35% of cases used techniques for accessing the joint (i.e., capsulotomy/capsulectomy). Of those that did only 16% indicated capsular repair.

### 1. Are the Results for Labral Debridement and Refixation Very Similar?

Some surgeons prefer to refixate injured labrums while others prefer to excise degenerated ones. Larson et al.<sup>14</sup> published a comparative study. Group 1 with refixated labrums (50 hips) had better subjective outcomes than group 2 with focally excised or debrided labrums (44 hips) ( $P<0.01$ ). At a mean 3.5 year follow-up, good to excellent results were noted in 68.2% of group 2 and 92% of the refixation group ( $P=0.004$ ). This report also suggests that the labrum provides a sealing function and some degree of joint stability. Debated opinion can be noted a degenerative labrum, on the other hand, may be the source of discomfort and its preservation may result in persistent pain and the added risk of failure of re-attachment.

### 2. Does the Range of Motion Increase after a Cam-resection?

FAI patients have a significantly decreased range of motion with respect to internal rotation of the hip. Audenaert et al.<sup>15</sup> assessed the range of internal rotation in healthy people and found it to be an average of  $27.9^\circ$ . An asymptomatic group had an angle of  $21.1^\circ$  while FAI patients had an angle of  $12.3^\circ$  ( $P<0.001$ ). The range of motion is not related to the size of the cam lesion. Decreased femoral anteversion and increased acetabular over coverage add to the risk of early osteoarthritis. In this case, excessive cam resection may necessitate the restoration of the normal range of motion. Kubiak-Langer et al.<sup>16</sup> reported on the influence of surgical debridement: the average improvement of internal rotation was  $5.4^\circ$  for pincer hips,  $8.5^\circ$  for cam hips, and  $15.7^\circ$  for mixed impingement. Kelly et al.<sup>17</sup> carried out a survey for patients under the age of 40 years: internal rotation of the hip increased from  $9.9^\circ \pm 6.6^\circ$  preoperatively to  $27.6^\circ \pm 6.4^\circ$  after decompression, and  $30.1^\circ \pm 5.3^\circ$  at three months ( $P<0.003$ ). However, hip flexion was not significantly different immediately after decompression, but improved significantly from  $115.7^\circ \pm 13.3^\circ$  preoperatively to  $127.9^\circ \pm 6.6^\circ$  postoperatively (after three months). Although improvement in internal

rotation after decompression increased independently of femoral version, patients with abnormal version had altered internal rotation with increased values associated with increased anteversion and decreased relative retroversion ( $P<0.05$ ). All reports which deal with femoral-osteoplasty for cam impingement show progressive improvement of internal hip rotation after about three months.

### 3. What is the Ideal Amount of Bone Resection to Restore?

The ideal amount of bone resection to restore has not been determined. A standard resection is about 7 to 10 mm from the labral edge (distally). Larger resections can result in loss of the sealing function of the labrum. Decompressions of cam lesions do not influence the ability to restore the  $\alpha$ -angle to below  $50^\circ$ . Resections based on  $\alpha$ -angle restoration should be discouraged. It is important to maintain labral function whenever possible, and attempts should be made to maintain the labral seal function<sup>18</sup>. Sometimes reshaping of the lateral edge of the head could not be completed in AP view. Therefore, some resection was carried out in cross-table lateral view (Dunn  $90^\circ$  view). So we need a multiplane examination of the femoral head-neck junction. In addition, an image intensifier is necessary to understand the three-dimensional pattern of the deformity and to ensure a complete circumferential resection<sup>14</sup>. However, it must be acknowledged that the main reason for hip arthroscopy revision is likely incomplete or inadequate remodeling of FAI deformities.

### 4. Is Capsular Repair to Be Preferred?

Whether one should go ahead with capsular repair or not is an open question (Fig. 1). Domb et al.<sup>19</sup> published a retrospective review of the impact of capsular repair. They compared an unrepaired capsular group (A) comprising 235 patients with a repaired group (B) comprising 168 patients. They tried to determine whether capsular repair showed better results over a two-year period (403 patients). The conclusion was that the capsular repair group was safer and showed better results than the unrepaired group with regard to outcome scores such as hip outcome score-activities of daily living (HOS-ADL) and hip outcome score sport-specific subscale subsets (HOS-SSS), non-arthritic hip scores (NHAS) and

modified Harris hip scores (mHHS). However, when the confounding variables were taken into account, the use of capsular repair did not show clinically relevant superiority over the use of unrepaired capsulectomy. But we must not forget that iatrogenic hip instability has been associated with capsulotomy without repair, labral resection and aggressive labra resection. Excessive resection of the lateral acetabular rim and labrum has led to instability requiring conversion to total hip arthroplasty<sup>20,21</sup>. Acetabular and femoral osteochondroplasty with<sup>22</sup> or without<sup>23</sup> capsular plication has resulted in postoperative dislocation, requiring immediate open revision plication and revision arthroscopic plication two months postoperatively after minor trauma<sup>22</sup>. We agree that a center-edge angle of less than 20° is a contraindication for rim trimming<sup>24</sup>.

### 5. Is Labral Reconstruction with Autograft or Allograft Necessary?

Philippon et al.<sup>27</sup> reported that hip arthroscopic labral reconstruction using iliotibial band autograft was

performed on patients who had a labral deficiency or advanced labral degeneration (mean age, 37 years). These patients had good outcomes and a high satisfaction rating. But lower satisfaction was associated with joint space narrowing (2 mm or less) and increased age<sup>25</sup>. There is a report using a Gracilis tendon which also noted satisfactory results without any complications<sup>26</sup>. However, there were no reports outlining allograft reconstruction results (Fig. 2).

### 6. What Is a Common Cause of Second-look Hip Arthroscopy?

The most common cause for revision hip arthroscopy is a residual deformity<sup>14</sup>. Ross et al.<sup>26</sup> reported that 90% of patients undergoing revision surgery for symptomatic FAI had residual deformities; the mean maximal alpha angle in revision hips was 68° ± 16° and most often located at 1:15, considering the acetabulum as a clock face and 1 to 5 o'clock as anterior independent of side. They found marked radiographic evidence of incomplete correction of deformities in patients with residual

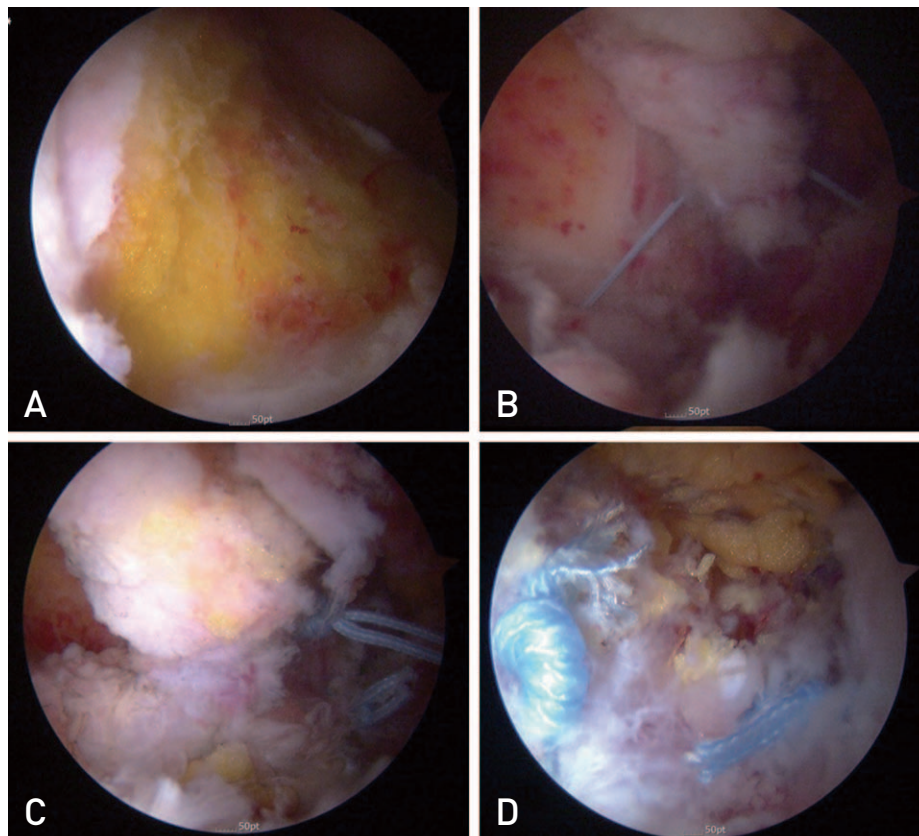


Fig. 1. This photograph shows a sequences of capsular repair process after cam resection through the anterolateral portal.

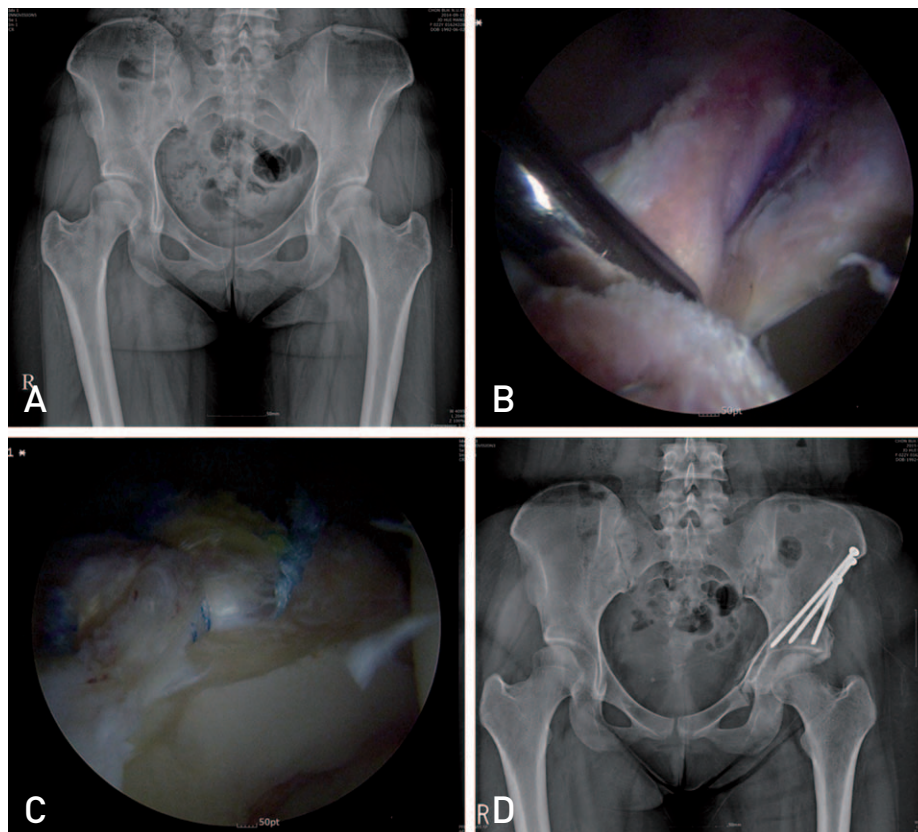
symptoms compared with patients with successful results. However, the causes are little different in adolescent patients. Sixty consecutive pediatric and adolescent patients (65 hips), aged 16 years or younger, who underwent hip arthroscopy were retrospectively analyzed. According to the index procedure, 8 patients (all girls) needed second-look diagnostic arthroscopies because of intra-articular adhesions<sup>28</sup>.

## 7. What Are Minor and Major Complications of Hip Arthroscopy?

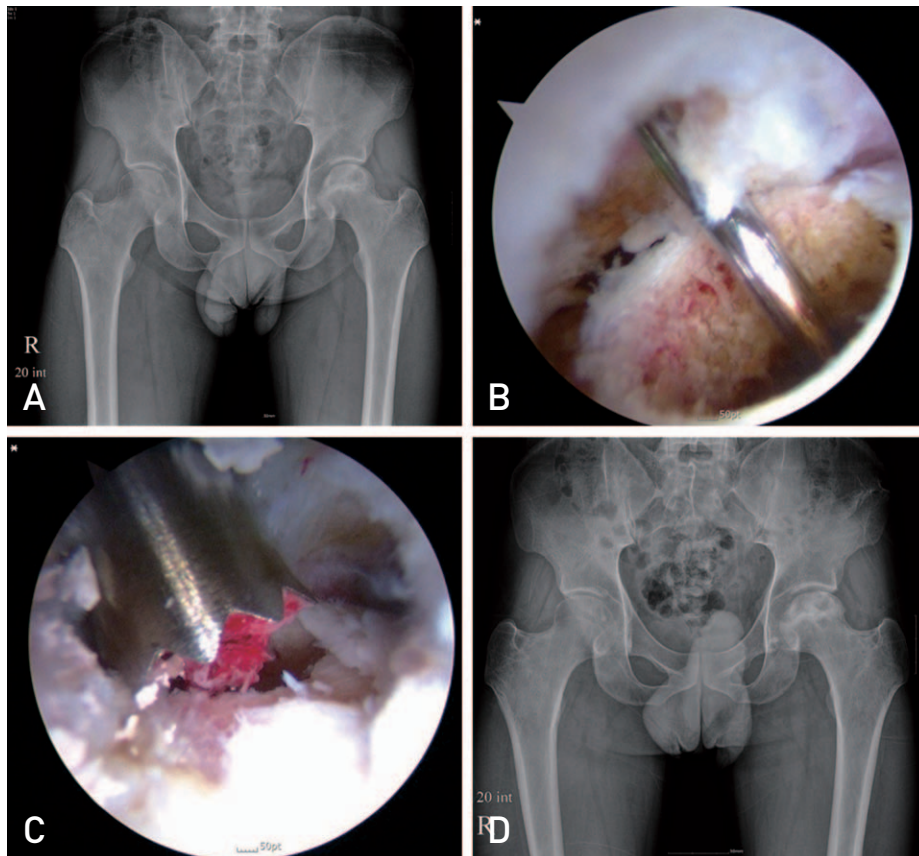
Harris et al.<sup>13</sup> reported a systemic review of 6,344 hips (6,134 patients; mean participant age, 34.4 years). These were subdivided into minor complications (iatrogenic chondral damage, temporary nerve palsy, superficial infection, hypothermia, deep vein thrombosis, broken instrumentation, heterotopic ossification) and major complications (deep infection, skin damage, pulmonary embolus, intra-abdominal or intrathoracic extravasation, requiring surgical decompression drainage, large vessel

vascular injury, avascular necrosis, femoral neck fracture, dislocation, death). All information used in this review was extracted from these articles. There was a 7.5% minor complication rate. Iatrogenic chondral and labral injuries during portal placement were the most common complications. And the most common neural complications were temporary pudendal nerve and lateral femoral cutaneous nerve injuries. There was a 0.58% major complication rate. Of these, damage to the perineal skin, hip dislocation, intra-abdominal and intrathoracic fluid extravasation, hypothermia, infection, thromboembolic phenomena, avascular necrosis, heterotopic ossification, femoral neck fracture and death all occurred in less than 1% of patients.

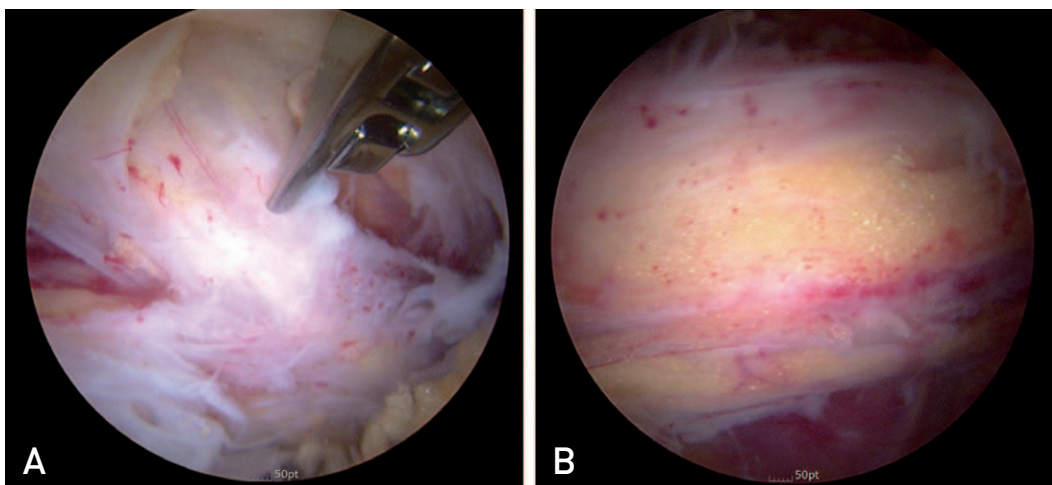
The authors of this paper experienced a new complication: a second-degree burn while working through the anterolateral portal. This thermal burn was caused by insufficient pumping action<sup>29</sup>.



**Fig. 2.** Nineteen-year-old female with hip dysplasia. **(A)** Preoperative pelvis anteroposterior radiograph view. **(B)** Intraoperative view, labral reconstruction process using an allograft in right hip. **(C)** After reconstruction with allograft. **(D)** Periacetabular osteotomy was performed to the left hip shows more advanced dysplasia than right hip.



**Fig. 3.** Thirty one-year male patient who had an idiopathic avascular necrosis of left hip, who wanted to preserve his hip. Bone graft to lesion using hip arthroscopy. **(A)** Preoperative pelvis anteroposterior radiograph shows avascular necrosis (AVN) of left femoral head (grade II). **(B)** Making a hole at the femoral neck. **(C)** Autogenous bone graft. **(D)** Four years later, no progression AVN of left femoral head.



**Fig. 4.** This patient complained of sitting pain and tenderness in the groin area. **(A)** Release of the scar tissue and blood vessel over the sciatic nerve. **(B)** Sciatic nerve without compression.

## 8. What Are the Main Issues in Hip Arthroscopy Today and What Will the Future Bring?

There are papers reporting on femoral head fractures, avascular necrosis of the femoral head, and deep gluteal syndromes that were all managed by hip arthroscopy (Fig. 3). Park et al.<sup>30)</sup> reported that a femoral head fracture dislocation (Pipkin I) was successfully managed and internally fixed using arthroscopy. Recently a few reports were published that deal with the assessment and management of avascular necrosis of the femoral head using bone grafts and hip arthroscopy<sup>31,32)</sup>.

Another new field of application for arthroscopy is deep gluteal syndrome (DGS), which is also called sciatic nerve entrapment in the gluteal region (including piriformis syndrome) (Fig. 4). According to Martin et al.<sup>33)</sup>, DGS was successfully managed using a hip arthroscopic instrument.

We can imagine that in the future the indication will be expanded to the pelvic cavity such as endoscopic pelvic surgery, e.g., pudendal nerve entrapment syndrome, reduction of fractures of the pelvic bone, assessing the cutting line near the sciatic nerve (pelvic osteotomy), and inserting an electrode into sciatic nerves in the case of paralyzed patients.

## CONCLUSION

FAI is becoming one of the most frequent indications for hip arthroscopy. Due to the technical complexity of hip arthroscopy it is necessary to carefully select suitable patients for this procedure. Complications are directly related to technical aspects of the procedure and will therefore decrease with surgeon experience and better instrumentation. In spite of the great effort needed to master this technique, hip arthroscopy should be expanded to intra-articular and extra-articular hip disease.

## REFERENCES

- Ganz R, Parvizi J, Beck M, Leunig M, Nötzli H, Siebenrock KA. *Femoroacetabular impingement: a cause for osteoarthritis of the hip. Clin Orthop Relat Res.* 2003;417:112-20.
- Beck M, Kalhor M, Leunig M, Ganz R. *Hip morphology influences the pattern of damage to the acetabular cartilage: femoroacetabular impingement as a cause of early osteoarthritis of the hip. J Bone Joint Surg Br.* 2005;87:1012-8.
- Byrd JW, Jones KS. *Prospective analysis of hip arthroscopy with 2-year follow-up. Arthroscopy.* 2000;16:578-87.
- Bellaïche L, Lequesne M, Gedouin JE, Laude F, Boyer T. *French Arthroscopy Society. Imaging data in a prospective series of adult hip pain in under-50 year-olds. Orthop Traumatol Surg Res.* 2010;96(8 Suppl):S44-52.
- Lequesne M, Bellaïche L. *Anterior femoroacetabular impingement: an update. Joint Bone Spine.* 2012;79:249-55.
- Tannast M, Siebenrock KA. *Conventional radiographs to assess femoroacetabular impingement. Instr Course Lect.* 2009;58:203-12.
- Lequesne MG, Laredo JD. *The faux profil (oblique view) of the hip in the standing position. Contribution to the evaluation of osteoarthritis of the adult hip. Ann Rheum Dis.* 1998;57:676-81.
- Nötzli HP, Wyss TF, Stoecklin CH, Schmid MR, Treiber K, Hodler J. *The contour of the femoral head-neck junction as a predictor for the risk of anterior impingement. J Bone Joint Surg Br.* 2002;84:556-60.
- Vaughn ZD, Safran MR. *Arthroscopic femoral osteoplasty/for cam-type femoroacetabular impingement in the athlete. Sports Med Arthrosc.* 2010;18:90-9.
- Rakhra KS. *Magnetic resonance imaging of acetabular labral tears. J Bone Joint Surg Am.* 2011;93 Suppl 2:28-34.
- Botser IB, Smith TW Jr, Nasser R, Domb BG. *Open surgical dislocation versus arthroscopy for femoroacetabular impingement: a comparison of clinical outcomes. Arthroscopy.* 2011;27:270-8.
- Matsuda DK, Carlisle JC, Arthurs SC, Wierks CH, Philippon MJ. *Comparative systematic review of the open dislocation, mini-open, and arthroscopic surgeries for femoroacetabular impingement. Arthroscopy.* 2011;27:252-69.
- Harris JD, McCormick FM, Abrams GD, et al. *Complications and reoperations during and after hip arthroscopy: a systematic review of 92 studies and more than 6,000 patients. Arthroscopy.* 2013;29:589-95.
- Larson CM, Giveans MR, Stone RM. *Arthroscopic debridement versus refixation of the acetabular labrum associated with femoroacetabular impingement: mean 3.5-year follow-up. Am J Sports Med.* 2012;40:1015-21.
- Audenaert EA, Peeters I, Vigneron L, Baelde N, Pattyn C. *Hip morphological characteristics and range of internal rotation in femoroacetabular impingement. Am J Sports Med.* 2012;40:1329-36.
- Kubiak-Langer M, Tannast M, Murphy SB, Siebenrock KA, Langlotz F. *Range of motion in anterior femoroacetabular impingement. Clin Orthop Relat Res.* 2007;458:117-24.
- Kelly BT, Bedi A, Robertson CM, Dela Torre K, Giveans MR, Larson CM. *Alterations in internal rotation and alpha angles are associated with arthroscopic cam decompression in the hip. Am J Sports Med.* 2012;40:1107-12.
- Ilizaliturri VM Jr. *Complications of arthroscopic femoroacetabular impingement treatment: a review. Clin Orthop Relat Res.* 2009;467:760-8.
- Domb BG, Stake CE, Finley ZJ, Chen T, Giordano BD. *Influence of capsular repair versus unrepaired capsulotomy on 2-year clinical outcomes after arthroscopic hip preservation surgery. Arthroscopy. Published online December 16, 2014; doi: 10.1016/j.arthro.2014.10.014.*
- Philippon MJ, Schenker ML. *Athletic hip injuries and capsular laxity. Oper Tech Orthop.* 2005;15:261-6.

21. Philippon MJ, Schenker ML, Briggs KK, Maxwell RB. *Can microfracture produce repair tissue in acetabular chondral defects?* *Arthroscopy*. 2008;24:46-50.
22. Karthikeyan S, Roberts S, Griffin D. *Microfracture for acetabular chondral defects in patients with femoroacetabular impingement: results at second-look arthroscopic surgery.* *Am J Sports Med*. 2012;40:2725-30.
23. Domb BG, Redmond JM, Dunne KF, Stake CE, Gupta A. *A matched-pair controlled study of microfracture of the hip with average 2-year follow-up: Do full-thickness chondral defects portend an inferior prognosis in hip arthroscopy?* *Arthroscopy*. Published online December 10, 2014; doi: 10.1016/j.arthro.2014.10.011.
24. Geyer MR, Philippon MJ, Fagrelus TS, Briggs KK. *Acetabular labral reconstruction with an iliotibial band autograft: outcome and survivorship analysis at minimum 3-year follow-up.* *Am J Sports Med*. 2013;41:1750-6.
25. Matsuda DK, Burchette RJ. *Arthroscopic hip labral reconstruction with a gracilis autograft versus labral refixation: 2-year minimum outcomes.* *Am J Sports Med*. 2013;41:980-7.
26. Ross JR, Larson CM, Adeoyo O, Kelly BT, Bedi A. *Residual deformity is the most common reason for revision hip arthroscopy: a three-dimensional CT study.* *Clin Orthop Relat Res*. Published online December 5, 2014; <http://dx.doi.org/10.1007/s11999-014-4069-9>.
27. Philippon MJ, Stubbs AJ, Schenker ML, Maxwell RB, Ganz R, Leunig M. *Arthroscopic management of femoroacetabular impingement: osteoplasty technique and literature review.* *Am J Sports Med*. 2007;35:1571-80.
28. Philippon MJ, Ejnisman L, Ellis HB, Briggs KK. *Outcomes 2 to 5 years following hip arthroscopy for femoroacetabular impingement in the patient aged 11 to 16 years.* *Arthroscopy*. 2012;28:1255-61.
29. Park MS, Yoon SJ, Kim YJ, Chung WC. *Hip arthroscopy for femoroacetabular impingement: the changing nature and severity of associated complications over time.* *Arthroscopy*. 2014;30:957-63.
30. Park MS, Yoon SJ, Choi SM. *Arthroscopic reduction and internal fixation of femoral head fractures.* *J Orthop Trauma*. 2014;28:e164-8.
31. Pierannunzii L. *Endoscopic and arthroscopic assistance in femoral head core decompression.* *Arthrosc Tech*. 2012;1:e225-30.
32. Ellenrieder M, Tischer T, Kreuz PC, Fröhlich S, Fritsche A, Mittelmeier W. *Arthroscopically assisted therapy of avascular necrosis of the femoral head.* *Oper Orthop Traumatol*. 2013;25:85-94.
33. Martin HD, Shears SA, Johnson JC, Smathers AM, Palmer IJ. *The endoscopic treatment of sciatic nerve entrapment/deep gluteal syndrome.* *Arthroscopy*. 2011;27:172-81.