


HOSTED BY



ELSEVIER

Available online at www.sciencedirect.com

ScienceDirect

journal homepage: www.elsevier.com/locate/IPEJ

CrossMark

An unusual WPW syndrome: What is the preexcitation variant?

Hussam Ali ^{a,*}, Antonio Sorgente ^b, Guido De Ambroggi ^a,
Riccardo Cappato ^c

^a Arrhythmia & Electrophysiology Unit II, Humanitas Gavazzeni Clinics, Bergamo, Italy

^b Heart & Vascular Institute, Cleveland Clinic Abu Dhabi, Abu Dhabi, United Arab Emirates

^c Arrhythmia & Electrophysiology Research Center, Humanitas Clinical & Research Center, Rozzano, Milan, Italy

ARTICLE INFO

Article history:

Available online 17 November 2015

Keywords:

WPW syndrome

Mahaim

Preexcitation variant

Catheter ablation

ABSTRACT

A 15-year-old female with WPW syndrome and normal heart underwent an electrophysiology study for paroxysmal palpitations and syncope. Intravenous adenosine produced an unexpected response of QRS changes and advanced AV block. During isoproterenol infusion, short-lasting and poorly tolerated wide QRS tachycardia was inducible, but pacing maneuvers were not feasible during tachycardia to determine its definitive mechanism. However, various electrophysiologic phenomena including adenosine response, junctional beats pattern, and multisite atrial pacing were helpful to overcome the diagnosis challenges. Finally, careful evaluation of tachycardia features and the comprehensive electrophysiology study were crucial to establish presence of unusual preexcitation variants, and thus to guide successful catheter ablation of the arrhythmic substrate.

Copyright © 2015, Indian Heart Rhythm Society. Production and hosting by Elsevier B.V.

This is an open access article under the CC BY-NC-ND license (<http://creativecommons.org/licenses/by-nc-nd/4.0/>).

Case presentation

A 15-year-old female with WPW and normal heart was referred to our center because of paroxysmal palpitations and syncope. Electrophysiology study (EPS) was performed, and multipolar diagnostic catheters were positioned in the coronary sinus (CS) and para-Hisian region. Her 12-lead ECG showed sinus rhythm with minimal preexcitation and occasional junctional beats (Fig. 1A). Baseline AH and HV intervals were 70 and 25 ms, respectively. Retrograde conduction was concentric and decremental. Incremental distal CS pacing showed progressive prolongation of the stimulus-delta

interval with no change in QRS morphology, except for few beats with a wider QRS pattern just after the Wenckebach AV block. During atrial pacing, intravenous adenosine induced an advanced AV block (AVB) episode (Fig. 1B). Based on these observations, what is the preexcitation variant?

Discussion

The differential diagnosis of this preexcitation pattern may include: 1) a right-sided accessory pathway (AP) with enhanced nodal AV conduction. 2) a fasciculoventricular pathway (FVP). 3) a nodoventricular pathway (NVP). 4) an AV

* Corresponding author. Arrhythmia & Electrophysiology Unit II, Humanitas Gavazzeni Clinics, Via M. Gavazzeni 21, 24125 Bergamo, Italy. Tel.: +39 0354204005; fax: +39 0282246453.

E-mail address: hussamali.ep@gmail.com (H. Ali).

Peer review under responsibility of Indian Heart Rhythm Society.

<http://dx.doi.org/10.1016/j.ipej.2015.11.001>

0972-6292/Copyright © 2015, Indian Heart Rhythm Society. Production and hosting by Elsevier B.V. This is an open access article under the CC BY-NC-ND license (<http://creativecommons.org/licenses/by-nc-nd/4.0/>).

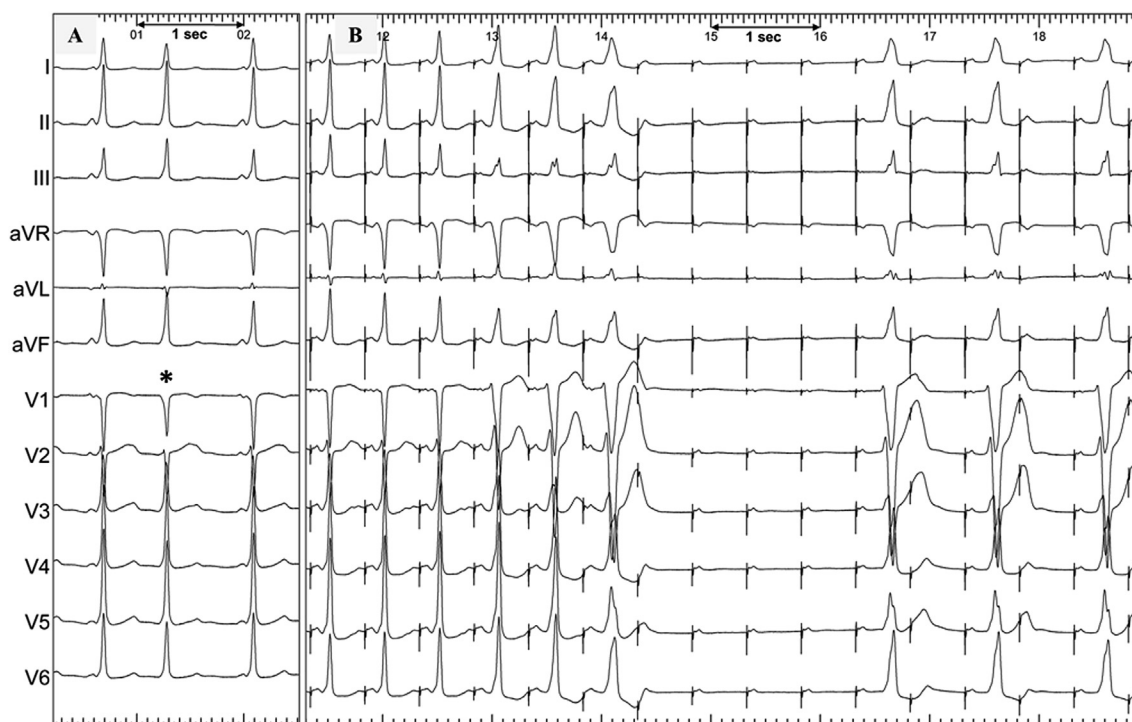


Fig. 1 – 12-lead ECG during sinus rhythm showing an occasional junctional beat (the asterisk, panel A), and during atrial pacing showing adenosine-induced AVB (panel B). See text for discussion.

Mahaim-like AP. 5) a combination of more than one of these AP types.

The preexcitation pattern (Fig. 1A) shows QS morphology in V1 and R/S transition between V2–V3, suggesting a right-sided AP. However, the latter AP typically presents with more evident preexcitation during sinus rhythm (P on Delta phenomenon) and a shorter HV interval. An exception might be the coexistence of accelerated or enhanced nodal AV conduction, which was not present in this case (a normal AH interval of 70 ms).

Interestingly, occasional junctional beats replicated the preexcitation morphology (the asterisk in Fig. 1A) indicating the presence of an infra-atrial AP (typically an FVP) [1]. However, preexcited junctional beats could be observed in NVP if they originate proximally in the AV node [2]. Furthermore, this phenomenon does not exclude the coexistence of an AV-AP.

During atrial pacing, intravenous adenosine induced an advanced AVB followed by a phase of 2:1 AVB (Fig. 1B). This indicates the presence of AP(s) with nodal-like properties (Mahaim physiology). Noteworthy, P-delta prolongation and a wider QRS morphology were observed before the advanced AVB and also during the phase of 2:1 AVB. This change in QRS morphology/preexcitation degree is not compatible with a lone FVP which typically shows minimal and fixed preexcitation even with variable nodal conduction times, unless aberrant conduction is present. The wider QRS morphology was unlikely to be caused by a coexistent, bradycardia-dependent, left bundle branch block (LBBB) since it was not only observed during bradycardia (2:1 AVB) but also at a similar pacing cycle length preceding the advanced AVB

(Fig. 1B). On the other hand, an NVP may demonstrate increased preexcitation and negative HV intervals since it bypasses only a portion of the AV node. Moreover, conduction delay over the left bundle, or preexcitation over an atrio/nodofascicular AP (inserting into the right bundle), usually present a typical LBBB pattern with rapid QRS onset and not the observed slow delta waves [3].

Accordingly, these electrocardiographic features of a minimal and right-sided preexcitation pattern, preexcited junctional beats, adenosine-responsiveness, and variable preexcitation degrees are best explained by the presence of an NVP or the coexistence of an FVP and a right-sided Mahaim-like AV-AP.

During isoproterenol infusion, short-lasting episodes of a wide QRS tachycardia were inducible by atrial overdrive pacing (independently on AH prolongation), or occasionally after premature ventricular beats (Fig. 2A). Unfortunately, no diagnostic pacing maneuvers were applicable during tachycardia since it often terminated spontaneously (~10 s), and it was also associated with significant hemodynamic instability due to its high rate (240–250 bpm). QRS morphology during tachycardia was similar to the wider QRS morphology observed during the adenosine-test or rapid atrial pacing. Intracardiac recordings showed constant 1:1 AV rapport, concentric atrial activation (identical to that during RV pacing), and the AV and VA intervals were 168 and 80 ms, respectively (Fig. 2B). No His potentials preceding the QRS were recorded, being apparently buried within the local ventricular electrograms (i.e., a negative HV interval). Interestingly, spontaneous termination of tachycardia showed V–V

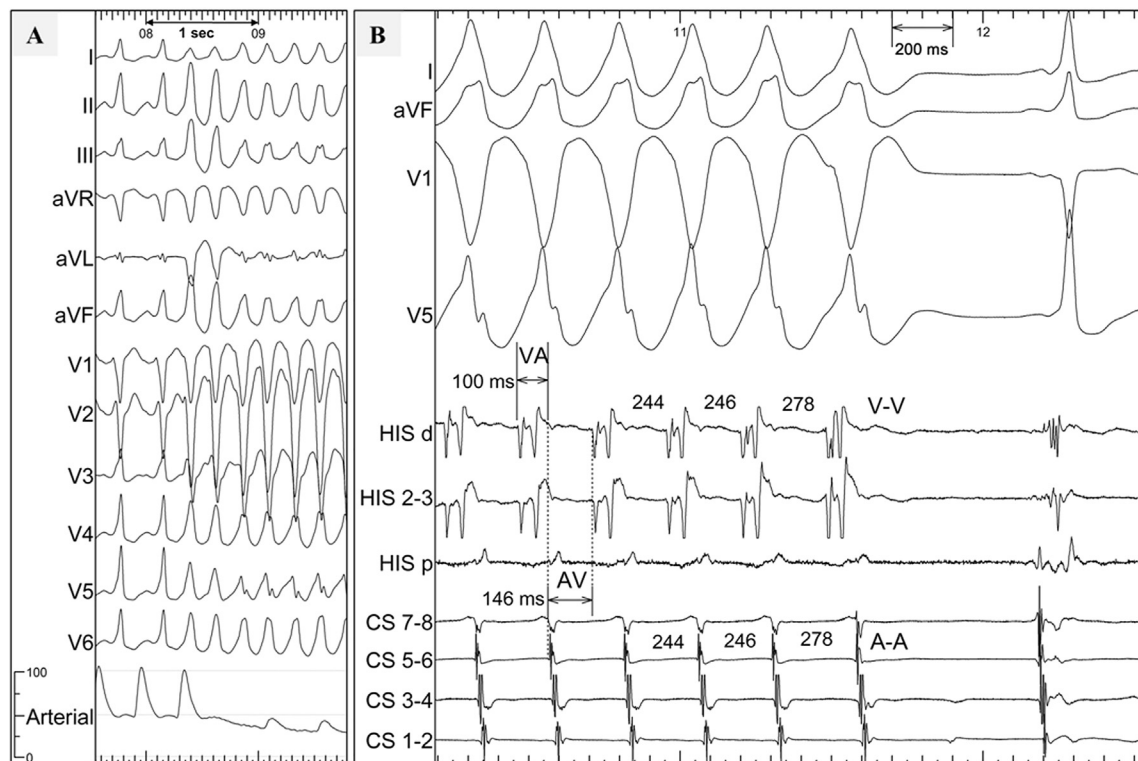


Fig. 2 – A) 12-lead ECG demonstrating the onset of a fast, and hemodynamically unstable, wide QRS tachycardia after a couple of mechanically-induced premature ventricular beats. B) ECG and intracardiac recordings showing spontaneous termination of the tachycardia. Note that tachycardia terminated with an A, and variations in the V–V intervals preceded those of the A–A intervals. CS = coronary sinus; distal electrodes → n°1.

prolongation preceding A–A variation before tachycardia termination with an A.

In order to elucidate the preexcitation pattern, an additional diagnostic catheter was placed in the right atrial appendage (RAA). Importantly, multisite atrial pacing at similar rates (400 ms) caused increased preexcitation during RAA, and not distal CS, pacing (Fig. 3A). This observation confirms the presence of an AV-AP and excludes the presence of a lone infra-atrial AP (e.g., NVP or FVP). Moreover, incremental RAA pacing demonstrated progressive prolongation of the stimulus-delta interval through the wider QRS morphology (decremental conduction).

Hence, the most appropriate diagnosis of this unusual preexcitation is the coexistence of an FVP and a right-sided Mahaim-like AV-AP. As mentioned earlier, due to tachycardia intolerance/spontaneous termination, we couldn't apply premature atrial extrastimuli which would have proven the proposed mechanism of this wide QRS tachycardia. However, tachycardia features and the basal EPS strongly suggested the diagnosis of an antidromic AV reciprocating tachycardia using a slowly conducting, Mahaim-like AV-AP.

Mapping the latter AP was performed during relatively fast RAA pacing (reproducing the wider QRS morphology) and using a non-irrigated, 4 mm-tip ablation catheter. The ventricular insertion of this pathway was localized at the superior

tricuspid annulus adjacent to the His bundle recording site (~1 cm as shown in the radiogram in Fig. 3B). Initially, a femoral vein approach did not provide optimal contact and stability of the ablation catheter at the area of interest. Therefore, a right jugular vein approach was performed and conventional radiofrequency (RF) ablation (25 W, 52 °C) at the site recording an early pre-potential (the arrow is in Fig. 3B), resulted in AV-AP block with a shift in QRS morphology from the overt to the residual minimal preexcitation pattern over the innocent FVP (Fig. 3C).

No automatic rhythm was observed during RF, but might be suppressed by the fast atrial pacing used during ablation. Interestingly, prior to RF ablation, transient episodes of mechanical AP Block were observed during mapping, a well-described phenomenon in Mahaim-like pathways [4]. After ablation, repeated pacing maneuvers confirmed the presence of a lone FVP with a minimal and fixed preexcitation degree (i.e., HV interval), even with multisite atrial pacing and at different pacing cycle lengths. No tachycardia was anymore inducible and nodal AV conduction was preserved. During one-year follow-up, the patient remained asymptomatic off antiarrhythmic drugs.

In summary, this case highlights the diagnostic difficulties in an unusual preexcitation pattern with double, adjacent, Mahaim-like pathways (an innocent FVP and an AV Mahaim-like AP). The close proximity of these pathways

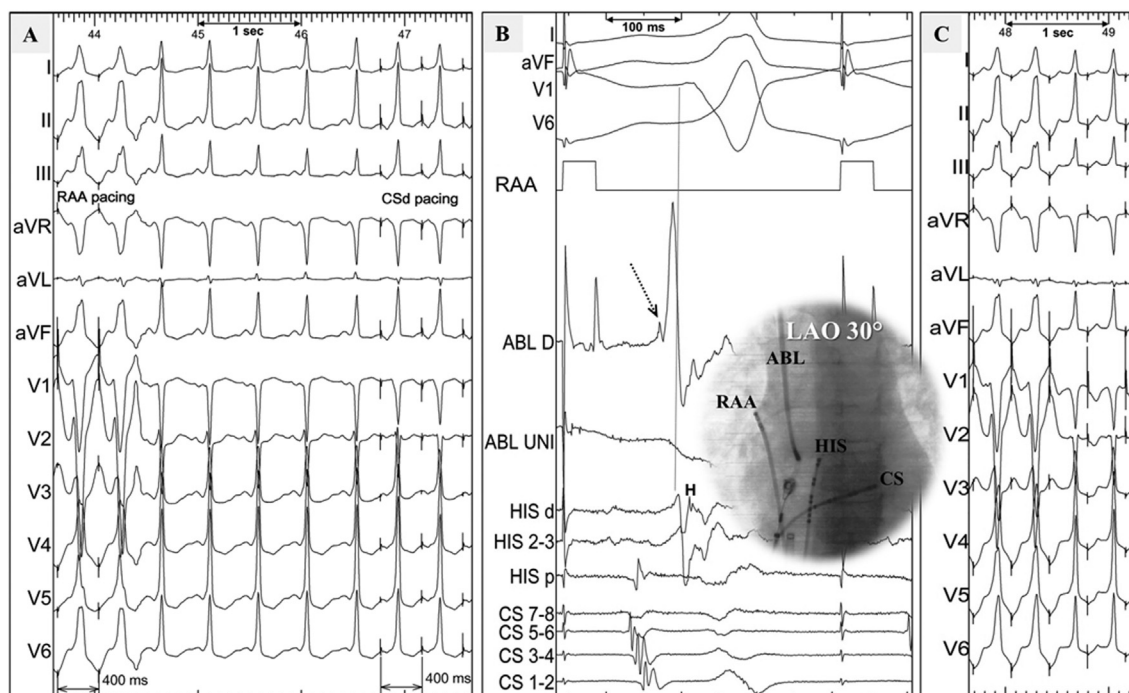


Fig. 3 – A) Continuous 12-lead ECG showing variable QRS morphologies during multisite atrial pacing (RAA vs distal CS) at the same pacing rate (400 ms). B) The successful ablation site recording early ventricular activation (the dotted arrow) preceding the delta wave onset (the vertical dotted line) during rapid RAA pacing. The LAO radiogram shows the proximity of the successful ablation site of the AV Mahaim-like AP (at the superior tricuspid annulus) to the His region (insertion site of the FVP). C) 12-lead ECG during rapid RAA pacing and RF ablation at that site showing clear shift in QRS morphology due to antegrade block of the AV Mahaim-like AP with residual minimal preexcitation over the FVP. ABL = ablation catheter; d = distal; H = His potential; LAO = left anterior oblique; p = proximal; RAA = right atrial appendage; UNI = unipolar recording.

giving similar initial delta polarities, and the shared Mahaim-like features (adenosine responsiveness and stimulus-delta prolongation at faster atrial rates); might have suggested the presence of a single AP. Mapping during sinus rhythm in this case would have been misleading with unnecessary, and potentially harmful, ablation attempts of the innocent FVP.

Moreover, even when the index tachycardia is not sustained or tolerated, the basal EPS with emphasis on multisite atrial pacing maneuvers, adenosine-response, and junctional beats pattern, is still crucial to establish the correct diagnosis of preexcitation variant and to guide catheter ablation of the arrhythmic substrate.

Financial disclosures/conflict of interest

None.

REFERENCES

- [1] Sternick EB, Gerken LM, Vrandečić MO, Wellens HJ. Fasciculoventricular pathways: clinical and electrophysiologic characteristics of a variant of preexcitation. *J Cardiovasc Electrophysiol* 2003;14:1057–63.
- [2] Hoffmayer KS, Lee BK, Vedantham V, Bhimani AA, Cakulev IT, Mackall JA, et al. Variable clinical features and ablation of manifest nodofascicular/ventricular pathways. *Circ Arrhythm Electrophysiol* 2015;8:117–27.
- [3] Tchou P, Lehmann MH, Jazayeri M, Akhtar M. Atriofascicular connection or a nodoventricular Mahaim fiber? electrophysiologic elucidation of the pathway and associated reentrant circuit. *Circulation* 1988;77:837–48.
- [4] Cappato R, Schlüter M, Weiss C, Siebels J, Hebe J, Duckeck W, et al. Catheter-induced mechanical conduction block of right-sided accessory fibers with Mahaim-type preexcitation to guide radiofrequency ablation. *Circulation* 1994;90:282–90.