

Comparing the Use of Axillary Radiographs and Axial Computed Tomography Scans to Predict Concentric Glenoid Wear

Kofi D. Agyeman, MD, Paul DeVito, DO, Emmanuel McNeely, MS, MPA, Andy Malarkey, DO, Michael J. Bercik, MD, and Jonathan C. Levy, MD

Investigation performed at the Holy Cross Orthopedic Institute and Holy Cross Hospital, Fort Lauderdale, Florida

Background: Axillary radiographs traditionally have been considered sufficient to identify concentric glenoid wear in osteoarthritic shoulders; however, with variable glenoid wear patterns, assessment with use of computed tomography (CT) has been recommended. The purpose of the present study was to compare the use of axillary radiographs and mid-glenoid axial CT scans to identify glenoid wear.

Methods: Preoperative axillary radiographs and mid-glenoid axial CT scans for 330 patients who underwent anatomic total shoulder arthroplasty were reviewed. Five independent examiners with differing levels of experience characterized the glenoid morphology as either concentric or eccentric. The morphologies determined with use of axillary radiographs and CT scans were assessed for correlation, and both intraobserver and interobserver consistency were calculated.

Results: Concentric wear identified with use of radiographs was confirmed with use of CT scans in an average of 61% of cases (range, 53% to 76%). Intraobserver consistency averaged 75% for radiographs and 73% for CT scans. There was significant interobserver consistency, as higher levels of training corresponded with greater consistency between imaging analyses ($p < 0.001$). The most senior observer identified the highest proportion of concentric wear on radiographs ($p < 0.001$), showed the greatest consistency between attempts when using CT ($p < 0.001$), and had the greatest agreement of radiographs and CT evaluating glenoid morphology ($p < 0.001$).

Conclusions: For the experienced shoulder surgeon, concentric glenoid wear identified on axillary radiographs will appear concentric on 2-dimensional CT in approximately 75% of cases. Obtaining a CT scan to confirm glenoid wear patterns most greatly benefits less-experienced surgeons. Across all levels of experience, axillary radiographs and single-slice, mid-glenoid CT scans appear insufficient for consistently predicting wear patterns.

Level of Evidence: Diagnostic Level III. See Instructions for Authors for a complete description of levels of evidence.

Recognition of glenoid wear is a critical step in surgical planning for shoulder arthroplasty because different wear patterns sometimes require modification of the surgical technique and implant selection¹⁻¹³. Axillary radiographs traditionally have been considered sufficient for preoperative assessment of glenoid wear patterns in osteoarthritic shoulders¹⁴. Several studies have emphasized the use of axillary radiographs in evaluating glenoid morphology because of the ability to anticipate glenoid wear and morphology, the lower costs, and the relatively limited exposure to radiation¹⁵⁻¹⁷. How-

ever, the recognition of eccentric patterns of glenoid wear has led to an emphasis on assessment with use of 2-dimensional computed tomography (CT)^{10,18}, with 3-dimensional reconstructions further increasing accuracy when determining the location and severity of eccentric wear¹⁸⁻²¹. Consequently, a number of classifications of been developed to facilitate recognition of glenoid wear, including Levine (standard radiographs)¹⁴, Walch (2-dimensional CT)¹⁰, and Bercik (a modification of the Walch classification using 3-dimensional reconstruction)²¹.

Disclosure: This study was supported by a research grant from DJO Global, Inc. The funding source did not play a role in the investigation. On the **Disclosure of Potential Conflicts of Interest** forms, which are provided with the online version of the article, one or more of the authors checked "yes" to indicate that the author had a relevant financial relationship in the biomedical arena outside the submitted work, including with DJO Global, Inc. (<http://links.lww.com/JBJSOA/A138>).

Copyright © 2020 The Authors. Published by The Journal of Bone and Joint Surgery, Incorporated. All rights reserved. This is an open-access article distributed under the terms of the [Creative Commons Attribution-Non Commercial-No Derivatives License 4.0](https://creativecommons.org/licenses/by-nc-nd/4.0/) (CCBY-NC-ND), where it is permissible to download and share the work provided it is properly cited. The work cannot be changed in any way or used commercially without permission from the journal.

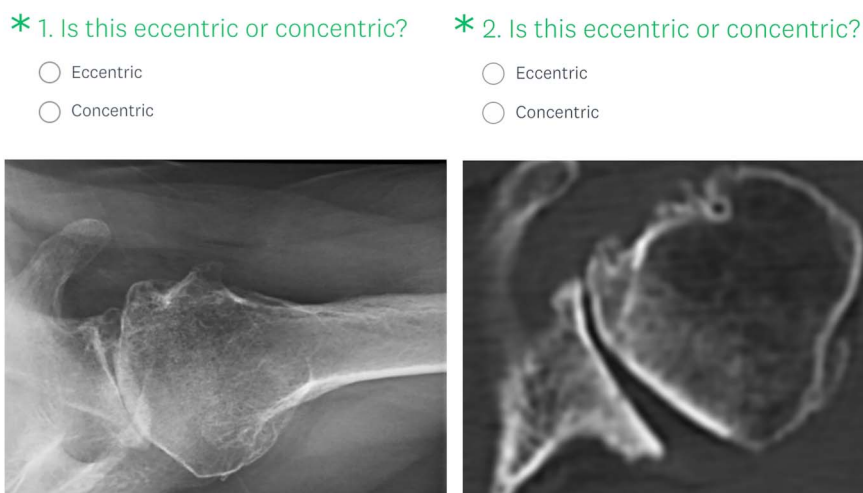


Fig. 1
Example of survey questions. For each axillary radiograph (left panel) and mid-axial CT image (right panel), the reviewer was asked to classify the image as eccentric or concentric wear.

Levine et al.¹⁴ reviewed axillary radiographs for patients who underwent hemiarthroplasty for glenohumeral osteoarthritis, and subdivided glenoid morphology as concentric (Class 1) and eccentric (Class 2) because of the propensity for less satisfactory results in patients with eccentric wear patterns. Hussey et al. adapted the Levine classification to involve the use of axial CT scans to describe concentric and eccentric wear patterns¹⁸. Although symmetric erosion and relatively evenly distributed cyst/sclerosis formation signifies a concentric, uniconcave glenoid, eccentrically worn glenoids show asymmetry in deformity and resultant biconcavity¹⁸. Identification of eccentric wear patterns has great importance for anatomic shoulder arthroplasty, as modifications of the surgical technique and/or implant selection may be required as a direct result of the glenoid wear. If an axillary radiograph can reliably identify a concentric wear pattern, then it may be possible to proceed with anatomic shoulder arthroplasty without the use of an additional CT scan for surgical planning purposes, reserving additional imaging for those patients with radiographs demonstrating eccentric glenoid wear.

The purpose of the present study was to compare the use of axillary radiographs and mid-glenoid axial CT scans to identify

concentric glenoid wear. We assessed whether axillary radiographs could consistently be used to predict concentric glenoid wear on CT scans, calculated the intraobserver and interobserver consistency for identifying wear patterns, and determined the impact of surgeon experience on the consistency of identifying glenoid wear. We hypothesized that glenoid wear identified on axillary radiographs would correlate well with that identified on CT scans, with good intraobserver and interobserver consistency and improved consistency with increased surgeon experience.

Materials and Methods

We retrospectively queried the Shoulder and Elbow Surgery Registry at our institution in order to identify all patients who had undergone primary anatomic total shoulder arthroplasty between April 2009 and October 2015. The query identified 380 patients with preoperative axillary radiographs and CT scans. Axillary radiographs were reviewed for quality, which led to 50 patients being excluded by the surgeon administrator (K.D.A.) for poor quality secondary to inadequate penetration or patient positioning^{18,22}. Preoperative axillary radiographs and mid-glenoid axial CT scans

TABLE I Wear Identification Consistency Proportions*

	Observer 1	Observer 2	Observer 3	Observer 4	Observer 5	P Value	Mean
Consistency between XR attempts	79%	58%	83%	75%	78%	<0.001	75%
Consistency between CT attempts	76%	56%	78%	72%	84%	<0.001	73%
Consistency between modalities, attempt 1	63%	63%	63%	59%	63%	0.770	62%
Consistency between modalities, attempt 2	65%	75%	58%	62%	61%	<0.001	64%

*Observer 1 = a second-year medical student, Observer 2 = a postdoctoral orthopaedic research fellow, Observer 3 = a PGY-4 orthopaedic resident, Observer 4 = a fellowship-trained orthopaedic hand surgeon undergoing shoulder-elbow fellowship training, Observer 5 = a dual-fellowship-trained trauma and shoulder-elbow attending surgeon, XR = axillary radiograph, and CT = mid-glenoid axial CT. Bolding indicates significance.

TABLE II Concentric Wear Observations (Attempt 1)*

	Observer 1	Observer 2	Observer 3	Observer 4	Observer 5	P Value	Mean
Proportion of identification of concentric wear on XR	57%	38%	38%	59%	47%	<0.001	48%
No. of cases of concentric wear on XR	188	124	124	196	156	–	–
No. of cases of XR-CT agreement	119	66	66	118	118	–	–
Proportion of cases of XR-CT agreement	63%	53%	53%	60%	76%	<0.001	61%

*Observer 1 = a second-year medical student, Observer 2 = a postdoctoral orthopaedic research fellow, Observer 3 = a PGY-4 orthopaedic resident, Observer 4 = a fellowship-trained orthopaedic hand surgeon undergoing shoulder-elbow fellowship training, Observer 5 = a dual-fellowship-trained trauma and shoulder-elbow attending surgeon, XR = axillary radiograph, and CT = mid-glenoid axial CT. Bolding indicates significance.

for the remaining 330 consecutive patients were included for comparative imaging analysis.

Survey Creation

With use of SurveyMonkey (www.surveymonkey.com), the system administrator (K.D.A.) created a survey that included anonymized versions of each of the 330 axillary radiographs and 330 CT scans^{23,24}. Images were randomized such that the radiographs and CT scan for any given patient were nonconsecutive. The preoperative morphology for each image was assessed in a closed-question format (Fig. 1), with observers required to identify concentric or eccentric glenoid wear patterns according to the Levine classification¹⁴ for axillary radiographs and the Hussey CT adaptation for mid-glenoid axial 2-dimensional CT images¹⁸.

Survey Protocol

Five independent observers completed the survey: a second-year medical student, a postdoctoral orthopaedic research fellow, a postgraduate year-4 (PGY-4) orthopaedic resident, a fellowship-trained orthopaedic hand surgeon undergoing shoulder-elbow fellowship training, and an attending surgeon with dual trauma and shoulder-elbow fellowship training. Completed survey results were blinded with respect to the observer and confidentially recorded to the SurveyMonkey platform, including the specific date and time of survey completion. Following a “visual wash-out period” of at least 3 weeks, each observer completed the identical survey for a second time to determine both intraobserver and interobserver consistency.

Statistical Analysis

Proportional consistency was calculated for the identification of the wear pattern on axillary radiographs and CT scans alone, as well as for radiographs compared with CT scans. In order to understand if there was a significant difference in the proportion of interobserver consistency, independent-sample Kruskal-Wallis tests with post-hoc Dunn-Bonferroni corrections were performed. Significance was set at 0.05, and statistical analyses were performed with use of SPSS (version 25.0; IBM).

Results

Axillary Radiographs

When using axillary radiographs (Table I), the observer identified the same pattern of wear between the first and second attempts in an average of 75% of cases (range, 58% to 83%; $p < 0.001$), and the PGY-4 orthopaedic resident was most consistent between attempts (83%).

Mid-Glenoid Axial CT Scans

When using CT scans (Table I), the observer identified the same pattern of wear between the first and second attempts in an average of 73% of cases (range, 56% to 84%; $p < 0.001$), and the attending was most consistent across attempts when using CT (84%).

Concentric Wear

On average, a concentric wear pattern was identified on 48% of axillary radiographs (range, 38% to 59%; $p < 0.001$) (Table II). Concentric glenoid wear identified on radiographs was also

TABLE III Impact of Observer Experience on Recognition of Glenoid Wear*

	Consistency Between XR Attempts	Consistency Between CT Attempts	Consistency Between Modalities, Attempt 1	Consistency Between Modalities, Attempt 2	Proportion of Cases of XR-CT Agreement
Observer with highest value	3	5	NS	2	5
Observer training level	PGY-4 orthopaedic resident	Dual-fellowship-trained trauma and shoulder-elbow attending surgeon		Postdoctoral orthopaedic research fellow	Dual-fellowship-trained trauma and shoulder-elbow attending surgeon

*XR = axillary radiograph, CT = mid-glenoid axial CT, and NS = not significant.

identified on CT scans an average of 61% of the time (range, 53% to 76%; $p < 0.001$) (Table II). The postdoctoral research fellow and the PGY-4 achieved agreement between radiographs and CT least frequently (53% for both), and the attending surgeon achieved agreement most frequently (76%).

Impact of Experience

The attending surgeon identified the highest proportion of concentric glenoid wear on axillary radiographs ($p < 0.001$), demonstrated the greatest consistency between attempts when utilizing CT ($p < 0.001$), and had the greatest agreement between radiographs and CT scans when identifying concentric glenoid wear ($p < 0.001$) (Tables II and III).

Discussion

The results of the present study support the growing emphasis on obtaining preoperative CT scans when assessing glenoid wear in osteoarthritic patients prior to shoulder arthroplasty, even in the setting of what appears to be concentric wear on radiographs. Although the most experienced surgeon in this study found concentric glenoid wear on radiographs consistent with CT scans in 76% of cases, the average consistency observed across observers was only 61%.

Recent studies have encouraged the use of 2-dimensional CT scans over standard radiographs when assessing preoperative glenoid wear^{10,18}, with 3-dimensional reconstruction potentially providing further utility¹⁸⁻²¹. Consequently, classification and treatment according to wear pattern have largely been based on advanced CT imaging^{10,11,15,17,21,25}. Nonetheless, studies have suggested several benefits to the use of radiographs both preoperatively and postoperatively, including in the determination of glenoid version and wear pattern, assessment of postoperative glenohumeral centering and congruence, and prediction of clinical outcomes^{14,26,27}. Furthermore, several foundational but contemporary concepts in shoulder arthroplasty have been anchored by studies that utilized radiographs alone while noting the adequacy in utility^{22,26,28-30}. Although CT scans are associated with greater financial cost^{26,31,32} and exposure to radiation^{26,33-35} than radiographs, the literature has yet to describe the additional clinical value and/or potential cost-value benefit as a result of improved outcomes provided by the use of CT scans in patients undergoing total shoulder arthroplasty, even when integrated with virtual planning software and generation of patient-specific instrumentation.

Previous studies have investigated the consistency of glenoid wear classification systems using various imaging modalities. In a study of the Walch classification involving 3 surgeons, Aronowitz et al. found “substantial” intraobserver consistency ($\kappa = 0.66$) with radiographs and “moderate” intraobserver consistency ($\kappa = 0.60$) with CT scans¹⁷. In contrast, Shukla et al. evaluated the Bercik modification of the Walch classification and found interobserver consistency equivalent between radiographs and CT scans ($\kappa = 0.55$ and $\kappa = 0.52$, respectively)¹⁵. In both studies, the most senior assessor was considered the control, and no comparative analysis of

observer experience was performed. Kopka et al. compared the use of radiographs and magnetic resonance imaging with the Walch classification and found radiographs to be less reliable, with fair-to-moderate agreement ($\kappa = 0.21$ to 0.51) between the two³⁶. Finally, Hussey et al. reported higher interobserver and intraobserver consistency when using the modified Levine classification ($\kappa = 0.54$ and $\kappa = 0.70$, respectively) compared with the Walch classification ($\kappa = 0.60$ and $\kappa = 0.70$, respectively) for the assessment of glenoid wear patterns on CT scans¹⁸. In the present study, assessors were able to identify concentric wear patterns in an average of 61% of cases when using radiographs, with improved consistency among the most experienced observers.

Despite a preponderance of literature on the classification of glenoid morphology, there remains a lack of evidence evaluating the impact of surgical experience on the use of preoperative imaging in the evaluation of osteoarthritic patients. Surgical experience has been shown to correlate with more favorable clinical outcomes and overall surgical costs in shoulder arthroplasty³⁷⁻⁴⁴; however, robust studies are lacking that evaluate variation in radiographic reviewing (and subsequent surgical planning) as a result of differing levels of clinical experience. The present study provides insight into this conundrum, with significant differences observed among different levels of training when classifying glenoid wear patterns with use of both radiographs and CT scans.

Obtaining routine CT scans for all shoulder arthroplasty patients has not been universally advocated, largely because planning is unlikely to change for the concentrically worn glenoid, as implant selection and surgical techniques are unlikely to be modified following additional advanced imaging. Although CT scanning does provide additional, possibly beneficial data (including determination of glenoid size, version, and inclination; identification of subchondral cysts, subchondral thickness, and bone density; and better estimation of glenoid component fit and positioning), much can still be appreciated on radiographs. Furthermore, if a surgeon believes that preparation of the glenoid in order to provide complete backside support of the component deserves the highest priority during glenoid component implantation, irrespective of glenoid version⁴⁵, then the primary focus of preoperative imaging would be to differentiate concentric from eccentric glenoid wear. Using this rationale, the ability to achieve complete backside support in a glenoid with concentric wear is typically straightforward and would not necessitate advanced imaging. Thus, if radiographs and CT scans consistently identified concentric wear, then the need for CT could be avoided. This study demonstrates that for an experienced attending surgeon, concentric wear identified on radiographs was also identified on CT scans in 76% of cases, with significant differences among varied levels of experience (range, 53% to 76%). Although an experienced surgeon may be comfortable with an accuracy rate of 76% when they identify glenoids as having a concentric wear pattern, not identifying eccentric wear patterns in the other 24% is of concern. Thus, a preoperative CT scan would help improve the ability to recognize glenoid wear patterns prior to a surgical procedure.

As with all studies, the present study has limitations. Clinical outcomes were not included in the analysis; thus, the impact of the glenoid wear classification was not evaluated. Additionally, intraoperative observations, which could have been used as a gold standard for determining concentric and eccentric wear patterns, were not recorded. Furthermore, although both axillary radiographs and CT images were standardized and screened, there are typically small variations in image quality seen even within a single imaging center. Additionally, it is possible that uniformity of assessment of overall glenoid morphology could have been improved with the use of scroll-through, 2-dimensional CT, which was not available for this study.

Nonetheless, the intraobserver consistency showed a higher rate of consistent identification of the same wear pattern in radiographs (average, 75%) compared with CT scans (average, 73%), although both exhibited a high degree of consistency.

In conclusion, for an experienced shoulder surgeon, recognition of concentric glenoid wear on radiographs should correlate with mid-glenoid CT scans in approximately 75% of cases. Radiographs appear to be insufficient at consistently differentiating concentric from eccentric wear patterns among those with less experience. ■

Note: The authors thank Leah Elson for providing statistical analysis and Teja Polisetty for manuscript writing and preparation.

Kofi D. Agyeman, MD¹
Paul DeVito, DO²
Emmanuel McNeely, MS, MPA³
Andy Malarkey, DO²
Michael J. Bercik, MD⁴
Jonathan C. Levy, MD²

¹Miller School of Medicine, University of Miami, Miami, Florida

²Holy Cross Orthopedic Institute, Fort Lauderdale, Florida

³Charles E. Schmidt College of Medicine, Florida Atlantic University, Boca Raton, Florida

⁴Lancaster Orthopedic Group, Lancaster, Pennsylvania

ORCID iD for K.D. Agyeman: [0000-0003-1943-8822](https://orcid.org/0000-0003-1943-8822)

ORCID iD for P. DeVito: [0000-0002-6252-8949](https://orcid.org/0000-0002-6252-8949)

ORCID iD for E. McNeely: [0000-0002-8019-767X](https://orcid.org/0000-0002-8019-767X)

ORCID iD for A. Malarkey: [0000-0003-3411-5642](https://orcid.org/0000-0003-3411-5642)

ORCID iD for M.J. Bercik: [0000-0003-4411-6497](https://orcid.org/0000-0003-4411-6497)

ORCID iD for J.C. Levy: [0000-0002-1699-0841](https://orcid.org/0000-0002-1699-0841)

References

- Matsen FA 3rd, Boileau P, Walch G, Gerber C, Bicknell RT. The reverse total shoulder arthroplasty. *J Bone Joint Surg Am.* 2007 Mar;89(3):660-7.
- Ho JC, Sabesan VJ, Iannotti JP. Glenoid component retroversion is associated with osteolysis. *J Bone Joint Surg Am.* 2013 Jun 19;95(12):e82.
- Konrad GG, Markmiller M, Jolly JT, Ruter AE, Sudkamp NP, McMahon PJ, Debski RE. Decreasing glenoid inclination improves function in shoulders with simulated massive rotator cuff tears. *Clin Biomech (Bristol, Avon).* 2006 Nov;21(9):942-9. Epub 2006 Jun 15.
- Oosterom R, Rozing PM, Bersee HEN. Effect of glenoid component inclination on its fixation and humeral head subluxation in total shoulder arthroplasty. *Clin Biomech (Bristol, Avon).* 2004 Dec;19(10):1000-8.
- Strauss EJ, Roche C, Flurin PH, Wright T, Zuckerman JD. The glenoid in shoulder arthroplasty. *J Shoulder Elbow Surg.* 2009 Sep-Oct;18(5):819-33. Epub 2009 Jul 1.
- Walch G, Mesaha M, Boileau P, Edwards TB, Lévine C, Moineau G, Young A. Three-dimensional assessment of the dimensions of the osteoarthritic glenoid. *Bone Joint J.* 2013 Oct;95-B(10):1377-82.
- Farron A, Terrier A, Büchler P. Risks of loosening of a prosthetic glenoid implanted in retroversion. *J Shoulder Elbow Surg.* 2006 Jul-Aug;15(4):521-6.
- Shapiro TA, McGarry MH, Gupta R, Lee YS, Lee TQ. Biomechanical effects of glenoid retroversion in total shoulder arthroplasty. *J Shoulder Elbow Surg.* 2007 May-Jun;16(3)(Suppl):S90-5. Epub 2006 Dec 12.
- Büchler P, Ramaniraka NA, Rakotomanana LR, Iannotti JP, Farron A. A finite element model of the shoulder: application to the comparison of normal and osteoarthritic joints. *Clin Biomech (Bristol, Avon).* 2002 Nov-Dec;17(9-10):630-9.
- Walch G, Badet R, Boulahia A, Khoury A. Morphologic study of the glenoid in primary glenohumeral osteoarthritis. *J Arthroplasty.* 1999 Sep;14(6):756-60.
- Scalise JJ, Codsí MJ, Brems JJ, Iannotti JP. Inter-rater reliability of an arthritic glenoid morphology classification system. *J Shoulder Elbow Surg.* 2008 Jul-Aug;17(4):575-7. Epub 2008 Apr 28.
- Daggett M, Werner B, Gauci MO, Chaoui J, Walch G. Comparison of glenoid inclination angle using different clinical imaging modalities. *J Shoulder Elbow Surg.* 2016 Feb;25(2):180-5. Epub 2015 Sep 6.
- Werner BS, Hudek R, Burkhart KJ, Gohlke F. The influence of three-dimensional planning on decision-making in total shoulder arthroplasty. *J Shoulder Elbow Surg.* 2017 Aug;26(8):1477-83. Epub 2017 Feb 2.
- Levine WN, Djurasovic M, Glasson JM, Pollock RG, Flatow EL, LU Bigliani. Hemiarthroplasty for glenohumeral osteoarthritis: results correlated to degree of glenoid wear. *J Shoulder Elbow Surg.* 1997 Sep-Oct;6(5):449-54.
- Shukla DR, McLaughlin RJ, Lee J, Cofield RH, Sperling JW, Sánchez-Sotelo J. Intraobserver and interobserver reliability of the modified Walch classification using radiographs and computed tomography. *J Shoulder Elbow Surg.* 2019 Apr;28(4):625-30. Epub 2018 Dec 6.
- Neyton L, Gauci MO, Deransart P, Collette P, Walch G, Athwal GS. Three-dimensional characterization of the anteverted glenoid (type D) in primary glenohumeral osteoarthritis. *J Shoulder Elbow Surg.* 2019 Jun;28(6):1175-82. Epub 2019 Jan 23.
- Aronowitz JG, Harmsen WS, Schleck CD, Sperling JW, Cofield RH, Sánchez-Sotelo J. Radiographs and computed tomography scans show similar observer agreement when classifying glenoid morphology in glenohumeral arthritis. *J Shoulder Elbow Surg.* 2017 Sep;26(9):1533-8. Epub 2017 Apr 7.
- Hussey MM, Steen BM, Cusick MC, Cox JL, Marberry ST, Simon P, Cottrell BJ, Santoni BG, Frankle MA. The effects of glenoid wear patterns on patients with osteoarthritis in total shoulder arthroplasty: an assessment of outcomes and value. *J Shoulder Elbow Surg.* 2015 May;24(5):682-90. Epub 2014 Dec 3.
- Nowak DD, Bahu MJ, Gardner TR, Dyrzka MD, Levine WN, LU Bigliani, Ahmad CS. Simulation of surgical glenoid resurfacing using three-dimensional computed tomography of the arthritic glenohumeral joint: the amount of glenoid retroversion that can be corrected. *J Shoulder Elbow Surg.* 2009 Sep-Oct;18(5):680-8. Epub 2009 May 31.
- Chan K, Knowles NK, Chaoui J, Gauci MO, Ferreira LM, Walch G, Athwal GS. Characterization of the Walch B3 glenoid in primary osteoarthritis. *J Shoulder Elbow Surg.* 2017 May;26(5):909-14. Epub 2017 Jan 11.
- Bercik MJ, Kruse K 2nd, Yalizis M, Gauci MO, Chaoui J, Walch G. A modification to the Walch classification of the glenoid in primary glenohumeral osteoarthritis using three-dimensional imaging. *J Shoulder Elbow Surg.* 2016 Oct;25(10):1601-6. Epub 2016 Jun 6.
- Matsen FA 3rd, Clinton J, Lynch J, Bertelsen A, Richardson ML. Glenoid component failure in total shoulder arthroplasty. *J Bone Joint Surg Am.* 2008 Apr;90(4):885-96.
- Hoonakker P, Carayon P. Questionnaire survey nonresponse: a comparison of postal mail and internet surveys. *Int J Hum Comput Interact.* 2009 Jul;25(5):348-73.
- Sheehan KB. E-mail survey response rates: a review. *J Comput-Mediat Comm.* 2006;6(2).
- Nowak DD, Gardner TR, LU Bigliani, Levine WN, Ahmad CS. Interobserver and intraobserver reliability of the Walch classification in primary glenohumeral arthritis. *J Shoulder Elbow Surg.* 2010 Mar;19(2):180-3. Epub 2009 Dec 5.
- Matsen FA 3rd, Gupta A. Axillary view: arthritic glenohumeral anatomy and changes after ream and run. *Clin Orthop Relat Res.* 2014 Mar;472(3):894-902. Epub 2013 Oct 18.

27. Matsen FA 3rd, Russ SM, Vu PT, Hsu JE, Lucas RM, Comstock BA. What factors are predictive of patient-reported outcomes? A prospective study of 337 shoulder arthroplasties. *Clin Orthop Relat Res.* 2016 Nov;474(11):2496-510. Epub 2016 Jul 25.
28. Nyffeler RW, Sheikh R, Atkinson TS, Jacob HAC, Favre P, Gerber C. Effects of glenoid component version on humeral head displacement and joint reaction forces: an experimental study. *J Shoulder Elbow Surg.* 2006 Sep-Oct;15(5):625-9.
29. Namdari S, Hsu JE, Baron M, Huffman GR, Glaser D. Immediate postoperative radiographs after shoulder arthroplasty are often poor quality and do not alter care. *Clin Orthop Relat Res.* 2013 Apr;471(4):1257-62. Epub 2012 Aug 29.
30. Lazarus MD, Jensen KL, Southworth C, Matsen FA 3rd. The radiographic evaluation of keeled and pegged glenoid component insertion. *J Bone Joint Surg Am.* 2002 Jul;84(7):1174-82.
31. Pallarito K. Six key medical scans and what they should cost. Accessed 2019 Mar 14. <https://www.health.com/health/gallery/0,20867990,00.html>
32. New Choice Health. CT shoulder, arm, wrist, hand (upper extremity) cost and procedure information. Accessed 2019 Mar 14. <https://www.newchoicehealth.com/procedures/ct-shoulder-arm-wrist-hand-ct-upper-extremity>
33. Pantos I, Thalassinou S, Argentos S, Kelekis NL, Panayiotakis G, Efsthopoulos EP. Adult patient radiation doses from non-cardiac CT examinations: a review of published results. *Br J Radiol.* 2011 Apr;84(1000):293-303. Epub 2011 Jan 25.
34. Biswas D, Bible JE, Bohan M, Simpson AK, Whang PG, Grauer JN. Radiation exposure from musculoskeletal computerized tomographic scans. *J Bone Joint Surg Am.* 2009 Aug;91(8):1882-9.
35. Orthoinfo. X-rays, CT scans and MRIs. Accessed 2019 Mar 14. <https://orthoinfo.aaos.org/en/treatment/x-rays-ct-scans-and-mris/>
36. Kopka M, Fourman M, Soni A, Cordle AC, Lin A. Can glenoid wear be accurately assessed using x-ray imaging? Evaluating agreement of x-ray and magnetic resonance imaging (MRI) Walch classification. *J Shoulder Elbow Surg.* 2017 Sep;26(9):1527-32. Epub 2017 May 5.
37. Hammond JW, Queale WS, Kim TK, McFarland EG. Surgeon experience and clinical and economic outcomes for shoulder arthroplasty. *J Bone Joint Surg Am.* 2003 Dec;85(12):2318-24.
38. Jain N, Pietrobon R, Hocker S, Guller U, Shankar A, Higgins LD. The relationship between surgeon and hospital volume and outcomes for shoulder arthroplasty. *J Bone Joint Surg Am.* 2004 Mar;86(3):496-505.
39. Weinheimer KT, Smuin DM, Dhawan A. Patient outcomes as a function of shoulder surgeon volume: a systematic review. *Arthroscopy.* 2017 Jul;33(7):1273-81. Epub 2017 Apr 26.
40. Ramkumar PN, Navarro SM, Haeberle HS, Ricchetti ET, Iannotti JP. Evidence-based thresholds for the volume-value relationship in shoulder arthroplasty: outcomes and economies of scale. *J Shoulder Elbow Surg.* 2017 Aug;26(8):1399-406.
41. Ramkumar PN, Haeberle HS, Iannotti JP, Ricchetti ET. The volume-value relationship in shoulder arthroplasty. *Orthop Clin North Am.* 2018 Oct;49(4):519-25. Epub 2018 Aug 16.
42. Singh A, Yian EH, Dillon MT, Takayanagi M, Burke MF, Navarro RA. The effect of surgeon and hospital volume on shoulder arthroplasty perioperative quality metrics. *J Shoulder Elbow Surg.* 2014 Aug;23(8):1187-94. Epub 2014 Feb 4.
43. Singh JA, Ramachandran R. Does hospital volume predict outcomes and complications after total shoulder arthroplasty in the US? *Arthritis Care Res (Hoboken).* 2015 May;67(6):885-90.
44. Lyman S, Jones EC, Bach PB, Peterson MGE, Marx RG. The association between hospital volume and total shoulder arthroplasty outcomes. *Clin Orthop Relat Res.* 2005 Mar;432:132-7.
45. Service BC, Hsu JE, Somerson JS, Russ SM, Matsen FA 3rd. Does postoperative glenoid retroversion affect the 2-year clinical and radiographic outcomes for total shoulder arthroplasty? *Clin Orthop Relat Res.* 2017 Nov;475(11):2726-39. Epub 2017 Jul 5.