

Displaced Intra-Articular Fractures of the Distal Radius: Open Reduction With Internal Fixation Versus Bridging External Fixation

Mohammad Fakoor^{1,*}; Morteza Fakoor¹; Payam Mohammadhoseini¹

¹Imam Khomeini Hospital, Ahvaz Jundishapur University of Medical Sciences, Ahvaz, IR Iran

*Corresponding author: Mohammad Fakoor, Imam Khomeini Hospital, Ahvaz Jundishapur University of Medical Sciences, Ahvaz, IR Iran. Tel: +98-9161186420, Fax: +98-6132921836, E-mail: dr_m_fakoor@yahoo.com

Received: January 16, 2014; Revised: September 28, 2014; Accepted: October 7, 2014

Background: Distal radius fracture is common in all ages. Mobility and wrist function is important. The choice of treatment should aim for optimal function with minimal complications.

Objectives: In this study we compared two surgical approaches, open reduction and internal fixation (ORIF) and closed reduction with external fixation (CR + EF), for treatment of intra-articular distal radius fractures.

Patients and Methods: Ninety-four patients with distal radius fracture (type 3, 4 and 5 Fernandez classification) were treated with two surgical methods (ORIF and CR + EF); 55 were treated with CR + EF and 39 were treated with ORIF by different surgeons. All patients were assessed at the end of the first, third and sixth week; and then after the third, sixth and 12th month. At the end of the follow-up, all patients completed the Michigan hand outcome questionnaire (MHOQ). We compared radiological parameters of distal radius, range of motion (ROM) of the wrist, duration of rehabilitation, complication and patient satisfaction of the methods.

Results: In our study, radiological findings for the ORIF group were radial inclination (RI): 19.35, radial length (RL): 10.35, radial tilt (RT): 8.92, and ulnar variance (UV): 1.64, while for the CR + EF group these were RI: 15.13, RL: 8, RT: 4.78, and UV: 0.27. The ROM for ORIF were flexion/extension (F/E): 137, Radial/Ulnar deviation (R/U): 52, and Supination/Pronation (S/P): 141, while for the CR + EF group these were F/E: 117, R/U: 40 and S/P: 116. Michigan hand outcome score for ORIF was 75% and for Ext. fix was 60%. The rate of complication with the ORIF method was 58% and in Ext. fix this was 69%. The patients in CR + EF had more than the ORIF course of physiotherapy and rehabilitation.

Conclusions: In comparison of ORIF and CR + EF, all results including functional score, clinical and radiologic criteria were in favor of the ORIF method while there were less complications with this method. We believe that ORIF is a better method for treatment of these types of fractures.

Keywords: Open Reduction; Internal Fixation; Closed Reduction; External Fixation; Outcome; Distal Radius Fractures

1. Background

Distal radius fractures can disable wrist function. The incidence of wrist fracture is not only expected to increase with aging, it is also caused by accidents. The most popular classification for distal radius fracture is the Fernandez classification that includes five groups, namely: 1) bending-metaphysis (Colles, Smith), 2) shearing-fractures of joint surfaces (Barton, radial styloid), 3) compression-intra-articular fracture with impaction of subchondral and metaphyseal bone (die-punch), 4) avulsion-fractures of ligament attachments (ulna, radial styloid), and 5) combined complex-high velocity injuries (Figure 1).

Popular surgical options for unstable distal radius fractures include closed reduction and pin fixation with or without external fixation (1, 2), and open reduction and internal fixation (ORIF) (3, 4).

2. Objectives

The aim of this study was to compare two methods of

surgical treatment (ORIF vs. CR + EF) regarding radiological findings, rehabilitation, range of motion, complication, patient satisfaction and wrist scoring.

3. Patients and Methods

From June 2010 to January 2012, 336 cases with distal radius fractures were admitted to Imam Khomeini and Razi Hospital. Ninety-four patients fulfilled our inclusion criterion, which was having one of the following fractures: 1) displaced fracture, 2) metaphyseal instability, 3) bilateral fracture, 4) associated carpal fractures, and 5) intra-articular fracture. In a randomized manner, 39 cases underwent ORIF with T-plate (3.5 mm) (Figure 2) and 55 cases underwent CR + EF (Figure 3). All patients had follow-up sessions during the 1st, 3rd, 6th week, and 3rd, 6th, and 12 months, during which their functional score was evaluated by the Michigan hand outcome questionnaire (MHOQ). This Questionnaire included four parts: general, work, pain, and appearance. Exclusion criteria were having an open

fracture, neurovascular injury, type I and II Fernandez fracture, multiple fractures and systematic disorders that can affect the healing process, such as diabetes, renal failure, rheumatologic disease, mental retardation and Parkinson's disease. In the operation room, Group I (ORIF) patients after receiving anesthesia and tourniquet with the volar Henry approach underwent reduction of the distal radius fracture fixed with a T-plate. For the closed reduction method, in the operation room, Group II (CR + EF) after receiving anesthesia, underwent closed reduction under a fluoroscope (C-ARM) and primary fixation with a k-wire. Using two Schanz pins (N 2.5) on dorsoradial, metaphyseal/diaphyseal junction on the distal and proximal of second metacarpal, and proximal fragment was fixed (N 2.5) the first one 1 - 1.5 cm from fracture site and the second 10 cm further proximal from the first pin. All pins were fixed with two bars in 30-degree flexion and slight ulnar deviation of the wrist. SPSS software version 19.0 (Inc, Chicago, IL, USA) was used for analysis. P values of < 0.05 were considered significant.

4. Results

In Group I the age range was between 17 and 76 years while in Group II the age range was between 19 and 84 years; 75.5% were male. Mechanisms of injury were falls (51.1%), motorcycle/car accident (13.8%) and car accident (11.7%). Return to work was significantly shorter in cases treated by ORIF (66.43 days) compared to CR + EF (88.67 days) (P value = 0.000). There was a significant difference between the two groups regarding RI, RL, RT and UV (Table 1). Range of motion was significantly higher in cases that underwent ORIF (Table 2). Scores (general, work, appearance, final, and MHOC) were significantly higher in cases that underwent ORIF. In subjects who underwent ORIF, pain score was significantly lower (Table 3). Pain and limitation of motion was more common in ORIF cases (Table 4).

5. Discussion

In our study, UV, RL, RT and RI were significantly more fa-

vorable in the ORIF compared to the CR + EF method. Other studies showed better radiographic findings in cases that were treated with ORIF compared to the external fixation method (5, 6). In some studies, external fixation was not considered as an appropriate method for reducing collapse and radial tilt during the healing process (3, 7, 8).

In our study, patient satisfaction after ORIF was significantly more favorable than CR + EF. Similar findings were reported in the literature (5, 6). However, there has been controversies for option of treatment between general orthopedic surgeons and hand surgeons regarding displaced radius fractures (9). In a study by Rozental et al. (10) both ORIF and closed reduction with percutaneous fixation were effective methods for treatment of unstable distal radius fracture.

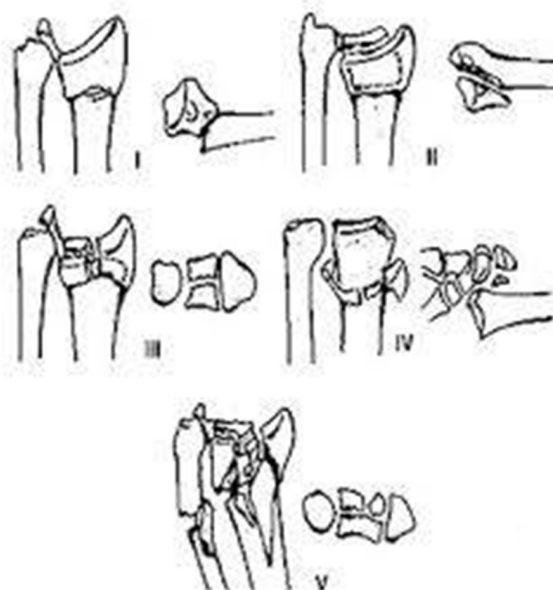


Figure 1. Fernandez Classification for Distal Radius Fracture

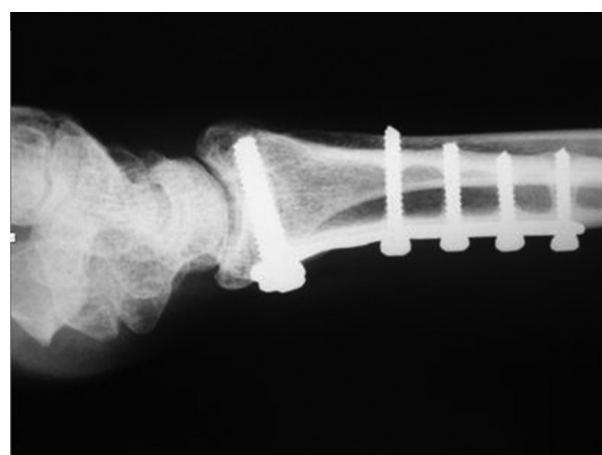
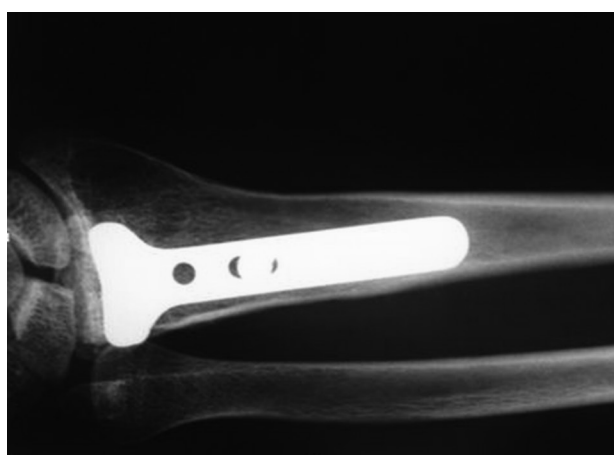

Figure 2. A Thirty-Two-Year-Old Patient With Distal Radius Fracture Treated With Open Reduction and Internal Fixation

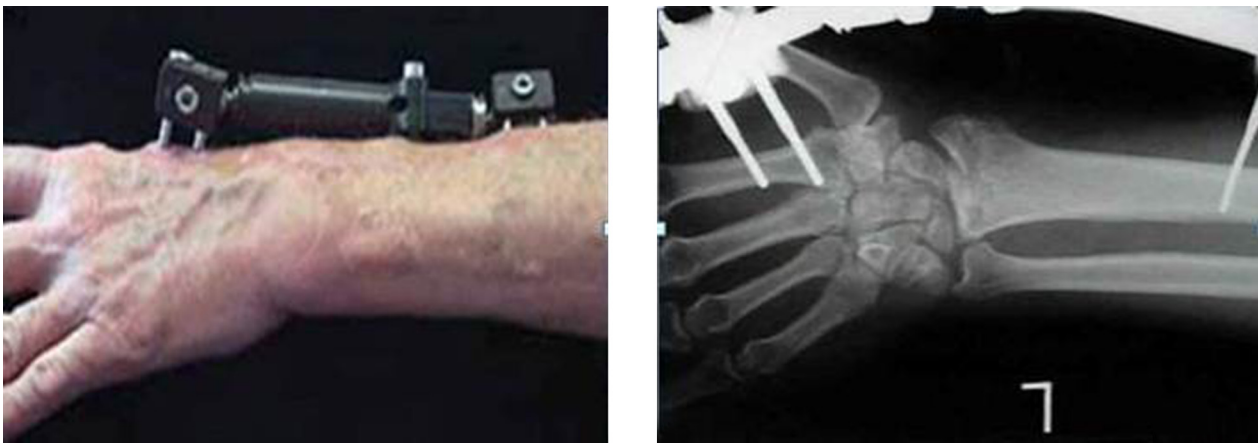


Figure 3. A Thirty-Eight-Year-Old Patient With Distal Radius Fracture Treated With Close Reduction With External Fixation

Table 1. Radiological Findings Among the Two Groups at the End of the Follow-up Period ^{a,b}

| Radiologic Criteria | ORIF (n = 14) | CR + EF (n = 37) | P Value |
|---------------------|---------------|------------------|---------|
| RI | 19.35 ± 2.61 | 15.13 ± 4.19 | 0.001 |
| RL | 10.35 ± 0.92 | 8.05 ± 1.92 | 0.000 |
| RT | 8.92 ± 2.33 | 4.78 ± 4.11 | 0.001 |
| UV | 1.64 ± 1.21 | 0.27 ± 1.78 | 0.004 |

^a Abbreviations: CR + EF, closed reduction with external fixation; ORIF, open reduction and internal fixation; RI, radial inclination; RL, radial length; RT, radial tilt; and UV, ulnar variance.

^b Values are presented as mean ± SD.

Table 2. Range of Motion Amongst the Two Groups ^{a,b}

| | ORIF | Ext. Fix | P Value |
|----|----------------|----------------|---------|
| FE | 137.14 ± 13.82 | 117.83 ± 24.48 | 0.00 |
| RU | 52.50 ± 7.00 | 40.67 ± 9.80 | 0.00 |
| SP | 141.42 ± 19.45 | 116.35 ± 29.24 | 0.00 |

^a Abbreviations: FE, range of flexion and extension; ORIF, open reduction and internal fixation; RU, range of ulnar and radial deviation; and SP, range of supination and pronation.

^b Values are presented as mean ± SD.

Table 3. Comparison of Scores Amongst the Two Groups of Patients ^{a,b}

| Score | ORIF (n = 39) | Ext. Fix (n = 55) | P Value |
|------------|---------------|-------------------|---------|
| General | 92.39 ± 5.58 | 80.19 ± 10.61 | 0.000 |
| Work | 66.79 ± 15.99 | 52.72 ± 15.86 | 0.000 |
| Pain | 33.84 ± 11.14 | 51.72 ± 14.56 | 0.000 |
| Appearance | 70.58 ± 7.68 | 61.99 ± 11.65 | 0.000 |
| Final | 80.70 ± 14.58 | 58.01 ± 19.71 | 0.000 |
| MHOQ | 75.34 ± 8.78 | 60.49 ± 12.86 | 0.000 |

^a Abbreviations: MHOQ: Michigan hand outcome questionnaire; and ORIF, open reduction and internal fixation.

^b Values are presented as mean ± SD.

Table 4. Complications of Surgery Among the Two Groups ^{a,b}

| Type of Treatment | Pain and Limitation of Motion | None |
|-------------------|-------------------------------|---------|
| ORIF | 23 (58) | 16 (42) |
| CR + EF | 38 (69) | 17 (31) |

^a Abbreviations: CR + EF, closed reduction with external fixation; and ORIF, open reduction and internal fixation.

^b Values are presented as No (%).

In the study done by Chung et al. (11) on cases with distal radius fractures, which were treated with external fixation methods, several complications were reported. These complications included median nerve neuropathy, radial nerve neuropathy, infection, nonunion, malunion, decreased radial tilt, carpal mal-alignment etc. These complications make the external fixation method a less favorable option (11). In the study by Wei et al. (12), functional score, forearm supination, and restoration of anatomic volar tilt after ORIF were more favorable than other methods.

Radiological criteria were more favorable in ORIF compared to external fixation. In the study by Rogachefsky et al. (13) on 17 cases with severely comminuted fracture of distal radius, ORIF restored radiographic parameters to near normal. In the study by Konstantinidis et al. (14), after treatment of distal radius fracture with ORIF, radial inclination was 23.1 at follow-up examination. In our study, radial inclination was 19.35 ± 2.61 . In other studies, patients who were treated with ORIF had more favorable outcomes (5, 6).

Generally, scores among patients who were treated by ORIF were significantly higher than cases treated by external fixation. In the study by Beharrie et al. (15), they reported ORIF to be a safe and effective method for treatment of displaced and comminuted fractures of distal radius in patients aged > 60 years.

Rehabilitation was more favorable among cases that underwent ORIF compared to external fixation. This was similar to the study of Rizzo et al. (5). Return to work was about 66.43 and 88.67 days for ORIF and external fixation methods, respectively.

In conclusion, as shown by some studies (16), ORIF may be the preferable method for the treatment of patients with unstable intra-articular fracture of distal radius. However, there was a difference between studies regarding use of different criteria for the assessment of treatment outcomes.

5.1. Limitation

Patient compliance was one of the limitations of our study. Our follow-up was 12 months in duration, yet there are previous studies with longer than three years of follow-up.

Acknowledgements

We thank the Ahvaz Jundishapur University of Medical Sciences for their financial support of this research project. Our special thanks goes to the Golestan Hospital Clinical Development Research Unit and Molook Salehzadeh (BSN/RN) for submission consultation.

Authors' Contributions

Mohammad Fakoor: supervision and manuscript writing. Morteza Fakoor: data collection and literature search.

Funding/Support

Financial support for this study was provided by the Ahvaz Jundishapur University of Medical Sciences, Ahvaz, IR Iran and there were no Sponsors.

References

- Christensen OM, Christiansen TC, Krashennikoff M, Lind B, Holmich LR, Hansen FF, et al. Plaster cast compared with bridging external fixation for distal radius fractures of the Colles' type. *Int Orthop*. 2001;**24**(6):358-60.
- Cooney W3, Linscheid RL, Dobyns JH. External pin fixation for unstable Colles' fractures. *J Bone Joint Surg Am*. 1979;**61**(6A):840-5.
- Catalano L3, Cole RJ, Gelberman RH, Evanoff BA, Gilula LA, Borrelli JJ. Displaced intra-articular fractures of the distal aspect of the radius. Long-term results in young adults after open reduction and internal fixation. *J Bone Joint Surg Am*. 1997;**79**(9):1290-302.
- Kapoor H, Agarwal A, Dhaon BK. Displaced intra-articular fractures of distal radius: a comparative evaluation of results following closed reduction, external fixation and open reduction with internal fixation. *Injury*. 2000;**31**(2):75-9.
- Rizzo M, Katt BA, Carothers JT. Comparison of locked volar plating versus pinning and external fixation in the treatment of unstable intraarticular distal radius fractures. *Hand (NY)*. 2008;**3**(2):111-7.
- Schmelzer-Schmied N, Wieloch P, Martini AK, Daecke W. Comparison of external fixation, locking and non-locking palmar plating for unstable distal radius fractures in the elderly. *Int Orthop*. 2009;**33**(3):773-8.
- McQueen MM, Hajducka C, Court-Brown CM. Redispaced unstable fractures of the distal radius: a prospective randomised comparison of four methods of treatment. *J Bone Joint Surg Br*. 1996;**78**(3):404-9.
- Cooney WP. External fixation of distal radial fractures. *Clin Orthop Relat Res*. 1983;**180**:44-9.
- Nazar MA, Mansingh R, Bassi RS, Waseem M. Is there a Consensus in the Management of Distal Radial Fractures? *Open Orthop J*. 2009;**3**:96-9.
- Rozental TD, Blazar PE, Franko OI, Chacko AT, Earp BE, Day CS. Functional outcomes for unstable distal radial fractures treated with open reduction and internal fixation or closed reduction and percutaneous fixation. A prospective randomized trial. *J Bone Joint Surg Am*. 2009;**91**(8):1837-46.
- Chung KC, Shauver MJ, Birkmeyer JD. Trends in the United States in the treatment of distal radial fractures in the elderly. *J Bone Joint Surg Am*. 2009;**91**(8):1868-73.
- Wei DH, Poolman RW, Bhandari M, Wolfe VM, Rosenwasser MP. External fixation versus internal fixation for unstable distal radius fractures: a systematic review and meta-analysis of comparative clinical trials. *J Orthop Trauma*. 2012;**26**(7):386-94.
- Rogachefsky RA, Lipson SR, Applegate B, Ouellette EA, Savenor AM, McAuliffe JA. Treatment of severely comminuted intra-articular fractures of the distal end of the radius by open reduction and combined internal and external fixation. *J Bone Joint Surg Am*. 2001;**83-A**(4):509-19.
- Konstantinidis L, Helwig P, Strohm PC, Hirschmuller A, Kron P, Sudkamp NP. Clinical and radiological outcomes after stabilisation of complex intra-articular fractures of the distal radius with the volar 2.4 mm LCP. *Arch Orthop Trauma Surg*. 2010;**130**(6):751-7.
- Beharrie AW, Beredjiklian PK, Bozentka DJ. Functional outcomes after open reduction and internal fixation for treatment of displaced distal radius fractures in patients over 60 years of age. *J Orthop Trauma*. 2004;**18**(10):680-6.
- Missakian ML, Cooney WP, Amadio PC, Glidewell HL. Open reduction and internal fixation for distal radius fractures. *J Hand Surg Am*. 1992;**17**(4):745-55.