

## Melanocytoma of the optic nerve head - a diagnostic dilemma

Zalilawati Mohmad,<sup>1</sup> Tan Aik Kah,<sup>1,2</sup>  
Ku Chui Yong,<sup>1</sup> Wan Haslina Wan Abdul  
Halim,<sup>1</sup> Then Kong Yong<sup>1</sup>

<sup>1</sup>Department of Ophthalmology, Faculty of Medicine, University Kebangsaan Malaysia; <sup>2</sup>Department of Ophthalmology, Faculty of Medicine and Health Sciences, University Malaysia Sarawak (UNIMAS), Malaysia

### Abstract

The clinical features, autofluorescence, B-scan ultrasonography, optical coherence tomography and fluorescein angiography of the lesion were described. Multiple investigation modalities are needed to confirm the benign nature of the lesion. Careful evaluation and follow-up is crucial to avoid misdiagnosis and erroneous management.

### Introduction

Melanocytoma of the optic disk is a hamartoma with malignant potential. Sometimes, it may be difficult to distinguish from malignant melanoma. We describe the clinical features, autofluorescence, B-scan ultrasonography, optical coherence tomography and fluorescein angiography of a case of melanocytoma of the optic disk.

### Case Report

A 40-year-old Chinese gentleman, presented to our department with right subconjunctival hemorrhage after an episode of vomiting. There was no blurring of vision or any other visual symptoms. At examination, his vision was 1.0 bilaterally. Intraocular pressure was 10 mm Hg (OS) and 12 mm Hg (OD). There was a sectoral subconjunctival hemorrhage at the nasal aspect of his right eye. There were no other remarkable findings on his right eye. Incidentally, there was a light brown lesion at the optic nerve head. The lesion was elevated with feathery margins, involving the inferior and nasal aspect of the optic nerve head, extending from the 5:00 to 11:00. Pigmentation was heavier at the inferonasal optic disc margin. The lesion was about 1.5 disc-area in size with the involvement of adjacent choroid.

Retinal involvement was less prominent with slight obscuration of the overlying major retinal vessels (Figure 1A). There was neither glial proliferation nor dragging of the retinal vasculature. Lipofuscin deposition, retinal hemorrhages, retinal edema and subretinal fluid were absent. There were no other retinal lesions or ocular melanocytosis. The vitreous was clear. Pupillary light reflexes were brisk and equal bilaterally.

The lesion did not manifest any autofluorescence (Figure 1B). B-scan ultrasonography showed an elevated dome-shaped lesion with an initial tumor thickness of 1.4 mm (Figure 2A). The adjacent choroidal involvement had low internal reflectivity (Figure 2B). Optical coherence tomography (Heidelberg Spectralis® Tracking Laser Tomography; Heidelberg Engineering, Carlsbad, CA, USA) revealed a predominant choroidal involvement with marked displacement of the overlying retina nerve fiber layer (Figure 3). The optic nerve architecture was markedly distorted. Fluorescein angiography revealed fine retinal vasculature on the surface of the tumor; there was no choroidal vasculature supplying the lesion. In the late phase, the hyperfluorescence at the nasal optic disc margin increased size and intensity (Figure 4). Visual field examination (Humphrey, Central 30-2 threshold test, stimulus III) showed a mildly enlarged blind spot. The above features were consistent with melanocytoma of the optic nerve head. The patient is examined periodically. The tumor remains stable; there is no deterioration of visual function or evidence of tumor growth to date.

### Discussion

Pigmented tumors of the optic nerve head raised the possibility of malignancy. Primary optic nerve melanoma is extremely rare, whereas secondary invasion of optic nerve by uveal melanoma is uncommon. Lindegaard et al found that the frequency of optic nerve invasion in uveal melanoma varied between 5% and 7%. Increased intraocular pressure and juxtapapillary location of uveal melanoma were risk factors associated with optic nerve invasion.<sup>1</sup> The features of the optic nerve tumor in this patient were consistent with melanocytoma of the optic disk. Nevertheless, the presence of malignancy should be ruled out with a reasonable degree of certainty; due to the aggressive nature of choroidal melanoma and to avoid erroneous enucleation in benign cases.

Melanocytoma of the optic nerve head is a hamartoma consist of large, uniform round or oval heavily pigmented melanocytes that are packed closely. The cells are located among axons in the optic disc, anterior optic nerve

Correspondence: Tan Aik Kah, Ophthalmology Department, Faculty of Medicine and Health Sciences, University Malaysia Sarawak, Lot 77, Sekyzen 22 Kuching Town Land District, Jalan Tun Ahmad Zaidi Aduce, 93150, Kuching, Sarawak, Malaysia.  
Tel +6082.416550 - Fax +6082 422564.  
E-mail: portwinestain@hotmail.com; aktan@fmhs.unimas.my

Key words: melanocytoma, choroidal melanoma, autofluorescence, fluorescein angiography, B-scan ultrasonography, optical coherence tomography.

Contributions: the authors contributed equally.

Conflict of interest: the authors report no conflicts of interest.

Received for publication: 15 July 2011.

Accepted for publication: 28 July 2011.

This work is licensed under a Creative Commons Attribution NonCommercial 3.0 License (CC BY-NC 3.0).

©Copyright Z. Mohmad et al., 2011  
Licensee PAGEPress, Italy  
Clinics and Practice 2011; 1:e60  
doi:10.4081/cp.2011.e60

and in the peripapillary retina.<sup>2</sup> This accounts for the total absence of autofluorescence. Classically, the appearance of optic disk melanocytoma was described as intensely black thickening of the optic disc with a feathery periphery. Hyperpigmentation may vary from dark brown to black. The degree of pigmentation of the tumor in our patient was lesser than those classically described for a

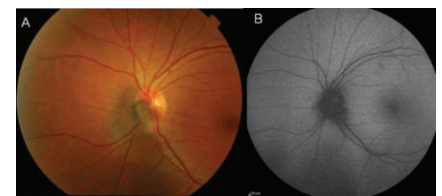

Figure 1. A) Color photo of the left optic disk; B) Absence of autofluorescence.

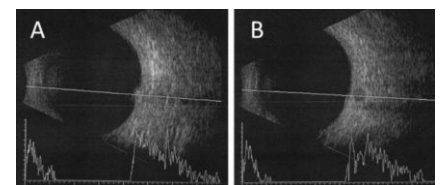


Figure 2. B-scan ultrasonography of the tumor. A) The lesion had a dome-shaped appearance; B) Adjacent choroidal extension of the tumor had low internal reflectivity.

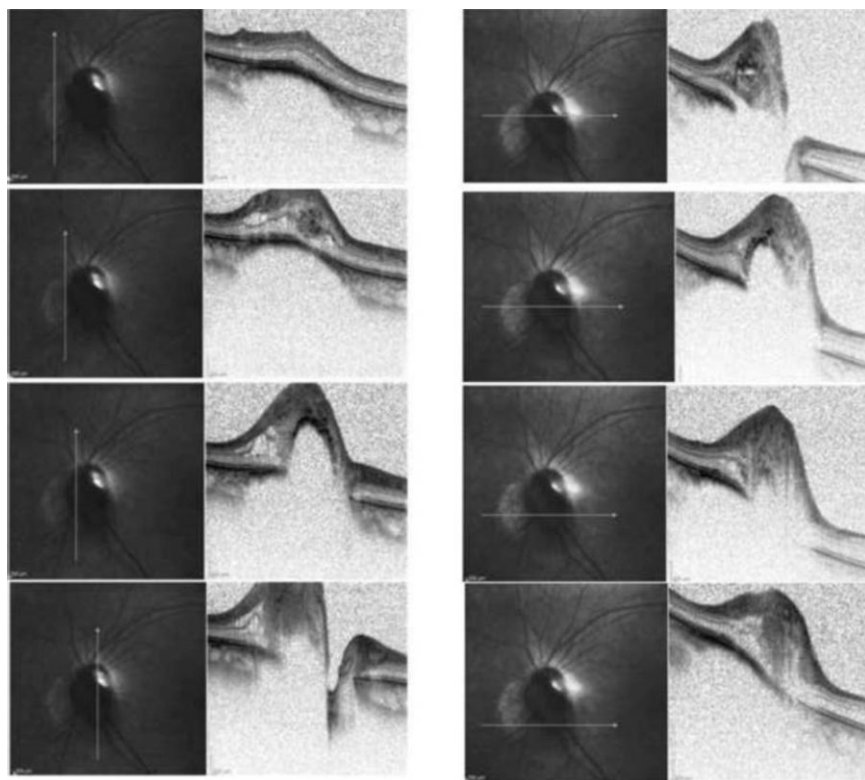


Figure 3. B-scan ultrasonography of the tumor. A) The lesion had a dome-shaped appearance; B) Adjacent choroidal extension of the tumor had low internal reflectivity.

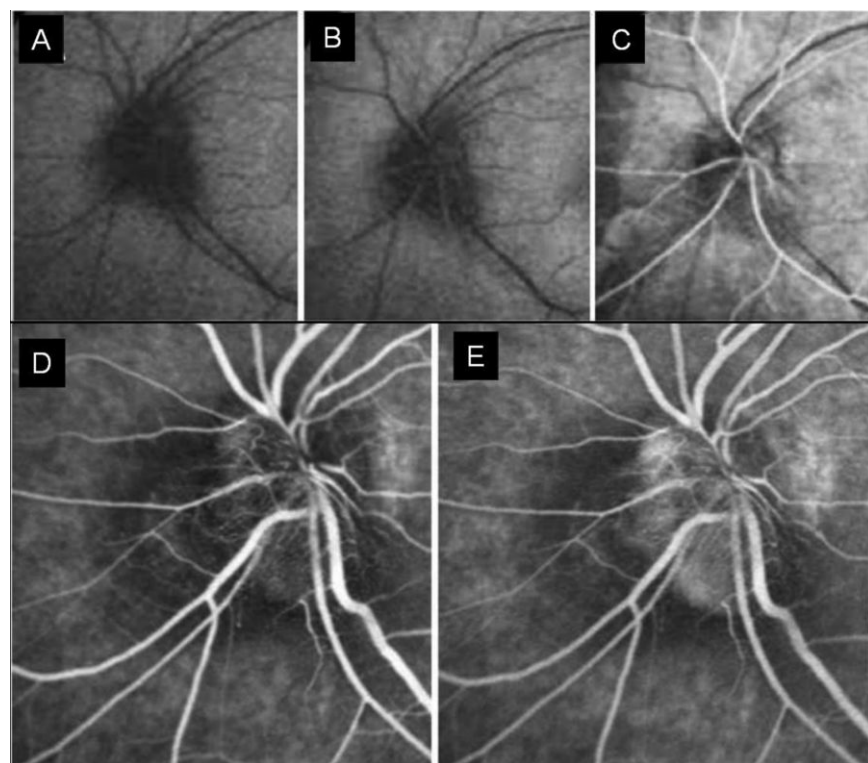


Figure 4. Fluorescein angiography. A) Red-free photograph; B) Choroidal phase; C) Arterial phase; D) At 100 second after injection; E) At 5 minutes after injection.

melanocytoma. Rarely melanocytoma has been reported to present as an amelanotic lesion, which later acquired pigmentation.<sup>3</sup> In about 85% of the cases, melanocytomas extend over the margin of the optic disk to involve the adjacent choroid or retina.<sup>4</sup> Absence of lipofuscin deposition, retinal hemorrhages, retinal edema and subretinal fluid pointed against the diagnosis of malignant melanoma.

Most melanocytomas do not cause significant visual impairment. In the Korean population, Lee *et al* found that 93% of cases have presenting vision of 20/40 or better. Relative afferent pupillary defect was present only in those with vision 20/50 or worse.<sup>3</sup> Visual loss in optic disk melanocytoma may be caused by local compression on the optic nerve, exudative retinal exudation, juxtapapillary choroidal neovascularization, tumor necrosis, central retinal vein obstruction or malignant transformation.<sup>4</sup> Visual field abnormalities reported include enlargement of the blind spot and nerve fiber bundle defects. The blind spot enlargement is related to the amount of tumor extension beyond the disk margin, whereas arcuate defects are related to compression of axons in the optic disk.<sup>4</sup> Melanocytoma of the optic disk was described as a static hamartomatous proliferation.<sup>2</sup> However, increased in tumor size have been documented. In a review of 116 eyes, using Kaplan-Meier survival curve, Shield *et al.* found that minor tumor enlargement occurred in 11% of patients by 5 years and 32% of patients by 10 years. Increased tumor thickness, presence of intrinsic vascularization and nodular (elevated configuration) were risk factors associated with tumor growth.<sup>5</sup> In the Korean population, Kaplan-Meier survival estimated that tumor growth was 0% at 1 year, 14% at 5 years, and 57% at 8 years.<sup>3</sup> Hence, slow increased in tumor size should not be regarded as a sign of malignant transformation. Rapid enlargement of the tumor can be caused by malignant transformation or ischemic necrosis of the tumor. Malignant transformation occurs in 2% of cases. It is not always possible to distinguish the two pathological processes clinically.<sup>4</sup>

The ultrasonographic features of melanocytoma of the optic nerve head was recently described by Gologorsky *et al.* Sixty-two percent (62%) of patients had dome-shaped lesions, while the remainder had mild elevation. About 90% lesions had medium to high internal reflectivity and demonstrated avascularity. They also advocated the use of the high-resolution 20 MHz B-scan for better tumor characterization. Increased tumor thickness, presence of intrinsic vascularization, and nodular (elevated) configuration were the 3 parameters used to stratify lesions into low-risk or high-risk for malignant transformation. These provide guidance for the interval of follow-up examination. They also illustrated a

case of malignant transformation based on ultrasonographic evidence of rapid tumor enlargement and increased tumor vascularity.<sup>6</sup> The presence of low internal reflectivity in our patient may suggest that the lesion is at higher risk of growth or malignant transformation.

In a review of optical coherence tomography (OCT) for intraocular tumor, melanocytoma was found to be a sessile or dome-shaped lesion occupying the anterior portion of the optic nerve with disorganization of the normal optic nerve features. The typical OCT features of melanocytoma of the optic disk were the appearance of a thin, delicate, echogenic line delineating the anterior aspect of the melanocytoma; associated with an abrupt and complete shadowing behind, obscuring all details of the optic nerve and adjacent retina. The mass often spills over into and under the adjacent retina. Retinal involvement appears as optically dense material in the nerve fiber layer and choroidal involvement appeared as slight elevation of the choroid, sometimes with subretinal fluid.<sup>7</sup> In fluorescein and indocyanine green angiography, melanocytoma of the optic disk typically shows persistent hypofluorescence. This is presumable because the cells are deeply pigmented and closely compact with relatively avascularity.<sup>4</sup> Increased vascularity on the surface with staining around the lesion, as in our patient, has been reported and was found to correlate with future tumor growth.<sup>3</sup> Magnetic resonance imaging (MRI) appearance of melanocytoma and uveal melanoma are similar;

hence MRI was not performed for this patient.<sup>8</sup> Life long follow-up is required. To date, there is no change in the patient's visual function or tumor characteristics. The diagnosis of malignant transformation in the future will require careful evaluation of clinical findings in combination with all investigation modalities mentioned above. Confronted with clinical uncertainties of malignant transformation, Lee et al reported the use of aspiration biopsy with a 25-gauge vitrectomy probe in 2 cases of definite tumor enlargement. Histopathological reports provide definitive confirmation of the benign nature of the tumor.<sup>3</sup>

## Conclusions

Melanocytoma of the optic disk is a benign tumor with the potential of growth, ischemic tumor necrosis and malignant transformation. Multiple investigation modalities are needed to confirm the benign nature of the lesion. Careful evaluation and follow-up is crucial to avoid misdiagnosis and erroneous management.

## References

1. Lindegaard J, Isager P, Prause JU,

Heegaard S. Optic nerve invasion of uveal melanoma: clinical characteristics and metastatic pattern. *Invest Ophthalmol Vis Sci* 2006;47:3268-75.

2. Sehu KW, Lee WR. *Ophthalmic Pathology: An illustrated guide for clinicians*. 1st edition. Oxford: Blackwell Publishing; 2005. p. 255.
3. Lee CS, Bae JH, Jeon IH, et al. Melanocytoma of the optic disk in the Korean population. *Retina* 2010;30:1714-20.
4. Shields JA, Demirci H, Mashayekhi A et al. Melanocytoma of the optic disc: a review. *Surv Ophthalmol* 2006;51:93-104.
5. Shields JA, Demirci H, Mashayekhi A, Shields CL. Melanocytoma of optic disc in 115 cases: the 2004 Samuel Johnson Memorial Lecture, part 1. *Ophthalmology* 2004;111:1739-46.
6. Gologorsky D, Scheffler A, Ehlied FJ, et al. Clinical imaging and high-resolution ultrasonography in melanocytoma management. *Clinical Ophthalmology* 2010;4: 855-9.
7. Shields CL, Materin MA, Shields JA. Review of optical coherence tomography for intraocular tumors. *Curr Opin Ophthalmol* 2005;16:141-54.
8. Mafee MF, Karimi A, Shah J, et al. Anatomy and pathology of the eye: role of MR imaging and CT. *Radiol Clin N Am* 2006; 2006;44:135-57.