

Received: 2014.11.18  
Accepted: 2014.12.15  
Published: 2015.04.23

ISSN 1941-5923  
© Am J Case Rep, 2015; 16: 236-239  
DOI: 10.12659/AJCR.893072

## Purulent Pericarditis with Quadruple Valve Endocarditis

Authors' Contribution:  
Study Design A  
Data Collection B  
Statistical Analysis C  
Data Interpretation D  
Manuscript Preparation E  
Literature Search F  
Funds Collection G

ABEF **Huliyurdurga S. Setty Natrajsetty**  
A **Ishwarappa B. Vijayalakshmi**  
F **Chitra Narasimhan**  
AF **Cholenahalli N. Manjunath**

Department of Cardiology, Sri Jayadeva Institute of Cardiovascular Sciences and Research, Bengaluru, Karnataka, India

**Corresponding Author:** Natraj Setty, e-mail: drnatrajsetty75@gmail.com  
**Conflict of interest:** None declared





---

**Patient:** Male, 7  
**Final Diagnosis:** Purulent pericarditis with quadruple valve endocarditis  
**Symptoms:** —  
**Medication:** (4S,4aS,5aR,12aS)-9-[2-(tert-butylamino)acetamido]-4,7bis(dimethylamino)-1,4,4a,5,5a,6,11,12a-octahydro-3,10,12,12a-tetrahydroxy-1,11-dioxo-2naphthacene-carboxamide  
**Clinical Procedure:** Pericardiocentesis  
**Specialty:** Cardiology

**Objective:** Rare disease  
**Background:** Infective endocarditis (IE) is a disease with a highly varied clinical picture. Spread of the infection to the pericardium from the infective endocardium is uncommon and IE involving all 4 cardiac valves is also a very rare occurrence, being more common in intravenous drug users (IVDU).  
**Case Report:** A 7-year-old boy had purulent pericarditis with infective endocarditis (IE) on all 4 cardiac valves and vegetation in the left ventricular and right atrial cavity. Culture of the pericardial fluid grew methicillin-resistant staphylococcus aureus (MRSA) sensitive to tigecycline. The child made a dramatic improvement with tigecycline treatment.  
**Conclusions:** Aggressive management with pericardiocentesis and appropriate antibiotics can show remarkable clinical improvement. Tigecycline can be used safely and effectively as a life-saving drug in children.

**MeSH Keywords:** Endocarditis • Methicillin Resistance • Pericarditis

**Full-text PDF:** <http://www.amjcaserep.com/abstract/index/idArt/893072>

 1005   2  10



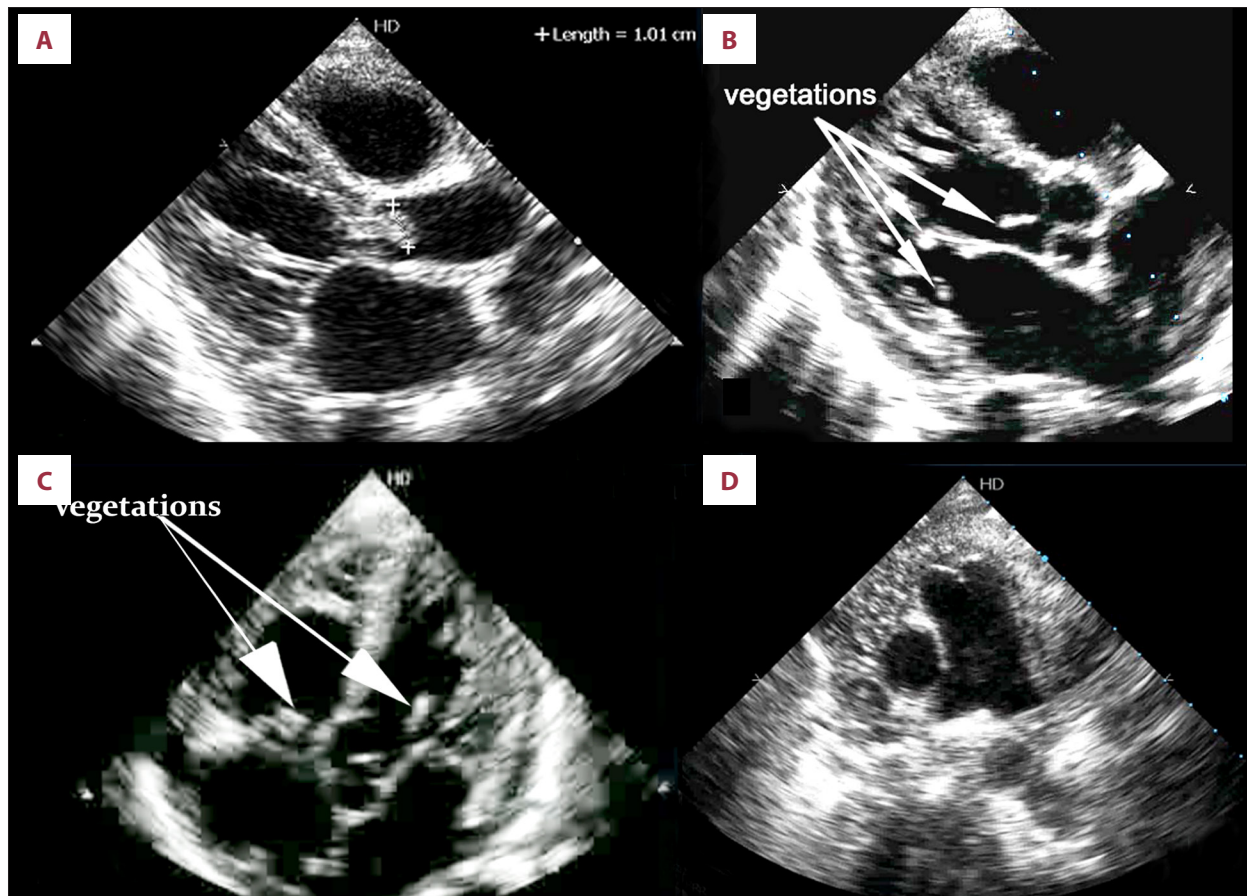
## Background

Infective endocarditis is a disease with a highly varied clinical picture. Spread of the infection to the pericardium from the infected endocardium is uncommon and IE involving all 4 cardiac valves is also a very rare occurrence, being more common in intravenous drug users (IVDU) [1]. We report the case of a 7-year-old boy who had a bicuspid aortic valve with non-compaction of the left ventricle (LV) and the septum, and had a rare combination of purulent pericarditis with quadruple-valve endocarditis of the cardiac valves. This infection was caused by methicillin-resistant *Staphylococcus aureus* and the child responded dramatically to parenteral tigecycline administration.

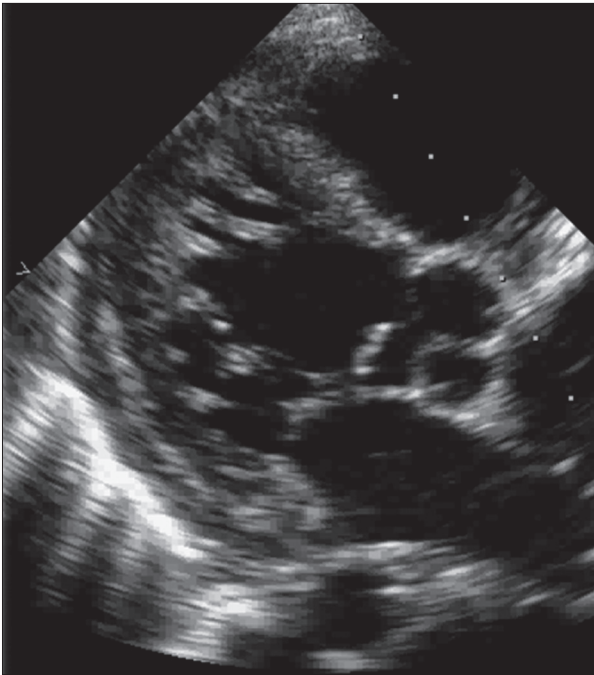
## Case Report

A 7-year-old boy had a history of fall and sustained fracture of the head of the humerus with hemarthrosis of the left shoulder. Aspiration and open nailing had been done 1 week ago. He

presented to us with history of fever with chills, rigors, and breathlessness. On clinical examination, the child was very sick, toxic, listless, febrile, and moribund with puffiness of the face and distension of the abdomen. Pulse was 118/min, regular, and low-volume, and blood pressure was 80/60 mm of Hg. On auscultation, the heart sounds were muffled. Chest x-ray showed cardiomegaly and electrocardiogram showed sinus tachycardia with low-voltage complexes. The echocardiogram on admission showed a large pericardial effusion with tamponade and a large mobile vegetation on the bicuspid aortic valve (Figure 1A). There was mild mitral and tricuspid regurgitation with trivial aortic regurgitation. There was also non-compaction of the LV and the septum (Figure 2). Emergency pericardiocentesis was done, which revealed frank pus. The pus was sent for analysis and for culture and sensitivity testing. The total white blood cell count was 23,800/cu mm, with 80% being neutrophils. He was started on injections of vancomycin 200 mg every 8 hours and amoxicillin plus clavulanic acid 750 mg every 8 hours. On the second day, repeat echocardiogram showed vegetations on the aortic, mitral, tricuspid, and the pulmonary valves. Fuzzy mobile echoes were



**Figure 1.** Transthoracic echocardiogram in: (A) Parasternal long axis view shows a large vegetation on the aortic valve. (B) Parasternal long axis view shows minimal pericardial effusion, non-compaction of the left ventricle and apical septum with vegetation on the mitral valve, papillary muscle, and the aortic valve. (C) Five-chamber view shows vegetation on the aortic, tricuspid, and mitral valves. (D) Short axis view shows vegetation on the pulmonary valve and pus appearing like a contrast echo.



**Figure 2.** Parasternal long axis view shows left ventricular and septal non-compaction with a large vegetation on the aortic valve.

also seen on the mitral valve, papillary muscle, the aortic valve, and tricuspid valve (Figure 1B, 1C). The vegetation was also seen on the pulmonary valve with the pus flakes churning around the heart, giving an appearance of contrast echocardiogram in the pericardium (Figure 1D). The bacteria detector (VITEK 2 COMPACT BIOMERIEUX) detected the organism as MRSA. The pericardial fluid culture and sensitivity report showed maximum sensitivity to tigecycline with  $\leq 0.12$  minimal inhibitory count (MIC) and quinupristin/ dalbapristin with  $\leq 0.25$  MIC. The child started deteriorating and the repeat pericardial cultures showed an increasing MIC from 0.5 to 1 to Vancomycin. Immediately, 50 mg of intravenous tigecycline was administered followed by 25 mg every 12 hours. The child made a dramatic clinical improvement within 24 hours. He became alert, started taking food, and his edema decreased. The echocardiogram repeated after 5 days of tigecycline therapy showed minimal pericardial effusion and vegetation only on the aortic valve. All the other vegetations had completely disappeared. Intravenous tigecycline was given for 14 days. Daily pericardial cavity lavage was done with vancomycin. The repeat culture of the pericardial fluid after 5 days showed no MRSA. After 6 months of follow-up, the child's echocardiogram was normal with a normal pericardium with no vegetations.

## Discussion

The majority of IE cases involve a single cardiac valve; the demonstration of double, triple, or even quadruple valve

involvement by echocardiography is rare [2]. Attachment of the vegetation to the chordae tendineae is also not common. *Staphylococcus aureus* is able to infect the previously normal heart valves and usually causes an acute illness. In most cases, the etiologic microorganisms are methicillin-sensitive *Staphylococcus aureus* [2].

The incidence of purulent pericarditis has declined since the introduction of broad-spectrum antibiotics; untreated, the combination of tamponade and sepsis results in a mortality rate approaching 100% [3]. The overall survival rate is about 30% with antibiotic therapy alone and 50% when combined with early complete surgical drainage [4]. Standard management consists of parenteral antibiotics and surgical drainage. In infants and children, development of purulent pericarditis is associated with pharyngitis, pneumonia, meningitis, otitis media, impetigo, endocarditis, bacterial arthritis, and osteomyelitis [5]. Although the clinical spectrum of bacterial purulent pericarditis has changed over the past 4 decades, *Staphylococcus aureus* is still the most commonly detected microorganism in purulent pericarditis [6]. Methicillin-resistant strains are resistant to all  $\beta$ -lactam antibacterials but usually remain susceptible to vancomycin [7].

In our case, the organism isolated from the pericardial fluid was MRSA. It was sensitive to vancomycin with an MIC of  $< 0.5$ . Although the child was initially started on vancomycin injections, he started deteriorating. Tigecycline with  $\leq 0.12$  MIC and quinupristin/ dalbapristin with  $\leq 0.25$  MIC were the other highly sensitive drugs, as per the pericardial fluid sensitivity report. The drug tigecycline was available, whereas quinupristin/ dalbapristin were not available.

Tigecycline is glycycline antibiotic structurally similar to tetracyclines. The safety and efficacy in pediatric patients younger than 18 years of age has not been established; hence, it is used only in very highly selected cases. Its use in children less than 8 years old is not recommended as it is likely to cause bone and tooth discoloration. Other potential adverse events include photosensitivity, pseudo tumor cerebri, pancreatitis and anti-anabolic effects. The dosage in children aged 12 years and older has been suggested as 1.5 mg/kg followed by 1 mg/kg (not to exceed 50 mg) every 12 hours [8]. In our case, we used half the adult dose, with no adverse effects and it was lifesaving. There are only 2 previous case reports on the use of tigecycline in children [9,10].

## Conclusions

This is the first case report of quadruple valve endocarditis, in a 7-year-old child with purulent pericarditis who responded dramatically to tigecycline. Aggressive management with

pericardiocentesis and appropriate antibiotics achieve remarkable clinical improvement. Tigecycline can be used safely and effectively as a life-saving drug in children, in whom there are no other alternative treatment options. However, further studies on the safety of tigecycline in pediatric patients are needed.

## References:

1. Fernandez JP, McKenzie DB, Roberts PR: Four-valve endocarditis caused by group G *Streptococci*. *Heart*, 2007; 93: 1039
2. Kim N, Lazar JM, Cunha BA, Laio W, Minnaganti V: Multi-valvular endocarditis. *Clin Microbiol Infect*, 2000; 6: 207–12
3. Mann-Segal DDM, Shanahan EA, Jones B, Ramasamy D: Purulent pericarditis: rediscovery of an old remedy. *J Thorac Cardiovasc Surg*, 1996; 111: 487–88
4. Defouilloy C, Meyer G, Slama M et al: Intrapericardial fibrinolysis: a useful treatment in the management of purulent pericarditis. *Intensive Care Med*, 1997; 23: 117–18
5. Hier-Madsen K, Suanamaki KI, Wulff J et al: Purulent pericarditis in children. Review and case report. *Scand J Thorac Cardiovasc Surg*, 1985; 19: 185–88
6. Thebaud B, Sidi D, Kachaner J: Purulent pericarditis in children: a 15 year-experience. *Arch Pediatr*, 1996; 3: 1084–90
7. Chuard C, Herrmann M, Vaudaux P et al: Successful therapy of experimental chronic foreign-body infection due to methicillin-resistant *Staphylococcus aureus* by antimicrobial combinations. *Antimicrob Agents Chemother*, 1991; 35: 2611–16
8. Pankey GA, Steele RW: Tigecycline: A single antibiotic for polymicrobial infections. *Pediatr Infect Dis J*, 2007; 26: 77–78
9. Jaspan HB, Brothers AW, Campbell AJ et al: Multidrug-resistant *Enterococcus faecium* meningitis in a toddler: Characterization of the organism and successful treatment with intraventricular daptomycin and intravenous tigecycline. *Pediatr Infect Dis J*, 2010; 29: 379–81
10. Dinleyici EC, Yargic ZA, Bor O et al: Tigecycline treatment of multi-drug-resistant *Corynebacterium jeikeium* infection in a child with relapsing and refractory acute lymphoblastic leukemia. *Pediatr Blood Cancer*, 2010; 55: 349–51

## Conflict of interest

Nothing to report. No financial grants were received.