



Case report

Wandering splenomegaly reduction after splenopexy

Andy Petroianu^{*}, Kelly Renata Sabino

Department of Surgery, School of Medicine, Federal University of Minas Gerais, Brazil

ARTICLE INFO

Keywords:

Wandering spleen
Splenomegaly
Vascular torsion
Splenic detorsion
Splenopexy
Splenic reduction

ABSTRACT

Introduction and importance: A wandering spleen is characterized by excessive splenic mobility due to the laxity of its ligaments, which leads to spleen migration and its long mobile vascular pedicle is liable to torsion. The purpose of this paper was to present a wandering splenomegaly reduction after splenic detorsion and splenopexy. **Case presentation:** A 14-year-old boy presented a symptomatic visible pelvic wandering splenomegaly with torsion of the splenic pedicle. He was submitted to laparotomy, detorsion of the spleen, and splenopexy to the left diaphragm and surrounded peritoneum. The patient had an uneventful follow-up and was discharged from the hospital on the second postoperative day. All laboratory exams went to normal. The size of the spleen reduced from the $22 \times 16 \times 13$ cm before the treatment to $14 \times 12 \times 10$ cm after the surgical procedure.

Clinical discussion: The most relevant aspect of this communication is the reduction of the huge splenomegaly to a normal size spleen after detorsion of the splenic vessels and splenopexy to the left diaphragm. Reduction of the splenic size is well-known after distal splenorenal shunt, but this is the first publication of a spontaneous splenic size reduction after treating a congestive wandering splenomegaly by detorsion of the spleen pedicle.

Conclusion: Ectopic congestive splenomegaly due to the splenic pedicle rotation is adequately treated by splenic detorsion and splenopexy in its proper subdiaphragmatic site, which reduces the splenic size to normal.

1. Introduction

Splenoptosis, or free-floating, or aberrant, or ectopic, or wandering spleen (WS) is a rare clinical condition defined as an ectopic spleen moved from its normal anatomical position in the left hypochondrium because of the congenital absence or malformations of peritoneal, gastric and colic attachments from the dorsal mesogastrium. In this hypermobility the spleen is attached to the hilum only by a long vascular pedicle and the organ “wanders” in the lower abdomen or in the pelvis [1,2,3]. This condition is predisposed to complications, including the torsion of the splenic pedicle and partial or complete infarction of the spleen associated with splenic vein thrombosis [4,5,6,7,8,9,10]. The WS may be mistaken for an unidentified abdominal mass [1,2,6,10,11,12]. Its long pedicle includes the splenic artery and vein as well as lymphatic ducts and autonomous nerves surrounded by connective tissue. Other associated congenital anomalies must be always considered.

This condition is often asymptomatic and undetected, and thus its exact incidence is unknown [1]. The nonspecific clinical symptoms consisting mostly of abdominal pain make the definition of this diagnosis challenging. As a result, computed tomography (CT) is the best imaging tool to make this diagnosis, although ultrasound may be used as

well. The acute presentation with sudden onset of sharp abdominal pain is usually due to torsion of the splenic pedicle [2,4,5,6,7,8,9,10,11,12,13].

In the presence of a total splenic infarction, treatment is in general splenectomy [5,7,8,11,12]. In such circumstances tissue implants from the removed spleen on the greater omentum, to preserve at least part of the splenic functions, should be considered [14]. In the case of WS with no complications, the first-line treatment is elective laparoscopic splenopexy, performed in different techniques, including or not the use of a mesh [1,6,9,10,15,16]. Elective splenectomy for complicated WS is recommended when the spleen parenchyma is too damaged to recover from several ischemic events, or for the spleen dimension [7,11,12].

The purpose of this communication is to present a wandering splenomegaly reduction after splenic detorsion and splenopexy. This work has been reported in line with the SCARE [17].

2. Presentation of case

The patient was a 14-year-old boy with a visible pelvic mass. He presented a long-term history of frequent episodes of progressively worsening lower abdominal pain associated with dysuria, tenesmus and

^{*} Corresponding author at: Avenida Afonso Pena, 1626 – apto. 1901, Belo Horizonte, MG 30130-005, Brazil.

E-mail address: petroianu@gmail.com (A. Petroianu).

<https://doi.org/10.1016/j.ijscr.2021.106273>

Received 5 July 2021; Received in revised form 1 August 2021; Accepted 1 August 2021

Available online 4 August 2021

2210-2612/© 2021 Published by Elsevier Ltd on behalf of IJS Publishing Group Ltd. This is an open access article under the CC BY-NC-ND license

(<http://creativecommons.org/licenses/by-nc-nd/4.0/>).

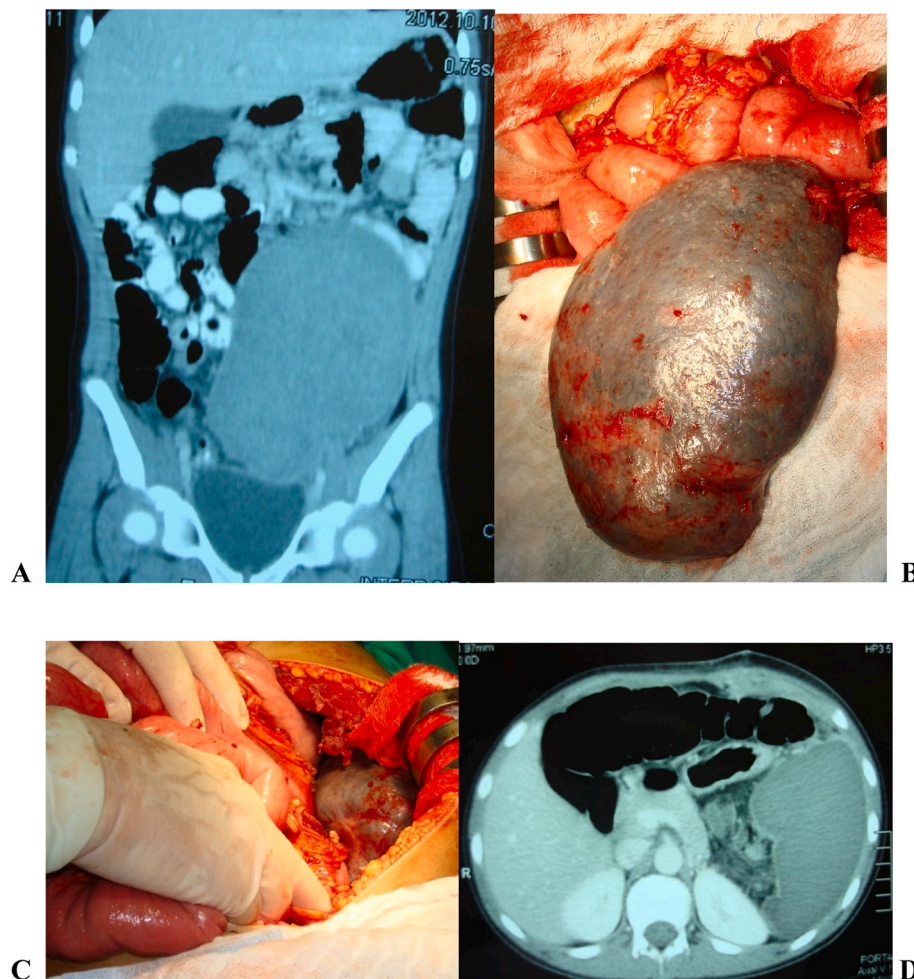


Fig. 1. Wandering splenomegaly.

A – Contrast-enhanced CT scan of the abdomen showing a displaced ectopic spleen in the hypogastrium and pelvic region characteristic of a wandering spleen. Observe the absence of the spleen in the left upper quadrant.

B – Intraoperative appearance of the huge spleen out of the abdomen with no ligament surrounding it.

C – Final view of the surgical procedure. Observe the spleen in the left upper quadrant after the splenopexy.

D – Early post-operative CT scan of the abdomen showing the spleen in the left upper quadrant.

constipation. A physical examination of the abdomen revealed a visible tender pelvic mass, changing position with the variation of the patient's decubitus. The patient and his relatives do not know similar case in their family.

Laboratory data showed a reduced platelet count of $114 \times 10^3/\mu\text{L}$, a white blood cell count of $6.2 \times 10^3/\mu\text{L}$, and a hemoglobin level of 11.2 g/dL. Axial computed tomography (CT) showed the absence of the spleen in the left subphrenic space and a spleen-like mass in the pelvis, suggestive of a WS, compressing the bladder. A coronal contrast-enhanced CT image showed the enlarged spleen, measuring $22 \times 16 \times 13$ cm, suspended by elongated, dilated, and somewhat tortuous splenic vessels. (Fig. 1A) No radiological signs of portal hypertension were found.

Because of the symptomatic splenomegaly with images of torsion, a laparotomy was performed. Examination of the abdomen revealed a large hypogastric mass. (Fig. 1B) The diagnosis of splenic torsion starting at the tail of the pancreas was confirmed during this procedure. The perisplenic ligaments (gastrosplenic, phrenocolic, splenophrenic and splenorenal) were absent leading to an inferiorly displaced wandering spleen and absence of the left colic flexure [2,3] (Fig. 1B). The twisting of these vessels was responsible for the congestive splenomegaly.

Other internal organs were normal. When splenic detorsion was performed, the dark color spleen turned to normal color. The spleen was located in the upper left quadrant and splenopexy was performed with four stitches to the diaphragm and left peritoneum, using a 2-0 polyglactin 910 thread. (Fig. 1C).

The patient had an uneventful recovery and was discharged from the hospital on the second postoperative day. All urinary and digestive

complaints as well as abdominal discomfort, disappeared in the early post-operative period. All laboratory exams went to normal, including platelet count of $280 \times 10^3/\mu\text{L}$, a white blood cell count of $6.4 \times 10^3/\mu\text{L}$, and a hemoglobin level of 14.9 g/dL. A CT image showed the preservation of the enlarged spleen, measuring $22 \times 16 \times 13$ cm in the upper left quadrant. (Fig. 1D) After four years, the patient is still in good health with a normal life, with no complaint related to the spleen and the surgical procedure. The spleen is not palpable. All laboratory exams are normal. A new CT image demonstrated an almost normal size spleen ($14 \times 12 \times 10$ cm) with no splenic or abdominal abnormality.

3. Discussion

The ectopic spleen is a rare condition, which is responsible for 0.25% of all splenectomies [1,6,8,12,14]. Nevertheless, more than 700 papers have been published describing this splenic disorder. This abnormality is found more commonly in women of the reproductive age group, however, in pediatrics, this condition is more detected in boys [1,10,12,16]. The diagnosis is difficult due to nonspecific clinical or laboratory findings, except for occasional pancytopenia, and is defined only by imaging exams [1,2,7,11,12,15]. This condition is usually asymptomatic, but it may be responsible for chronic abdominal pain with or without gastrointestinal or urinary symptoms. Patients with torsion of the wandering spleen may have not only acute abdomen, or chronic and intermittent symptoms, but also splenomegaly and splenic infarction as a result of vascular congestion [4,5,6,7,8,11,13].

The treatment must consider the risk of post-splenectomy overwhelming sepsis, mainly in the pediatric and elderly population, as well

as in patients with chronic diseases [1,2,15]. A conservative approach is the best management whenever possible. Detorsion and splenopexy must always be tried to avoid many complications of the asplenic status [2,10,12,16]. Even when a splenectomy is indicated, the surgeon is able to cut the removed spleen in small cubes (1 cm to 2 cm) and perform at least 50 g of splenic tissue implants on the greater omentum in order to preserve the splenic drainage to the portal vein and liver, as well as to maintain the immune splenic functions [2,14].

Concerning all these treatments, laparoscopic procedures should be preferred whenever feasible. Laparoscopic splenopexy has many advantages over open splenopexy or splenectomy, including preserving splenic function, minimal postoperative pain, early discharge from the hospital, and rapid recovery [1,2,5,12,16]. Spleen size must be taken into consideration, facing the frequent necessity of conversion to open surgery in the presence of splenomegaly [10,12,10,15,16].

The most relevant aspect of this communication is the reduction of the huge splenomegaly to a normal size spleen after detorsion of the splenic vessels and splenopexy to the left diaphragm. Reduction of the splenic size is well-known after distal splenorenal shunt (Warren procedure) to treat splenomegaly due to portal hypertension [2]. However, this is the first publication of a spontaneous splenic size reduction after treating a congestive wandering splenomegaly by detorsion of the spleen pedicle due to the normalization of the venous blood flow. After detorsion, the color of the entire spleen returned to normal, without apparent infarction in any part of the spleen.

The wandering spleen is frequently associated with the partial or total vascular pedicle torsion, leading to impairment of the natural blood flow. The blood pressure allows the arterial flow to the spleen, but the venous course is never adequate. Therefore, a splenic congestion and even a splenomegaly results from the venous blood flow decreasing. After detorsion of the spleen and its vascular pedicle, the blood flow is released and the splenic congestion reduces. The splenopexy in the splenic normal place prevents a new torsion, and, in the case of this report, after several months the spleen reduced its size to normal without any shunt.

4. Conclusion

Ectopic congestive splenomegaly due to the splenic pedicle rotation is adequately treated with splenic detorsion and splenopexy in its proper subdiaphragmatic site, which reduces the splenic size to normal.

Ethical approval

Patient gave to the authors a signed informed consent. Ethical

approval was not required; this paper reports the treatment performed in a patient without research intention.

Funding

The authors declare there is no funding or sponsor related to this work or manuscript.

CRediT authorship contribution statement

ANDY PETROIANU: Conceptualization; Data curation; Formal analysis; Investigation; Methodology; Performed the surgical procedure; Assisted the patient; Writing original draft, reviewing and editing; Responsible for all informations; Submitting the article for publication.

KELLY RENATA SABINO: Data curation; Formal analysis; Investigation; Assisted the patient; Writing original draft.

Guarantors

Andy Petroianu and Kelly Renata Sabino accept full responsibility for the work and/or the conduct of the study, had access to the data, and controlled the decision to publish.

Registration of research studies

This paper is not a research on human participants, it is a case report of a patient who was treated by the authors. All findings reported herein were registered during this treatment.

The registration unique identifying number is: researchregistry7017.

Consent

Written informed consent was obtained from the patient for publication of this case report and accompanying images. A copy of the written consent is available for review by the Editor-in-Chief of this journal on request. No alteration of scientific meaning derives from identifying data omission.

Provenance and peer review not commissioned, externally peer-reviewed.

Declaration of competing interest

The authors declare they have no competing interests.