

**EDITORIAL**

## EIC Remarks for a Special 20th Anniversary Issue of MRMS

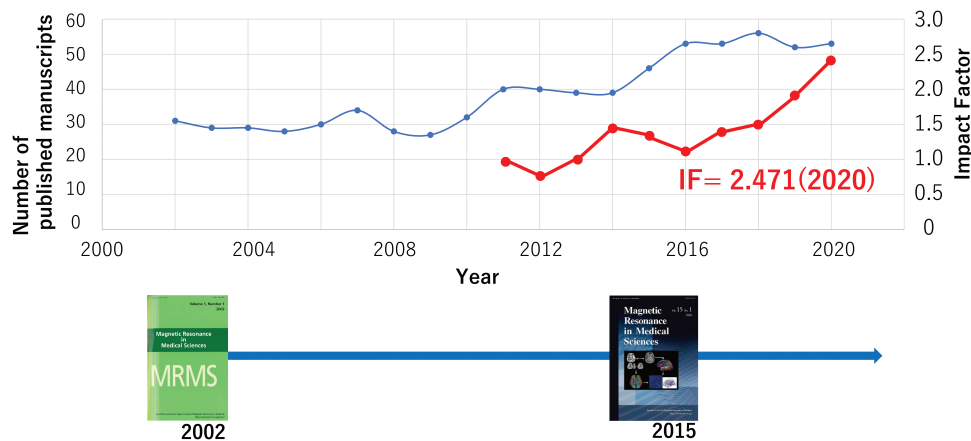
Takayuki Obata

Editor-in-Chief, Magnetic Resonance in Medical Sciences

Magnetic Resonance in Medical Sciences (MRMS), the official journal of the Japanese Society of Magnetic Resonance in Medicine (JSMRM), has reached the milestone of Vol. 20. To celebrate the occasion, we have invited a group of researchers who have made certain outstanding contributions over the years to write a review article for this special 20th anniversary issue. We sincerely thank the authors for their contributions and believe that you will find the reviews informative as they contain a lot about the recent state of the art.

For the 20th anniversary, I would like to present here a short history of the journal and talk about some of the major contributors to MRMS over the years. MRMS was first published in 2002 under the leadership of Professor Kazuro Sugimura, the 1st Editor-in-Chief (EIC). His mission was to create an internationally recognized journal published by JSMRM for all active MR scientists and engineers. At first, MRMS was unfamiliar to people in the field of MR, but under the 2nd EIC, Dr. Tsuneya Watabe, the editorial committee endeavored to raise the profile of the journal. Happily, the number of submissions has gradually increased over time. At about the time Dr. Shigeki Aoki was selected as the 3rd EIC, MRMS succeeded in acquiring an Impact Factor (IF), and from that time, the number of submissions has significantly increased. Although there have been some fluctuations, the IF has been on an upward trend with the most recent value, announced in June 2021, being 2.471 (Fig. 1).

We are extremely grateful for the contributions of both the authors who submit important research and the reviewers who volunteer their time to review and comment on those submissions. From here, I would like to introduce some of the major contributions.



**Fig. 1** Year-by-year changes to the number of published manuscripts (blue) together with the IF (red). The design of the journal cover was changed to the current version in 2015. IF, Impact Factor.



This work is licensed under a Creative Commons Attribution-NonCommercial-NoDerivatives International License.

©2022 Japanese Society for Magnetic Resonance in Medicine

**Table 1** Most cited papers

Authors	Title	Year	Citation	Type
Reiko Woodhams, et. al. <sup>1</sup>	ADC mapping of benign and malignant breast tumors.	2005	261	Major Paper
Akira Kunimatsu, et. al. <sup>2</sup>	The optimal trackability threshold of fractional anisotropy for diffusion tensor tractography of the corticospinal tract.	2004	198	Major Paper
Masamitsu Hatakenaka, et. al. <sup>3</sup>	Apparent diffusion coefficients of breast tumors: clinical application.	2008	190	Major Paper
Kei Yamada, et. al. <sup>4</sup>	MR Tractography: A Review of Its Clinical Applications	2009	188	Review
Christoph J Zech, et. al. <sup>5</sup>	MR imaging in patients with suspected liver metastases: value of liver-specific contrast agent Gd-EOB-DTPA.	2007	185	Major Paper
Yoshifumi Kuroki, et. al. <sup>6</sup>	Diffusion-weighted imaging of breast cancer with the sensitivity encoding technique: analysis of the apparent diffusion coefficient value.	2004	163	Major Paper
Dow-Mu Koh, et. al. <sup>7</sup>	Practical aspects of assessing tumors using clinical diffusion-weighted imaging in the body.	2007	160	Major Paper
Katsuyuki Nakanishi, et. al. <sup>8</sup>	Whole-body MRI for detecting metastatic bone tumor: diagnostic value of diffusion-weighted images.	2007	138	Major Paper
Kazuhiro Saito, et. al. <sup>9</sup>	Gd-EOB-DTPA enhanced MRI for hepatocellular carcinoma: quantitative evaluation of tumor enhancement in hepatobiliary phase.	2005	130	Major Paper
Shinji Naganawa, et. al. <sup>10</sup>	Diffusion-weighted imaging of the liver: technical challenges and prospects for the future.	2005	123	Major Paper

The most cited articles over the past 20 years are listed in Table 1. All these papers have received more than 100 citations, indicating that MRMS has always published high quality and influential work.

To reduce bias due to the length of time from publication, Table 2 lists papers that have received the most citations in the first two years from the publication date.

We also greatly appreciate all those researchers who have participated in the peer review process. Table 3 lists those reviewers who, we think, have made a particularly valuable contribution.

Each year since 2006, the JSMRM has selected the best original articles appearing in MRMS. Table 4 lists the first authors of those articles.

The editorial committee has also recently selected the following article to be the best article in the first 20 years of MRMS' history (Table 5).<sup>11</sup>

You can also read a review related to this article in this special issue (see P.182–194). The review was written by the first author, Dr. Naganawa.

In this editorial, I have presented a brief history of our journal. It is not possible to list the names of all the authors and reviewers who have contributed over the years, but we thank them all. We also thank the many companies that have supported MRMS, not only financially but also through their scientific and technological collaborations with our authors. Finally, I really appreciate the excellent work of the editorial committee members and all the JSMRM staff. If you have any comments or suggestions that you think may help further improve our journal, please send them to [editor\\_in\\_chief@jsmrm.jp](mailto:editor_in_chief@jsmrm.jp)

**Table 2** Papers with the most citations within two years of the publication date

Author	Title	Year	Citation	Type
Masamitsu Hatakenaka, et al. <sup>3</sup>	Apparent diffusion coefficients of breast tumors: clinical application.	2008	31	Major Paper
Shinji Naganawa, et al. <sup>11</sup>	Gd-based Contrast Enhancement of the Perivascular Spaces in the Basal Ganglia	2017	30	Major Paper
Toshiaki Taoka, Shinji Naganawa <sup>12</sup>	Gadolinium-based Contrast Media, Cerebrospinal Fluid and the Glymphatic System: Possible Mechanisms for the Deposition of Gadolinium in the Brain	2018	30	Review
Shintaro Ichikawa, et al. <sup>13</sup>	Magnetic Resonance Elastography for Staging Liver Fibrosis in Chronic Hepatitis C	2012	29	Major Paper
Kei Yamada, et al. <sup>4</sup>	MR Tractography: A Review of Its Clinical Applications	2009	22	Review
Shinji Naganawa, et al. <sup>14</sup>	Visualization of Endolymphatic Hydrops in Meniere's Disease with Single-dose Intravenous Gadolinium-based Contrast Media using Heavily T-2-weighted 3D-FLAIR	2010	18	Major Paper
Masami Goto, et al. <sup>15</sup>	Head Motion and Correction Methods in Resting-state Functional MRI	2016	16	Review
Lauren Wallaert, et al. <sup>16</sup>	The Advantage of Synthetic MRI for the Visualization of Anterior Temporal Pole Lesions on Double Inversion Recovery (DIR), Phase-sensitive Inversion Recovery (PSIR), and Myelin Images in a Patient with CADASIL	2018	16	Major Paper
Ningxin Chen, et al. <sup>17</sup>	Added Value of a Gadoteric Acid-enhanced Hepatocyte-phase Image to the LI-RADS System for Diagnosing Hepatocellular Carcinoma	2016	15	Major Paper

**Table 3** Winners of the reviewer awards

	Most valuable reviewer		Most distinguished reviewer	
2014	Yoshiteru Seo	Toshiaki Taoka	Shinji Naganawa	Takashi Yoshiura
2015	Toshinori Hirai		Mika Kitajima	Akira Kunimatsu
2016	Noriyuki Fujima		Kazuhiro Tsuchiya	
2017	Masayuki Maeda		Shingo Kato	Yoshiyuki Watanabe
2018	Aki Kido	Yuichi Suzuki	Takatoshi Aoki	Junichi Hata
			Takao Komada	Yoshiyuki Watanabe
2019	Yoshitaka Bito	Mika Kitajima	Shintaro Ichikawa	Shigeo Okuda
			Yasutaka Fushimi	Koji Kamagata
			Yasuhiko Tachibana	Takahiro Tsuboyama
			Kazuhiro Tsuchiya	Daisuke Utsunomiya
			Koichiro Yasaka	

*(Continued)*

**Table 3** (Continued).

	Most valuable reviewer	Most distinguished reviewer	
2020	Yasuhiko Tachibana	Kentaro Akazawa	Shintaro Ichikawa
		Mika Kitajima	Takao Komada
		Yoshitaka Masutani	Shinji Naganawa
		Shigeo Okuda	Noriko Oyama-Manabe
		Daiki Tamada	

**Table 4** The 1st authors of the best articles of the year

<b>2006</b>	Atsushi Wakai, Akihiro Tanimoto
<b>2007</b>	Hirotsada Fujii, Eri Shibata
<b>2008</b>	Hiroyuki Muranaka, Yoshimasa Matsuda, Makoto Sasaki
<b>2009</b>	Taisuke Nagao, Atsuomi Kimura
<b>2010</b>	Hajime Tamura, Tokunori Kimura
<b>2011</b>	Eizou Umezawa, Masaya Matsushima
<b>2012</b>	Tsutomu Soma, Masako Suzuki
<b>2013</b>	Yukihisa Takayama, Shintaro Ichikawa
<b>2014</b>	Mariko Kajihara, Dai Joishi
<b>2015</b>	Koichi Oshio, Yoshitaka Masutani
<b>2016</b>	Yoshitaka Bito, Fumie Yamazaki
<b>2017</b>	Kouhei Kamiya, Tokunori Kimura
<b>2018</b>	Shinji Naganawa, Satoru Ide
<b>2019</b>	Kohsuke Kudo, Satoshi Yatsushiro
<b>2020</b>	Akihiko Wada, Akira Kunimatsu
<b>2021</b>	Yasuo Takehara, Ryusuke Irie

**Table 5** The best article in the first 20 years of MRMS' history

Gd-based Contrast Enhancement of the Perivascular Spaces in the Basal Gangli<sup>11</sup>  
 Shinji Naganawa, Toshiki Nakane, Hisashi Kawai, and Toshiaki Taoka  
 Magn Reson Med Sci. 2017; 16:61–65.

## References

1. Woodhams R, Matsunaga K, Kan S, Hata H, Ozaki M, Iwabuchi K, et al. ADC mapping of benign and malignant breast tumors. *Magn Reson Med Sci* 2005; 4:35–42.
2. Kunimatsu A, Aoki S, Masutani Y, Abe O, Hayashi N, Mori H, et al. The optimal trackability threshold of fractional anisotropy for diffusion tensor tractography of the corticospinal tract. *Magn Reson Med Sci* 2004; 3:11–17.
3. Hatakenaka M, Soeda H, Yabuuchi H, Matsuo Y, Kamitani T, Oda Y, et al. Apparent diffusion coefficients of breast tumors: clinical application. *Magn Reson Med Sci* 2008; 7:23–29.
4. Yamada K, Sakai K, Akazawa K, Yuen S, Nishimura T. MR tractography: a review of its clinical applications. *Magn Reson Med Sci* 2009; 8:165–174.
5. Zech CJ, Herrmann KA, Reiser MF, Schoenberg SO. MR imaging in patients with suspected liver metastases: value of liver-specific contrast agent Gd-EOB-DTPA. *Magn Reson Med Sci* 2007; 6:43–52.
6. Kuroki Y, Nasu K, Kuroki S, Murakami K, Hayashi T, Sekiguchi R, et al. Diffusion-weighted imaging of breast cancer with the sensitivity encoding technique: analysis of the apparent diffusion coefficient value. *Magn Reson Med Sci* 2004; 3:79–85.
7. Koh DM, Takahara T, Imai Y, Collins DJ. Practical aspects of assessing tumors using clinical diffusion-weighted imaging in the body. *Magn Reson Med Sci* 2007; 6:211–224.
8. Nakanishi K, Kobayashi M, Nakaguchi K, Kyakuno M, Hashimoto N, Onishi H, et al. Whole-body MRI for detecting metastatic bone tumor: diagnostic value of diffusion-weighted images. *Magn Reson Med Sci* 2007; 6:147–155.
9. Saito K, Kotake F, Ito N, Ozuki T, Mikami R, Abe K, et al. Gd-EOB-DTPA enhanced MRI for hepatocellular carcinoma: quantitative evaluation of tumor enhancement in hepatobiliary phase. *Magn Reson Med Sci* 2005; 4:1–9.
10. Naganawa S, Kawai H, Fukatsu H, Sakurai Y, Aoki I, Miura S, et al. Diffusion-weighted imaging of the liver: technical challenges and prospects for the future. *Magn Reson Med Sci* 2005; 4:175–186.
11. Naganawa S, Nakane T, Kawai H, Taoka T. Gd-based contrast enhancement of the perivascular spaces in the basal ganglia. *Magn Reson Med Sci* 2017; 16:61–65.
12. Taoka T, Naganawa S. Gadolinium-based contrast media, cerebrospinal fluid and the glymphatic system: Possible mechanisms for the deposition of gadolinium in the brain. *Magn Reson Med Sci* 2018; 17:111–119.
13. Ichikawa S, Motosugi U, Ichikawa T, Sano K, Morisaka H, Enomoto N, et al. Magnetic resonance elastography for staging liver fibrosis in chronic hepatitis C. *Magn Reson Med Sci* 2012; 11:291–297.
14. Naganawa S, Yamazaki M, Kawai H, Bokura K, Sone M, Nakashima T. Visualization of endolymphatic hydrops in Ménière's disease with single-dose intravenous gadolinium-based contrast media using heavily T(2)-weighted 3D-FLAIR. *Magn Reson Med Sci* 2010; 9:237–242.
15. Goto M, Abe O, Miyati T, Yamasue H, Gomi T, Takeda T. Head motion and correction methods in resting-state functional MRI. *Magn Reson Med Sci* 2016; 15:178–186.
16. Wallaert L, Hagiwara A, Andica C, Hori M, Yamashiro K, Koshino S, et al. The advantage of synthetic MRI for the visualization of anterior temporal pole lesions on double inversion recovery (DIR), Phase-sensitive inversion recovery (PSIR), and myelin images in a patient with CADASIL. *Magn Reson Med Sci* 2018; 17:275–276.
17. Chen N, Motosugi U, Morisaka H, Ichikawa S, Sano K, Ichikawa T, et al. Added value of a Gadoteric acid-enhanced hepatocyte-phase image to the LI-RADS system for diagnosing hepatocellular carcinoma. *Magn Reson Med Sci* 2016; 15:49–59.