

## SURGERY

# Proximal Extracapsular Tunneling: A Simple Technique for the Management of Impending Cylinder Erosion and Complications Related to Corporal Dilation



Jonathan Clavell-Hernández, MD<sup>1,2</sup>

## ABSTRACT

**Introduction:** Impending cylinder erosion and floppy glans secondary to an undersized penile prosthesis are rare complications that can cause cosmetic deformity and patient discomfort.

**Aim:** To demonstrate a technique for the management of impending cylinder erosion and floppy glans secondary to cylinder under-sizing.

**Methods:** We retrospectively reviewed 6 patients who required the proximal extracapsular tunneling technique during penile prosthesis revision surgery.

**Main Outcome Measure:** Main outcome was successful placement of a penile prosthesis with proper cylinder placement.

**Results:** Mean patient age for these 6 patients was 71.2 years (64–86 y). After a mean follow-up of 6.6 months, all 6 patients who underwent this procedure had a functional penile prosthesis without evidence of recurrence.

**Conclusion:** The proximal extracapsular tunneling technique is a simple approach performed through a single incision that can be used for proper cylinder replacement during penile prosthesis revision surgeries. It may be utilized for the management of impending cylinder erosion and other cases with corporal dilation-related complications in which the surgical pseudo-capsule has already formed around the implant. This technique can be safely performed without the need of a distal counter-incision on the penis. **Clavell-Hernández J. Proximal Extracapsular Tunneling: A Simple Technique for the Management of Impending Cylinder Erosion and Complications Related to Corporal Dilation. Sex Med 2021;9:100379.**

Copyright © 2021 The Authors. Published by Elsevier Inc. on behalf of the International Society for Sexual Medicine. This is an open access article under the CC BY-NC-ND license (<http://creativecommons.org/licenses/by-nc-nd/4.0/>).

**Key Words:** Inflatable Penile Prosthesis; Extracapsular Tunneling; Impending Cylinder Erosion; Glans Hypermobility; Corporal Dilation

## INTRODUCTION

The inflatable penile prosthesis (IPP) has been proven to be one of the most reliable medical devices currently available with 70% 15-year survival rate.<sup>1</sup> Given its longevity, revision surgeries have been reported to be more common for nonmechanical reasons,

including cosmetic problems and erosion, than mechanical complications.<sup>2–4</sup> Cosmetic complications after IPP surgery include floppy glans or SST deformity, impending cylinder erosion and cylinder aneurysm. The first two have been managed with different techniques most of which involve a distal counter-incision.

Floppy glans, commonly referred to as glans hypermobility, can occur in the setting of an improperly sized implant secondary to inadequate dilation.<sup>5</sup> This is often managed with a glanulopexy,<sup>6,7</sup> but when severely undersized (Figure 1), may require explant of the cylinders, re-dilation and re-implantation of prosthetic cylinders. Moreover, impending cylinder erosion, also referred to as extrusion, is a rare complication during penile prosthesis surgery that is commonly managed with a counter-incision in the distal shaft (Figure 2). This occurs when the

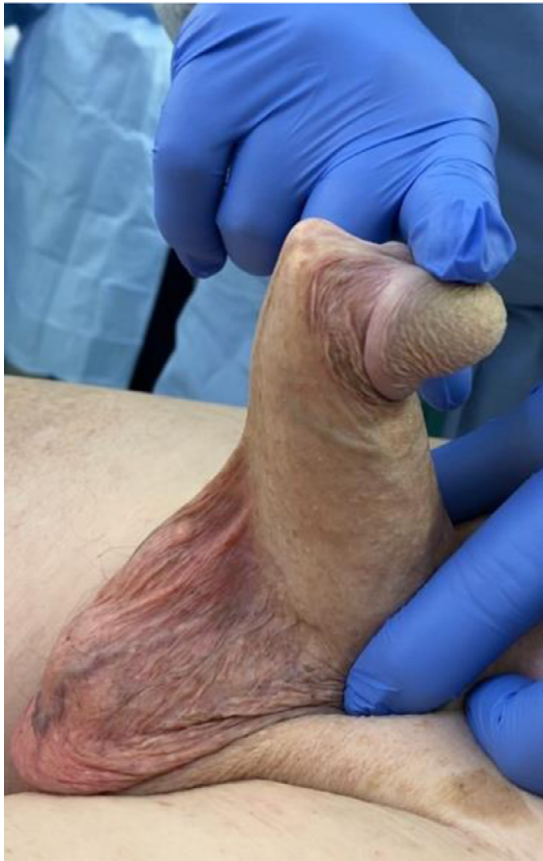Received January 13, 2021. Accepted April 9, 2021.

<sup>1</sup>University of Texas Health Science Center - McGovern Medical School at Houston, Texas, USA;

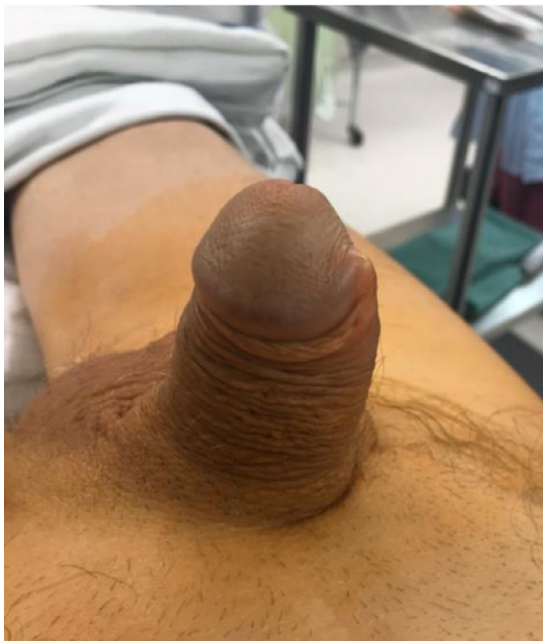<sup>2</sup>St Joseph Medical Center, Houston, Texas, USA

Copyright © 2021 The Authors. Published by Elsevier Inc. on behalf of the International Society for Sexual Medicine. This is an open access article under the CC BY-NC-ND license (<http://creativecommons.org/licenses/by-nc-nd/4.0/>).

<https://doi.org/10.1016/j.esxm.2021.100379>



**Figure 1.** Flail penis, or severe glans hypermobility, secondary to undersized cylinders.



**Figure 2.** Impending cylinder erosion.

prosthetic cylinder presses under the skin after it has worked its way through or against a weakened tunica albuginea.

Refinements in surgical technique are common during corrective surgery for penile implants. In the setting of impending cylinder erosions and glans hypermobility, techniques reported in the literature often include a distal counter-incision. We hereby present a simple technique, called extracapsular tunneling (ECT), that avoids a counter-incision. ECT can be used for the management of impending distal erosion, flail penis secondary to cylinder under sizing, among other cosmetic complications secondary to improper corporal dilation.

## METHODS

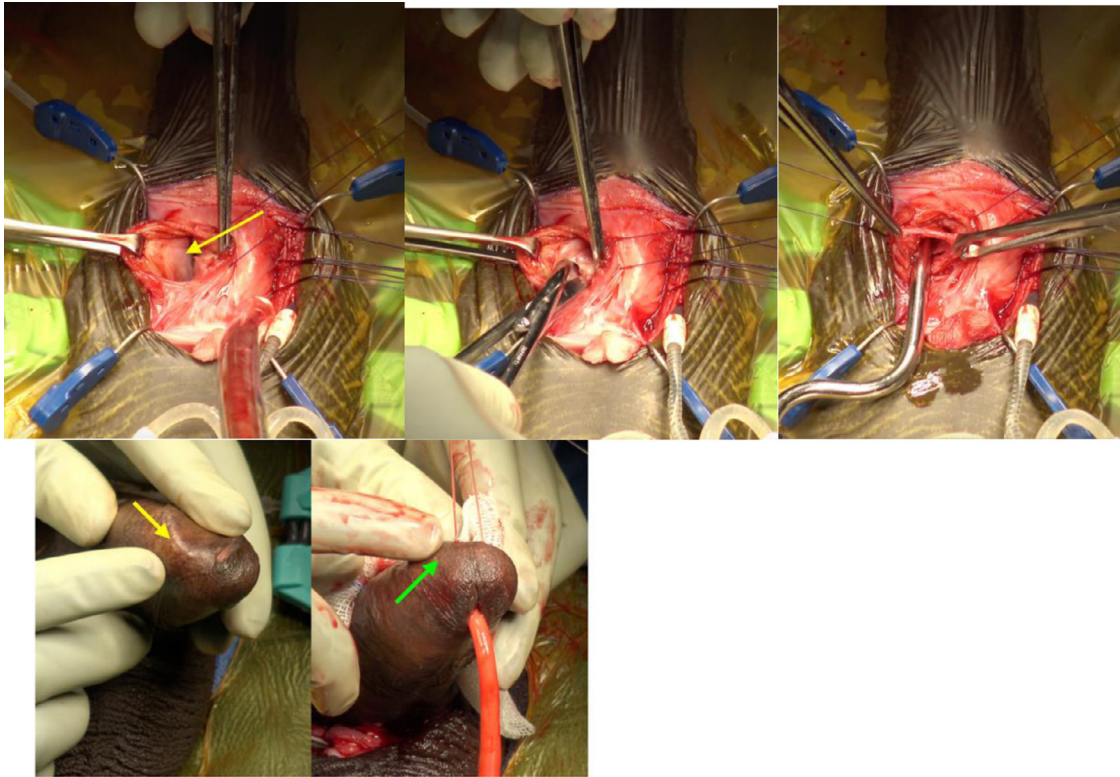
From November 2019 to November 2020, a total of 18 revision cases were performed by a single surgeon of which 6 patients underwent removal and replacement with extracapsular tunneling. This study obtained approval from the Institutional Review Board (IRB: 187020).

The indication for ECT is impending distal erosion of an IPP and any other deformities caused in the distal shaft by misplacement of the cylinders which include: extrusion, corporal cross-over, and glans hypermobility secondary to undersized cylinders. Undersized cylinders that have been present for several months form a pseudo-capsule that can be challenging to perforate through for the unexperienced implanter. Extracapsular tunneling allows the surgeon to develop a new 'virgin' tract outside of the surgical capsule. The technique can be done through a proximal incision, either via a penoscrotal or infrapubic approach, which allows for better tissue coverage to prevent infection and eliminates the need for a counter incision.

Prior to performing this type of revision surgery, the patient's penis and urethra should be examined to rule out the presence of a complete erosion or infection. If a microperforation or a cylinder is visible, a revision surgery with replacement of a cylinder should be avoided. The patient is prepped in similar fashion as for any routine IPP surgery. The procedure can be performed under local, regional or general anesthesia. Broad spectrum antibiotics are given prior to commencement of the surgery and the patient's skin, including the lower abdomen, genitals and perineum, is prepped with Chloraprep.

## Procedure

The procedure can be performed through an infrapubic or a penoscrotal incision. It is our preference to perform this procedure through a penoscrotal incision. The prosthetic pump is first identified, dissected and exposed to the surgical field. Tubings going from the pump to the prosthetic cylinders are traced until their point of origin in the bilateral proximal corporas. A corporotomy is performed by cutting through the tunica albuginea and dissection is carried down until the anterior aspect of the



**Figure 3.** A. Exposure of the posterior wall of the surgical pseudo-capsule (yellow arrow). B. Posterior wall of the surgical pseudo-capsule is incised and opened until the corporal sinusoidal tissue is identified. C. Dilation of the new extracapsular space. D. Before and after pictures of the point of impending cylinder erosion (yellow arrow) and proper cylinder replacement after ECT (green arrow).

surgical capsule surrounding the IPP cylinder is visualized. The capsule is then incised and opened to expose the cylinders.

The prosthetic cylinder is removed, including rear tip extenders. Allis clamps are used to grab the walls of both the surgical capsule and the corporotomy in order to identify the posterior wall of the surgical capsule (Figure 3a). The intracapsular space is irrigated with antibiotic solution to prevent infection. The posterior wall of the surgical capsule is then identified and incised with either a blade or sharp scissors to identify the corporal sinusoidal tissue behind the capsule (Figure 3b). Once the opening of the extracapsular space is created, stay sutures are placed to include both the corporotomy and the new edge of the extracapsular tunnel. EC tunneling is performed by serially dilating (starting with size 9 Brooks or Hegar dilators) the space posterior and lateral to the previous intracapsular space (Figure 3c).

Once the extracapsular space is completely developed, a Furlow needle-introducer device is placed through the extracapsular tunnel to facilitate placement of a new IPP cylinder. Previously placed stay sutures are then tied to close the corporotomy. The remainder of the operation is performed in the standard fashion for IPP insertion (Figure 3d).

### Postoperative Management

The patient can be discharged after the surgery or admitted for 23-hour observation. Antibiotic prophylaxis is encouraged

perioperatively and continued for 1 week after surgery. It is our standard practice to use a 3<sup>rd</sup> generation cephalosporin. The patient's IPP is left inflated ~75% of its full capacity for 6 weeks after surgery to avoid displacement and ensure proper re-encapsulation. After 6 weeks, the patient can resume cycling of the implant. Sexual activity is avoided for 6 weeks.

### RESULTS

From November 2019 to November 2020, a total of 18 revision cases were performed by a single high-volume surgeon of which 6 patients underwent removal and replacement with extracapsular tunneling. Mean patient age for these 6 patients was 71.2 years (64–86 y). Even though the procedure can be performed with the anesthesia of the surgeon's choice, we performed all six cases under general anesthesia. Reason for use of the extracapsular tunneling varied and included: 3 impending erosions, 1 severe glans hypermobility/flail penis who presented 10 months after original implantation, one delayed proximal crossover and one with proximal cylinder aneurysm. An AMS 700 CX IPP was used for 3 cases and Coloplast Titan IPP device was used for the other 3 cases (Table 1).

Mean time from initial placement to revision surgery with ECT was 5.8 years (range 6 mo to 15 y) After a mean follow-up of 6.6 months, all 6 men were doing well and engaging in



**Table 1.** Summary of cases and patient characteristics.

	Age	Comorbidities	Main complaint	Time since IPP (y)	# of revisions	Type of anesthesia	Approach for ECT	Type of implant
Patient 1	64	None	Malfunction and cylinder aneurysm	6	3 <sup>rd</sup>	General	PS	Coloplast titan
Patient 2	86	HTN, PCa s/p cryotherapy	Flail penis	0.5	3 <sup>rd</sup>	General	PS	AMS CX
Patient 3	70	HTN	IE and Malfunction	7	1 <sup>st</sup>	General	PS	Coloplast Titan
Patient 4	70	HIV	IE and pain	0.5	3 <sup>rd</sup>	General	PS	AMS CX
Patient 5	66	DM, stroke, PCa s/p RP	IE and malfunction	15	3 <sup>rd</sup>	General	PS	AMS CX
Patient 6	71	PCa s/p RP	Proximal crossover/pain	6	1 <sup>st</sup>	General	PS	Coloplast Titan

*Abbreviations:* AMS = American Medical Systems; DM = Diabetes Mellitus; IE = impending erosion; HIV = human immunodeficiency virus; HTN = Hypertension; PCa = prostate cancer; PS = Penoscrotal; RP = radical prostatectomy.

penetrative intercourse without recurrence of IPP malposition, malfunction, or device infection. No complications have been observed thus far with ECT. However, potential complications of this procedure include infection, extrusion recurrence, and cylinder erosion.

## DISCUSSION

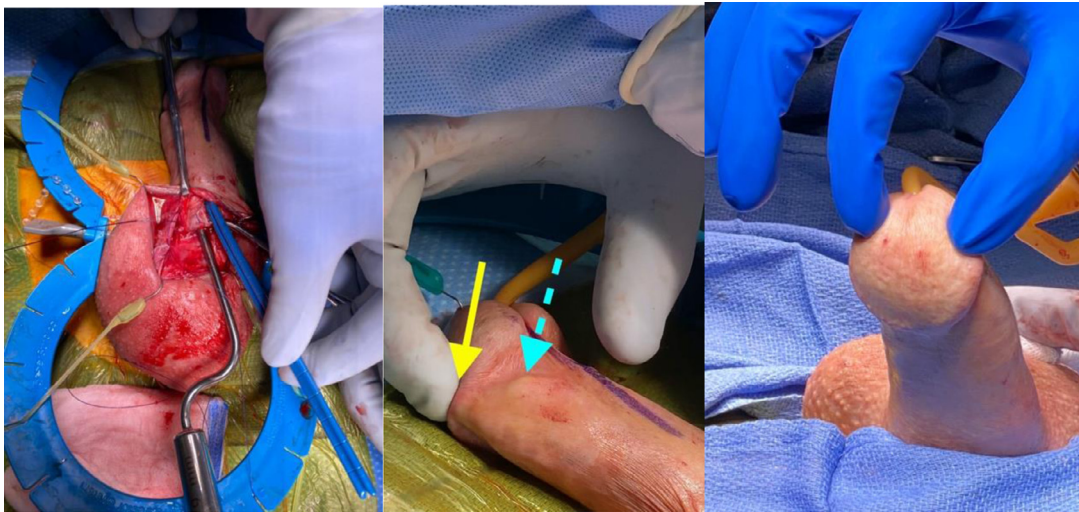
Distal penile implant impending erosion is not a common complication but can be a serious one once the device is eroded through the skin. Risk factors for cylinder extrusion include aggressive dilation, placement of a cylinder into a very narrow corporal cavity, previous distal intervention for management of priapism, or chronic mechanical pressure from the cylinder.<sup>8–10</sup> Floppy glans, on the other hand, doesn't carry much risk other than difficulty with intercourse. In some cases, this condition can be secondary to under-sizing of the penile implant. In this series, we report outcomes using a different approach, extracapsular tunneling, that can help resolve impending cylinder erosion and undersized floppy glans, among other complications, without the use of a counter-incision.

In the hands of an inexperienced surgeon, impending cylinder erosion can be a challenging task to manage. Historically, surgeons have attempted to manage impending erosions with different techniques, most of which involved a distal counter-incision. Mulcahy proposed the use of a distal corporoplasty. This involved a distal incision to expose and incise the surgical pseudo-capsule around the prosthesis. This technique helps the surgeon create a new surgical plane behind the pseudo-capsule's sheath to secure the cylinder's tip and use the sheath and tunica albuginea to cover the implant and prevent recurrence.<sup>11,12</sup> Shindel et al<sup>13</sup> proposed a different approach using a transglanular incision with reseating of the distal tip of the IPP.<sup>13</sup> More recently, Antonini and colleagues combined the concepts of these two techniques.<sup>14</sup> Their novel approach involved a distal

corporal anchoring stitch placed via a subcoronal corporotomy that incises the tunica albuginea and the surgical pseudo-capsule. The "anchoring stitch" is placed through the small ring of the distal cylinder in order to redeliver the implant through a new channel using the Furlow device. A small incision is then made on the glans at the location of the suture and the 'stitch is anchored' by tying the down the knot that is then buried underneath the glans tissue.

To our knowledge, there is only one technique described in the literature for the management of cylinder extrusion that does not involve a counter-incision. Karpman et al<sup>15</sup> reported a simplified technique that uses biologic acellular matrix as a distal biologic cap that covers the distal tip of the cylinder to prevent cylinder erosion. This technique involves cylinder placement within the original intracapsular space and utilizes the biologic cap as an "extra layer" to decrease the risk of extrusion recurrence.

Similar to the distal biologic cap, the ECT technique allows the surgeon to manage the extrusion without the need for a counter-incision. This minimizes dissection and provides for a theoretical advantage on risk of infection. However, as opposed to other techniques, ECT provides the additional benefits of not requiring a graft and utilizing a neo-tract within the tunica albuginea. Cadaver studies have described intracavernosal pillars, or different compartments, within each corporal body.<sup>16</sup> Ventrolateral corporal dilation during initial penile prosthesis insertion guides the penile prosthesis into what has been considered a weaker area of the tunica albuginea near the 5 to 7 o'clock position. A review of the current penile prosthetic literature suggests that cylinders placed in this area have an increased incidence of impending cylinder erosion.<sup>17</sup> In theory, ECT takes advantage of the dorsal compartment of the corpora that lies posterior to the surgical capsule. By going into a new channel, the cylinder will theoretically have a decreased risk of infection and, when inflated, will collapse the previous intracapsular space.



**Figure 4.** A. Brooks Dilator is present in the new extracapsular space while the measuring stick is in the original intra-capsular space. B. Close up image demonstrates the difference between the extracapsular space (yellow solid arrow) vs the intracapsular space (blue dotted arrow). C. Proper placement of bilateral cylinders after ECT.

Management options for correction of a floppy glans include glanulopexy, distal penile-plasty and, in cases of a significantly undersized implant, removal and replacement of the penile prosthesis.<sup>5</sup> Patients with a floppy or unstable glans who present in a delayed setting may have the surgical pseudocapsule already formed. Re-dilation through a capsule that has already formed may be challenging for the inexperienced surgeon. In our small series, one patient presented 10 months after his original penile prosthesis placement (Figure 1). During the surgery, re-dilation through the intracapsular space was not possible and ECT allowed for proper cylinder placement (Figure 4).

This study has several limitations. It only represents a small number of cases with short follow-up. Therefore, the long-term durability of this approach to treat impending cylinder erosions remains unknown. The proximal ECT procedure may also have limitations itself. The surgeon should be aware of whether the patient's original surgery was performed via an infrapubic or penoscrotal approach as initial dilation may help determine where the sinusoidal tissue should be found. Most penoscrotal dilations are done ventro-laterally which should, theoretically, provide for a dorsal sinusoidal space to be created posterior to the capsule. On the other hand, infrapubic initial dilations tend to be more dorsolateral and will likely have the extra-capsular sinusoidal tissue more ventrally. Not accounting for these distinctions may increase the risk of perforating the tunica albuginea or the urethra at the time of ECT. Moreover, in the setting of severe corporal fibrosis or patients who have corporal bodies with less volume (or "girth"), ECT may be challenging to be performed. In these cases, the surgeon may attempt to create the extracapsular window. However, if the corporal sinusoidal tissue is unable to be identified and/or initial extracapsular dilation is difficult, ECT should not be completed.

## CONCLUSION

ECT is a viable technique that may treat distal cylinder impending erosion and floppy glans syndrome in the setting of an undersized penile prosthesis, among other corporal dilation-related complications, with minimal increase in operative time. This technique is simple and can be safely performed by both high and low volume surgeons. It avoids the need of additional counter incisions on the penis and, therefore, theoretically decreases the risk of infection. Further outcomes analysis will elucidate the role of this approach for prosthetic surgeons.

**Corresponding Author:** Jonathan Clavell-Hernández, MD, Adjunct Assistant Professor, University of Texas McGovern Medical School, Division of Urology, St Joseph Medical Center, Mail: 1315 St Joseph Pkwy Ste 1700, Houston, TX 77002, USA. Tel: 713-652-5011; Fax: 713-654-4056 E-mail: [jonathan.clavell@gmail.com](mailto:jonathan.clavell@gmail.com)

*Conflict of Interest:* Jonathan Clavell-Hernández is a consultant for Boston Scientific/AMS and Coloplast.

*Funding:* None.

## REFERENCES

1. Ziegelmann M, Kohler TS, Baile GC, et al. Surgical selection and counseling. *Transl Androl Urol* 2017;6:609–619.
2. Henry GD, Laborde E. A review of surgical techniques for impending distal erosion and intraoperative penile implant complications: Part 2 of a three-part review series on penile prosthetic surgery. *J Sex Med* 2012;9:927–936.
3. Henry GD, Wilson SK, Delk JR II, et al. Penile prosthesis cultures during revision surgery: A multicenter study. *J Urol* 2004;172:153–156.

4. Henry GD, Wilson SK. Updates in inflatable penile prostheses. *Urol Clin North Am* 2007;34:535–547 vi.
5. Bickell M, Manimala N, Parker J, et al. Floppy glans syndrome: pathogenesis and treatment. *Sex Med Rev* 2016;4:149–156.
6. Morey AF. Reconstructing penile supersonic transporter (SST) deformity using glanulopexy (Glans fixation). *J Urol* 2005;174:969.
7. Ball TP. Surgical repair of penile SST deformity. *Urology* 1980;15:603–604.
8. Mulcahy JJ. The prevention and management of noninfectious complications of penile implants. *Sex Med Rev* 2015;3:203–213.
9. Stember DS, Kohler TS, Morey AF. Management of perforation injuries during and following penile prosthesis surgery. *J Sex Med* 2015;12(suppl 7):456–461.
10. Brant WO, Garcia MM, Bella AJ, et al. T-shaped shunt and intracavernous tunneling for prolonged ischemic priapism. *J Urol* 2009;181:1699–1705.
11. Brant MD, Ludlow JK, Mulcahy JJ. The prosthesis salvage operation: Immediate replacement of the infected penile prosthesis. *J Urol* 1996;155:155–157.
12. Carson CC, Mulcahy JJ, Gover FE. Efficacy, safety, and patient satisfaction outcomes of the AMS 700CX inflatable penile prosthesis: results of a long-term multicenter study. AMS 700CX Study Group. *J Urol* 2000;164:376–380.
13. Shindel AW, Brant WO, Mwamukona K, et al. Transglanular repair of impending penile prosthetic cylinder extrusion. *J Sex Med* 2010;7:2884–2890.
14. Antonini G, Busetto GM, Del Giudice F, et al. Distal corporal anchoring stitch: A technique to address distal corporal cross-overs and impending lateral extrusions of a penile prosthesis. *J Sex Med* 2017;14:767–773.
15. Karpman E, DiGiorgio L, Carrion RE. Distal biologic cap for impending distal erosion. *J Sex Med* 2020;17:551–555.
16. Pagano MJ, Weinber AC, Deibert CM, et al. Penile intracavernosal pillars: Lessons from anatomy and potential implications for penile prosthesis placement. *Int J Impot Res* 2016;28:114–119.
17. Wilson SK. Postoperative pitfalls and their solutions in: *Pearls, Perils and Pitfalls of Prosthetic Urology*. AR, USA: Calvert McBride Publishing; Fort Smith; 2008. p. 45.