

Antiphospholipid Antibody Syndrome Associated with Graves' Disease Presenting As Inferior Vena Cava Thrombosis with Bilateral Lower Limb DVT

Ankur Jain

Department of Medicine, Maulana Azad Medical College, Bahadur Shah Zafar Marg, New Delhi, India.

ABSTRACT: We report a case of a 60-year-old lady who presented with bilateral lower limb swelling and a thyroid swelling with clinical features consistent with thyrotoxicosis. Investigations revealed the presence of a thrombus in bilateral external, internal iliac veins, and inferior vena cava extending up to its infrahepatic part. Hormone profile and radioiodine uptake scan confirmed the diagnosis of Graves' disease. Further workup revealed the presence of antiphospholipid antibodies (confirmed after a repeat test at 12 weeks). The patient was treated with antithyroid drugs and anticoagulants. The patient improved with normalization of thyroid function and partial recanalization of the infrahepatic part of inferior vena cava. Hyperthyroidism has been implicated as a potential hypercoagulable state; however, the association of Graves' disease with antiphospholipid antibody syndrome is limited to isolated case reports. This case highlights a new mechanism underlying hypercoagulability associated with Graves' disease.

KEYWORDS: Graves' disease, antiphospholipid antibody syndrome, inferior vena cava thrombosis

CITATION: Jain. Antiphospholipid Antibody Syndrome Associated with Graves' Disease Presenting As Inferior Vena Cava Thrombosis with Bilateral Lower Limb DVT. *Clinical Medicine Insights: Case Reports* 2014;7:37–39 doi: 10.4137/CCRep.S15302.

RECEIVED: March 9, 2014. **RESUBMITTED:** March 24, 2014. **ACCEPTED FOR PUBLICATION:** March 25, 2014.

ACADEMIC EDITOR: Athavale Nandkishor, Associate Editor

TYPE: Case report

FUNDING: Author discloses no funding sources.

COMPETING INTERESTS: Author discloses no potential conflicts of interest.

COPYRIGHT: © the authors, publisher and licensee Libertas Academica Limited. This is an open-access article distributed under the terms of the Creative Commons CC-BY-NC 3.0 License.

CORRESPONDENCE: drankur589@yahoo.in

Introduction

Hyperthyroidism has been implicated as a procoagulant state since many years. Multiple mechanisms underlying this have been proposed including elevated Factor VIII levels and high fibrinogen levels seen in this condition. However, the association of hypercoagulability with Graves' disease because of the presence of antiphospholipid antibody syndrome has been extremely rare and is limited to isolated case reports in the literature. Presence of antiphospholipid antibodies in Graves' disease represents a unique mechanism of hypercoagulability. The present case highlights the importance of testing for these antibodies in patients with Graves' disease and following up the patients closely who are tested positive for any future thrombotic episode as well as highlights the fact that Graves' disease might account for sizeable proportion of the so-called "idiopathic" thrombosis.

Case Report

A 60-year-old lady presented to our emergency with the complaints of swelling over bilateral lower limbs up to the thigh since 10 days. The patient was well 10 days back when she developed swelling over the left lower limb, which was followed in 2 days by appearance of swelling over the right lower limb. The patient had history of increased sweating, anxiety, and weight loss of about 7 kg since four months. There was no associated pain, numbness, orthopnea, breathlessness, respiratory complaints, fever, anorexia, postmenopausal bleeding, pain abdomen, jaundice, hematemesis, malena, history suggestive of an autoimmune disorder or history of heart disease, prolonged immobilization, recent surgery, and fracture. The patient was nonsmoker, nonalcoholic, nondiabetic, and nonhypertensive, and there was no past or family history of any thrombotic episode, any autoimmune disorder, or recurrent abortions during childbearing age. On examination, patient

was lean and thin with BMI of 18 kg/m². General physical examination revealed warm extremities with wet palms. The BP was 110/60 mmHg and pulse rate 110/minute (regular). Pallor was present, but there was no icterus, cyanosis, clubbing, and lymphadenopathy. There was presence of a midline neck swelling, moving with deglutition and on palpation; thyroid was diffusely enlarged, soft in consistency with the presence of a bruit over it. There was generalized edema over the bilateral lower limbs up to the thigh, and skin over it was shiny, darkly pigmented, and warm to touch (Fig. 1). Cardiovascular, respiratory, abdominal, and neurological examinations were unremarkable.

On clinical suspicion of deep vein thrombosis (DVT), venous Doppler ultrasound for patient was done which revealed the presence of an echogenic thrombus in bilateral external iliac veins, extending into the common iliacs and the infrahepatic portion of inferior vena cava with periportal collateral formation. Patient's Contrast Enhanced CT (CECT) abdomen revealed the evidence of an intraluminal filling defect in the hepatic and infrahepatic parts of inferior vena cava and bilateral common iliac, internal and external iliac veins, and right common femoral vein suggestive of thrombosis (Fig. 2). The suprahepatic part of inferior vena cava was patent with evidence of multiple tortuous collaterals in perirectal region and anterior abdominal wall. Portal vein was dilated, measuring 14 mm in diameter, and splenic vein was dilated measuring 12 mm in diameter. There was no mass lesion in the adnexa or abdomen, and small and large bowel loops had normal mural thickness. There was no lymphadenopathy or free fluid in abdomen.

The patient's routine investigations revealed hemoglobin 102 g/L, total leukocyte count $7.300 \times 10^9/L$, differential count-polymorphs 0.66, lymphocytes 0.28, eosinophils 0.4, monocyte 0.2, platelet count $63 \times 10^9/L$, erythrocyte sedimentation rate (ESR) 56 mm/hour, total serum calcium 2.25 mmol/L, and phosphorus 1.13 mmol/L. Kidney function and liver function tests were normal. Coombs test

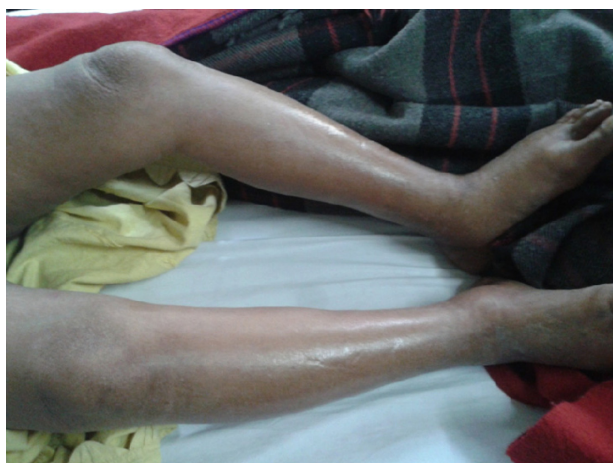

Figure 1. Patient with bilateral lower limb DVT showing edema up to the thigh with overlying shiny skin.

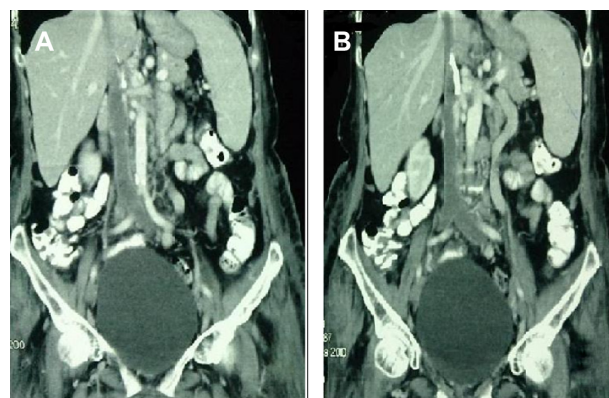


Figure 2. CECT abdomen of the patient showing a thrombus in bilateral external iliac, internal iliac veins, and inferior vena cava up to its infrahepatic part.

was negative. Coagulation profile was prothrombin time – test = 11.40 seconds, control = 12.20 seconds, INR = 1.26, activated partial thromboplastin time – test = 40.38 seconds, control = 29.0 seconds, mixing = 35.0 seconds, and fibrinogen 3.50 g/L, and D-dimers were negative. Factor VIII level was 110% (normal 50–150%). VDRL test was positive, and treponema pallidum hemagglutination assay (TPHA) test was negative. Anti-b2GP1 antibody (IgM, tested by ELISA, using b2GP1 as the substrate) was 42.45 U/mL (normal <8 U/mL). TSH was low (<0.005 mIU/L), and FT3 = 3.3 pmol/L (normal), FT4 = 53.41 pmol/L (9–16 pmol/L), and anti-TPO = 1,200 kIU/L (normal < 34 kIU/L). Patient's radioiodine uptake scan revealed diffusely increased uptake. Uptake at 2 hours was 20% (normal 5–15%) and at 24 hours was 45% (normal 15–35%), thereby confirming the diagnosis of Graves' disease. Serum homocysteine level was 7.53 μmol/L (4.4–10.8 μmol/L). Protein C, Protein S, and antithrombin III levels were normal. ANA and double-stranded DNA were negative, and malignancy workup including CA-125, CEA, alpha fetoprotein (AFP), and β-hCG was negative. Chest X-ray was normal. HIV-1 and HIV-2, hepatitis B surface antigen, and anti-HCV were negative. Genetic workup for Factor V Leiden mutation and prothrombin gene mutation was negative. 2D-echocardiography (2D-ECHO) was normal. Patient was started on anticoagulation, and initially combined enoxaparin (40 mg subcutaneously twice daily) and warfarin (5 mg once daily) for five days followed by oral warfarin maintaining the INR between 2 and 3. The patient was also started on antithyroid drugs (carbimazole, 10 mg thrice daily) with propranolol (40 mg twice daily) along with compression stocking of the lower limbs and leg elevation. The patient was followed up with INR, and repeat anti-b2GP1 antibody done after three months tested positive (IgM 40.30 U/mL), thus confirming the diagnosis of antiphospholipid antibody syndrome. The patient improved symptomatically with significant reduction in leg swelling and disappearance of thyrotoxic symptoms. The patient's ESR normalized after three months



of the treatment; however, she continued to have thrombocytopenia ($98 \times 10^9/L$), which increased from the baseline value. Repeat CECT abdomen of the patient done after three months of the treatment revealed partial recanalization of the infrahepatic part of inferior vena cava. The patient is still under our follow-up.

Discussion

Hyperthyroidism as a hypercoagulable state and a predisposing factor for venous thromboembolism has been studied for quite some time, and literature provides examples of venous thrombosis associated with thyrotoxicosis. Exact mechanism of hypercoagulability in thyrotoxicosis is not known; however, available literature provides insights into various proposed mechanisms underlying the hypercoagulable state. Increased Factor VIII levels have been associated with cerebral venous thrombosis,¹ and high fibrinogen levels seen in overt hyperthyroidism have been implicated to result in a procoagulant state seen in these patients² as is increased Factor X activity in subclinical hyperthyroidism.³ Our case had normal levels of both Factor VIII as well as fibrinogen. Nabriski et al found 43% prevalence of antiphospholipid antibodies (IgG) in Graves' disease and 7% prevalence of IgM type in autoimmune thyroid disease; however, they did not find any positive clinical events in the patients for these antibodies and considered their presence to be an epiphenomenon.⁴ This has been explained by the molecular mimicry between the epitopes of TSH receptors and b2 glycoprotein 1.⁵ Since then, very few cases have been published regarding the association of Graves's disease with antiphospholipid antibody syndrome presenting with cerebrovascular accident,^{6,7} Budd–Chiari syndrome,⁸ and recurrent venous thrombosis.⁹ None of the published data to our best understanding show the occurrence of extensive inferior vena cava thrombosis and bilateral lower limb DVT in patients having Graves' disease with antiphospholipid antibody syndrome. Graves' disease may therefore act as a risk factor for venous thrombosis possibly because of the induction of antiphospholipid antibody syndrome. Our patient had false positive VDRL test (demonstrating anticardiolipin antibodies indirectly); therefore, antiphospholipid antibody syndrome was confirmed by the presence of anti-b2GP1 antibodies (measured by ELISA using b2GP1 as the substrate), which were found to be elevated with a very high titer and remained elevated after 12 weeks of follow-up. Presence of thrombocytopenia is a well-documented feature of Grave's disease and represents an immune phenomenon; however, platelet counts return to normal with the initiation of antithyroid drugs. Persistent thrombocytopenia with slow recovery of platelet counts in our case further highlights the antiphospholipid syndrome as the cause of low platelet counts.

Conclusion

Graves' disease represents a risk factor for both venous and arterial thrombosis, and this may be explained by the induction of antiphospholipid antibody syndrome in these patients as a result of autoimmune phenomenon. Graves' disease may be considered as one of the causes of "idiopathic DVT." The association of antiphospholipid antibody syndrome and Graves' disease is unique, and Graves' disease may represent one of the etiology of secondary antiphospholipid antibody syndrome. Patients with Graves' diseases with clinical evidence of hypercoagulability must be tested for antiphospholipid antibodies.

Author Contributions

AJ completed the patient evaluation and investigated the patient. AJ is also the treating physician. AJ wrote the manuscript, made critical revisions and reviewed and approved of the final manuscript.

DISCLOSURES AND ETHICS

As a requirement of publication the authors have provided signed confirmation of their compliance with ethical and legal obligations including but not limited to compliance with ICMJE authorship and competing interests guidelines, that the article is neither under consideration for publication nor published elsewhere, of their compliance with legal and ethical guidelines concerning human and animal research participants (if applicable), and that permission has been obtained for reproduction of any copyrighted material. The author states that appropriate consent from the patient has been obtained before taking pictures and regarding publication of the case. This article was subject to blind, independent, expert peer review. The reviewers reported no competing interests.

REFERENCES

1. Verberne HJ, Fliers E, Prummel MF, Stam J, Brandjes DP, Wiersinga WM. Thyrotoxicosis as a predisposing factor for cerebral venous thrombosis. *Thyroid*. 2000;10:607–10.
2. Dorr M, Robinson DM, Wallaschofski H, et al. Low serum thyrotropin is associated with high plasma fibrinogen. *J Clin Endocrinol Metab*. 2006;91:530–4.
3. Erem C. Blood coagulation, fibrinolytic activity and lipid profile in subclinical thyroid disease: subclinical hyperthyroidism increases plasma factor X activity. *Clin Endocrinol (Oxf)*. 2006;64:323–9.
4. Nabriski D, Ellis M, Ness-Abramof R, Shapiro M, Shenkman L. Autoimmune thyroid disease and antiphospholipid antibodies. *Am J Hematol*. 2000;64:73–5.
5. Dagenais P, Urowitz MB, Gladman DD, Norman CS. A family study of the antiphospholipid syndrome associated with other autoimmune diseases. *J Rheumatol*. 1992;19:1393–6.
6. Khochtali I, Hamza N, Gassab E, et al. Graves' disease associated with cerebrovascular disease and antiphospholipid antibody syndrome. *Int J Endocrinol*. 2010;2010:1–3.
7. Mayaudon H, Crozes P, Riveline JP, Boyer B, Simon P, Bauduceau B. Antiphospholipid antibodies in Basedow disease. *Presse Med*. 1994;23:1496.
8. Mouelhi L, Chaieb M, Debbeche R, et al. Association Budd Chiari syndrome, antiphospholipid syndrome and Graves' disease. *Tunis Med*. 2009;87:164–6.
9. Hofbauer LC, Spitzweg C, Heufelder AE. Graves' disease associated with the primary antiphospholipid syndrome. *J Rheumatol*. 1996;23:1435–7.